IS-6 Effect Of Na^+ In The Uptake Of Tc-99m-MIBI: Comparison With Tc-99m-Tetrofosmin.

A.S. Arbab, K. Koizumi,* K. Toyama, T. Arai, T. Araki. (Yamanashi Med. Univ., * Tokyo Med. Univ.)

The effect of Na^+ in the uptake of Tc-99m-MIBI was studied with primary culture of rat myocardial cells and the results were compared with that of Tc-99m-tetrofosmin.

The cells were equilibrated either in Na^+ containing or Na^+ free buffers. The cells were treated with dimethyl amiloride (DMA), a Na^+/H^+ antiport inhibitor, and monensin, an ionophore that stimulates Na^+ accumulation inside the cell.

In Na^+ free buffer, significant increased uptake of Tc-99m-MIBI was observed. Monensin stimulated the uptake of Tc-99m-MIBI but more in Na^+ containing buffer. DMA inhibited the uptake of Tc-99m-MIBI, partially, even in the presence of monensin. No significant change of Tc-99m-tetrofosmin uptake was observed in Na^+ free buffer, although DMA inhibited the uptake. However, DMA showed no inhibitory effect on Tc-99m-tetrofosmin uptake in presence of monensin.

Part of the uptake of Tc-99m-MIBI involves Na^+/H^+ antiport system and during its uptake Tc-99m-MIBI may behave as Na^+ or its uptake may be related to intracellular Na^+ concentration.

IS-7 COMPARISON OF SESTAMIBI, TETROFOSMIN, AND Q12 RETENTION DURING VASODILATION IN PORCINE MYOCARDIUM

I. Matsunari, F. Haas, N. Nguyen, G. Stöcklin, R. Senekowistch-Schmidtke, M. Schwaiger. *Technische Universität München, Germany*

The aim of this study was to compare the myocardial retention of sestamibi (MIBI), tetrofosmin (TF), and Q12 during vasodilation. We used a pig model with (n=6) or without (n=3) coronary occlusion. Each pig received a simultaneous injection of MIBI and either TF or Q12 labeled with either Tc-99m or Tc-95m during dipyridamole induced vasodilation. Absolute myocardial retention of each tracer was calculated from the myocardial tracer activity and arterial input function. Figure shows absolute retention for each tracer vs microsphere flow.

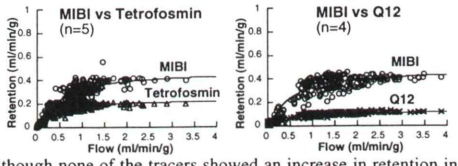

Although none of the tracers showed an increase in retention in direct proportion to flow, MIBI demonstrated greater absolute tissue retention and higher increments in retention than did TF or Q12. Thus, sestamibi displays more suitable physiologic characteristics as a flow tracer.

IS-8 RADIONUCLIDE (RN) AND ULTRA-SONOGRAPHIC (US) STUDY OF THE NEUROLEPTICS EFFECT ON MYOCARD CONTRACTILE ABILITY

Irić V, Matović M.,Vučković M., Đukić-D. S.,Mijatović Lj., Janković S. (Univ. Clinical Center, Kragujevac, Yugoslavia)

The aim of this study was evaluating effects of the neuroleptics (derivatives of phenotiazine, chlorpromazine, tioksantins and butirophenons) on the myocard contractility.

The controlled clinical examination was done on a group of 12 young psychiatric patients (7 male and 5 female, age from 25 to 35 years). Using RN and US, left ventricle global ejection fraction (LVGEF) was estimated before neuroleptic treatment and 3 months later (table 1).

LVGEF	before therapy	3 months therapy
RN	71.08±9.64 %	60.25±6.85 %
US	69.38±8.70 %	59.03±5.53 %

In all patients, except one, 3 months after beginning of neuroleptic treatment, the fall of LVGEF was registered with both methods, RN and US ($p<0.01$). Correlation between LVGEF derived by RN and US methods was high too($r=0.89$).

Based on our modest experience it can be concluded that neuroleptics negative inotropic effect, is probably cause of the fall of LVGEF.

IS-9 REVERSE REDISTRIBUTION ON POST-PTCA MYOCARDIAL SPECT IS RELATED TO RESTENOSIS.

HC Song, HS Bom, JJ Min, HJ Jeong, JY Kim, MH Jeong, JC Kang. Chonnam Natl. Univ. Hosp., Korea

The aim of this study was to evaluate the relation between restenosis and segments (segs) showing reverse redistribution (RRd), reversible perfusion defect (Rv), and normal uptake (N) on post-PTCA myocardial perfusion SPECT (M-SPECT).

Sixteen patients(M:F=14:2, mean age 55±9) underwent M-SPECTs 7.8±7.4 weeks after PTCA. Fourteen segs showed RRd(51.9%), 8 N(29.6%), 5 Rv(18.5%) in PTCA-related coronary arterial territories. Follow-up coronary angiographies were performed after 19.9±11.9 weeks.

Restenoses were noted in 3/8 (37.5%) segs with N, 3/5 (60%) segs with Rv, and 10/14 (71.4%) segs with RRd. Therefore, RRd as well as Rv on post-PTCA M-SPECT were related to restenosis.

IS-10 Clinical usefulness of combined diagnosis by EBT and TL-201 myocardial SPECT for the detection of coronary artery disease.

K. Aoyagi, T. Inoue, Y. Tomaru, K. Endo. Gunma University School of Medicine

The aim of this study is to evaluate the clinical usefulness of combined diagnosis of coronary artery calcification and myocardial ischemia in detecting CAD. The 34 patients were received electron beam computer tomography(EBT) and SPECT . Final diagnosis for CAD was based on the results of CAG. Diagnostic accuracy of EBT, SPECT and combined diagnosis of EBT and SPECT were statistically compared. Only in LAD lesion, a sensitivity of SPECT was improved by combined diagnosis but its specificity was sacrificed. There was no reason to combine results of SPECT and EBT as a screeningtest for detecting CAD before CAG is performed.

IS-11 Radionuclide ventriculography in Dengue Fever.

Malhotra A.;Biswas A.;Behl V.K.;Wali J.P.;Bandopadhyaya G.P.; Rakesh Kumar. (A.I.I.M.S, New Delhi 110029,India.)

India experienced an epidemic of Dengue Haemmorhagic Fever (DHF) in September 1996.110 patients (M:F;71:39) of DHF with age range 20-50 yr were admitted to AIIMS. Radionuclide ventriculography (RNV) was done in 18 patients of Dengue Shock Syndrome (DSS)

Results revealed enlarged left ventricle in 60% cases and severe global hypokinesia in 11 (61%) cases along with depressed LVEF of 40%(33-47%). Four months serial follow-up showed return of ejection fraction to normal values 63%(60-66%)with significant improvement in contractions, and the patients are now asymptomatic.

We conclude that in patients of DSS, there is transient derangement of cardiac functions due to myocarditis.

Presented by Medical*Online