

The value of combined ^{99m}Tc -Sn-colloid and ^{99m}Tc -RBC scintigraphy in the evaluation of a wandering spleen

Masashi SHIMIZU, Hikaru SETO, Masanari KAGEYAMA, Yi-wei WU, Toshirou NAGAYOSHI, Yuichi KAMISAKI, Makoto MORIJIRI, Naoto WATANABE and Masao KAKISHITA

Department of Radiology, Faculty of Medicine, Toyama Medical and Pharmaceutical University

Wandering spleen is the term commonly applied to splenic hypermobility that results from laxity or maldevelopment of its suspensory ligaments. It comes to medical attention usually as an abdominal mass, or when the spleen undergoes torsion. Diagnosis on clinical grounds alone is rarely made, and ultrasonography, CT and MRI findings have no specific characteristics for this condition. ^{99m}Tc -labeled colloid taken up by the spleen may provide a specific diagnosis. We report a case of wandering spleen, in which the preoperative diagnosis was made on the basis of sequential liver-spleen scintigraphy with ^{99m}Tc -Sn-colloid and blood-pool scintigraphy with ^{99m}Tc -RBC. This is a rare case, in which hypermobility was assessed by sequential ^{99m}Tc -Sn-colloid scintigraphy, and to our knowledge, is the first case in which ^{99m}Tc -RBC scintigraphy provided useful information on splenic blood volume and its location.

Key words: wandering spleen, ^{99m}Tc -Sn-colloid, liver-spleen scintigraphy, blood-pool scintigraphy, ^{99m}Tc -RBC

INTRODUCTION

WANDERING SPLEEN is an uncommon condition in which the spleen is located lower than in the left upper quadrant¹ and is most often brought to the physician's attention when the spleen simulates a mass or undergoes torsion.^{1,2} It is characterized by laxity or absence of supporting splenic ligaments, with splenomegaly also originally considered to be the major predisposing factor.¹⁻⁴ Diagnosis on clinical grounds alone is rarely made, and findings of ultrasonography, CT and MRI suggest no specific diagnosis.^{3,4,6} ^{99m}Tc -labeled colloid taken up by the spleen may demonstrate specific characteristics for this condition.^{4,7} We report a case of wandering spleen, in which sequential ^{99m}Tc -Sn-colloid scintigraphy was of great clinical value in the evaluation of spleen mobility and size change, and moreover, ^{99m}Tc -RBC scintigraphy provided useful information on the vascularity and blood volume of the spleen.

CASE REPORT

A 35-year-old woman received medication at a local hospital for membrano-proliferative glomerulonephritis. Marked splenomegaly was incidentally found by ultrasonography and liver-spleen scintigraphy with ^{99m}Tc -Sn-colloid (Fig. 1) Sep. 1990. She had subsequently undergone a follow-up study for kidneys and spleen by ultrasonography. She had previously noticed splenic mobility, but recently she became aware of a large mass in the pelvis located at a site lower than noticed before. She was then admitted for further examination of the giant pelvic mass in July, 1994. On physical examination, a hard, tender pelvic mass was found. Pancytopenia was seen due to hypersplenism (RBC 372×10^4 , WBC 3700, Platelet 8.4×10^4 per mm^3). The other laboratory data were within normal limits. Ultrasonography, CT and MRI findings showed a large, solid mass in the pelvis. Angiography, performed for preoperative planning, showed dilatation of the splenic artery supplying blood to a giant spleen in the pelvic region (Fig. 2). The second liver-spleen scintigraphy was performed ten minutes after intravenous injection of 185 MBq of ^{99m}Tc -Sn-colloid. The spleen was more enlarged and displaced lower than in the previous study (Fig. 3). ^{99m}Tc -RBC scintigraphy was performed to estimate the blood volume of the spleen.

Received January 25, 1995, revision accepted March 24, 1995.

For reprint contact: Masashi Shimizu, M.D., Department of Radiology, Faculty of Medicine, Toyama Medical and Pharmaceutical University, 2630 Sugitani, Toyama 930-01, JAPAN.

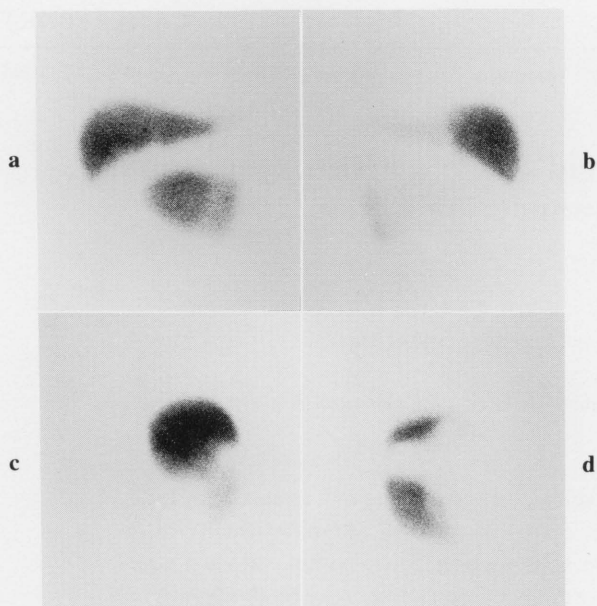


Fig. 1 The anterior (a), posterior (b), right lateral (c) and left lateral (d) views, respectively. The first ^{99m}Tc -Sn-colloid scintigraphy reveals marked splenomegaly with the spleen located lower than in the left upper quadrant.

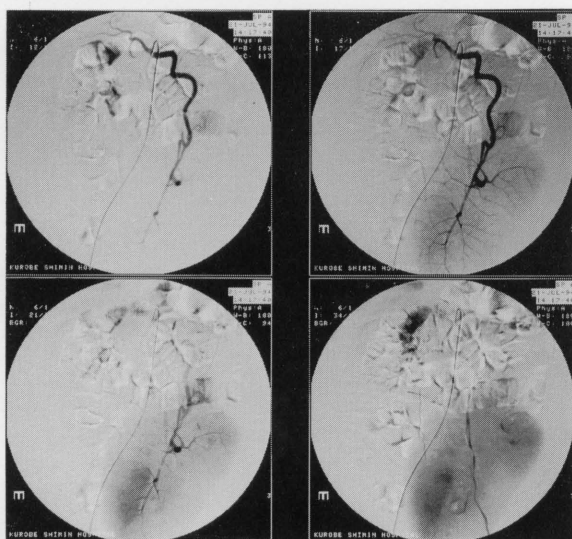


Fig. 2 Angiography shows dilatation of the splenic artery supplying blood to a giant spleen in the pelvic region.

Radionuclide angiography with ^{99m}Tc -RBC (740 MBq) revealed increased arterial flow to the giant pelvic mass. Blood-pool scintigraphy conducted ten minutes later revealed a giant hypervascular mass in the pelvis, but no vascular component in the left upper quadrant. Because the spleen was located in the anterior abdomen, we did volume measurement of the left ventricle on an equilibrium ventriculogram and calculated the blood volume of the giant spleen with the following equation: Spleen volume

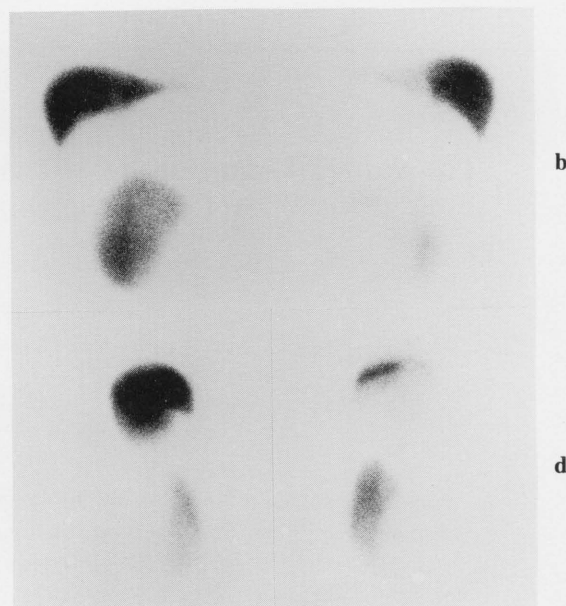

Fig. 3 The anterior (a), posterior (b), right lateral (c) and left lateral (d) views, respectively. The second ^{99m}Tc -Sn-colloid scintigraphy reveals the spleen to be more enlarged and displaced lower as compared to the first study.

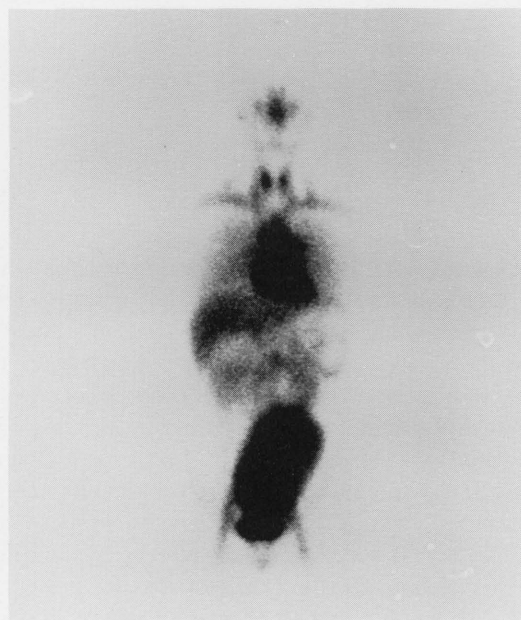


Fig. 4 Blood-pool scintigraphy in the anterior view shows a giant hypervascular mass in the pelvis, but no vascular component in the left upper quadrant. Blood volume of the spleen was found to be 690 ml.

$$= \frac{(\text{Blood-sample volume}) \times (\text{Spleen count rate})}{(\text{Blood-sample count rate})}$$

We estimated the blood volume of the spleen to be 690 ml (Fig. 4).

Splenectomy was performed to prevent torsion and improve the pancytopenia. At surgery, the spleen weighed

580 g and measured $16.5 \times 10.5 \times 6.0$ cm. Pathological examination revealed chronic congestion of the spleen. After splenectomy the pancytopenia improved (RBC 429×10^4 , WBC 6500, Platelet 8.6×10^4 per mm^3).

DISCUSSION

"Wandering spleen" (also known as "ectopic spleen," "floating spleen," and "splenic ptosis") is very rare and occurs primarily in women. Agenesis and laxity of the suspensory ligaments of the spleen are the most frequent causes.¹ Splenomegaly may enhance the potential for migration and torsion in the presence of an embryologic defect, but splenomegaly alone does not lead to abnormality of the splenic position.⁴ Many patients with a wandering spleen are symptomatic early in life, and occasionally acute abdominal pain may result from torsion of the splenic pedicle.¹ Because of the rarity of this condition and the variety of clinical presentations, diagnosis on clinical grounds alone is difficult. The main clinical finding is usually an abdominal or pelvic mass.⁹

Various techniques have been used to evaluate wandering spleen. Ultrasonography, CT and MRI usually demonstrate a solid mass, but may not disclose the nature of the mass.^{6,9} Definitive preoperative diagnosis is achieved only by angiography,¹ but it is a more invasive technique. Since colloid is taken up specifically by the spleen and liver, the nature of the mass may be established by scintigraphy^{4,7} and $^{99\text{m}}\text{Tc}$ -damaged RBC scintigraphy may also provide a specific diagnosis. When there is twisting of the vascular pedicle producing congestion and/or infarction, radionuclide labeled colloid uptake by the spleen may be diminished or absent, depending upon the degree of compromise in the splenic vascular supply.^{2,3,5}

Previous reports have revealed that a diagnosis of wandering spleen may be made by scintigraphic visualization of the spleen in positions other than the left upper quadrant, but most reports did not show the movement of the spleen.^{4,7,10} This report illustrated the movement of the spleen to a lower position and an increase in size compared to the first scan by sequential $^{99\text{m}}\text{Tc}$ -Sn-colloid scintigraphy.

$^{99\text{m}}\text{Tc}$ -RBC scintigraphy in a case of wandering spleen has not been reported to our knowledge. If it reveals an

intense focal uptake in an abdominal or pelvic mass, and no vascular component in the left upper quadrant, it may be diagnosed as a wandering spleen in shape and in location. Moreover, the blood volume of the spleen may be estimated. In this case, we estimated the blood volume of the spleen to be 690 ml. The estimated volume was found to be relatively accurate when compared with the weight of spleen (580 g) after splenectomy.

It may be concluded that $^{99\text{m}}\text{Tc}$ -Sn-colloid scintigraphy is of great clinical value in the evaluation of a wandering spleen, and $^{99\text{m}}\text{Tc}$ -RBC scintigraphy provides specific diagnosis and useful information regarding the vascularity and blood volume of the spleen for preoperative planning. To our knowledge, this is the first reported case which was assessed by $^{99\text{m}}\text{Tc}$ -Sn-colloid and $^{99\text{m}}\text{Tc}$ -RBC scintigraphy.

REFERENCES

1. Gordon OH, Burrell MI, Levin DC, Levin DC, Mueller CF, Becker JA. Wandering spleen—the radiological and clinical spectrum. *Radiology* 125: 39–46, 1977.
2. Rosenthal L, Libona R, Banerjee K. A neurogenic and radioangiographic study of a patient with torsion of the spleen. *Radiology* 110: 427–428, 1974.
3. Broker FHL, Khettry J, Filler RM. Splenic torsion and accessory spleen: a scintigraphic demonstration. *J Pediatr Surg* 10: 913–915, 1975.
4. Groshar D, Israel O, Front D. Spleen imaging: enlargement of the spleen. *Semin Nucl Med* 13: 295, 1983.
5. Dublin AB, Rosenquist CJ. Diagnosis of splenic torsion: a combined diagnosis approach. *Br J Radiol* 49: 1045–1046, 1976.
6. Hunter TB, Haber K. Sonographic diagnosis of a wandering spleen. *AJR* 129: 925–926, 1977.
7. Groshar D, Israel O, Barzilai A, Front D. The value of scintigraphy in the evaluation of a wandering spleen. *Clin Nucl Med* 11: 42–43, 1986.
8. Early PJ, Sodee DB. Equilibrium gated radionuclide ventriculogram. In *Principles and Practice of Nuclear Medicine*, Sodee DB (ed.), 2nd ed., St. Louis, Mosby-Year Book, Inc., pp. 383–405, 1994.
9. Savolaine ER, Schlembach PJ, Robinson MG, McCann K. Wandering spleen presenting as a pediatric pelvic mass. *Clin Nucl Med* 14: 623–624, 1989.
10. Dodds WJ, Taylor AJ, Erickson SJ, Stewart ET, Lawson TL. Radiologic imaging of splenic anomalies. *AJR* 155: 805–810, 1990.