

## Limited value of interictal brain perfusion SPECT for detection of epileptic foci: High resolution SPECT studies in comparison with FDG-PET

Tamotsu NAGATA,\* Fumiko TANAKA,\*\* Yoshiharu YONEKURA,\*\* Akio IKEDA,\*\* Sadahiko NISHIZAWA,\*\* Koichi ISHIZU,\*\* Hidehiko OKAZAWA,\*\* Kiyohito TERADA,\*\* Nobuhiro MIKUNI,\*\* Itsuo YAMAMOTO,\* Hiroshi SHIBASAKI,\*\* Junji KONISHI\*\* and Rikushi MORITA\*

\*Shiga University of Medical Science

\*\*Kyoto University School of Medicine

Accurate localization of epileptic foci is important for pre-surgical evaluation of patients with medically intractable epilepsy, and F-18 FDG PET has been proved to be a valuable method for this purpose. To examine the clinical value with interictal brain perfusion SPECT, we performed brain perfusion SPECT of Tc-99m HMPAO by means of a high resolution SPECT camera, and compared the results with F-18 FDG PET images and MRI in 10 patients with medically intractable epilepsy. In 9 of 10 patients (90%), FDG PET images showed focal hypo-metabolism in the area corresponding with the results of electroencephalography (EEG). SPECT images, however, demonstrated hypo-perfused lesions which corresponded with hypo-metabolic lesions on FDG PET images in only 6 cases (60%). Although MRI showed abnormal findings in 8 cases, the lesions were not directly related to epileptic foci in 2 cases. In conclusion, FDG PET is a valuable tool for accurate localization of epileptic foci. Brain perfusion SPECT, however, may not always be paralleled to metabolism visualized on FDG PET images.

**Key words:** epilepsy, high resolution SPECT, FDG PET, MRI

### INTRODUCTION

DETECTION of the epileptic foci in partial epilepsy is especially important when surgical therapy is anticipated. Although the diagnosis and classification of epilepsy depend mainly on the use of scalp-recorded electroencephalography (EEG), it is often difficult to lateralize or localize the origin of the seizure. Therefore, invasive or complicated procedures such as subdural or deep electrodes recording as well as video EEG monitoring are often needed for determination of the epileptic foci. On the other hand, magnetic resonance imaging (MRI) has been used for evaluating epileptic patients with structural abnormalities,<sup>1-5</sup> but it does not always match the epileptic foci. The recent detection of functional abnormality in

epileptic foci is expected to play an important role in patient care. Both positron emission tomography (PET) and single-photon emission computed tomography (SPECT) have been reported to be useful for functional imaging in partial epilepsy.

PET with F-18 fluorodeoxyglucose (FDG) has been proved to be a sensitive method for detecting epileptic foci. Initial PET studies in patients with partial seizures have indicated that EEG wise epileptogenic focus may be demonstrated as the site of hypo-metabolic glucose utilization interictally and as that of hyper-metabolic activity ictally. Past reports demonstrated that FDG PET has excellent detectability of epileptic foci as hypometabolic areas in the inter-ictal state,<sup>11-16</sup> but PET study requires a cyclotron, and cannot be applied easily for routine clinical examination. Although a similar observation was reported with cerebral perfusion SPECT,<sup>6-10</sup> the detectability was not as good as PET, and studies of direct comparison of PET and, SPECT are few.<sup>17,18</sup> Recently introduced Tc-99m d,l-hexamethylpropylene amine oxime (HMPAO) and a three- or four-head SPECT camera

Received September 20, 1994, revision accepted November 18, 1994.

For reprint contact: Tamotsu Nagata, M.D., Department of Radiology, Shiga University of Medical Science, Seta Tsukinowacho, Otsu 520-21, JAPAN.

**Table 1** Type of seizure and EEG findings

No.	Sex	Age	Seizure type	Inter-ictal EEG	Final EEG diagnosis (methods)
1	M	16	Complex partial seizure	Left temporal sharp wave	Left temporal (ictal EEG)
2	M	45	Complex partial seizure	Diffuse spike and slow wave	Left frontal (subdural EEG)
3	F	35	Complex partial seizure	Left temporal spike	Left temporal (ictal EEG)
4	F	30	Secondary generalized tonic-clonic	Right temporal sharp wave	Right temporal (ictal EEG)
5	F	29	Complex partial seizure	Left temporal 3 Hz rhythmic wave	Left temporal (ictal EEG)
6	M	23	Complex partial seizure	Right temporal spike and slow wave	Right temporal (ictal EEG)
7	M	13	Secondary generalized tonic-clonic	Right cerebral hemisphere	Right parietal (ictal EEG)
8	M	49	Complex partial seizure	Right temporal spike and slow wave	Right temporal (ictal EEG)
9	M	32	Complex partial seizure	Left temporal sharp wave	Left temporal (ictal EEG)
10	M	56	Complex partial seizure	Right temporal spike	Right temporal (ictal EEG)

provide excellent quality in regional cerebral blood flow images. We therefore investigated the clinical value of high resolution SPECT for the detection of epileptic foci in comparison with MRI and FDG PET.

## MATERIALS AND METHODS

### Subjects

A total of 10 patients underwent PET, SPECT, MRI, and EEG examinations. They were 7 males and 3 females (mean age 32.8 years; range 13–56 years). The clinical data for these 10 patients are summarized in Table 1. All of them were suffering from intractable complex partial seizures.

### MRI

MRI studies were performed with a 1.5 T superconductive whole body scanner (Signa system GE Medical Systems, Milwaukee, USA). The spin echo technique was applied for T2-weighted images with a repetition time (TR) of 2,300 msec and echo time (TE) of 80 msec. T1-weighted images were obtained at TR 500–600 msec and TE 20 msec. MR scanning was performed in coronal or axial planes.

### SPECT

Tc-99m HMPAO was prepared from a freeze-dried kit (Amersham Co., Tokyo, Japan) by adding 1,110 MBq (30 mCi) of freshly eluted Tc-99m pertechnetate in saline solution just prior to intravenous injection. Each patient received an intravenous injection of 740 MBq (20 mCi) of Tc-99m HMPAO at 5 minutes before the scanning. SPECT scan was performed by means of a three-head rotating SPECT camera (Picker PRISM 3000; Picker International, Bedford Heights, U.S.A.) with a low energy high resolution fan beam collimator or four-head SPECT camera (SPECT 2000H; Hitachi Medical Co., Tokyo, Japan) with low energy high resolution parallel collimators. The images were reconstructed with a Ramachandran filter after preprocessing with a Butterworth filter (0.4 cycles/pixel, order 4), providing a spatial resolution of 10 mm FWHM and a slice thickness of 7 mm for

PRISM 3000. SPECT 2000H provided a spatial resolution of 10 mm FWHM and a slice thickness of 8 mm. The images were reconstructed with a Ramachandran filter after preprocessing with a Butterworth filter (0.2 cycles/pixel, order 8). The attenuation correction was performed by the post-correction methods assuming uniform attenuation in the ellipsoid object. The SPECT images were visually assessed on the transaxial tomographic sections parallel to the orbitomeatal line, and on the coronal tomographic sections.

### PET

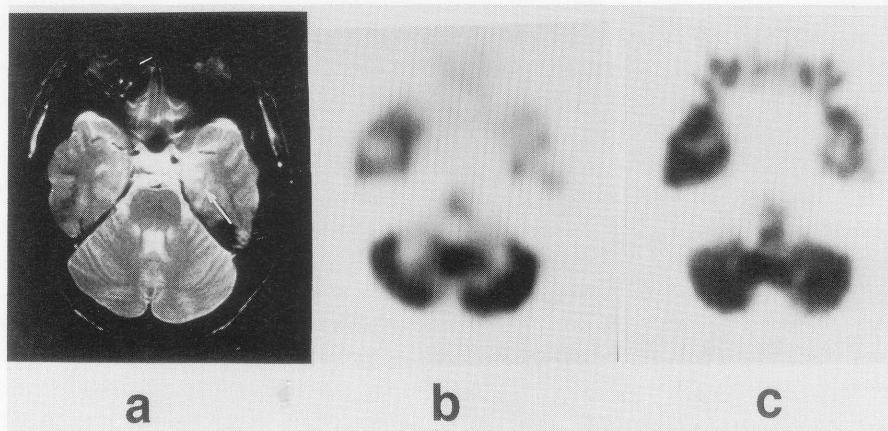
F-18 FDG was produced by a small cyclotron (CYPRIS 325, Sumitomo Heavy Industries, Ltd., Tokyo, Japan) and an automatic synthesizer installed at Kyoto University Hospital. PET scan was performed with the PCT-3600W (Hitachi Medical Co., Tokyo, Japan). This scanner simultaneously acquires 15 slices with an interslice distance of 7 mm. Scanning was performed at a resolution of 7 mm FWHM in the transaxial plane and 6.5 mm in the axial direction. Prior to all emission measurements, tomographic transmission data were obtained with a Ge-68/Ga-68 standard plate source for photon attenuation correction. Tissue activity concentration in the images was cross-calibrated against the well scintillation counter with a cylindrical phantom filled with F-18 solution. PET images were acquired for 20 min starting at 40 min after the intravenous injection of 111–185 MBq (3–5 mCi) of FDG.

## RESULTS

Table 2 summarizes the results of MRI, SPECT, and PET studies. MRI showed abnormal findings in 8 patients. These included 5 patients with hippocampal lesions, 2 patients with brain mass lesions, and 1 patient with an operative brain defect. No abnormal findings were observed on MRI in two cases. In addition, in two cases (cases 2 and 6), the abnormal findings were due to a structural defect (cyst or post surgical resection) and MRI did not provide valuable information regarding the epileptic foci.

**Table 2** Image findings of MRI, SPECT and PET

No.	MRI	SPECT	PET
1	Left hippocampal sclerosis	Left temporal hypoperfusion (both mesial and lateral)	Left temporal hypometabolism (both mesial and lateral)
2	Left frontal cyst (arachnoid cyst)	Left frontal defect (cyst)	Left frontal defect (cyst) Left frontal hypometabolism
3	Left hippocampal sclerosis	Left mesial temporal hypoperfusion	Left mesial temporal hypometabolism
4	Right hippocampal sclerosis	Right temporal hypoperfusion (both mesial and lateral)	Right fronto-temporal hypometabolism
5	Left hippocampal sclerosis	Left temporal hypoperfusion (both mesial and lateral)	Left temporal hypometabolism (both mesial and lateral)
6	Right temporal ependymoma post-opec (no sign of recurrence)	Right temporal defect (post-opec)	Right temporal defect (post-opec) Additional right anterior temporal hypometabolism
7	Right fronto-parietal cavernous angioma	Right fronto-parietal defect (angioma) Right parietal hypoperfusion Left temporal hypoperfusion	Right fronto-parietal defect (angioma) Right parietal hypoperfusion Left temporal hypometabolism
8	Normal	Normal	Right fronto-temporo-occipital hypometabolism
9	Left hippocampal sclerosis	Left mesial temporal hypoperfusion	Left mesial temporal hypometabolism
10	Normal	Normal	Normal



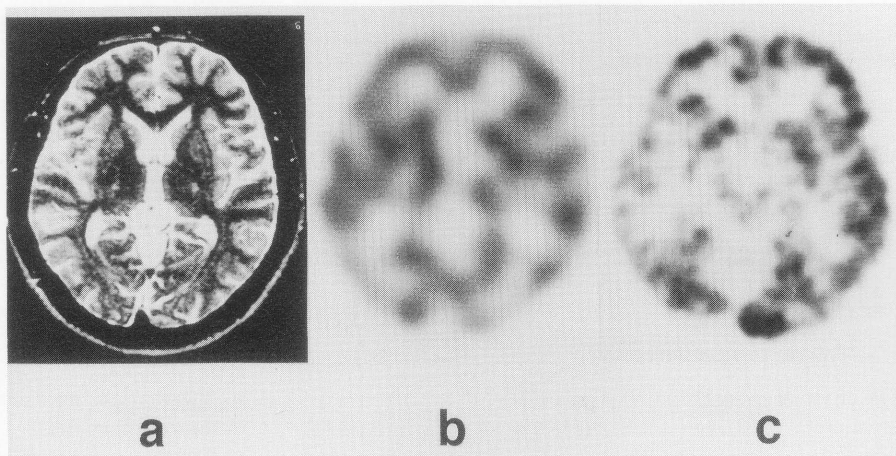
**Fig. 1** A 16-year-old man with complex partial seizure. (a) The high intensity lesion was located at left mesial temporal lobe (arrow) on T2 weighted MRI (TR 2300/TE 80). (b) Decreased accumulation of Tc-99m HMPAO was observed at left temporal lobe. (c) Decreased glucose metabolism was demonstrated at left temporal lobe, as similar to the hypoperfused area with SPECT.

Inter ictal SPECT studies demonstrated decreased uptake in 8 patients. However in 2 of these 8 cases, the abnormal hypoperfusion was due to a structural brain defect, and the epileptic foci could not be determined by SPECT images (cases 2 and 6). Two studies showed no abnormal findings (case 2). The abnormal focal hypoperfusion observed in the other 6 SPECT studies corresponded with the final diagnosis obtained by EEG.

All PET studies were also performed interictally. Focal hypometabolism was found by visual inspection in 9 of these cases (90%). The abnormalities were localized in a unilateral temporal lobe in 7 patients, unilateral frontal lobe in 1 patients, and unilateral frontoparietal lobe in 1 patient. In these 9 patients focal hypometabolism agreed with the epileptic foci determined by the final EEG

diagnosis. In 3 patients with structural brain defect due to cystic lesion (case 2), post surgical resection (case 6), or angioma (case 7), additional hypometabolic areas were observed in the surrounding regions, which were concordant with EEG findings. Two of these cases (cases 2 and 6) were not diagnosed properly by SPECT images.

Figure 1 shows the case of left temporal epilepsy in which both SPECT and PET demonstrated corresponding findings (case 1). SPECT revealed hypoperfusion in the left temporal lobe, probably due to the atrophy, and FDG PET showed similar findings. On the other hand, Figure 2 (case 8) showed normal MRI and normal cerebral perfusion on SPECT, while FDG PET revealed decreased glucose metabolism in the right fronto-temporo-occipital cortex.



**Fig. 2** A 49-year-old man with complex partial seizure. (a) No abnormal findings were found on T2 weighted MRI. (b) No abnormal findings were detected on SPECT images. (c) Decreased glucose metabolism was observed at right fronto-temporo-occipital cortex in FDG PET images.

## DISCUSSION

The purpose of our study was to examine the clinical feasibility of PET and SPECT for detecting epileptic foci compared with EEG, MRI, and FDG PET. The possibility of detecting epileptic foci has been greatly improved by the introduction of MRI. MRI is more sensitive than CT in demonstrating small lesions in the brain structure, with the minor exception of small calcifications. The pathological findings in epileptic foci were reported to be gliosis (mild-moderate-severe), tumor, focal neuronal loss, corpora amylacea, or deposits of hemosiderin. But the detectability of epileptic foci was 60% on MRI in our study, which was similar to other clinical data published in the past.<sup>5</sup>

The detectability of epileptic foci by Tc-99m HMPAO SPECT was also 60% in this study, considering the two cases with focal hypoperfusion due to a structural brain defect as false negative cases. It was reported to be 25 to 55% in past reports.<sup>17,18</sup> Our studies showed a little better detectability than these studies, probably because we used high resolution SPECT, and analyzed the coronal sections as well. On the other hand, the detectability of focal hypometabolism by F-18 FDG PET was excellent, and the lesions agreed well with EEG foci.

In this study PET was more sensitive than SPECT in the detection of epileptic foci. Our data were similar to those in past reports.<sup>17,18</sup> The lower detectability of SPECT might be partly due to the weaker physical performance of the equipment. Lower spatial resolution and undesired scattering of the SPECT images may obscure the subtle hypoperfusion in the epileptic foci, but our studies with high resolution SPECT did not greatly improve the detectability. The difference between SPECT and PET may therefore not be only due to the physical characteristics of the equipment but also due to the difference between cerebral blood flow and glucose metabolism. In 3 cases

with structural defects, which were found on MRI (case 2, 6, 7), PET showed additional hypometabolism in the surrounding area, while SPECT showed similar hypoperfusion in only one of these two cases. It was reported that local cerebral blood flow measured by N-13 NH<sub>3</sub> was different from the local cerebral metabolic rate for glucose measured by F-18 FDG.<sup>15</sup> It seems that, in epileptic foci or in the surrounding area, glucose metabolism was not always concordant with cerebral blood flow. Although cerebral blood flow and glucose metabolism were generally coupled in most circumstances, our data suggested that the uncoupling of flow and metabolism may exist in a patient with epilepsy, but the mechanism of this discrepancy is unclear and further studies are needed.

The possible cause of focal hypo-metabolism includes the structural abnormalities due to the permanent destruction of nervous tissue and secondary neuronal suppression. Structural damage involving synapses, the major source of glucose utilization in the brain, could be much more extensive than is appreciated on light microscopy. Electron microscopic preparations have demonstrated the absence of dendritic spines and decreases in dendritic domains.<sup>14</sup> From our study it is considered that focal hypometabolic lesions observed by FDG PET were the most responsible sites for seizures, but the area of hypo-metabolism is usually larger than the epileptogenic foci. Therefore, although FDG PET is the optimal method for detecting the epileptic foci, accurate localization of the epileptogenic foci for surgical resection seems to require invasive subdural or deep electrode EEG recording.

As surgical resection of the epileptic foci becomes popular as treatment for medically intractable seizures, the accurate detection of epileptic foci becomes an important issue. Various methods are used in detecting epileptic foci. Although interictal and ictal EEG are valuable methods, and we selected cases in which EEG

could demonstrate the epileptogenic area without any difficulty, they do not always provide confirmatory results. We confirmed that FDG PET is the most sensitive imaging method for detecting epileptic foci, and cerebral perfusion SPECT is of limited value. When interictal FDG PET does not show focal hypometabolism, ictal SPECT may play an important role before invasive methods, such as subdural EEG or depth electrode EEG recording, are applied.

## REFERENCES

1. Abou-Khalil BW, Sackellares JC, Latack JT, Vaderzant CW. Magnetic resonance imaging in refractory epilepsy. *Epilepsia* 25: 650, 1984.
2. Laster DW, Penry JK, Moody DM. Chronic seizure disorders: contribution of MR imaging when CT is normal. *Am J Neuroradiol* 6: 177-180, 1985.
3. Latack JT, Abou-Khalil BW, Siegel GJ, Sackellares JC, Gabrielson T, Aisen AM. Patients with partial seizures: evaluation by MR, CT and PET imaging. *Radiology* 159: 159-163, 1986.
4. Sussman NM, Scanlon M, Garfinkle W. Magnetic resonance imaging in temporal lobe epilepsy: comparison with EEG and computed tomography. *Epilepsia* 25: 650-651, 1984.
5. Sperling MR, Wilson G, Engel J Jr, Babb TL, Phelps M, Bradley W. Magnetic resonance imaging in intractable partial epilepsy: correlative studies. *Ann Neurol* 20: 57-62, 1986.
6. Ryding E, Rosen I, Elmqvist D, Ingvar DH. SPECT measurements with Tc-99m-HMPAO in focal epilepsy. *J Cereb Blood Flow Metab* 8: 95-100, 1988.
7. Duncan R, Patterson J, Hadley DM, Wyper DJ, McGeorge AP, Bone I. Tc-99m-HMPAO single photon emission computed tomography in temporal lobe epilepsy. *Acta Neurol Scand* 81: 287-293, 1990.
8. Grasso E, Ambrrogio L, Cognazzo A, Gerbino-Promis PC, Zagnoni P, Camuzzini GF, et al. Single photon emission computed tomography with Tc-99m-HMPAO in the study of focal epilepsy. *Ital J Neurol Sci* 10: 175-179, 1989.
9. Bonte FJ, Devous MD, Stokely EM, Homan RW. Single-photon tomographic determination of regional cerebral blood flow in epilepsy. *AJNR* 4: 544-546, 1983.
10. Neirinckx RD, Canning LR, Piper IM, Nowotnik DP, Pickett RD, Holmes RA, et al. Technetium-99m-d,l-HMPAO: A new radiopharmaceutical for SPECT imaging of regional cerebral blood perfusion. *J Nucl Med* 28: 191-202, 1987.
11. Theodore WH, Newmark ME, Sato S, Brooks R, Patronas N, Paz R De La, et al. F-18 Fluorodeoxyglucose positron emission tomography in refractory complex partial seizures. *Ann Neurol* 14: 429-437, 1983.
12. Henry TR, Mazziotta JC, Engel Jr J, Christenson PD, Zhang JX, Phelps ME, et al. Quantifying interictal metabolic activity in human temporal lobe epilepsy. *J Cereb Blood Flow Metab* 10: 748-757, 1990.
13. Abou-Khalil BW, Siegel GJ, Sackellares JC, Gilman S, Hichwa R, Marshall R. Positron emission tomography studies of cerebral glucose metabolism in chronic partial epilepsy. *Ann Neurol* 22: 480-486, 1987.
14. Engel J Jr, Brown WJ, Kuhl DE, Phelps ME, Mazziotta JC, Crandall PH. Pathological findings underlying focal temporal lobe hypometabolism in partial epilepsy. *Ann Neurol* 12: 518-528, 1982.
15. Kuhl DE, Engel J Jr, Phelps ME, Selin C. Epileptic patterns of local cerebral metabolism and perfusion in humans determined by emission computed tomography of F-18 FDG and N-13 NH<sub>3</sub>. *Ann Neurol* 8: 348-360, 1980.
16. Engel J Jr, Kuhl DE, Phelps ME, Crandall PH. Comparative localization of epileptic foci in partial epilepsy by PCT and EEG. *Ann Neurol* 12: 529-537, 1982.
17. Stefan H, Pawlik G, Bocher-Schwarz HG, Biersack HJ, Burr W, Penin H, et al. Functional and morphological abnormalities in temporal lobe epilepsy: a comparison of interictal and ictal EEG, CT, MRI, SPECT and PET. *J Neurol* 234: 377-384, 1987.
18. Ryvlin P, Philippon B, Cinotti L, Froment JC, Bars D Le, Mauguire F. Functional neuro imaging strategy in temporal lobe epilepsy: a comparative study of F-18 FDG-PET and Tc-99m HMPAO-SPECT. *Ann Neurol* 31: 650-656, 1992.