

Reflex sympathetic dystrophy syndrome secondary to organophosphate intoxication induced neuropathy

Murathan ŞAHİN,* İrem BERNAY,* Ferhan CANTÜRK**
and Arif Engin DEMİRÇALI*

*Departments of *Nuclear Medicine and **Physical Therapy and Rehabilitation, Faculty of Medicine,
Ondokuz Mayıs University, Samsun, Turkey*

Reflex sympathetic dystrophy or Sudeck's atrophy is a syndrome that can usually be followed by a traumatic insult. This disorder is accompanied by signs and symptoms of vasomotor instability, trophic skin changes, and rapid development of bony demineralization. This report presents a case with reflex sympathetic dystrophy syndrome secondary to organophosphate intoxication induced neuropathy. The patient was treated with calcitonin well.

Key words: reflex sympathetic dystrophy, neuropathy, organophosphate compounds

INTRODUCTION

REFLEX SYMPATHETIC DYSTROPHY SYNDROME (RSDS) is characterized by severe burning pain, vasomotor instability, swelling, limitation of motion, patchy demineralization on x-ray graphy and increased radionuclide activity on scintigraphy.^{1,2} Trauma, a number of diseases such as myocardial infarction, cervical osteoarthritis, central nervous system abnormalities and neuropathy, drugs such as cyclosporin A and other precipitating events have been associated with RSDS.²⁻⁴ They provoke RSDS with reflex neurological mechanisms, but their exact role in the pathogenesis has not been clarified yet. Autonomic nervous system dysfunction is generally accused in the generation of the clinical manifestations of this disorder.¹ RSDS, classically affects the distal part of the extremity involving the entire hand or foot, but is seldomly found in a segmental nature. We present a patient with RSDS secondary to organophosphate intoxication induced neuropathy, that has not been reported in the literature to our knowledge.

CASE REPORT

A 30-year-old man was admitted to the hospital because of organophosphate intoxication due to a derivative named dimethoate. He received 40 mg/kg pralidoxime two times

a day and totally 100 mg of atropin until the clinical symptoms were healed. Ten weeks after he was discharged from the hospital, he was admitted again, with complaints of pain, swelling, stiffness and color change in his hands. On physical examination, there were erythema, hyperesthesia and oedema in his hands. Spontaneous and provocative pain and limitation of active and passive range of motion in his wrists, metacarpophalangeal (MCP) and interphalangeal joints were present bilaterally.

X-ray graphy was normal (Fig. 1). Electromyography (EMG) revealed loss of motor unit action potentials in the upper extremity muscles bilaterally. Motor conduction velocities of nervus medianus and nervus ulnaris were also slowed down bilaterally. Using Tc-99m methylene diphosphonate, scintigraphy was performed with a gamma camera equipped with a low energy general purpose collimator. After the injection of 740 MBq of radionuclide, three phase bone scanning (TPBS) was performed and the scans were interpreted visually and quantitatively. There was a general increase in the periarticular activity of all joints in both hands (Fig. 2). The patient received a 4-week course of calcitonin (Micalcic-Sandoz) 100 Units daily and calcium 1 g daily. This resulted in complete resolution of the symptoms and the repeat bone scan was also improved quantitatively and qualitatively (Fig. 3).

DISCUSSION

Although it is not specific for RSDS, patchy demineralization which cannot be observed in all cases is the typical radiological finding for this disease. X-ray graphy was

Received March 7, 1994, revision accepted May 14, 1994.

For reprint contact: İrem Bernay, M.D., Department of Nuclear Medicine, Faculty of Medicine, Ondokuz Mayıs University, Samsun, TURKEY.

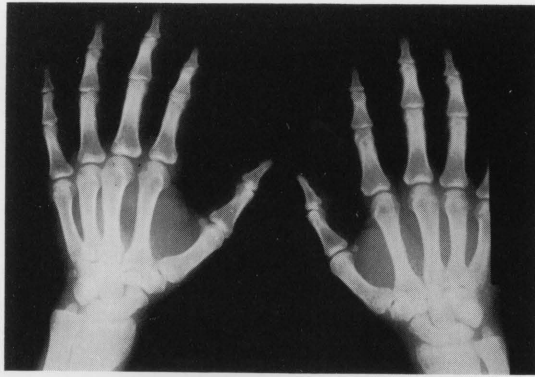

Fig. 1 X-ray graphy of the patient was normal.

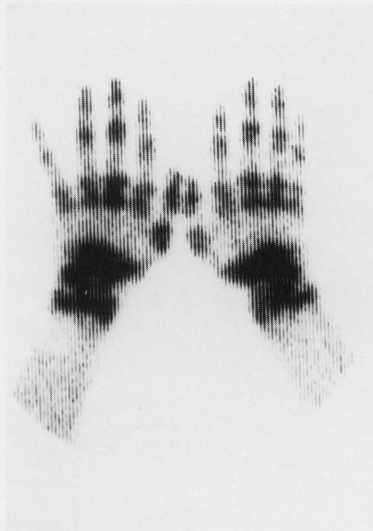

Fig. 2 Three-hour delayed image demonstrated increased osteoblastic activity in periarticular regions of the hands before therapy.

also found to be normal in this patient. Clinical diagnostic criteria for definite RSDS which were defined by Kozin et al.⁵ were present in this case. Although to some authors the sensitivity of the first two phases of TPBS is not as high as the third phase in the early period (0–20 weeks after the onset of symptoms),^{6,7} TPBS is a valuable examination in establishing the diagnosis of RSDS. In our patient the kinetic, blood-pool and the 3-hour delayed static images revealed increased radionuclide activity in all joints of the hands bilaterally and this activity decreased after the therapy.

EMG findings for this patient imply abnormality of function along the length of the largest fibers and loss of large motor neuron axons indicated neuropathy. Although acute effects of organophosphate intoxication appear to be directly related to cholinergic overactivity, the pathophysiology of the later neuropathy is less clear and is not related to cholinesterase inhibition.⁸

To the best of our knowledge this is the first docu-

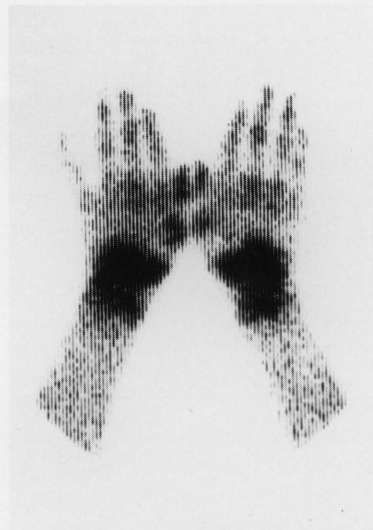


Fig. 3 Delayed image of the patient after 4-weeks of therapy.

mented case of RSDS secondary to organophosphate intoxication induced neuropathy and we want to take this opportunity to emphasize the value of bone scintigraphy in the diagnosis of RSDS and in the evaluation of response to therapy.

REFERENCES

1. Laukatis JP, Varma VM, Borenstein DG. Reflex sympathetic dystrophy localized to a single digit. *J Rheum* 16: 402–405, 1989.
2. Helms CA, O'Brien ET, Katzberg RW. Segmental reflex sympathetic dystrophy syndrome. *Radiology* 135: 67–68, 1980.
3. Kozin F: Painful shoulder and the reflex sympathetic dystrophy syndrome. In *Arthritis and Allied Conditions*, Mc Carty DJ (ed.), Philadelphia, Lee and Febiger Co., pp. 1510–1544, 1989.
4. Munoz-Gomez J, Collado A, Gratacos S, Campistol JM, Lomena F, Llana J, et al. Reflex sympathetic dystrophy syndrome of the lower limbs in renal transplant patients treated with Cyclosporin A. *Arthritis Rheum* 34: 625–630, 1991.
5. Kozin F, Ryan LM, Carrera GF, Soin JS, Wortman RL. The reflex sympathetic dystrophy syndrome (RSDS). III. Scintigraphic studies, further evidence for the therapeutic efficacy of systemic corticosteroids, and proposed diagnostic criteria. *Am J Med* 70: 23–30, 1981.
6. Demengeat JL, Constantinesco A, Brunot B, Foucher G, Farcot JM. Three-phase bone scanning in reflex sympathetic dystrophy of the hand. *J Nucl Med* 29: 26–32, 1988.
7. Holder LE, Mackinnon SE. Reflex sympathetic dystrophy in the hands: Clinical and scintigraphic criteria. *Radiology* 152: 517–522, 1984.
8. Dyck PJ, Low PA, Stevens JC. Diseases of peripheral nerves. In *Clinical Neurology*, Baker AB (ed.), Philadelphia, Harper and Row, pp. 1–126, 1986.