

Combined study with I-123 fatty acid and thallium-201 to assess ischemic myocardium: Comparison with thallium redistribution and glucose metabolism

Masahide KAWAMOTO,* Nagara TAMAKI,* Yoshiharu YONEKURA,* Eiji TADAMURA,* Yasuhisa FUJIBAYASHI,*
Yasuhiro MAGATA,* Ryuji NOHARA,** Shigetake SASAYAMA,** Katsuji IKEKUBO,***
Hiroshi KATO*** and Junji KONISHI*

*Department of Nuclear Medicine, **Third Division, Department of Internal Medicine,
Kyoto University Faculty of Medicine
***Kobe General Hospital

To assess the clinical value of combined SPECT imaging with I-123-15-(p-iodophenyl)-3-methyl pentadecanoic acid (BMIPP) and thallium-201 (Tl), the findings were compared with those obtained in a stress Tl study and positron emission tomography (PET) with fluorine-18-fluorodeoxyglucose (FDG) in 22 patients with myocardial infarction.

In 20 patients who underwent a stress Tl study, among 75 hypoperfused segments, 27 segments exhibited less BMIPP uptake than Tl (discordant segments), and the remaining 48 segments showed a similar decrease in BMIPP uptake (concordant segments). Twenty-two of 27 discordant segments (81%) exhibited redistribution on stress Tl study. On the other hand, only one of the 48 concordant segments had redistribution ($p < 0.001$).

In 10 patients who underwent a FDG PET study, among 33 hypoperfused segments, seven segments were discordant segments, and the remaining 25 segments were concordant segments. Seven of the eight discordant segments (88%) demonstrated an increase in FDG uptake. In contrast, only five of 25 concordant segments (20%) showed increase in FDG uptake ($p < 0.01$).

Thus, the segments showing discordant BMIPP uptake are considered to be ischemic but viable myocardium. We conclude that combined imaging with BMIPP and Tl is a useful mean for evaluating tissue viability in patients with coronary artery disease, but it may underestimate the extent of tissue viability, compared with FDG PET imaging.

Key words: single photon emission computed tomography, I-123 BMIPP, thallium-201, myocardial infarction, fluorine-18-fluorodeoxyglucose

INTRODUCTION

MYOCARDIAL METABOLIC IMAGING has the potential for early detection of the myocardial alteration and assessment of tissue viability in patients with ischemic heart disease. Since fatty acids are a major energy source for the normal myocardium,¹ a variety of iodinated fatty acid compounds have been introduced in order to probe the regional fatty acid metabolism *in vivo*.^{2,3} Among them,

iodine-123-labeled β -methyl iodophenyl pentadecanoic acid (BMIPP) is a promising agent for myocardial SPECT imaging, because it is metabolically trapped in the myocardium due to its methyl branching.⁴⁻⁷

We recently reported that BMIPP imaging showed a decrease in BMIPP uptake compared to Tl in some myocardial areas in patients with coronary artery disease. Such discordant BMIPP uptake was observed more often in areas of acute myocardial infarction and areas supplied by revascularized arteries.⁸

Stress Tl myocardial imaging is valuable for identifying reversible myocardial ischemia.⁹⁻¹² However, it may underestimate reversible myocardial areas when the delayed scan fails to show definite redistribution.¹³ Persistent glucose utilization has been observed in some of those

Received August 18, 1993, revision accepted November 5, 1993.

For reprint contact: Masahide Kawamoto, M.D., Department of Nuclear Medicine, Kyoto University Faculty of Medicine, Shogoin, Sakyo-ku, Kyoto 606, JAPAN.

areas in PET studies with FDG.^{14,15}

We hypothesize that a combined study with BMIPP and TI imaging may improve the detection of reversible ischemia. In order to evaluate the usefulness of this technique for assessing tissue viability, it was performed in patients with myocardial infarction and the findings were compared with those from a stress TI study and FDG-PET.

MATERIALS AND METHODS

Study population

A combined study with BMIPP and TI was performed in 22 patients with myocardial infarction. Myocardial infarction was diagnosed on the basis of a history of acute myocardial infarction with an increase in cardiac enzymes, typical precordial symptoms, and Q-waves on the electrocardiograms. The interval from the most recent onset of infarction ranged from 2 weeks to 1 year. The age ranged from 29 to 73 years, with a mean of 61.9 years. There were four female and 18 male patients. Of these, 20 patients were randomly selected for the stress TI study, and 10 were selected for the FDG PET study. The TI studies and PET studies were performed within 2 weeks of the BMIPP study. Informed written consent approved by the Kyoto University Clinical Study Committee was obtained prior to enrollment in the study.

Radiopharmaceuticals

BMIPP was prepared and supplied by Nihon Medi-Physics Co., Ltd. The BMIPP contained 111 MBq (3 mCi) of I-123-labeled 15-(para-iodophenyl)-3(R,S)-methyl pentadecanoic acid (0.6 mg) dissolved in 10.5 mg of urso-deoxycholic acid as a solvent.⁸

BMIPP and TI imaging

Single photon emission computed tomography (SPECT) was performed with a rotating gamma camera equipped with a low-energy, general-purpose collimator (Starcam 2000; General Electric; Milwaukee, Wisconsin), collecting 32 views over 180 degrees from the right anterior oblique position to left posterior oblique position, taking 30 seconds per view.

BMIPP SPECT was performed after an overnight fast. SPECT imaging started 30 minutes after the injection of 111 MBq (3 mCi) of BMIPP.

TI SPECT imaging at rest was started 10 to 15 minutes after an injection of 111 MBq (3 mCi) of TI-201 chloride.

Stress and delayed TI SPECT images were obtained for 20 patients. The procedure for stress TI SPECT imaging has been fully described elsewhere.¹⁶ Briefly, patients underwent graded bicycle exercise starting at a 25-watt workload with 25-watt increments every 3 min. Approximately 111 MBq (3 mCi) of TI-201 chloride was injected at peak exercise, and the exercise was continued for another minute. SPECT imaging began within 10 min.

after the tracer injection. The patients were asked to remain sedentary and refrain from eating any carbohydrate meals for the 3-hr. interval between their initial and delayed thallium scans.

A series of transaxial slices was reconstructed by filtered back projection without attenuation correction. Oblique tomograms parallel to the long- and short-axis of the left ventricle were also reconstructed.¹⁶

FDG PET

The PET study was performed in 10 patients with a whole-body, multislice positron camera (Positologica III; Hitachi Medico Co.; Tokyo, Japan) with 4 rings providing 7 tomographic slices at 16-mm intervals.¹⁷ Each patient was studied in the fasting condition for at least 5 hr. to maintain a steady-state during the PET study.¹⁵ The patients were positioned on the PET camera by the ultrasound technique. Transmission scanning was performed for 20 minutes for accurate correction of the photon attenuation. Sixty minutes after an injection of 185 MBq of F-18 FDG, a 15 minutes static image was obtained.¹⁵

From a series of transverse slices, oblique tomograms parallel to the long- and short-axis of the left ventricle were also reconstructed for comparison with the SPECT images.¹⁸

Image analysis

The left ventricular myocardium was divided into seven segments (anterobasal, anterior, apical, inferior, posterobasal, septal and lateral).⁸ BMIPP and TI uptakes were scored by two experienced nuclear physicians with a 4-point grading system for each segment (3 = normal, 2 = mild reductions, 1 = moderate reductions, 0 = severe reductions).⁸

In the stress TI study, when the score increased by one or more on the delayed scan, the segment was considered to have redistribution. When the score was unchanged on the delayed scan, the segment was considered to be a persistent defect.

In the combined study with BMIPP and TI, the BMIPP score was compared with the TI score at rest in the corresponding segment. When the BMIPP score was equal to the TI score, the segment was considered to be a concordant segment. When the BMIPP score was smaller than the TI score, the segment was considered to be a discordant segment. In this study, none of the segments showed a BMIPP score which was greater than the TI score.

The FDG PET images were compared with the TI perfusion images at rest in corresponding segments. Hypoperfused segments defined by the TI study were divided into two groups based on the FDG uptake. The FDG uptake was quantitatively measured as the percent of the injected dose per 100 ml of tissue (%ID/100 ml) in each segment.¹⁹ The hypoperfused segments with FDG uptake which increased above the normal range were

Table 1 Relationship of BMIPP and Tl uptake scores in the total of myocardial segments

Tl score	BMIPP score				Total
	3	2	1	0	
3	76	3	0	0	79
2	0	16	13	3	32
1	0	0	16	9	25
0	0	0	0	18	18
Total	76	19	29	30	154

3 = normal; 2 = mildly reduced; 1 = moderately reduced; 0 = severe reduced

Table 2 Number of segments on BMIPP/Tl imaging in relation to stress Tl study

BMIPP/Tl finding	n	Stress Tl findings	
		Redistribution (+)	Redistribution (-)
Discordant	27	22	5
Concordant	48	1	47
Total	75	23	52

Table 3 Number of segments on BMIPP/Tl combined imaging in relation to PET findings

BMIPP/Tl findings	n	PET findings	
		PET ischemia	PET scar
Discordant (BMIPP < Tl)	8	7	1
Concordant (BMIPP = Tl)	25	5	20
Total	33	12	21

defined as PET ischemia, while those with no increase in FDG uptake were defined as PET scar.²⁰⁻²² The normal range of FDG uptake was determined in each segment as the mean \pm 2 s.d. of the FDG uptake in eight normal subjects. The upper limit was approximately 0.7%ID/100 ml in the septal, anterior and apical regions and 0.85%ID/100 ml in the lateral and inferior regions.¹⁹

Statistical analysis

Comparisons of proportions were performed by chi-square analysis. Probability values of < 0.05 were considered significant.

RESULTS

BMIPP and Tl findings at rest (Table 1)

Of the total 154 segments, 78 segments showed perfusion abnormalities on the Tl scan at rest. Of those, 50 segments (64%) showed the same scores in the BMIPP and Tl uptakes, indicating concordant distribution. whereas 28 segments (36%) showed a lower BMIPP score than the Tl score, indicating discordant uptake. None of the segments showed a higher BMIPP score than the Tl score.

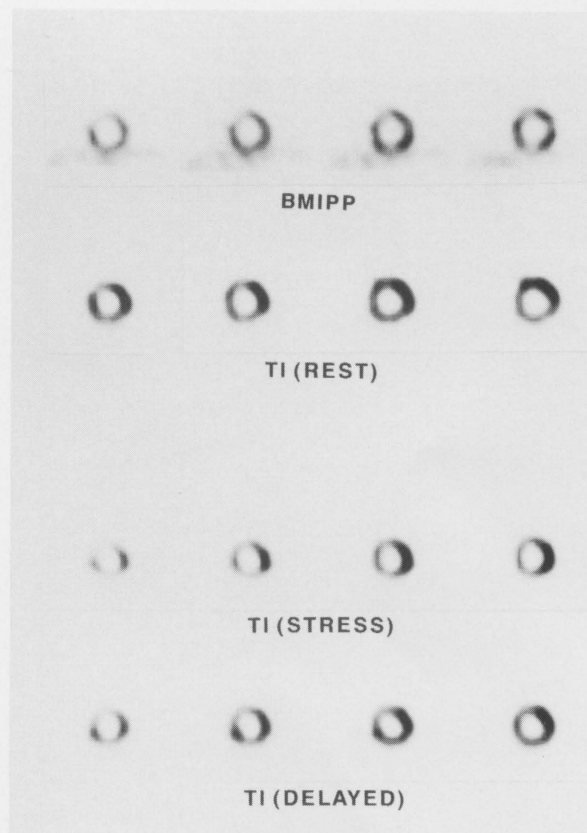


Fig. 1 75-year-old man with antero-septal and inferior MI after 21 weeks from onset. Coronary arteriogram revealed 99% stenosis of LAD #7 and LCX #12 and 90% stenosis of RCA #2. Left ventriculogram showed dyskinesia of Seg. 3 and hypokinesia of Seg. 4. A series of short-axis slices of BMIPP and Tl images at rest (Top), and stress and delayed Tl images (Bottom). Decreased uptake of both BMIPP and Tl are observed in antero-septal and inferior wall. But BMIPP uptake is less than Tl uptake in inferior region. Redistribution is observed in inferior and lower septal region.

Comparison with stress Tl study (Table 2)

In the stress Tl study of 20 patients, 75 segments showed perfusion abnormalities on the initial scan. Twenty-seven segments showed discordant BMIPP uptake, and the remaining 48 segments showed concordant BMIPP uptake. Redistribution on the delayed scan was observed in 22 of the 27 discordant segments (81%) (Fig. 1), but in only one of the 48 concordant segments ($p < 0.001$). On the other hand, no redistribution was observed in 47 of the 48 concordant segments and also in five of the 27 discordant segments (Fig. 2).

Comparison with FDG PET (Table 3)

The FDG PET findings were normal in 37 segments but indicated PET ischemia in 12 segments and PET scar in 21 segments. Seven of eight segments (88%) which showed discordant BMIPP uptake were PET ischemia (Figs. 2 and 3), and the remaining one segment was PET scar. On the other hand, 20 of 25 (80%) segments with

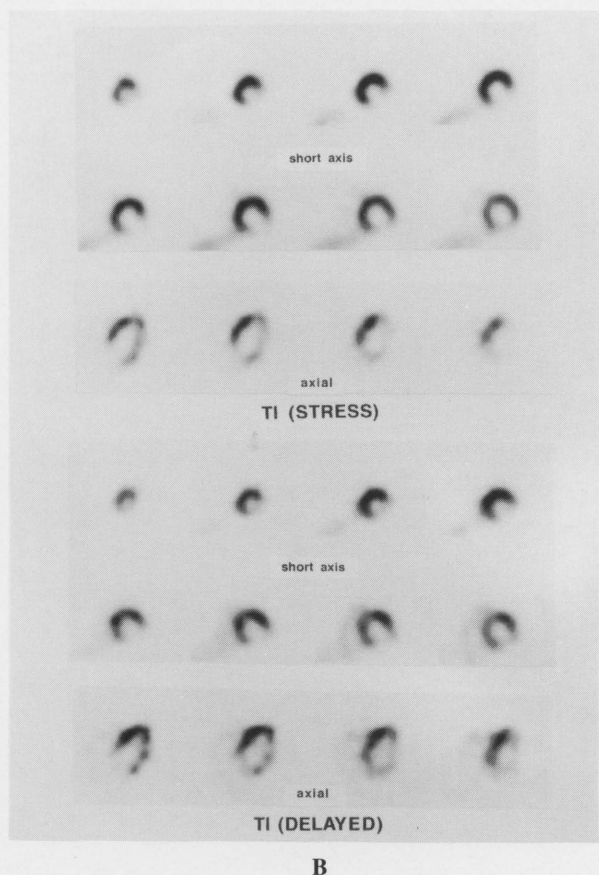
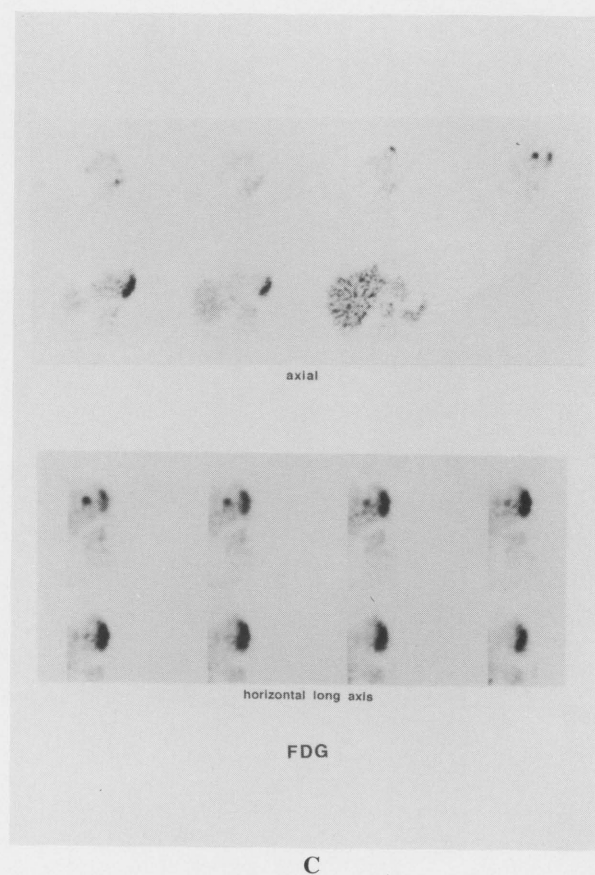
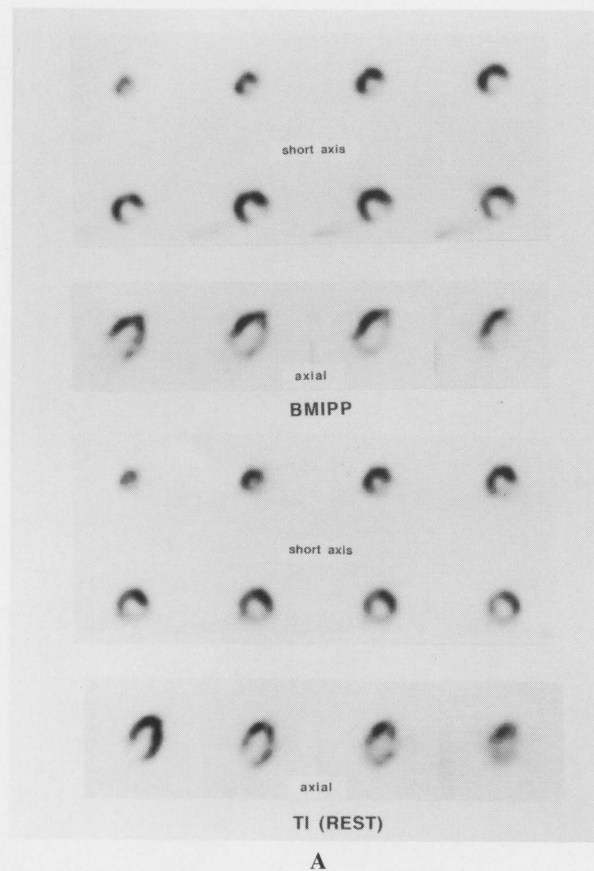


Fig. 2 A) 62-year-old man with lateral MI after 4 weeks from onset. Coronary arteriogram revealed 90% stenosis of LCX #11. Wall motion was almost normal in left ventriculogram. A series of short-axis and axial slices of BMIPP images (Top) and Tl images (Bottom). BMIPP uptake is less than Tl uptake in the lateral region. B) A series of short-axis and axial slices of stress Tl images (Top) and delayed Tl images (Bottom) from the same patient. No redistribution is observed in lateral wall. C) A series of axial (Top) and horizontal long-axis (Bottom) slices of FDG PET images from the same patient. FDG uptake is observed in the lateral wall.

concordant BMIPP/Tl uptake were PET scar (Fig. 4). However, the remaining five segments (20%) showing concordant uptake had persistent metabolic activity on FDG PET.

DISCUSSION

The present study demonstrates that less BMIPP uptake than thallium uptake (discordant uptake) was occasionally observed in patients with myocardial infarction, and such segments are likely to show redistribution in a stress Tl study and increased FDG uptake on PET study. These data indicate that segments exhibiting discordant BMIPP uptake may represent ischemic but viable myocardium. Regarding the detection of ischemic myocardium in

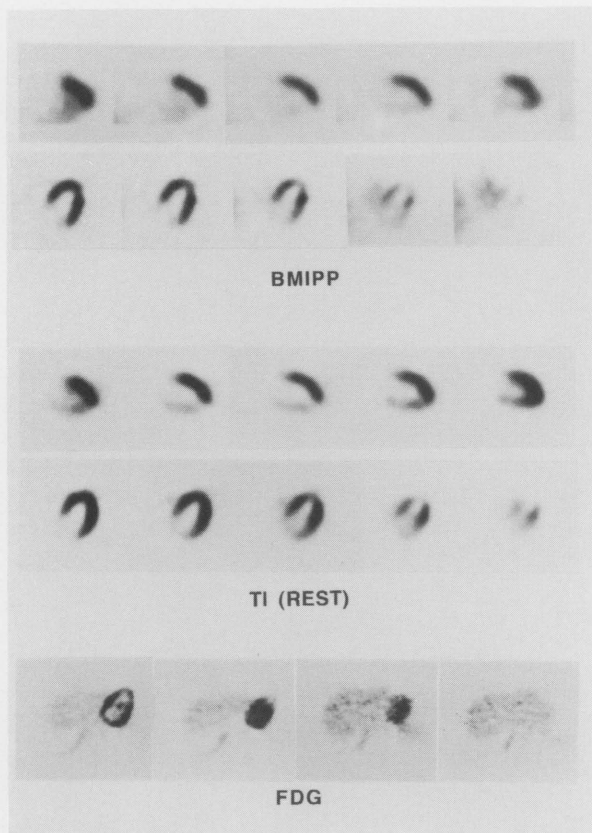


Fig. 3 61-year-old woman with inferior MI after 20 months from onset. Coronary arteriogram revealed 100% stenosis of RCA #2 with collateral circulation from LAD and LCX. Left ventriculogram showed hypokinesis of Seg. 4 and Seg. 5. A series of vertical long-axis slices of BMIPP images (Top) and TI images (Middle), and a series of axial slices of FDG PET images (Bottom). BMIPP uptake is less than TI uptake in the inferior region, where FDG uptake was observed on PET images.

infarcted areas, FDG PET seems to be the most sensitive among these three techniques, followed by combined imaging with BMIPP and TI, and stress-redistribution TI scan.

Possible uptake mechanism of BMIPP

Following the administration of BMIPP, it is trapped in the myocardium according to regional myocardial blood flow, and it is incorporated into the endogenous lipid pool. The methyl-branched fatty acid tracer, BMIPP, is thought to be protected from metabolism by β -oxidation.⁴⁻⁷ Therefore, it may reflect fatty acid uptake and the size of the endogenous lipid pool rather than β -oxidation of fatty acids. Our previous experiments suggested a close correlation between BMIPP uptake and triglyceride synthesis and the ATP concentration.^{23,24}

In addition, a number of experimental studies reported discordant distribution between methyl-branched fatty acids and TI-201 in hypertensive rats,^{25,26} in occlusion-reperfusion models,²⁷ and in cardiomyopathy hamster

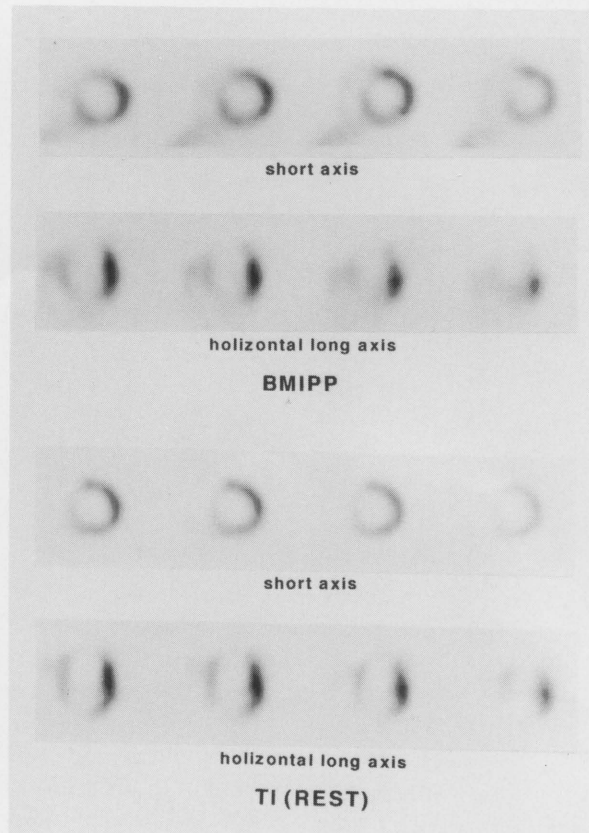


Fig. 4 60-year-old man with antero-septal MI after 13 months from onset. Coronary arteriogram revealed 90% stenosis of LAD #6. Left ventriculogram showed dyskinesia of Seg. 2 and Seg. 3 and akinesis of Seg. 6. A series of short-axis and horizontal long-axis slices of BMIPP images (Top) and TI images (Bottom). Both images show concordant distribution. This case showed no significant FDG uptake in the PET study.

models.²⁸ These data indicate that the distribution of BMIPP may provide some comprehensive information regarding myocardial metabolic function, although it is largely dependent on the regional blood flow. To enhance the metabolic information, the BMIPP uptake should be compared with the thallium distribution. Saito et al. showed greater methylated fatty acid uptake than TI-201 uptake in several patients with unstable angina,²⁹ possibly due to an increase in the triglyceride pool in the ischemic tissue. But in the current study, none of the patients showed greater BMIPP uptake than TI-201 uptake. In the chronic phase of myocardial infarction, however, the prolonged ischemia and reperfusion may decrease the net extraction fraction and increase the back-diffusion of BMIPP. Our first clinical results also supported this concept.⁸

Comparison with TI redistribution

Stress TI studies were valuable for assessing tissue viability in patients with coronary artery disease. However, the myocardial segments without redistribution often contain

ischemic tissue whose regional function improves after revascularization.^{12,13}

To improve the detection of ischemic but viable myocardium, various techniques have been developed, such as reinjection imaging^{30,31} and 24-hr. delayed imaging.^{32,33} In this study, we proposed combined imaging with BMIPP and TI study as one such technique. It identified approximately 10% of the segments without redistribution as ischemic myocardium. However, whether the segments showing discordant BMIPP uptake are capable of improved regional function after revascularization remains to be clarified.

Comparison with metabolic activity

The myocardial segments with an increase in FDG uptake are likely to show improved regional function after coronary bypass surgery.^{21,22} Sochor et al., in an experimental study,³⁴ showed that preservation of metabolic activity correlated with the histologic presence of residual viable myocardium. Thus, segments with FDG uptake are considered to be mainly myocardium with reversible ischemia.

In our present study comparing BMIPP imaging with the FDG PET findings, most of the segments with discordant BMIPP uptake had preserved metabolic activity on the FDG PET. Therefore, segments with discordant BMIPP uptake may be considered to be reversible ischemic myocardium. In such segments, ischemia may cause suppression of the utilization of fatty acids and conversion of energy sources from fatty acids to glucose. In concordant segments, on the other hand, the utilization of both fatty acids and glucose may be suppressed. However, some segments without discordant BMIPP uptake still showed persistent metabolic activity on FDG PET. A number of potential reasons are considered for the higher detectability of ischemic myocardium by FDG PET. The higher resolution and higher count density of FDG PET can identify metabolic alternation in ischemia. In addition, while SPECT images were evaluated visually, the PET images were quantitatively evaluated. Furthermore, FDG PET can identify ischemia as an increased uptake, whereas BMIPP may show the lesion as a decreased uptake. Thus, combined imaging with BMIPP and TI seems to be useful for assessing tissue viability, but it still may underestimate the extent of the viable myocardium compared with FDG PET.

Limitations

The present study involves a comparison of combined imaging with BMIPP and TI with stress-delayed TI imaging, but not stress-reinjection imaging nor rest-stress TI imaging. Since a reinjection imaging or a rest-stress TI imaging might identify additional ischemic myocardium, a better correlation may be expected between findings in a BMIPP-TI combined study and those studies.

In this study, we considered that myocardial segments exhibiting discordant BMIPP uptake are ischemic but

viable myocardium, because these segments are likely to show redistribution in a stress TI study or FDG uptake in a PET study. But this conclusion remains speculation, because the viability of ischemic myocardium should be proved by the improvement in wall motion after revascularization.

Myocardial utilization of glucose is known to be altered by changes in the plasma substrate levels. In the postprandial condition, an increase in insulin results in increased FDG uptake in the normal myocardium with a relative decrease in FDG uptake in the ischemic myocardium. As a result, an FDG study on the postprandial state may underestimate the extent of tissue viability.³⁵ In contrast, in the fasting condition, the normal myocardium prefers to utilize fatty acids. As a result, FDG uptake in the normal myocardium is suppressed, whereas even a small area of ischemic tissue may show intense uptake of FDG. Thus, an FDG study in the fasting state may overestimate tissue viability, although it is sensitive for detecting of ischemic myocardium.³⁶ In addition, Gropler et al. suggested that the uptake of FDG by the normal myocardium is heterogeneous in the fasting state.³⁷ In the current study, FDG studies were performed under fasting conditions. To minimize overestimation of ischemic myocardium, the FDG uptake was quantitatively assessed to compare its uptake with the normal range of FDG uptake in each segment.

Clinical implications

The combined imaging with BMIPP and TI often showed less BMIPP uptake than TI uptake, particularly in the segments with redistribution on the stress TI study and the segments with increased FDG uptake, indicating such segments to be ischemic but viable myocardium. However, there were some segments without discordant BMIPP uptake associated with an increase in FDG uptake. Although this technique may still underestimate the extent of viable myocardium, it is useful for identifying ischemic myocardium. In addition, this technique can be applied to patients who cannot perform adequate exercise for a stress TI study, for example on the acute phase of myocardial infarction.

ACKNOWLEDGMENTS

We thank Isthiaque H. Mohiuddin, M.D., Kazumi Okuda, M.D. and Shinji Ono, M.D. for their assistance with the PET studies. We also thank Toru Fujita, R.T., and the Cyclotron staff for their fine technical assistance.

REFERENCES

1. Neely JR, Rovetto MJ, Oram JF. Myocardial utilization of carbohydrate and lipids. *Prog Cardiovasc Dis* 15: 685-698, 1972.
2. Van der Wall EE, Heidendal GAK, den Hollander W, Westera G, Roos JP. I-123-labelled hexadecanoic acid in

- comparison with thallium-201 for myocardial imaging in coronary artery disease. *Eur J Nucl Med* 6: 391–396, 1983.
3. Otto CA, Brown LE, Wieland DM, Beerwaltes WH. Radioiodinated fatty acids for myocardial imaging: effects of chain length. *J Nucl Med* 22: 613–618, 1981.
4. Ambrose KR, Owen BA, Goodman MM, Knapp FF Jr. Evaluation of the metabolism in rat heart of two new radioiodinated 3-methyl-branched fatty acid myocardial imaging agents. *Eur J Nucl Med* 12: 486–491, 1987.
5. Ambrose KR, Owen BA, Callhan J, et al. Effects of fasting on the myocardial subcellular distribution and lipid distribution of terminal p-iodophenyl-substituted fatty acids in rats. *Nucl Med Biol* 15: 695–700, 1988.
6. DeGrado TR, Holden JE, Chin KN, et al. β -methyl-15-p-iodophenyl pentadecanoic acid metabolism and kinetics in the isolated rat heart. *Eur J Nucl Med* 15: 78–80, 1989.
7. Fink GD, Montgomery JA, David F, et al. Metabolism of β -methylheptadecanoic acid in the perfused rat heart and liver. *J Nucl Med* 31: 1823–1830, 1990.
8. Tamaki N, Kawamoto M, Yonekura Y, et al. Regional Metabolic abnormality in relation to perfusion and wall motion in patients with myocardial infarction: assessment with emission tomography using an iodinated branched fatty acid analog. *J Nucl Med* 33: 659–667, 1992.
9. Rigo P, Bailey IK, Griffith LSC, et al. Value and limitation of segmental analysis of stress thallium myocardial imaging for localization of coronary artery disease. *Circulation* 61: 973–981, 1980.
10. Maddahi J, Garcia EV, Hamilton GW, et al. Improved noninvasive assessment of coronary artery disease by quantitative analysis of regional stress myocardial distribution and washout of thallium-201. *Circulation* 64: 924–935, 1981.
11. Rozanski A, Berman DS, Gray R, et al. Use of thallium-201 redistribution scintigraphy in the preoperative differentiation of reversible and nonreversible myocardial asynergy. *Circulation* 64: 936–944, 1986.
12. Berger BC, Watson DD, Burwell LR, et al. Redistribution of thallium at rest in patients with stable and unstable angina and the effect of coronary artery bypass surgery. *Circulation* 60: 1114–1125, 1979.
13. Liu P, Kiess MC, Okada RD, et al. The persistent defect on exercise thallium imaging and its fate after myocardial revascularization: does it represent scar or ischemia? *Am Heart J* 110: 996–1001, 1985.
14. Brunken R, Schwaiger M, Grover-McKay M, Phelps ME, Tillisch J, Schelbert HR. Positron emission tomography detects tissue metabolic activity in myocardial segments with persistent thallium perfusion defects. *J Am Coll Cardiol* 10: 557–567, 1987.
15. Tamaki N, Yonekura Y, Yamashita K, et al. SPECT thallium-201 tomography and positron tomography using N-13-ammonia and F-18-fluorodeoxyglucose in coronary heart disease. *Am J Cardiac Imaging* 3: 3–9, 1989.
16. Tamaki N, Yonekura Y, Mukai T, et al. Segmental analysis of stress thallium myocardial emission tomography for localization of coronary artery disease. *Eur J Nucl Med* 9: 99–105, 1984.
17. Senda M, Tamaki N, Yonekura Y, et al. Performance characteristics of Positologica III, a whole-body positron emission tomography. *J Comput Assist Tomogr* 9: 940–946, 1985.
18. Senda M, Yonekura Y, Tamaki N, et al. Interpolating scan and oblique-angle tomograms in myocardial PET using nitrogen-13-ammonia. *J Nucl Med* 27: 1180–1186, 1986.
19. Tamaki N, Yonekura Y, Kawamoto M, et al. Simple quantification of regional myocardial uptake of fluorine-18-deoxyglucose in the fasting condition. *J Nucl Med* 32: 2152–2157, 1991.
20. Marshall RC, Tillisch JH, Phelps ME, et al. Identification and differentiation of resting myocardial ischemia and infarction in man with positron computed tomography, F-18-labeled fluorodeoxyglucose and N-13-ammonia. *Circulation* 67: 766–778, 1983.
21. Tillisch J, Brunken R, Marshall R, et al. Reversibility of cardiac wall motion abnormalities predicted by positron tomography. *N Engl J Med* 314: 884–888, 1986.
22. Tamaki N, Yonekura Y, Yamashita K, et al. Positron emission tomography using fluorine-18-deoxyglucose in evaluation of coronary artery bypass grafting. *Am J Cardiol* 64: 860–865, 1989.
23. Fujibayashi Y, Yonekura Y, Kawai C, et al. Basic studies on I-123-beta-methyl-p-iodophenyl pentadecanoic acid (BMIPP) for myocardial functional diagnosis: effect of beta-oxidation inhibition. *Jpn J Nucl Med* 25: 1131–1135, 1988.
24. Fujibayashi Y, Yonekura Y, Takemura Y, et al. Myocardial accumulation of iodinated beta-methyl-branched fatty acid analogue, iodine-125-15-(p-iodophenyl)-3-(R,S)methyl pentadecanoic acid (BMIPP), in relation to ATP content. *J Nucl Med* 31: 1818–1822, 1990.
25. Yonekura Y, Brill AB, Som P, et al. Regional myocardial substrate uptake in hypertensive rats: a quantitative autoradiographic measurement. *Science* 227: 1494–1496, 1985.
26. Yamamoto K, Som P, Brill AB, et al. Dual-tracer autoradiographic study of beta-methyl-(1-C-14)heptadecanoic acid and 15-p-(I-131)-iodophenyl-beta-methyl pentadecanoic acid in normotensive and hypertensive rats. *J Nucl Med* 27: 1178–1183, 1986.
27. Nishimura T, Sago M, Kihara K. Fatty acid myocardial imaging using ^{123}I -beta-methyl-iodophenyl pentadecanoic acid (BMIPP): comparison of myocardial perfusion and fatty acid utilization in canine myocardial infarction (occlusion and reperfusion model). *Eur J Nucl Med* 15: 341–345, 1989.
28. Kurata C, Kobayashi A, Yamazaki N. Dual-tracer autoradiographic study with thallium-201 and radioiodinated fatty acid in cardiomyopathic hamsters. *J Nucl Med* 30: 80–87, 1989.
29. Saito T, Yasuda T, Gold HK, et al. Differentiation of regional perfusion and fatty acid uptake in zones of myocardial injury. *Nucl Med Commun* 12: 663–675, 1991.
30. Ohtani H, Tamaki N, Yonekura Y, et al. Value of thallium-201 reinjection after delayed SPECT imaging for predicting reversible ischemia after coronary artery bypass grafting. *Am J Cardiol* 66: 394–399, 1990.
31. Tamaki N, Ohtani H, Yonekura Y, et al. Significance of fill-in after thallium-201 reinjection following delayed imaging: comparison with regional wall motion and angiographic findings. *J Nucl Med* 31: 1617–1622, 1990.
32. Gutman J, Berman DS, Freeman M, et al. Time to complete redistribution of thallium-201 in exercise myocardial

- scintigraphy: relationship to the degree of coronary artery disease. *Am Heart J* 106: 989–995, 1983.
33. Kiat H, Berman DS, Maddahi J, et al. Late reversibility of tomographic myocardial thallium-201 defects: an accurate marker of myocardial viability. *J Am Coll Cardiol* 12: 1456–1463, 1988.
 34. Sochor H, Schwaiger M, Schelbert HR, et al. Relationship between Tl-201, Tc-99m(Sn)pyrophosphate and F-18-2-deoxyglucose uptake in ischemically injured dog myocardium. *Am Heart J* 114: 1066–1077, 1987.
 35. Brunken R, Tillisch J, Schwaiger M, et al. Regional perfusion, glucose metabolism, and wall motion in patients with chronic electrocardiographic Q-wave infarctions: evidence for persistence of viable tissue in some infarct regions by positron emission tomography. *Circulation* 73: 951–963, 1986.
 36. Tamaki N, Yonekura Y, Konishi J. Myocardial FDG PET studies with the fasting, oral glucose loading or insulin clamp methods. *J Nucl Med* 33: 1263–1268, 1992.
 37. Gropler RJ, Siegel BA, Lee KJ, et al. Nonuniformity in myocardial accumulation of fluorine-18-fluorodeoxyglucose in normal fasted humans. *J Nucl Med* 31: 1749–1756, 1990.