

Value of thallium-201 early reinjection for assessment of myocardial viability

Hiroshi YOSHIDA,* Kazuyuki SAKATA,* Mamoru MOCHIZUKI,** Tsukasa KOUYAMA,** Yasunori MATSUMOTO,** Mitsuru TAKEZAWA,** Masami YOSHIMURA,** Norihisa ONO,* Noriko MORI,* Shoichi YOKOYAMA,* Tsuneo HOSHINO* and Tsuneo KABURAGI*

**Department of Cardiology, **Department of Nuclear Medicine, Shizuoka General Hospital*

To assess the efficacy of early reinjection for predicting post intervention improvement in thallium-201 (Tl) uptake and regional wall motion, we reinjected a small dose of Tl following post-stress imaging and obtained reinjection early images (10 min after early reinjection) and reinjection delayed images (3 hr afterwards) in 40 patients who were referred to us for revascularization (group I). Twenty-nine patients in group I also underwent conventional stress-redistribution Tl scintigraphy (group II). Conventional stress-redistribution Tl scintigraphy was repeated after intervention. Contrast left ventriculography was performed before and after intervention and changes in regional wall motion were assessed in 22 of 40 patients. In group I, the predictive value for improvement and no improvement (the accuracy) of reinjection early images in perfusion was 83%, while that of reinjection delayed images was 91%. Furthermore, the accuracy of reinjection early images in regional wall motion was 80%, while it was 91% for reinjection delayed images. In group II, the accuracy in perfusion was 78% and the value in regional wall motion was 70%. Both accuracy in perfusion and in regional wall motion obtained from reinjection delayed images were significantly higher than the values in group II ($p < 0.05$). These data suggest that early reinjection is useful for predicting postintervention thallium uptake and regional wall motion.

Key words: thallium-201, early reinjection, myocardial viability

INTRODUCTION

THALLIUM-201 myocardial imaging has been widely used to detect coronary artery disease and to assess myocardial viability. The unique property of this tracer to redistribute in the myocardium has been applied to distinguish reversible myocardial ischemia from scar. At present, thallium-201 single photon emission computed tomography (SPECT) is performed according to the stress-redistribution approach introduced by Pohost and his associates in 1977¹ where, following a single injection of thallium-201 at peak exercise, the initial image is obtained immediately after exercise and the delayed image is obtained 3–4 hours later. The post-exercise perfusion abnormalities, that improve with thallium-201 uptake (redistribution), represent ischemia, while the initial perfusion abnormalities

that are present on the delayed images are considered as myocardial scar. With the stress-redistribution approach two different phenomena are actually being studied: one is myocardial perfusion and the other is the myocardial potassium pool, as an indicator of myocardial viability.² However, several studies have demonstrated that areas of the myocardium showing nonreversible perfusion defects frequently exhibit normal perfusion after coronary revascularization,^{3,4} and these “nonreversible” defects occasionally display metabolic activity in positron emission computed tomography with 18-fluorodeoxyglucose.^{5,6} Recently, the reinjection of a small dose of thallium-201 about 10 minutes after delayed imaging was used to distinguish myocardial scar from viable but jeopardized myocardium.^{7,8} However, repeat imaging 10 minutes after reinjection might be too early to detect viable but severely hypoperfused myocardium. Furthermore, an additional venipuncture is required. In addition, redistribution partially depends on the blood level of thallium-201, so tracer uptake by a severely hypoperfused lesion might be facilitated by earlier reinjection to

Received July 21, 1993, revision accepted October 13, 1993.

For reprint contact: Hiroshi Yoshida, M.D., Department of Cardiology, Shizuoka General Hospital, Kita-andou 4-27-1, Shizuoka 420, JAPAN.

increase the thallium-201 concentration. Accordingly, we reinjected a small dose of thallium-201 after the initial (post-exercise) image was obtained, in order to promote early fill-in and potential tracer redistribution in hypoperfused myocardium, and assessed the value of this method for predicting improvement in thallium-201 perfusion and regional wall motion after intervention.

MATERIALS AND METHODS

Study patients: The subjects of this study were 40 patients (29 men and 11 women), referred to us for coronary artery bypass grafting (CABG) or percutaneous transluminal coronary angioplasty (PTCA) who underwent early reinjection of thallium-201 before intervention (group I). Of these 40 patients, 29 also underwent conventional stress-redistribution thallium-201 SPECT before intervention (group II). The profile of the subjects is given in Table 1. The age range was 47 to 77 years, with a mean of 62.6 years in group I and a mean of 63.2 years in group II. Eighteen patients in group I and 13 in group II underwent CABG, while the remaining 22 patients in group I and 16 in group II underwent PTCA. Sixteen patients in group I and 12 in group II had a history of myocardial infarction.

Exercise thallium-201 study protocol: All patients in group I underwent early reinjection thallium-201 SPECT at 1–2 weeks before intervention. Medications were discontinued at least 12 hours before the study, with the exception of sublingual nitroglycerin for the relief of chest pain. After an overnight fast, the patients underwent thallium-201 SPECT while exercising on a motorized treadmill according to the standard Bruce protocol. Continuous monitoring of symptoms, electrocardiogram, heart rate and blood pressure was performed. The end point of exercise was chest pain, dyspnea, leg fatigue, horizontal or downsloping ST-segment depression (≥ 0.2 mV), ventricular tachyarrhythmia, or decrease in blood pressure. At peak exercise, 111 MBq of thallium-201 was administered intravenously, and the patients continued to exercise for an additional 60 seconds. Post-exercise perfusion

images (initial images) were obtained within 5 minutes after tracer injection. Immediately after the initial image was obtained, an additional 37 MBq of thallium-201 was injected intravenously and the reinjection early images were obtained 10 minutes later. The interval from the initial injection of thallium-201 to early reinjection was approximately 30 minutes. Before injection of the additional 37 MBq of thallium-201 as well as after reinjection early imaging, 1 ml of blood was collected from each of the 23 patients and thallium-201 activity was determined in a scintillation gamma counter (Aloca ARC 301) with a 20% energy window centered over 80 keV. Three hours after reinjection early imaging, reinjection delayed images were obtained (Fig. 1). With the same exercise protocol, 29 of the 40 patients (group II) also underwent conventional stress-redistribution thallium-201 SPECT within 2 weeks before early reinjection thallium-201 SPECT. At peak exercise, 111 MBq of thallium-201 was administered intravenously, and the patients continued to exercise for an additional 60 seconds. Post-stress images were obtained within 5 minutes after tracer injection and

Table 1 Comparison of clinical and exercise variances in patients who underwent stress thallium-201 SPECT with or without early reinjection

	group I (n = 40)	group II (n = 29)	p
Age	63 \pm 8	63 \pm 8	NS
Male	29 (73%)	22 (76%)	NS
Prior MI	16 (40%)	12 (41%)	NS
Diseased Vessel	1.4 \pm 0.6	1.3 \pm 0.6	NS
CABG/PTCA	18/22	13/16	NS
Peak HR (bpm)	134 \pm 18	141 \pm 14	NS
Peak BP (mmHg)	176 \pm 35	179 \pm 45	NS
RPP(bpm mmHg)	23526 \pm 5619	25291 \pm 7121	NS
Ex Duration (sec)	388 \pm 131	411 \pm 130	NS

SPECT = single photon emission computed tomography, MI = myocardial infarction, CABG = coronary artery bypass graft, PTCA = percutaneous transluminal coronary angioplasty, HR = heart rate, BP = blood pressure, RPP = rate pressure product, Ex = exercise, NS = not significant

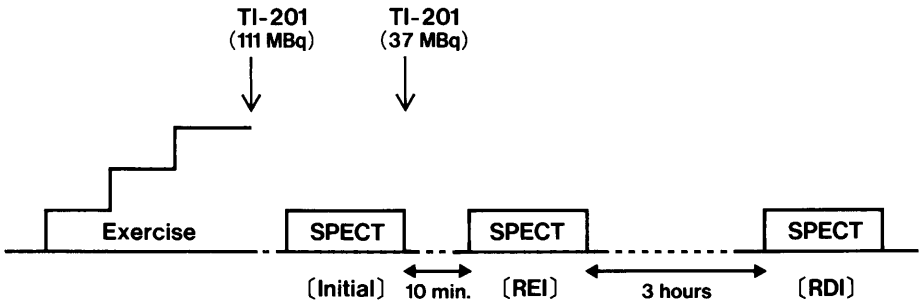


Fig. 1 Exercise, early reinjection of thallium-201, and SPECT acquisition sequence. TI = thallium-201, SPECT = single photon emission computed tomography, [REI] = reinjection early images, [RDI] = reinjection delayed images.

delayed images were obtained 4 hours later. SPECT studies were done with a rotating single-head digital gamma camera equipped with a low-energy, high-resolution, parallel-hole collimator (SHIMADZU SNC-500R) interfaced to a dedicated computer (SHIMADZU Scintipac 700). A 10% energy window centered on 80 Kev was used. Thirty-two projections were obtained over 180 degrees, from the 45-degree right anterior oblique to the 45-degree left posterior oblique position. Each projection image was acquired at a preset interval of 30 sec. The raw data were initially smoothed by means of a Butterworth filter with a cutoff frequency of 0.25 cycles/pixel. Contiguous transverse slices of the left ventricular myocardium were reconstructed by the filtered back-projection method with a Shepp & Logan filter. These images were further processed to obtain vertical long axis, horizontal long axis, and short axis slices. In addition, conventional stress-redistribution thallium-201 SPECT was repeated between 1 week and 3 months after CABG or PTCA, and 2 sets of images (post-stress and delayed images) were obtained.

Coronary arteriography: Coronary arteriography was performed by the standard Judkins technique within 2 weeks of early reinjection thallium-201 SPECT and about 1 to 3 months after intervention. The coronary arteriograms were interpreted by two experienced observers, who were blinded to the results of the thallium-201 SPECT. Each native coronary vessel and bypass graft was graded as follows: complete occlusion (100%), or 99%, 75–98%, and < 75% luminal diameter narrowing. More than 75% stenosis was considered to be significant.

Intervention: Eighteen patients underwent CABG with saphenous vein, internal mammary artery, or gastroepiploic artery grafts. Two patients with 1-vessel disease received 1 bypass graft, 5 patients with 1-vessel disease received 2 bypass grafts, 5 patients with 2-vessel disease received 2 bypass grafts, 4 patients with 2-vessel disease received 3 bypass grafts, 1 patient with 3-vessel disease received 2 bypass grafts, and 1 patient with 3-vessel disease received 3 bypass grafts. Of these 39 bypass grafts, 37 (95%) were shown to be patent by arteriography performed about 1 month after CABG. The remaining 22 patients underwent PTCA. All of these 22 patients had 1-vessel disease. Immediate improvement in coronary stenosis was assessed angiographically by measuring the luminal diameter.

Qualitative interpretation of scintigraphy: For visual interpretation, the initial images, reinjection early images, and reinjection delayed images or the post-stress and delayed images were displayed simultaneously. The left ventricular myocardium was divided into 5 segments (anterior, septal, inferior, lateral, and apical) (Fig. 2). Thallium-201 uptake in each segment was scored by a

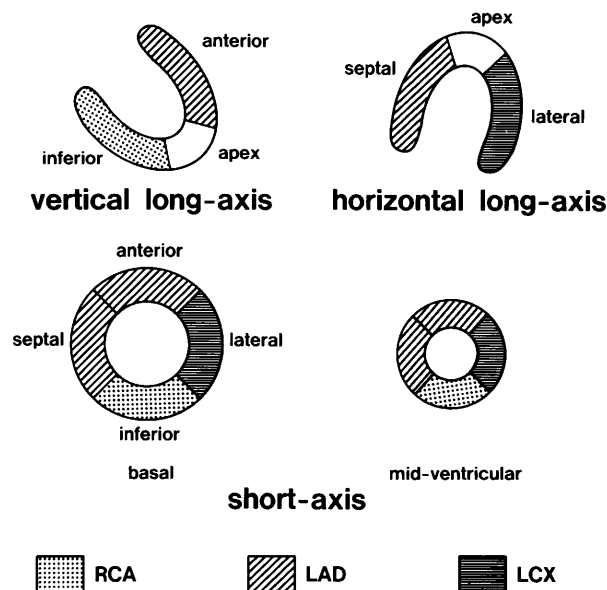


Fig. 2 Diagrammatic representation of mid vertical and horizontal long-axis slices, and two short axis slices displaying five myocardial segments. The distributions of the three major coronary arteries are also described. [RCA] = right coronary artery, [LAD] = left anterior descending coronary artery, [LCX] = left circumflex coronary artery.

consensus of the opinions of two experienced nuclear-medicine physicians with a four-point grading system (3 = normal, 2 = mild reduction, 1 = moderate reduction, and 0 = defect). Both physicians were blinded to the clinical, electrocardiographic, and angiographic data. In group I, a post-stress perfusion defect was considered to be present on the initial image when a myocardial segment had an initial post-stress score ≤ 1 . When the score increased by one or more points on the reinjection early image, the segment was considered to show early fill-in, whereas defects with an unchanged score on the reinjection early image were defined as having no early fill-in. These defects without early fill-in were further categorized according to their score on the reinjection delayed image; those with an increase in the score on the reinjection delayed image were defined as showing new redistribution and those with an unchanged score were defined as persistent defects. Preintervention stress-redistribution thallium-201 SPECT in group II was also interpreted by means of the same grading system. A post-stress perfusion defect was considered to be present when the post-stress thallium-201 uptake score was 0 or 1. The segment was considered to show a reversible defect when the thallium-201 uptake score increased by one or more points on the delayed image, and the segment was considered to show a persistent defect when the uptake score was not changed. A preintervention thallium-201 perfusion defect was considered to have been improved by intervention if the postintervention delayed thallium-201 score was 2 or 3.

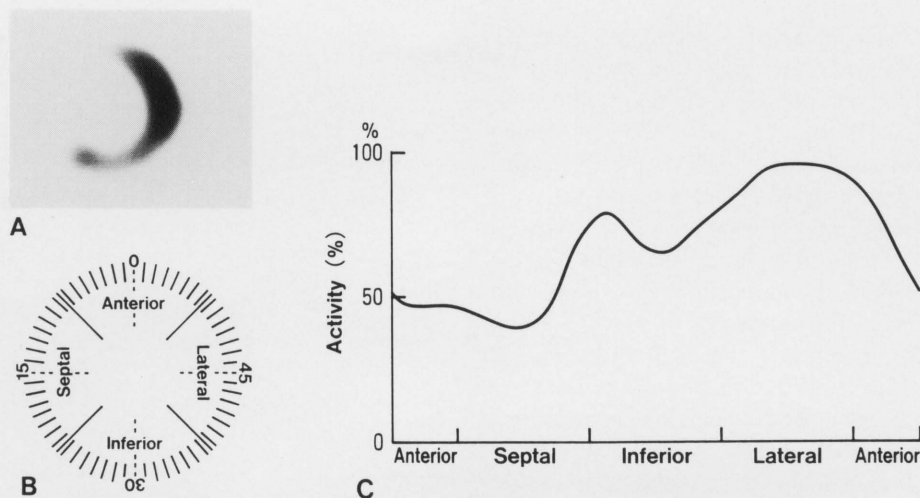


Fig. 3 Sector analysis for assessing the regional myocardial thallium-201 uptake. A short axis thallium-201 tomogram obtained after exercise in a patient with coronary artery disease is shown in Panel A. The left ventricular myocardium is subdivided into 60 sectors, representing four myocardial regions (Panel B). Panel C shows the patient's thallium-201 uptake during stress imaging in each sector. In this patient, perfusion defects are apparent in the anterior and septal regions.

Quantitative scintigraphic interpretation: The same short axis tomograms used for visual interpretation were also analyzed with a semiautomatic quantitative circumferential-profile analysis.⁹ An operator-defined region of interest was drawn around the left ventricular activity of the short axis slices on initial images, the corresponding tomograms of early reinjection images, and reinjection delayed images. The myocardial activity was subdivided into 60 sectors, each emanating from the center of the tomograph. All 60 sectors were of equal arc, which began at 12 o'clock and proceeded counterclockwise. To facilitate comparison of these data with the qualitative interpretations, the sectors were then grouped and averaged into four myocardial regions (Fig. 3).

Regional wall motion analysis: In all 40 patients, preintervention resting left ventricular wall motion was assessed by X-ray contrast ventriculography in the right anterior and left anterior oblique projections. Postintervention resting left ventriculography, which was obtained in 22 of the patients, was also assessed in the same way. The left ventricle was similarly divided into five segments (anterior, septal, inferior, lateral, and apical). Two experienced cardiologists reviewed regional wall motion in each segment and scored it with a four-point grading system (normal = 3, hypokinesis = 2, akinesis = 1, dyskinesis = 0). When the wall motion score increased by ≥ 1 point after intervention, the segments were considered to have improved. Wall motion in the septal segments of the patients who underwent CABG was excluded from this analysis because paradoxical motion is occasionally observed in this region postoperatively.¹⁰

Statistical analysis: Results are given as the mean \pm SD. Statistical comparisons were performed by appropriate t-

tests. Comparisons of proportions were performed by way of chi-square analysis or Fisher's exact test, and probability values < 0.05 were considered significant.

RESULTS

Group characteristics

There were no significant differences between groups I and II regarding mean age, sex, the number of diseased vessels, the prevalence of myocardial infarction, or the interventions done. The peak heart rate, peak systolic blood pressure, rate pressure product, and exercise duration at the time of preintervention thallium-201 SPECT were also similar in both groups (Table 1).

Qualitative versus quantitative thallium-201 analysis of initial or post-stress images

Mean regional thallium uptake was $35 \pm 11\%$ for the regions with a visual score of 0, $59 \pm 8\%$ for the regions with a visual score of 1, $72 \pm 7\%$ for the regions with a visual score of 2, and $87 \pm 6\%$ for the regions with a visual score of 3 (all $p < 0.01$).

Preintervention thallium-201 SPECT findings

Of a total of 200 myocardial segments in the 40 patients in group I, 81 segments had definite perfusion defects (visual scores of 0 or 1). Of these 81 hypoperfused segments, 62 (77%) were judged to display early fill-in on reinjection early images. The remaining 19 segments were judged to show no early fill-in. Of the latter 19 segments without early fill-in, 9 showed new redistribution and 10 were persistent defects on the reinjection delayed images. Therefore, 71 (88%) of a total of 81 segments with hypoperfusion on initial images showed early fill-in or new redistribution, and the remaining 10

Myocardial Segments

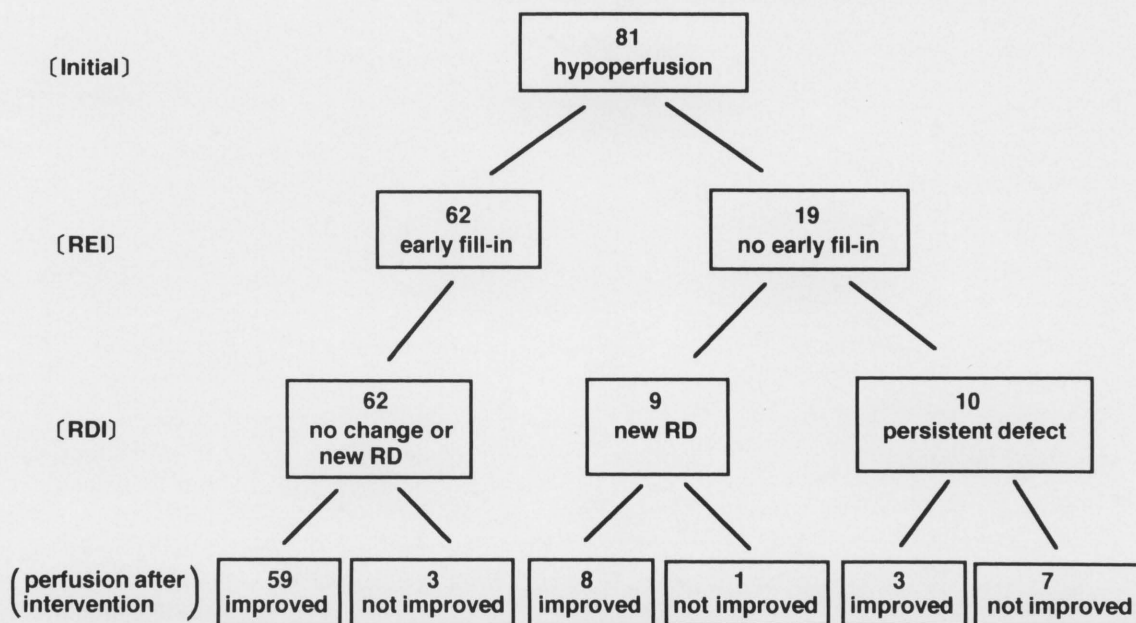


Fig. 4 Outcome of initial hypoperfusion segments at reinjection early imaging, reinjection delayed imaging, and after intervention. [initial] = post-stress image, [REI] = reinjection early images, [RDI] = reinjection delayed images, RD = redistribution.

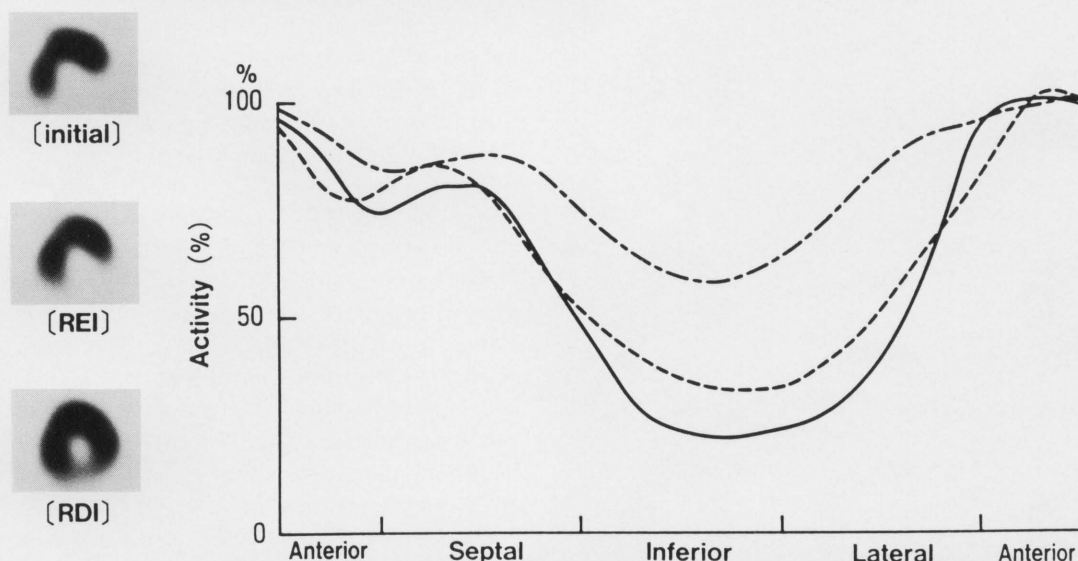


Fig. 5 Quantitative analysis of regional thallium-201 activity. The [initial] (thick solid line), [REI] (dashed line), and [RDI] (dashed and dotted line) curves are shown as a percentage of the activity in the sector with peak activity. In this patient, the myocardial sectors in the inferior region with abnormal perfusion during exercise testing continued to have abnormal perfusion on the [REI], but improved on the [RDI]. [initial] = post-stress image, [REI] = reinjection early images, [RDI] = reinjection delayed images.

segments were persistent defects on the reinjection delayed images (Fig. 4). The mean regional uptake of thallium-201 in segments showing early fill-in or new redistribution increased from $41 \pm 15\%$ to $65 \pm 9\%$ ($p < 0.01$) (Fig. 5). Blood thallium-201 activity in the sample obtained before the reinjection early images was

29732 ± 7957 counts/min, and that in the sample obtained after the reinjection early images was 39938 ± 11520 counts/min ($p < 0.01$). Group II had a total of 51 hypoperfusion segments on post-stress images, with 39 being reversible and 12 being persistent defects on delayed images.

Table 2 Relationship of preoperative thallium-201 imaging with improvement of regional perfusion after intervention in group I and group II

Preoperative Thallium-201 findings	Post intervention perfusion		Total	
	improved	not improved		
group I	70	11	81	
early fill-in on [REI]	59	3	62] $p < 0.01$
no early fill-in on [REI]	11	8	19	
new RD on [RDI]	8	1	9] $p < 0.05$
no new RD on [RDI]	3	7	10	
group II	46	5	51	
RD on [DI]	37	2	39] NS
no RD on [DI]	9	3	12	

[REI] = reinjection early images, RD = redistribution, [RDI] = reinjection delayed images, [DI] = delayed images, NS = not significant

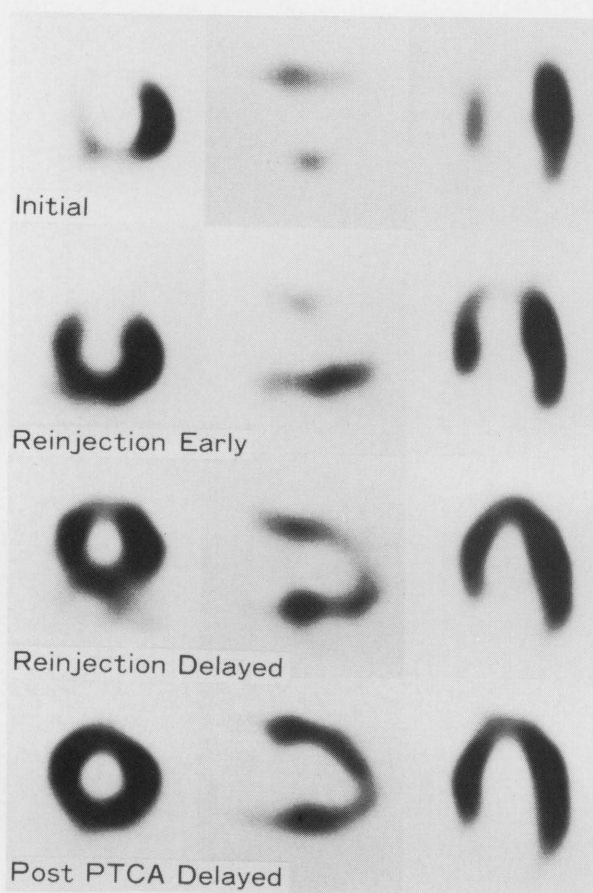


Fig. 6 Short axis, vertical long axis and horizontal long axis thallium-201 tomograms of a patient with coronary artery disease. Before PTCA, severe decrease of thallium-201 activity was observed in the anterior, septal and apical wall on initial images (top row). Early fill-in was observed in the septal and apical wall on reinjection early images (second row). New redistribution was observed in the anterior and apical wall on reinjection delayed images (third row). After PTCA, thallium-201 uptake was normal (fourth row). PTCA = percutaneous transluminal coronary angioplasty.

Postintervention conventional stress-redistribution thallium-201 SPECT findings and improvement in perfusion

Of 81 hypoperfused segments on initial images in group I, 70 segments showed improved perfusion (visual scores of 2 or 3) after intervention and the remaining 11 did not improve. Of the 62 preintervention early fill-in segments, 59 (95%) improved after intervention, and 11 of the 19 (58%) segments without early fill-in also improved ($p < 0.01$). Thus, improvement of perfusion was accurately predicted in 95% (59 of 62) by the reinjection early images, while no improvement was properly predicted in 42% (8 of 19). Therefore, the overall predictive value for improvement and no improvement (the accuracy) was 83% (67 of 81) with initial and reinjection early images. Eight of 9 segments (89%) with new redistribution on reinjection delayed images showed improved thallium-201 uptake after intervention, and 7 of 10 segments (70%) with no new redistribution on reinjection delayed images showed persistent defects on postintervention delayed images ($p < 0.05$) (Table 2, Fig. 6). Therefore, 67 of 71 segments (94%) with early fill-in or new redistribution had improved thallium-201 uptake after intervention, and 7 of 10 persistent defects (70%) did not improve ($p < 0.01$). In group I, the accuracy was 91% (74 of 81) with initial and reinjection delayed images.

Of 51 hypoperfusion segments in group II, 46 showed improved perfusion and the remaining 5 did not improve after CABG or PTCA. Of the 39 segments with redistribution, 37 showed improved perfusion, but 9 of 12 with persistent defects also improved after intervention (p : not significant). Thus, improvement of perfusion was accurately predicted in 95% (37 of 39), while no improvement was properly predicted in 25% (3 of 12). In group II, the accuracy was 78% (40 of 51) (Table 2).

The predictive value for improvement in perfusion was 95% on reinjection early images, 94% on reinjection delayed images, and 95% on conventional delayed images (p : not significant). Although the predictive value for no improvement in perfusion was 42%, 70%, and 25%

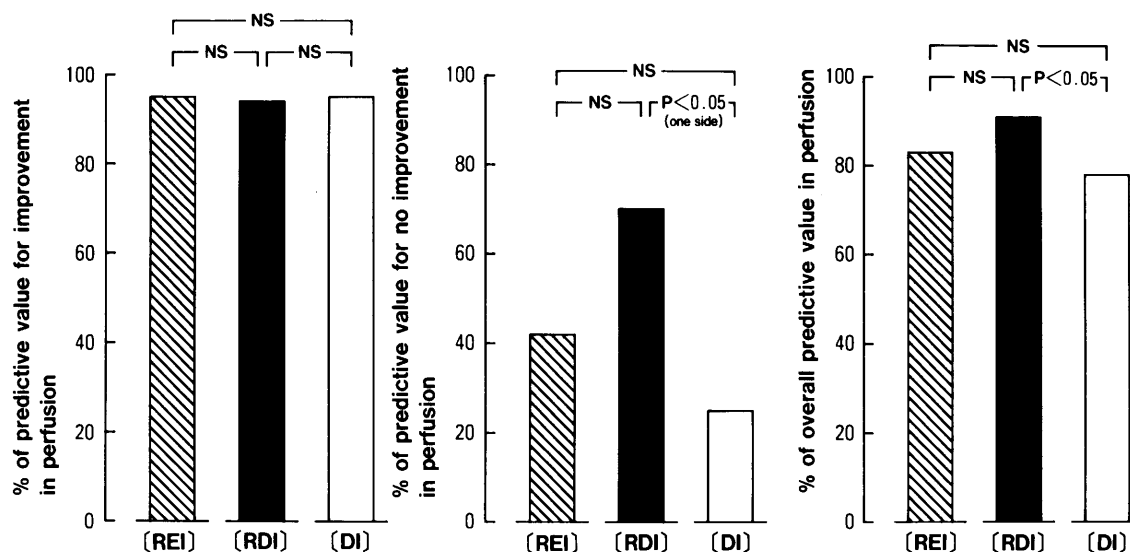


Fig. 7 Comparison of the predictive value of the improvement and no improvement in perfusion obtained from early reinjection and conventional stress-redistribution thallium-201 SPECT. SPECT = single photon emission computed tomography, [REI] = reinjection early images, [RDI] = reinjection delayed images, [DI] = delayed images, NS = not significant.

Table 3 Relationship of preoperative thallium-201 imaging with improvement of regional wall motion after intervention in group I and group II

Preoperative thallium-201 findings	Post intervention wall motion		Total	
	improved	not improved		
group I	40	6	46	
early fill-in on [REI]	33	2	35] p < 0.05
no early fill-in on [REI]	7	4	11	
new RD on [RDI]	5	0	5] NS
no new RD on [RDI]	2	4	6	
group II	25	5	30	
RD on [DI]	19	3	22] NS
no RD on [DI]	6	2	8	

Abbreviations same as in Table 2

respectively (p: not significant), the predictive value obtained from reinjection delayed images showing a tendency to be higher than that of conventional delayed images (70% vs. 25%) (p < 0.05, one-side). Furthermore, the accuracy in perfusion was 91% with initial and reinjection delayed images. This was significantly higher than the accuracy obtained with post-stress and delayed images in group II (78%, p < 0.05), although these values were similar in group I (91% and 83%, respectively) (Fig.7).

Relationship between severity of coronary stenosis and preintervention thallium-201 uptake in group I

Coronary arteries with severe stenosis ($\geq 99\%$ stenosis) supplied 53 of the 62 segments showing early fill-in, all 9 segments showing new redistribution on reinjection delayed images, and all 10 segments with persistent defects (p: not significant).

Relationship between regional wall motion and preintervention thallium-201 uptake in group I

The mean wall motion score was 2.21 ± 0.83 for early fill-in segments, which was significantly higher than the score of 1.29 ± 1.11 for the segments with persistent defects (p < 0.05). The wall motion score for segments showing new redistribution on reinjection delayed images was 1.63 ± 0.74 (p: not significant).

Preintervention thallium-201 findings versus improvement in regional wall motion

In group I, 46 of 81 hypoperfused segments were compared to assess changes in regional wall motion after intervention. Of these 46 segments, 35 showed early fill-in on reinjection early images. Of the remaining 11 segments, 5 showed new redistribution on reinjection delayed images and 6 showed persistent defects. Of the 35 segments with early fill-in, 33 had normal or improved wall motion after intervention and the remaining 2 did not

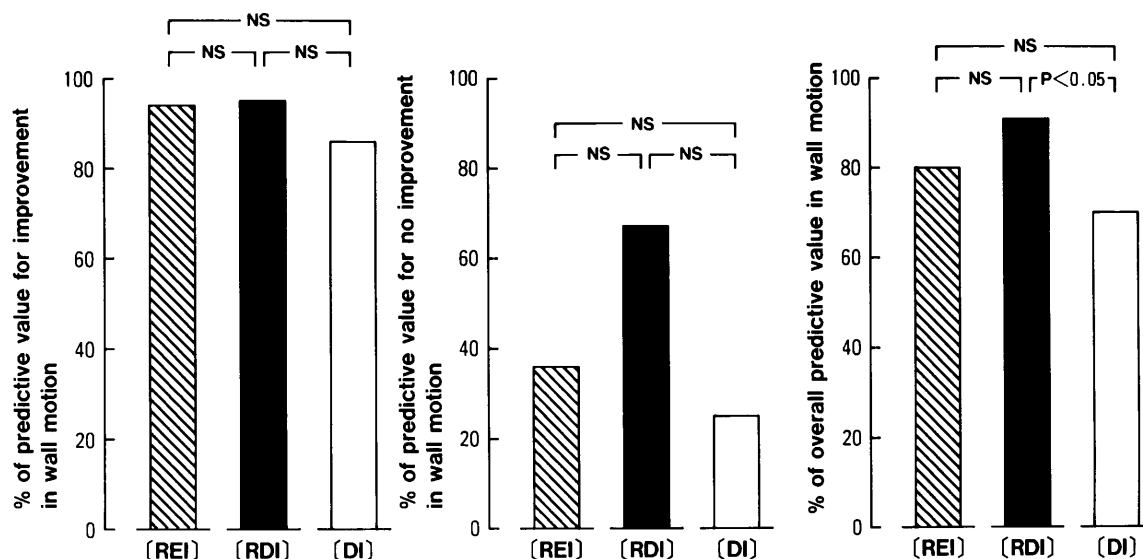


Fig. 8 Comparison of the predictive value of improvement and no improvement in regional wall motion obtained from early reinjection and conventional stress-redistribution thallium-201 SPECT. Abbreviations as in Figure 7.

improve. Of 11 segments with no early fill-in, 7 had improved wall motion after intervention and 4 did not improve ($p < 0.05$). After intervention, all 5 segments with new redistribution on reinjection delayed images exhibited normal or improved wall motion, and 2 of 6 segments with persistent defects also showed improvement (p : not significant). In group II, 30 of 51 hypoperfused segments were compared before and after intervention. Of these 30 segments, 22 showed redistribution and the remaining 8 showed persistent defects. After intervention, 19 of the 22 segments with redistribution exhibited normal or improved wall motion, while 6 of the 8 segments with persistent defects also showed improvement (p : not significant) (Table 3).

The predictive value of reinjection early images for improvement of wall motion was 94% (33 of 35), while it was 95% (38 of 40) for reinjection delayed images, and 86% (19 of 22) for conventional delayed images (p : not significant). Furthermore, the predictive value for no improvement in wall motion was 36% (4 of 11), 67% (4 of 6), and 25% (2 of 8), respectively (p : not significant). The accuracy in wall motion was 91% with the initial and reinjection delayed images. This was significantly higher than the accuracy of the conventional post-stress and delayed images in group II (70%, $p < 0.05$), although these values were similar in group I (91% and 80%, respectively) (Fig. 8).

DISCUSSION

At present there are more options for myocardial revascularization than before and broader indications for intervention. Therefore, accurate assessment of the extent of viable myocardium in patients with prior myocardial

infarction is of considerable clinical importance. Conventional stress-redistribution thallium-201 SPECT has played an important role in distinguishing ischemic from infarcted myocardium in patients with coronary artery disease. However, recent reports have shown that up to 50% of the myocardial regions with persistent defects may improve after revascularization.^{3,4,11,12} It is therefore necessary to explore various techniques for detecting viable myocardium in areas showing persistent defects on conventional stress-redistribution thallium-201 SPECT.¹³ Separate injections at stress and rest performed on different days,^{14,15} reinjection after delayed imaging,^{8,9,16,17} late (24–72 hours) delayed imaging,^{18–20} a combination of thallium reinjection followed by late imaging,^{21,22} and a combination of late imaging followed by reinjection²³ have been proposed to overcome the limitations of conventional stress-redistribution thallium-201 imaging.

In the late 1970s, there were two studies of separate injections of thallium-201 at stress and rest performed on different days.^{14,15} In both studies, redistribution thallium-201 imaging was comparable with rest imaging. However, Verani and associates²⁴ suggested that resting scintigrams might be needed in a substantial number of patients with severe obstruction of a major coronary artery supplied by collaterals in order to discriminate between myocardial scarring and ischemic tissue. Although double-dose thallium-201 myocardial imaging is a better technique, it is expensive, inconvenient, and delivers a higher dose of radiation.

In 1978, Berman and his associates²⁵ suggested a relationship between coronary artery stenosis and the rate of thallium-201 redistribution. In 1983, Gutman and co-workers²⁶ reported early redistribution (3 to 5 hours) in 14% of hypoperfused segments on post-stress images and

additional late redistribution (18 to 24 hours) in 23%. In 1988, Kiat and his coworkers¹⁹ reported that 4-hour images did not predict postintervention scintigraphic improvement, but late images (18 to 72 hours) images accurately predicted scintigraphic improvement. However, thallium-201 imaging at 18–72 hours after exercise is inconvenient and often yields poor image quality due to a low target-to-background count ratio. In 1991, Kayden and associates²³ reported that poor quality studies occurred in 13% of patients having late (24 hour) imaging. They commented that late images may not only be of a suboptimal count density (which could be a particular problem for SPECT images), but also may not detect all of the potentially viable myocardium, especially when the thallium-201 blood level is too low.

In 1988, Rocco and his coworkers⁷ suggested that the reinjection of a small dose of thallium-201 after delayed imaging might provide a means of identifying jeopardized myocardium in segments exhibiting persistent defects on delayed images. In 1990, Ohtani and his associates¹⁶ stated that the reinjection of thallium-201 after delayed imaging appeared to be a useful noninvasive means for the accurate prediction of reversible ischemic myocardium after CABG, particularly when conventional stress-redistribution thallium-201 imaging showed persistent defects. A similar result was obtained by Dilsizian and his coworkers in 1990.⁹ Furthermore, in 1991 Dilsizian and his coworkers²¹ reported that thallium-201 reinjection might be used instead of 24-hour imaging in most patients in whom a persistent defects were observed on conventional thallium-201 redistribution images.

Our study highlights the ability of early reinjection of thallium-201 to identify myocardial ischemia and viability. In our group II patients who underwent conventional stress-redistribution thallium-201 SPECT, the accuracy in perfusion was 78%, and in regional wall motion, 70%. These values are in agreement with those of previous reports.^{3,4} In our group I patients who underwent early reinjection, the accuracy percentages for perfusion and regional wall motion were 83% and 80%, respectively, with only reinjection early images. These values are comparable with those obtained with conventional stress-redistribution thallium-201 SPECT. Comparing reinjection delayed images with postintervention delayed images, the predictive value for no improvement in perfusion was 70%, which tended to be higher than the value obtained with conventional delayed images ($p < 0.05$, one-side). Furthermore, the accuracy in perfusion and regional wall motion was 91% in both, which was significantly higher than the accuracy obtained in group II (although it was similar to that in group I).

In 1991, Kiat and his associates²² reported that early reinjection of thallium-201 did not reduce the frequency of late reversibility and that thallium-201 reinjection just prior to or immediately after 4-hour redistribution imaging

might be more effective in reducing the incidence of late reversibility. They obtained 3 sets of images: post-stress images, 4-hour images (which were identical to the reinjection delayed images in our study), and late images. Although 68% of segments showing post-stress perfusion defects demonstrated nonreversibility on 4-hour images, 24% of persistent defects on 4-hour images and 16% of hypoperfused segments on post-stress images showed new redistribution on late images. In our study, only 12% of segments demonstrating initial hypoperfusion were persistent defects on reinjection delayed images. We did not obtain late images, so late redistribution might have occurred in some segments with persistent defects on reinjection delayed images.

Recently, Van Eck-Smit and his associates demonstrated the advantages of immediate thallium-201 reinjection to detect myocardial viability.²⁷ They reinjected a small dose of thallium-201 immediately after post-stress imaging and obtained another two sets of images 1 and 3 hours after reinjection. They concluded that immediate postexercise reinjection of thallium-201 followed by 1-hour image acquisition may be superior to 3-hour redistribution imaging in identifying viable myocardium. In our study, the second imaging (reinjection early image) was obtained 10 minutes after early reinjection. Therefore the accuracy of reinjection early images might be equal to conventional delayed images. Even if serum thallium-201 concentration increased, sufficient time might be needed for thallium-201 to fill in severely ischemic but viable myocardium.

Thallium-201 redistribution depends not only on the severity of the initial defect but also on its continuing thallium input function as reflected by the serum thallium-201 concentration.²⁸ Hence, if the serum thallium-201 concentration remains the same or increases slightly during the interval between serial images, a viable defect should be filled in. On the other hand, if the thallium-201 delivery is insufficient, the defect may persist even though the underlying myocardium is not infarcted.²⁹ Furthermore, augmenting the blood concentration of the tracer facilitates the redistribution process (i.e., the uptake of thallium-201 by viable myocardial cells). The quality of thallium-201 images after reinjection is consistently better than that of the late images. Our results suggest that early reinjection of thallium-201 with 3-hour delayed imaging may provide a convenient, efficient, and accurate method of assessing myocardial viability in patients in whom invasive interventions are contemplated for myocardial salvage.

ACKNOWLEDGMENT

We thank Mrs. Sanae Onoda for her expert secretarial assistance.

REFERENCES

1. Pohost GM, Zir LM, Moore RH, McKusick KA, Guiney TE, Beller GA. Differentiation of transiently ischemic from infarcted myocardium by serial imaging after a single dose of thallium-201. *Circulation* 55: 294-302, 1977.
2. Strauss HW, Harrison K, Langan JK, Lebowitz E, Pitt B. Thallium-201 for myocardial imaging—Relation of thallium-201 to regional myocardial perfusion. *Circulation* 51: 641-645, 1975.
3. Gibson RS, Watson DD, Taylor GJ, Crosby IK, Wellons HL, Holt ND. Prospective assessment of regional myocardial perfusion before and after coronary revascularization surgery by quantitative thallium-201 scintigraphy. *JACC* 1: 804-815, 1983.
4. Liu P, Kiess MC, Okada RD, Block PC, Strauss HW, Pohost GM, et al. The persistent defect on exercise thallium imaging and its fate after myocardial revascularization: Does it represent scar or ischemia? *Am Heart J* 110: 996-1001, 1985.
5. Brunken R, Schwaiger M, Grover-Mckay M, Phelps ME, Tillisch J, Schelbert HR. Positron emission tomography detects tissue metabolic activity in myocardial segments with persistent thallium perfusion defects. *JACC* 10: 557-567, 1987.
6. Tamaki N, Yonekura Y, Yamashita K, et al. SPECT thallium-201 tomography and positron tomography using N-13 ammonia and F-18 fluorodeoxyglucose in coronary heart disease. *Am J Cardiac Imaging* 3: 3-9, 1989.
7. Rocco TP, Dilsizian V, Maltais F, Strauss HW, Boucher CA, McKusick KA. Thallium reinjection after delayed imaging demonstrates fill-in to regions with "fixed" defects (abstract). *J Nucl Med* 29: 769, 1988.
8. Rocco TP, Dilsizian V, McKusick KA, Fischman AJ, Boucher CA, Strauss HW. Comparison of thallium redistribution with rest "reinjection" imaging for the detection of viable myocardium. *Am J Cardiol* 66: 158-163, 1990.
9. Dilsizian V, Rocco TP, Freedman NMT, Leon MB, Bonow RO. Enhanced detection of ischemic but viable myocardium by the reinjection of thallium after stress-redistribution imaging. *N Engl J Med* 323: 141-146, 1990.
10. Righetti A, Crawford MH, O'Rourke RA, Schelbert H, Daily PO, Ross J Jr. Interventricular septal motion and left ventricular function after coronary bypass surgery: Evaluation with echocardiography and radionuclide angiography. *Am J Cardiol* 39: 372-377, 1977.
11. Tamaki N, Yonekura Y, Yamashita K, Senda M, Saji H, Konishi J, et al. Value of rest-stress myocardial positron tomography using nitrogen-13 ammonia for the preoperative prediction of reversible asynergy. *J Nucl Med* 30: 1302-1310, 1989.
12. Bonow RO, Dilsizian V. Thallium 201 for assessment of myocardial viability. *Sem Nucl Med* 21: 230-241, 1991.
13. Iskandrian AS. Thallium reinjection imaging: the search for an optimal protocol. *J Nucl Med* 34: 743-746, 1993.
14. Blood DK, McCarthy DM, Sciacca RR, Cannon PJ. Comparison single-dose and double-dose thallium-201 myocardial perfusion scintigraphy for the detection of coronary artery disease and prior myocardial infarction. *Circulation* 58: 777-788, 1978.
15. Ritchie JL, Albro PC, Caldwell JH, Trobaugh GB, Hamilton GW. Thallium-201 myocardial imaging: A comparison of the redistribution and rest images. *J Nucl Med* 20: 477-483, 1979.
16. Ohtani H, Tamaki N, Yonekura Y, Mohiuddin IH, Hirata K, Ban T, et al. Value of thallium-201 reinjection after delayed SPECT imaging for predicting reversible ischemia after coronary artery bypass grafting. *Am J Cardiol* 66: 394-399, 1990.
17. Tamaki N, Ohtani H, Yonekura Y, Nohara R, Kambara H, Kawai C, et al. Significance of fill-in after thallium-201 reinjection following delayed imaging: Comparison with regional wall motion and angiographic findings. *J Nucl Med* 31: 1617-1623, 1990.
18. Cloninger KG, DePuey EG, Garcia EV, Roubin GS, Robbins WL, Nody A, et al. Incomplete redistribution in delayed thallium-201 single photon emission computed tomography (SPECT) images: an overestimation of myocardial scarring. *JACC* 12: 955-963, 1988.
19. Kiat H, Berman DS, Maddahi J, Yang LD, Train KV, Rozanski A, et al. Late reversibility of tomographic myocardial thallium-201 defects: An accurate marker of myocardial viability. *JACC* 12: 1456-1463, 1988.
20. Yang LD, Berman DS, Kiat H, Resser KJ, Friedman JD, Rozanski A, et al. The frequency of late reversibility in SPECT thallium-201 stress-redistribution studies. *JACC* 15: 334-340, 1990.
21. Dilsizian V, Smeltzer WR, Freedman NMT, Dextras R, Bonow RO. Thallium reinjection after stress-redistribution imaging: Does 24-hour delayed imaging after reinjection enhance detection of viable myocardium? *Circulation* 83: 1247-1255, 1991.
22. Kiat H, Friedman JD, Wang FP, et al. Frequency of late reversibility in stress-redistribution thallium-201 SPECT using an early reinjection protocol. *Am Heart J* 122: 613-619, 1991.
23. Kayden DS, Sigal S, Soufer R, Mattera J, Zaret BL, Wackers FT. Thallium-201 for assessment of myocardial viability: Quantitative comparison of 24-hour redistribution imaging with imaging after reinjection at rest. *JACC* 18: 1480-1486, 1991.
24. Verani MS, Jhingran S, Attar M, Rizk A, Quinones MA, Miller RR. Poststress redistribution of thallium-201 in patients with coronary artery disease, with and without prior myocardial infarction. *Am J Cardiol* 43: 1114-1122, 1979.
25. Berman D, Maddahi J, Charuzi Y, Waxman A, Diamond G, Swan HJC, et al. Rate of redistribution in TI-201 exercise myocardial scintigraphy: Inverse relationship to degree of coronary stenosis. [abstract] *Circulation* 58 (suppl II): II-63, 1978.
26. Gutman J, Berman DS, Freeman M, Rozanski A, Maddahi J, Waxman A, et al. Time to completed redistribution of thallium-201 in exercise myocardial scintigraphy: Relationship to the degree of coronary artery stenosis. *Am Heart J* 106: 989-995, 1983.
27. Van Eck-Smit BLF, van der Wal EE, Kuijper AFM, Pauwels EKJ. Immediate thallium-201 reinjection following stress imaging: A time-saving approach for detection of myocardial viability. *J Nucl Med* 34: 737-743, 1993.
28. Budinger TF, Pohost GM. Thallium "redistribution"—an explanation. [abstract] *J Nucl Med* 27: 996, 1986.
29. Budinger TF, Knittel BL. Cardiac thallium redistribution and model. [abstract] *J Nucl Med* 28: 588, 1987.