

Radioimmunoscintigraphy of CEA/CA 19-9 producing tumors with I-131 labeled monoclonal antibodies

Ali S. ARBAB,* Kiyoshi KOIZUMI,* Guio UCHIYAMA,* Takao ARAI,* Hideo EGUCHI,**
Yoshirou MATSUMOTO** and Kouichi SUDA***

*Department of Radiology, **First Department of Surgery ***First Department of Pathology,
Yamanashi Medical University

A total of 7 (4 males and 3 females) patients were included in this retrospective study to determine the sensitivity of radioimmunoscintigraphy with I-131 labeled anti CEA/CA 19-9 monoclonal antibodies. Out of 7 patients 2 had ascending colon cancer, one had sigmoid colon cancer, one had rectal cancer and one had adenocarcinoma in the CBD and the remaining two had metastatic tumor (one in the lungs and the other in the liver). Whole body as well as spot images showed a 72% (5/7) positive scan. But post operative specimen counts and imaging showed a high tumor to non-tumor ratio and a good tumor to non-tumor contrast of activity of I-131 labeled monoclonal antibody. We did not find any relation between CEA/CA 19-9 levels and scan findings. A case of liver metastasis was also detected by this radioimmunoscintigraphy.

Key words: CEA, CA 19-9, I-131, monoclonal antibody, radioimmunoscintigraphy

INTRODUCTION

WITH THE DISCOVERY of the hybridoma technique and the production of a monoclonal antibody (Mab) with specific immunoreactivity, immunoscintigraphy has gained momentum in detecting primary as well as metastatic sites of various types of malignancies. But with the radiolabeled Mab available the detection of malignancies still meets with various degrees of successes.¹

Carcinoembryonic antigen (CEA) and CA 19-9 antigen are glycoproteins and were first reported to be associated with colorectal carcinoma but later were found to be associated with malignancies of epithelial origin.²⁻⁴ The use of radiolabeled Mab to CEA and CA 19-9 in either intact or fragmented forms {Fab, F(ab')₂} to detect malignancies of gastrointestinal origin is well documented.^{5,6}

In our study (retrospective study) we used I-131 labeled F(ab')₂ fragments of Mab to CEA/CA 19-9 immunococktail to estimate the sensitivity of radioimmunoscintigraphy with anti CEA/CA 19-9 antibodies in 7 known cases of primary and metastatic adenocarcinoma at various stages.

MATERIALS AND METHODS

Patient population

Seven patients, 4 males and 3 females, known to have adenocarcinoma at various stages from poor to well differentiated either primary or secondary, were included in this study. The age of the patients was 39 to 66 and averaged 54.3 years. All cases were diagnosed by means of modern investigation facilities and histopathologically. Blood levels of CEA and CA 19-9 were estimated by standard RIA and IRMA methods. Human antimurine antibody (HAMA) was estimated by ELISA and the antibody titer was expressed by photoabsorption at 492 nm in all patients pre and post injection of Mab. Tumor size was measured in post operative specimens, or CT or X-ray films. All patients were thoroughly informed and gave their written consent before the examination started. All relevant data of patients are given in Table 1.

Antibody preparation and administration

Mab to CEA/CA 19-9 (IMACIS-1) was supplied by the CIS (Compagnie Oris Industrie) of France through Green Cross RI department of Japan. It was a prelabeled cocktail of Mab to CEA and CA 19-9 and was labeled with I-131. It was supplied as a frozen solution with the following composition:

Received May 12, 1993, revision accepted August 20, 1993.
For reprint contact: Kiyoshi Koizumi, M.D., Department of Radiology, Yamanashi Medical University, 1110 Shimokatou, Tamaho-cho, Nakakoma-gun, Yamanashi 409-38, JAPAN.

Table 1 Patient's data including tumor size, site, scan findings and blood levels of CEA & CA 19-9

Pts. no.	Sex	Age (yrs.)	Diag.	Site	Type	Size	CEA	CA 19-9	Scan
1	male	50	M	Rectum	primary	4.5 cm	5.03	87.95	(-)
2	female	58	W	AC	primary	6.8 cm	1.47	155	(+)
3	male	56	W	SC	primary	4 cm	61.34	4.78	(+)
4	male	60	M	CBD	primary	1.7 cm	1	53.70	(-)
5	male	51	W	Lung	secondary*	4 cm	570	310	(+)
6	female	39	P-M	AC	primary	8 cm	1	24.6	(++)
7	female	66	M	Liver	secondary**	3.2 cm	20.28	5100	(+)

(M = moderately, W = well, P = poorly differentiated adenocarcinoma, AC = ascending colon, SC = sigmoid colon, CBD = common bile duct, Normal values of CEA = 2.5 ng/ml & CA 19-9 = 37 u/ml, *Primary tumor was in rectum, **Primary tumor was in CBD)

Table 2 Post operative specimen data regarding percent injected dose taken up by the tumors, tumor to blood and tumor to non-tumor ratio of radioactivity

Pts. no	pt's scan	specimen scan	days of operation after injection	% ID/gm ($\times 10^{-4}$)	T/B	T/NT
1	-	not done	10	7.927	3.441	7.864
2	+	+	13	2.731	1.152	2.471
3	+	+	13	3.058	3.118	6.123
4	-	+	13	3.048	4.118	3.789
6	++	+	6	31.455	6.757	6.901

(ID = injected dose, T/B = tumor/blood ratio, T/NT = tumor/non-tumor ratio)

I-131 anti CEA antibody F(ab')₂ 1 mg
 I-131 anti CA 19-9 antibody F(ab')₂ 1 mg
 Human serum albumin (HSA) 10 mg
 Phosphate buffered saline 2 ml
 Total radioactivity 3 mCi

ROI in whole body images. The images were taken soon after, and on the 3rd, 5th and 7th days after the injection of radiolabeled Mab. Both anterior and posterior counting were performed and the geometric mean of the two counts was taken.

It was dissolved in 100 ml of normal saline and administered to the patients intravenously by slow drip over a period of 30 minutes. Before administration each patient was given potassium iodide 600 mg each day for 10 days starting 3 days prior to the administration of radio labeled Mab.

Gamma camera imaging

Anterior and posterior views of the whole body as well as spot images were taken with a Toshiba Gamma camera GCA-401-5. The image time and counts/frame were not predefined and were dependent on the image quality and the activity at the tumor site in each case. The first image was taken at 48-72 hours and the other images were taken on the 5th and 7th days after injection. Uptake to the tumors was visually evaluated and classified into three grades: no uptake to the known site of the tumor was (-), increased uptake but lower than the blood pool was (+) and increased uptake similar to or more than the blood pool was (++)

Whole body counting

To calculate the effective half life and the percentage of uptake of the injected dose to the tumor and the other organs, whole body counting was performed by selecting

Post operative tumor imaging

Imaging of the post operative specimen was done with a gamma camera without a collimator putting the specimen on the surface of the gamma camera separated by a sheet of paper.

Post operative specimen counting

Specimens of the tumor, non-tumorous tissue, surrounding fatty tissue and blood were collected separately and weighed. All of the collected materials were counted in a gamma well counter. To calculate the percentage of the injected dose taken up by the specimen, a standard solution was prepared from the residual volume of the injection and counted.

RESULTS

The findings are shown in Table 1. Among 7 patients 5 (72%), had a positive scan and 2 (28%) had a negative scan. Usually late views were considered because early i.e. 48-72 hour images included more background noise. Patients with ascending colon carcinoma and lung metastasis showed good contrast of activity of radiolabeled Mab after 3-7 days. The smallest tumor detected was 3.2 cm in diameter and it was a case of liver metastasis fol-

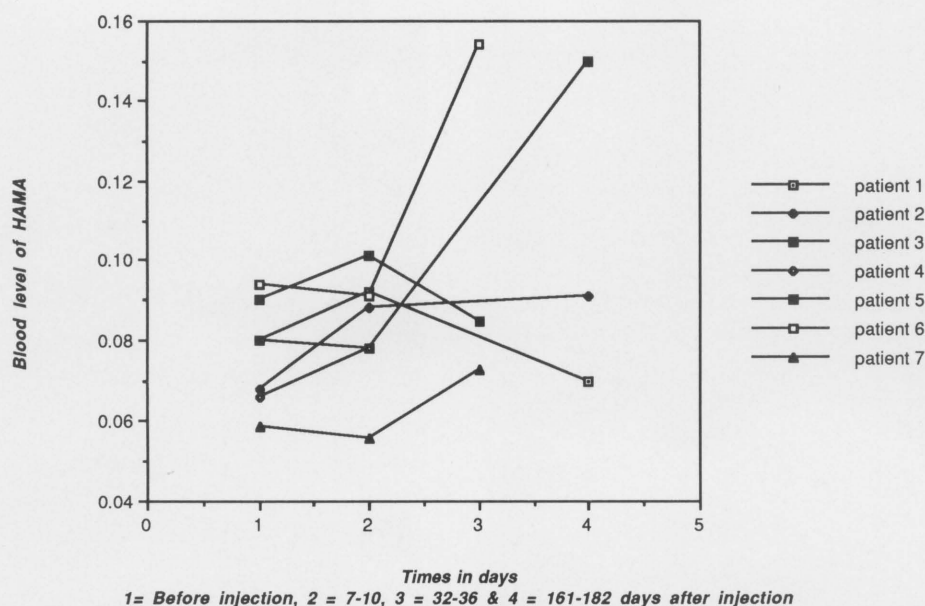


Fig. 1 Graphical representation of blood levels of HAMA before and after the administration of radiolabeled Mab.

lowing adenocarcinoma of the common bile duct (CBD). There was no relation between blood levels of CEA/CA 19-9 and the positive or negative scans.

In whole body counting, the retention half-life of I-131 was estimated to be 1.8 ± 0.53 days and there was no relation between blood levels of CEA/CA 19-9 and the retention half life of labeled Mab.

The post operative specimen data are shown in Table 2. Post operative imaging of specimens from 4 primary cases was performed and in all cases the scan was positive. A case of adenocarcinoma in CBD had a negative scan but in post operative specimen imaging there was good contrast between activity in tumor and surrounding tissues. Post operative specimen counts showed a good tumor to non tumor ratio of uptake of the tracer. The earlier the date of operation after injection, the higher the absolute uptake is.

No immediate or delayed allergic or hypersensitive reaction was observed in any patient after the infusion of radiolabeled Mab. However, in two patients HAMA levels were increased after 32–161 days of post injection of Mab and in other patients the levels were unchanged (Fig. 1). None of them showed any immediate change in laboratory test results except one who had metastasis in the liver and showed lowering of all blood counts, specially platelets, from 158×10^4 to 26×10^4 pre and post injection counts respectively but there was no bleeding episode and no treatment was needed.

CASE PRESENTATION

Case 1 (pt. No 6, Fig. 2)

A 39-year-old female had a large (8 cm) adenocarcinoma in the ascending colon with normal CEA and CA 19-9

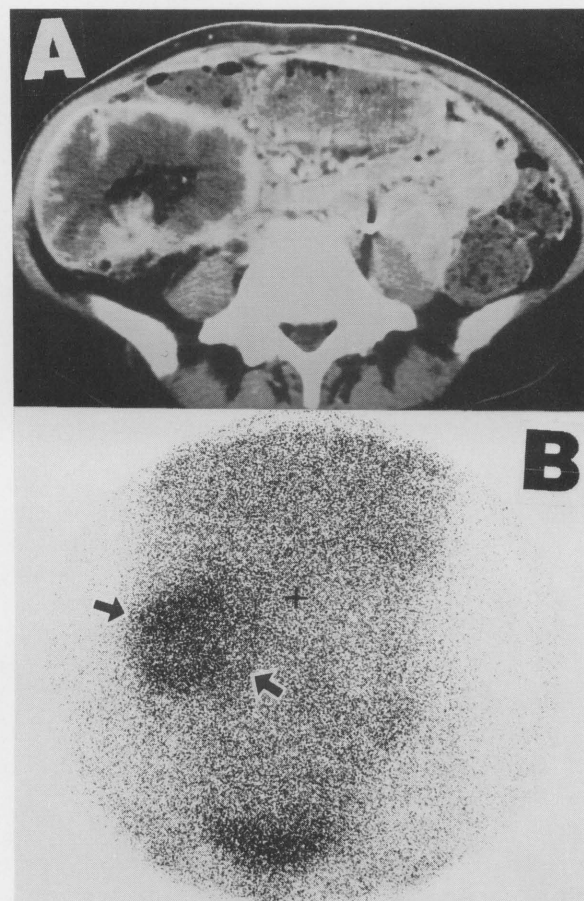


Fig. 2 (A) CT shows large tumor in ascending colon measuring more than 8 cm. (B) Scintigraphy shows intense activity of radiotracer at the tumor site (arrows).

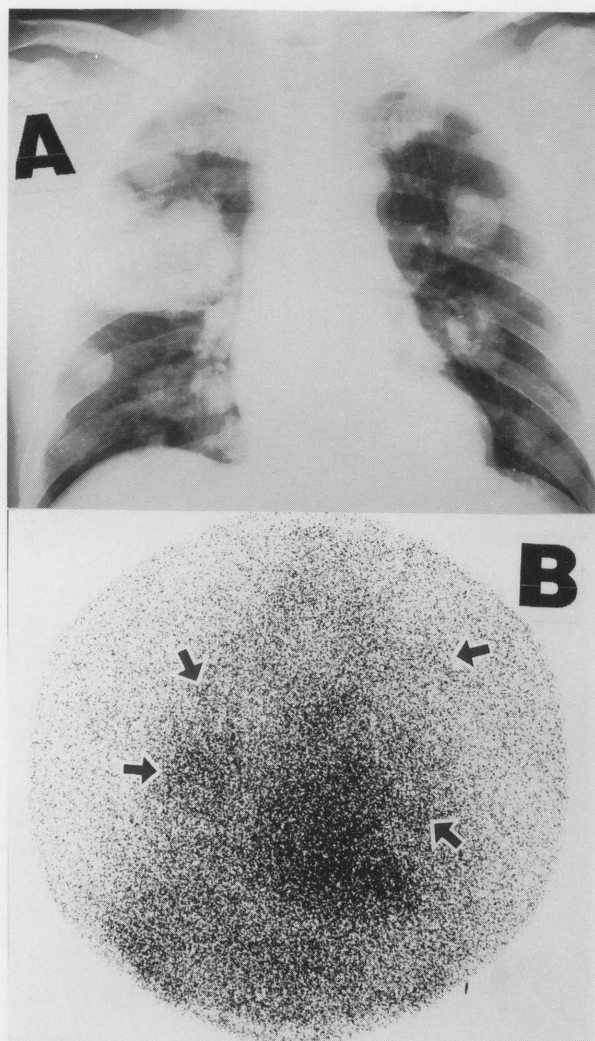


Fig. 3 (A) Chest X-ray of patient whose primary tumor was in the rectum shows multiple metastatic foci in both lungs. (B) Radionuclide imaging shows accumulation of radiolabeled Mab in the corresponding metastatic foci in lungs (arrows).

levels. Pre-operative scan showed very hot activity of the radiotracer at the tumor site and a post operative specimen showed a tumor to non-tumor ratio (T/NT) of 6.901. Though circulating CEA/CA 19-9 levels were normal, immunohistochemical staining of the resected specimen was positive for both anti CEA and CA 19-9 antibodies.

Case 2 (pt. No 5, Fig. 3)

A 51-year-old male with lung metastasis following carcinoma in the rectum. The primary tumor was resected and the largest focus in the lungs measured in a chest X-ray film was 4 cm. Both CEA and CA 19-9 levels were very high. Scan shows multiple metastatic foci in both lungs which corresponds with the chest X-ray findings.

Case 3 (pt. No 2, Fig. 4)

A 58-year-old female had a 6.8 cm (from a post operative

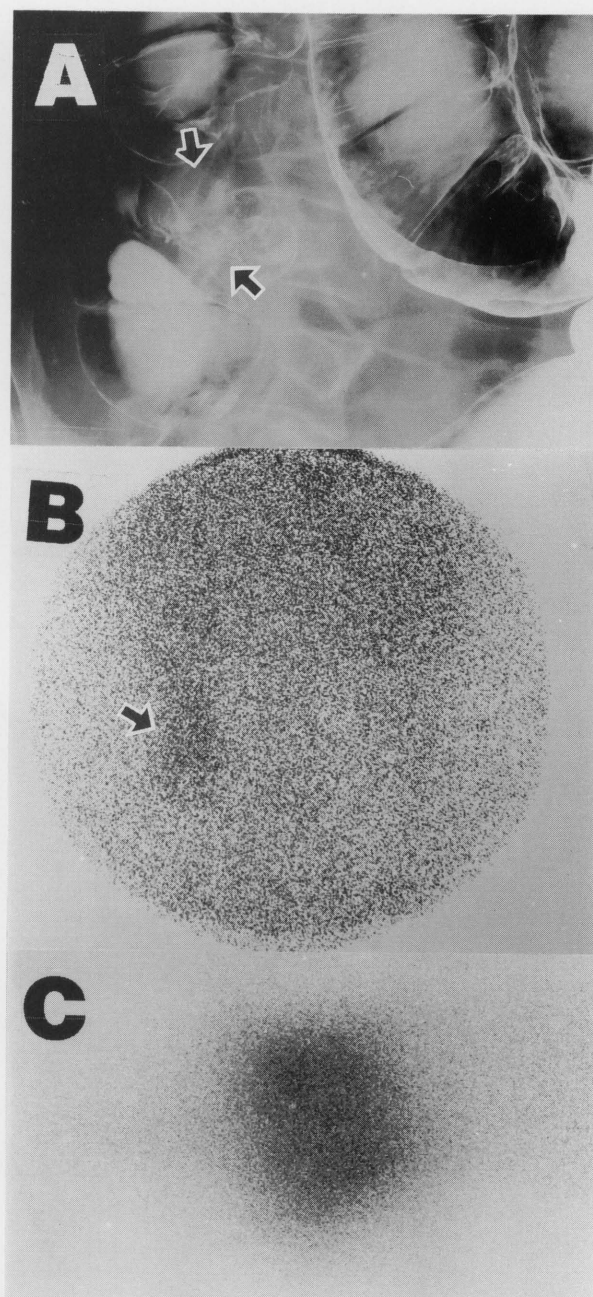


Fig. 4 (A) Double contrast X-ray shows tumor in the ascending colon (arrow). (B) Radionuclide imaging shows activity at the site of tumor (arrow). (C) Post operative specimen imaging shows clear contrast from tumor to non tumor tissues.

specimen) tumor in the ascending colon with normal CEA and increased CA 19-9 levels showing good accumulation of radiolabeled Mab. Post operative specimen scan also showed very clear contrast to the surrounding tissue with 2.471 T/NT.

Case 4 (pt. No 7, Fig. 5)

A lady of 66 years of age with a metastatic focus in liver from adenocarcinoma in CBD measuring 3.2 cm in diam-

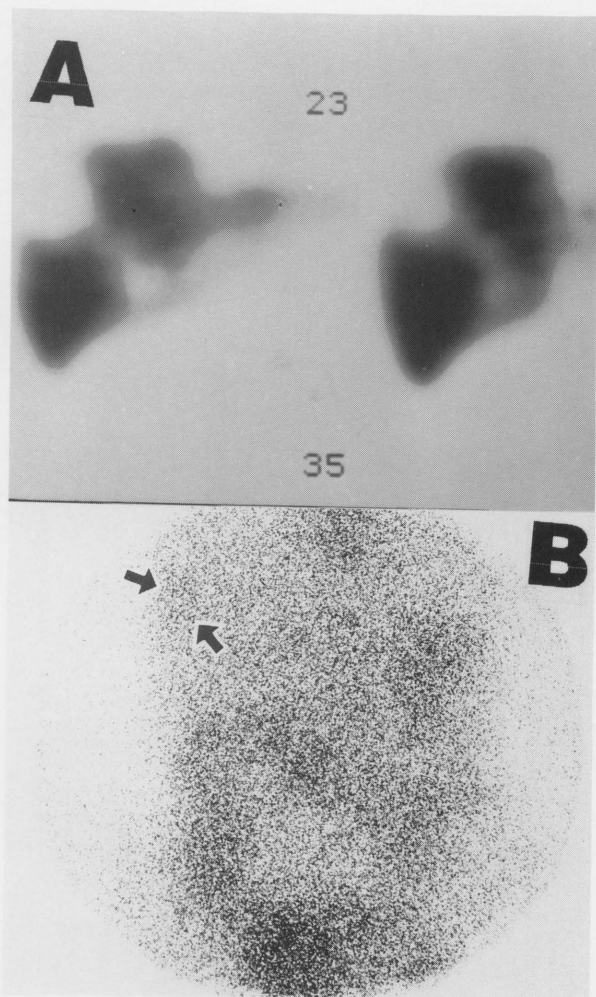


Fig. 5 (A) Colloid liver SPECT imaging of the patient with liver metastasis shows tumor at superio-lateral aspect of right lobe of liver. (B) Immunoscintigraphy shows increased activity at the region of tumor (arrows) compared to the surrounding normal liver tissue.

eter, had a positive scan despite high back ground activity. Both CEA and CA 19-9 levels were increased.

Case 5 (pt. No 4, Fig. 6)

A 60-year-old male presented with a 1.7 cm (post operative specimen) adenocarcinoma in the CBD adjacent to the duodenum and the blood level of CEA was normal with a mild increase in the CA 19-9 level which showed a negative scan, but imaging of post operative specimen showed increased activity in the region of the tumor with 3.789 T/NT.

DISCUSSION

Results with I-131 labeled intact IgG have shown a general sensitivity of 80%–90%, and tumor detection rates of 50%–70% are more common with indium-111 (In-111) labeled antibodies.⁸ R.P. Baum et al. and M.K.

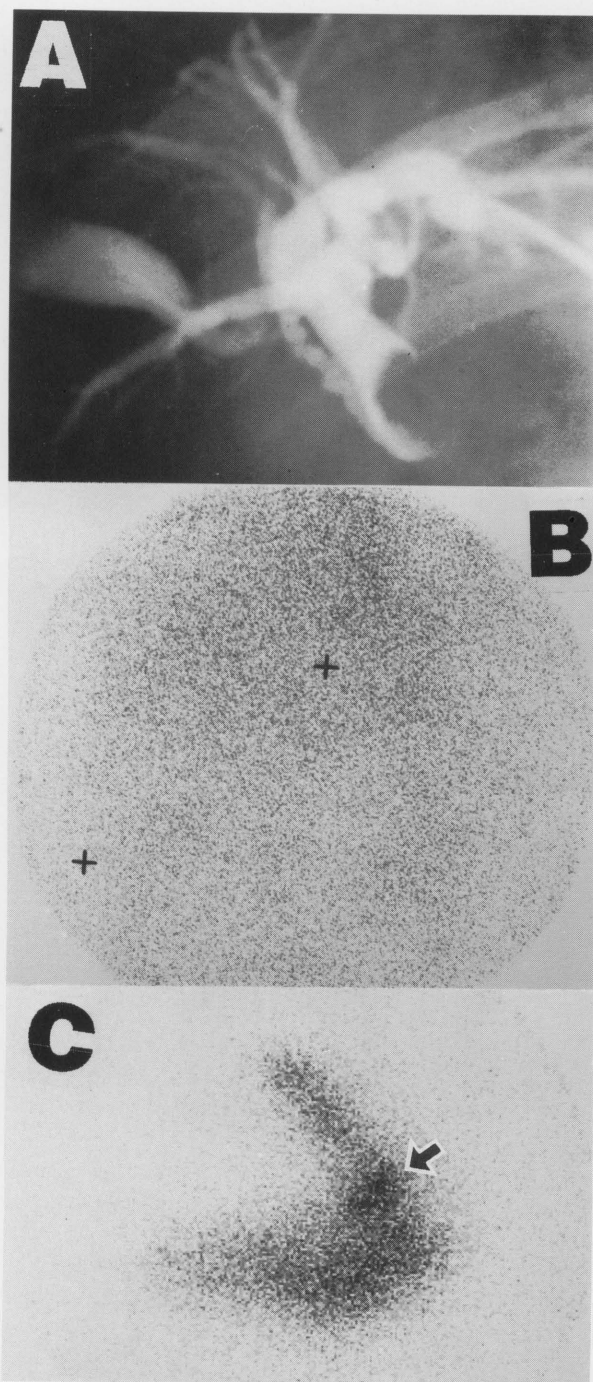


Fig. 6 (A) Endoscopic Retrograde Cholangiopancreatography (ERCP) shows filling defect in CBD adjacent to duodenum due to adenocarcinoma measuring 1.7 cm (from post operative specimen). (B) Immunoscintigraphy (ant. view) shows no apparent increased activity of radiotracer at the region of tumor. (+) markers indicate the inferior border of liver. (C) Post operative specimen imaging shows increased activity at the tumor site (arrow) compared to the surrounding CBD and duodenum.

Haseman et al. have found that the degrees of sensitivity of radioimmunoscintigraphy to detect CEA producing tumors by means of anti CEA/CA 19-9 Mab labeled with

I-131 are 93% and 79% respectively.^{7,9} In another study, out of 35 cases only 16 cases were detected with I-131 labeled B72.3 Mab.¹⁰ But in our study we found the sensitivity to be 72% i.e. 5 patients had a positive scan (one showed multiple metastatic foci in the lungs which corresponded with the chest X-ray findings) and two had a negative scan. One of the negative cases had the smallest tumor in CBD measuring 1.7 cm in diameter and the other one measured 4.5 cm in diameter, was situated in the rectum, so bladder activity might impair the detectability of rectal carcinoma. However, post operative imaging and uptake showed very good tumor to non-tumor contrast in both cases and they are relatively better than other positive cases. The smallest tumor detected was 3.2 cm in diameter and it was a case of metastasis to the liver. It reflects the advantage of using I-131 labeled Mab to detect liver metastasis¹¹ which is rather difficult with In-111 labeled Mab as it accumulates in the hepatic tissue due to its physiochemical behavior.^{12,13} Labeling of I-131 with Mab is rather complicated and could not be done in the hospitals so labeled Mab was supplied by a company in France and we had to order it at least 2 weeks before the study, which was inconvenient.

SPECT (Single Photon Emission Computed Tomography) imaging was tried but it was unsuccessful due to the low counting efficiency of I-131 and this is mentioned by other authors also.^{7,14} Usually late views are taken to minimize the background noise, and also eliminates the need for the subtraction method. In our study we took images on the 5th and 7th days and these provided good contrast between tumorous and non-tumorous tissues. Although potassium iodide was used prior to the injection of I-131 labeled Mab, in all patients there was considerable uptake into the thyroid. This uptake is due to free I-131 released into the blood after *in vivo* dissociation.

In our study although we did not find any relation between the blood level of CEA/CA 19-9 and positive scans, rather intense (++) activity was seen in a case with very low circulating CEA/CA 19-9 levels. This findings excludes the possibility of a relationship between a positive scan and the blood CEA/CA 19-9 level and immunohistochemical staining proves the presence of CEA /CA 19-9 antigen in the tumor without releasing into the circulation.

Many authors describe the formation of HAMA following the administration of Mab.^{8,15,16} In our study we measured the circulating HAMA before the administration of Mab and then 7–10 days, 32–36 days and 161–182 days after Mab administration. But we did not find significant changes in the HAMA levels. This may be due to the use of F(ab')₂ fragments of Mab and it correlates with the findings of others.⁷

No adverse reaction was observed in our study following the injection of Mab. One patient showed a decrease in all blood counts, especially platelets, but no treatment

was needed and this was not due to radiation but rather due to chemotherapy which was going on at that time, as we administered a very low dose (3 mCi) of radiation.

To draw conclusions concerning the sensitivity and specificity of radio immunoscintigraphy in detecting CEA/CA 19-9-producing tumors, more prospective as well as retrospective studies are needed.

ACKNOWLEDGMENTS

We are thankful to the Green Cross RI department of Japan for their kind cooperation and the supply of IMACIS-1.

REFERENCES

1. Larson SM. Clinical radioimmunodetection. 1978–1988: over view and suggestions for standardization of clinical trials. *Cancer Res* 50 (suppl): 892–898, 1990.
2. Gold P, Freedman SO. Demonstration of tumor specific antigen in human colonic carcinoma by immunological tolerance and absorption technique. *J Exp Med* 121: 439–459, 1965.
3. Shively JE, Betty JD. CEA related antigens: molecular biology and clinical significance. *Crit Rev Anc Hematol* 2: 355–399, 1985.
4. Jasson BA, Strand SE, Andersson L. Radiation dosimetry for In-111 labeled anti CEA-F(ab')₂ fragments evaluated from tissue distribution in rats. *J Nucl Med* 33: 1654–1660, 1992.
5. Goldenberg DM, Goldenberg H, Sharkey RM, Lee RE, Ford EH, Horowitz JA, et al. Imaging of colorectal carcinoma with radio labeled antibodies. *Semin Nucl Med* 19: 262–281, 1989.
6. Hinkle GH, Loesch JA, Hill TL, Lefevre SR, Olson JO. Indium-111 monoclonal antibodies in radioimmunoscintigraphy. *J Nucl Med Technol* 18: 16–28, 1990.
7. Baum RP, Maul FD, Senekowitsch R, Lorenz M, Hottenrott C, Happ J, et al. Radioimmunoscintigraphy of CA 19-9/CEA producing tumours using I-131 labeled F(ab')₂ fragments of monoclonal antibodies (19-9/anti CEA radio-immuno cocktail). *Nuclear Medicine in Clinical Oncology*, C. Winkler (ed.), Springer-Verlag Berlin Heidelberg, pp. 197–206, 1986.
8. Goldenberg DM, Larson SM. Radioimmunodetection in cancer identification. *J Nucl Med* 33: 803–814, 1992.
9. Haseman MK, Brown DW, Keeling CA, Reed NL. Radioimmunodetection of occult carcinoembryonic antigen producing cancer. *J Nucl Med* 33: 1750–1757, 1992.
10. Carrasquillo JA, Sugarbaker P, Colcher D, Reynolds JC, Esteban J, Bryant G, et al. Radioimmunoscintigraphy of colon cancer with I-131 labeled B72.3 monoclonal antibody. *J Nucl Med* 29: 1022–1030, 1988.
11. Bhargava KK, Acharya SA: Labeling of monoclonal antibodies with radionuclides. *Semin Nucl Med* 19: 187–201, 1989.
12. Hnatowich JD, Griffin TW, Kosciuszky C, Ruszkowski M, Childs RL, Mattis JA, et al. Pharmacokinetics of an Indium-111 labeled monoclonal antibody in cancer patients. *J Nucl Med* 26: 849–858, 1985.
13. Hnatowich JD. Dissociation and radiolabeling of antibody

- ies. *New Procedures in Nuclear Medicine*, R.P. Spencer (ed.), CRC press, Florida, p. 145, 1989.
14. Perkins AC, Whalley DR, Ballantyne KC, Pimm MV. Gamma camera emission tomography using radiolabelled antibodies. *Eur J Nucl Med* 14: 45–49, 1988.
 15. Zimmer AM, Rosen ST, Spics SM, Leikin RG, Kazikiewicz JM, Silverstein EA, et al. Radioimmunotherapy of patients with cutaneous T-cell lymphoma using an Iodine-131 labeled monoclonal antibody: analysis of retreatment following plasmapheresis. *J Nucl Med* 29: 174–180, 1988.
 16. Halpern SE, Tarburton JP, Sudora E, Hagan P. Alterations in an indium-111 Fab' under conditions of utilization. *Eur J Nucl Med* 19: 387–393, 1992.