

Bile leakage after laparoscopic cholecystectomy demonstrated with ^{99m}Tc -PMT hepatobiliary scintigraphy

Motoo OSHIMA and Hiroshi YASUKOCHI

Department of Radiology, Teikyo University School of Medicine, Tokyo, Japan

A 41-year-old woman underwent laparoscopic cholecystectomy for the treatment of gallstone and adenomyomatosis. One month after laparoscopic cholecystectomy, hepatobiliary scintigraphy was performed with ^{99m}Tc -Sn-N-pyridoxyl-5-methyltryptophan (PMT) to evaluate the presence of a bile leak and/or other complication. A biliary extravasation was noted in the left upper quadrant within 60 minutes. At five hours post injection, a progressive accumulation of ^{99m}Tc -PMT was noted in the lesser sac, the right and left paracolic gutter and in the pouch of Douglas. A diagnosis of biliary leakage was made. The patient underwent exploratory laparotomy to repair the leak from the cystic duct stump.

Key words: bile leakage, hepatobiliary scintigraphy, ^{99m}Tc -PMT, laparoscopic cholecystectomy, gallstone

INTRODUCTION

LAPAROSCOPIC cholecystectomy is a new method used in the treatment of gallstone disease. Its use is certain to become widespread.¹⁻⁴ The merit of this procedure is that it results in less surgical trauma than conventional cholecystectomy. However, laparoscopic cholecystectomy also requires special skills and trainings. This new technique is not without complications.⁵ Complication following this procedure can occur in the bile duct and most commonly leads to bile duct obstruction or bile leakage.⁶ Hepatobiliary scintigraphy is a noninvasive method for examining the bile ducts and looking for bile leakage.⁶⁻⁹

^{99m}Tc -Sn-N-pyridoxyl-5-methyltryptophan (^{99m}Tc -PMT) has more rapid blood clearance and hepatobiliary transit than any other hepatobiliary agent.¹⁰ Less ^{99m}Tc -PMT than ^{99m}Tc -DEIDA is less excreted in the urine, and ^{99m}Tc -PMT is superior in that biliary excretion of the radioactivity is less likely to be suppressed in hyperbilirubinemia.¹⁰ In this study,

we report a case of bile leakage using hepatobiliary scintigraphy with ^{99m}Tc -PMT in a patient who underwent laparoscopic cholecystectomy for the treatment of gallstones and adenomyomatosis.

CASE REPORT

CASE REPORT

A 41-year-old woman underwent laparoscopic cholecystectomy for gallstones and adenomyomatosis. On the fourth postoperative day, the patient was jaundiced. She also complained of distension of her abdomen. One month after laparoscopic cholecystectomy, the patient was given 185 MBq of ^{99m}Tc -PMT to evaluate the presence of a bile leak and/or other complication. A biliary extravasation was noted in the left upper quadrant within 60 minutes after the injection of ^{99m}Tc -PMT (Fig. 1). The accumulation in the left upper quadrant was considered to be a bile leakage into the lesser sac. At five hours post injection, extravasation was noted in the lesser sac (Fig. 2A), the right and left paracolic gutter and in the pouch of Douglas (Fig. 2B). A diagnosis of biliary leakage was made and 300 ml of bile was drained from the right paracolic gutter. Neither operative cholangiography nor CT scan was performed. The patient underwent exploratory laparotomy during which a disruption at the cystic

Received January 29, 1993, revision accepted April 9, 1993.

For reprints contact: Motoo Oshima, M.D., Department of Radiology, Teikyo University School of Medicine, 2-11-1 Kaga, Itabashi-ku, Tokyo 173, JAPAN.

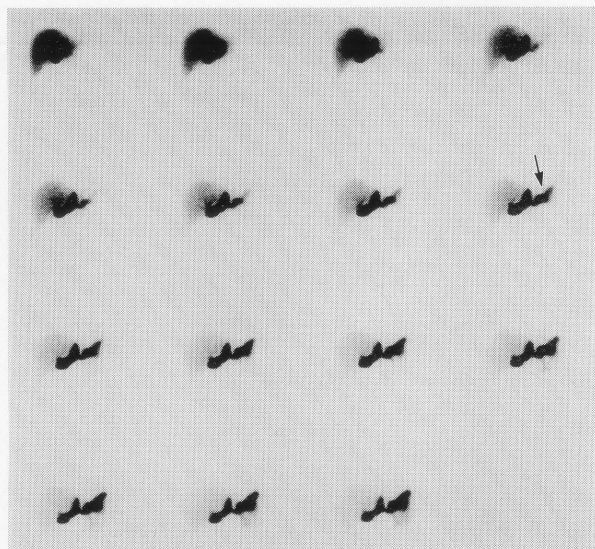
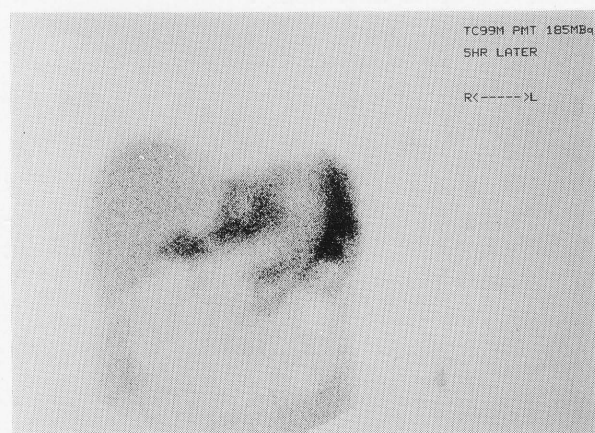
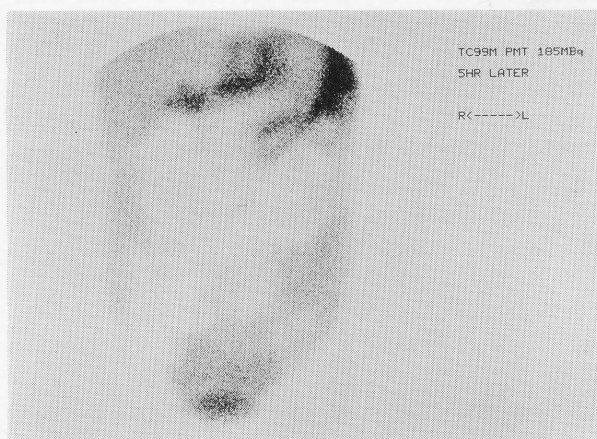


Fig. 1 Sequential 3.75-min images of the anterior abdomen were obtained after administration of 185 MBq of ^{99m}Tc -PMT. A biliary extravasation was noted in the left upper quadrant which was considered to be the lesser sac (arrow).



A



B

Fig. 2 A, B: At five-hour post injection, a progressive accumulation of ^{99m}Tc -PMT was distinctly demonstrated in the lesser sac, the right and left paracolic gutter and in the pouch of Douglas.

stump next to the surgical clip was found and subsequently repaired.

DISCUSSION

Laparoscopic cholecystectomy is associated with less postoperative pain, a shorter hospital stay, and a more rapid recovery and return to normal activity than open cholecystectomy. However, this new procedure requires special skills and training because it is not without complications.⁵ Ponsky⁵ pointed out that complications of laparoscopic cholecystectomy were such as bile duct injury, hemorrhage due to disruption of the cystic or hepatic ductic artery, and bile duct leaks from the gallbladder bed and cystic duct stump. Larson et al.⁴ reported that complications of laparoscopic cholecystectomy totaled 2.1% (41/1983). There were seven patients who developed bleeding at the gallbladder site. Also they reported that there were seven cases of a bile leak arising from the cystic duct stump or gallbladder bed, as in our patient.

Several investigators have recommended routine operative cholangiography to define the common duct anatomy and thereby prevent bile duct injury.¹¹ However, this method is rather invasive. There are many procedures such as cholescintigraphy, ultrasonography, and computerized tomography used in the evaluation of biliary tract disorders.¹² Among them, hepatobiliary scintigraphy has proven a valuable procedure as it provides a sensitive noninvasive assessment of bile leakage, ductal obstruction and complications.⁶⁻⁹ Weissmann et al.¹³ reported that ^{99m}Tc -IDA imaging is a simple, noninvasive way to detect the presence of a bile leak following cholecystectomy. Pasmans et al.⁶ reported the role of ^{99m}Tc -HIDA cholescintigraphy in diagnosing bile leakage after laparoscopic cholecystectomy. Results of seven out of 51 cholescintigrams were abnormal. They also reported that, in four patients without clinical symptoms, there was a minimal accumulation of activity in the right paracolic gutter.⁶

In our patient, following the injection of ^{99m}Tc -PMT, increased activity was seen in the lesser sac, in the right and left paracolic gutter, and in the pouch of Douglas (Figs. 1, 2). The diagnosis of bile leakage was easily made. Thus, the findings on the hepatobiliary scintigrams corresponded with her clinical symptoms.

In conclusion, hepatobiliary scintigraphy with ^{99m}Tc -PMT may be a highly noninvasive, sensitive procedure for the early detection of bile leakage after laparoscopic cholecystectomy.

REFERENCES

1. Reddick EJ, Olsen DO: Laparoscopic laser cholecystectomy: a comparison with mini-lap cholecystectomy. *Surg Endosc* 3: 131-133, 1989
2. DuBois F, Icard P, Berthelot G, et al: Coelioscopic cholecystectomy: preliminary report of 36 cases. *Ann Surg* 211: 60-62, 1990
3. Voyles CR, Petro AB, Meena AI, et al: A practical approach to laparoscopic cholecystectomy. *Am J Surg* 161: 365-370, 1991
4. Larson GM, Vitale GC, Casey J, et al: Multipractice analysis of laparoscopic cholecystectomy in 1983 patients. *Am J Surg* 163: 221-226, 1992
5. Ponsky JL: Complications of laparoscopic cholecystectomy. *Am J Surg* 161: 393-395, 1991
6. Pasmans HL, Go PM, Gouma DJ, et al: Scintigraphic diagnosis of bile leakage after laparoscopic cholecystectomy: a prospective study. *Clin Nucl Med* 17: 697-700, 1992
7. Edell SL, Milunsky C, Garren L: Cholescintigraphic diagnosis of cholecystocolic fistula. *Clin Nucl Med* 6: 303-304, 1981
8. Garide VJ, Gibson DW: Noninvasive evaluation of bile leakage. *Surg Gynecol Obstet* 154: 517-520, 1982
9. Suehiro M, Ishimura J, Fukuchi M: Detection of bile leakage into the thoracic cavity by hepatobiliary scintigraphy. *Ann Nucl Med* 5: 167-169, 1991
10. Kato-Azuma M: ^{99m}Tc -Sn-N-pyridoxylamines: A new series of hepatobiliary imaging agents. *J Nucl Med* 23: 517-524, 1982
11. Berci G, Sackier JM, Paz-Parlow M: Routine or selected intraoperative cholangiography during laparoscopic cholecystectomy? *Am J Surg* 16: 355-360, 1991
12. Weissmann HS, Frank M, Rosenblatt R: Cholescintigraphy, ultrasonography, and computerized tomography in the evaluation of biliary tract disorders. *Semin Nucl Med* 9: 22-35, 1979
13. Weissmann HS, Gliedman ML, Wilk PJ, et al: Evaluation of the postoperative patient with ^{99m}Tc -IDA cholescintigraphy. *Semin Nucl Med* 12: 27-52, 1982