Annals of Nuclear Medicine Vol. 7, No. 4, 223–230, 1993

# Usefulness of bone SPECT of the cervical spine: with special reference to separate visualization of the trachea and thyroid cartilage

Nobuharu YUI,* Takashi TOGAWA,* Fujimi KINOSHITA,* Masamichi YANAGISAWA* and Yoshihisa AKIYAMA**

*Division of Nuclear Medicine, **Division of Radiation Physics, Chiba Cancer Center Hospital

We applied bone SPECT for the examination of the cervical spine. A three-head rotating gamma camera SPECT system was employed for this study. The SPECT image disclosed 42.7% of abnormal accumulations in the skeleton not seen with planar imagings. SPECT could separately visualize the trachea and thyroid cartilage and also provided interpretation of abnormality in the anterior part of the vertebral body being difficult with planar imagings only. The trachea cartilage was seen in 55.4% and the thyroid cartilage was seen in 47.3% of patients with anterior neck density in planar imagings. SPECT clarified that marked cervical curvature and diffuse high uptake by the skeleton might cause high intensity of the anterior neck in planar imagings in the case of non-pathological change. We concluded that bone SPECT is a useful diagnostic tool in detecting occult lesion in the skeleton and to rule out extraskeletal accumulations in examination of the cervical spine.

**Key words:** bone scintigraphy, SPECT, cervical spine, extraskeletal uptake

## INTRODUCTION

IN SKELETAL SCINTIGRAPHY, limitation in getting a detector close to the cervical spine, which is anatomically curved forwards, makes it difficult to get a fine planar image of the skeleton in posterior projection studies. Moreover, in anterior projection studies we often find an unidentified accumulation of the material at the anterior neck. This finding also makes it difficult to interpret lesions in the skeleton. Silberestein et al. reported that this increased density was demonstrated as a result of uptake by the trachea and thyroid cartilage based on their experimental study with animals,[1] but this fact has not been proved in clinical studies. Other authors reported that extraskeletal uptake at the neck occurred in thyroid adenoma,[2] papillary carcinoma,[3] medullary carcinoma,[4] metastatic calcification,[5] multinodular goiter[6] and congenital fibromatosis.[7] These occurred less commonly in clinical studies. However, we often find such a case showing increased density in the neck which cannot be differentiated from the uptake by the skeleton. The purpose of this study is to confirm if the uptake by the trachea and thyroid cartilage actually causes the neck density and to know whether the cartilage can be visualized separately from the skeleton by a high resolution SPECT with a three-head rotating gamma camera.

## MATERIALS AND METHODS

Bone SPECT of the cervical spine was carried out in seventy-four patients with various malignant tumors who were examined by scintigraphy with $^{99m}$Tc-MDP for skeletal survey and showed increased accumulation in the anterior neck in planar imagings. The planar anterior and posterior images were made by making 1500 k counts for each with a rectangular digital camera (Toshiba GCA 90B). Twenty-six male

Received January 29, 1993, revision accepted April 16, 1993.

For reprint contact: Nobuharu Yui, M.D., Division of Nuclear Medicine, Chiba Cancer Center Hospital, 666–2 Nitona-cho, Chuo-ku, Chiba 260, JAPAN.

(age 42–85y, average 58.3y) and 48 female (age 35–72y, average 57.7y) patients were included in this study. SPECT images were taken 3 hours after the administration of 740 MBq (20 mCi) of $^{99m}$Tc methylene diphosphonate (MDP) with a high resolution three-head rotating gamma camera (Toshiba GCA 9300A) fitted with parallel hole collimators. Sixty projection data (6° step, 45 sec/projection) were stored in a 128 × 128 matrix and reconstructed with a Shepp and Logan filter. In all the patients transaxial, sagittal and coronal images were taken and the images were visually interpreted in comparison with conventional planar images. In the planar and SPECT images obtained, it was discussed if abnormal accumulation occurred mainly in the skeleton or the trachea and thyroid cartilage. Accumulation in the trachea cartilage was judged by longitudinally continual ring-shaped visualization in front of the spine and that of the thyroid cartilage was judged by extraskeletal uptake corresponding to thyroid-shape and location. The results were classified according to age and sex.

The following items were discussed:

1. Was the SPECT effective in confirming if the extraskeletal accumulations were actually caused by the trachea and/or thyroid cartilage or by any other tissues?
2. Was there any abnormal uptake by the cervical spine visualized only by SPECT?
3. Did the SPECT clarify if the marked cervical curvature caused high density in the neck in the planar image?

## RESULTS

The results clarified by SPECT were as follows:

1. Separate visualization of uptake by the thyroid cartilage was demonstrated in 35 patients (47.3%) and the uptake by the trachea cartilage was demonstrated in 41 patients (55.4%) with the SPECT imagings. These findings could not be obtained in planar imagings.
2. In forty-seven (64%) of 74 patients examined, abnormal accumulations were noticed in the skeleton, and 20 (42.7%) of them were visualized only by SPECT.
3. The SPECT sagittal image revealed 17 cases of marked curvature of the cervical spine. This finding suggested that the curvature results in high density in the neck in the planar image.
4. Forty-four patients showed signs of spinal increased diffuse uptake in SPECT without any abnormalities. These cases suggested that normal spines themselves result in high density of the anterior neck in the planar image.

Table 1 shows the visualization of the trachea

**Table 1** Visualization of trachea and thyroid cartilage and forward-curvature

| | No. | Cartilage | | Curvature |
|---|---|---|---|---|
| | | Trachea | Thyroid | |
| Male | 26 | 20 (76.9%) | 20 (76.9%) | 8 (30.8%) |
| Female | 48 | 21 (43.8%) | 15 (31.3%) | 9 (18.8%) |
| Total | 74 | 41 (55.4%) | 35 (47.3%) | 17 (23.0%) |

**Table 2** Classification according with age

| Age | No. | Cartilage | | Curvature |
|---|---|---|---|---|
| | | Trachea | Thyroid | |
| 31– | 2 | 1 (50%) | 1 (50%) | |
| 41– | 18 | 6 (33.3%) | 5 (27.8%) | 2 (11.1%) |
| 51– | 19 | 9 (47.4%) | 11 (57.9%) | 5 (26.3%) |
| 61– | 14 | 10 (71.4%) | 5 (35.7%) | 4 (28.6%) |
| 71– | 17 | 12 (70.6%) | 10 (58.8%) | 3 (17.6%) |
| 81– | 4 | 3 (75%) | 3 (75%) | 3 (75%) |

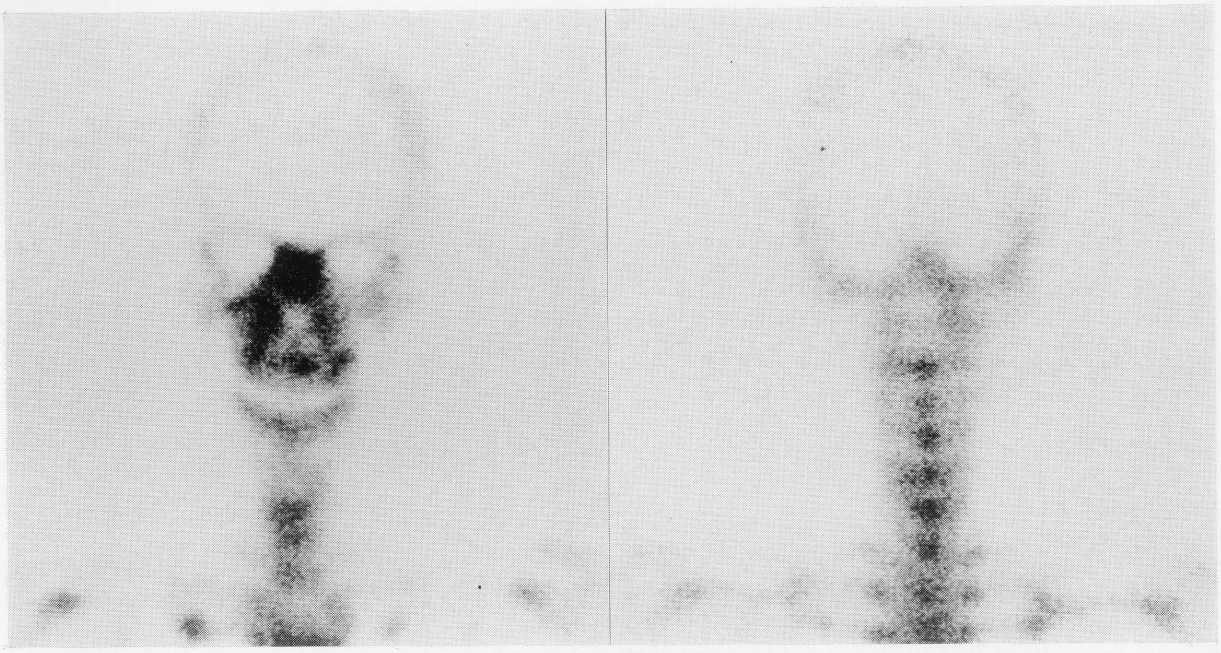

Ant. Post.

**Fig. 1** Case 1. Anterior and posterior images of the cervical spine. The anterior image shows slight increased accumulation in the anterior neck with unidentified origin. The posterior image does not show any abnormality in the skeleton.

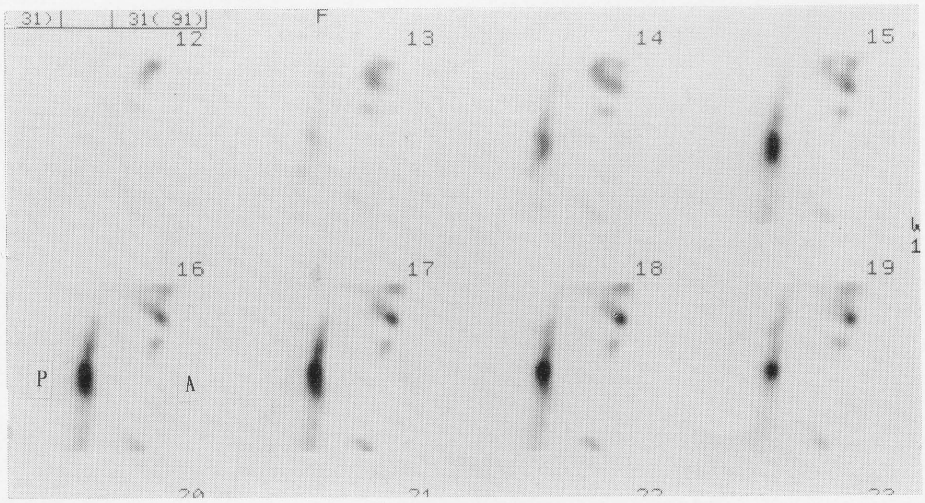


**Fig. 2** SPECT sagittal images shows the increased uptake to be localized in the skeleton.

cartilage, the thyroid cartilage and the curvature of the cervical spine which were clarified by SPECT and classified according to sex. These findings in the male patients were almost twice as numerous as in the female patients.

Table 2 shows the visualizations of these findings classified according to age. The older the patients were, the more frequently the cartilage was visualized. Visualization of the trachea cartilage in particular was seen in as many as 70% of the patients over 60 years and that of the thyroid cartilage in 60% of the patients over 70 years. The curvature was not related to the age of the patient.

*Case presentation*

*Case 1*

A 49-year-old female. This patient who has been treated for right breast cancer by surgery was examined by skeletal scintigraphy in a follow-up study. The anterior planar image showed slightly high density of uncertain origin in the neck. The posterior image did not show any abnormal finding

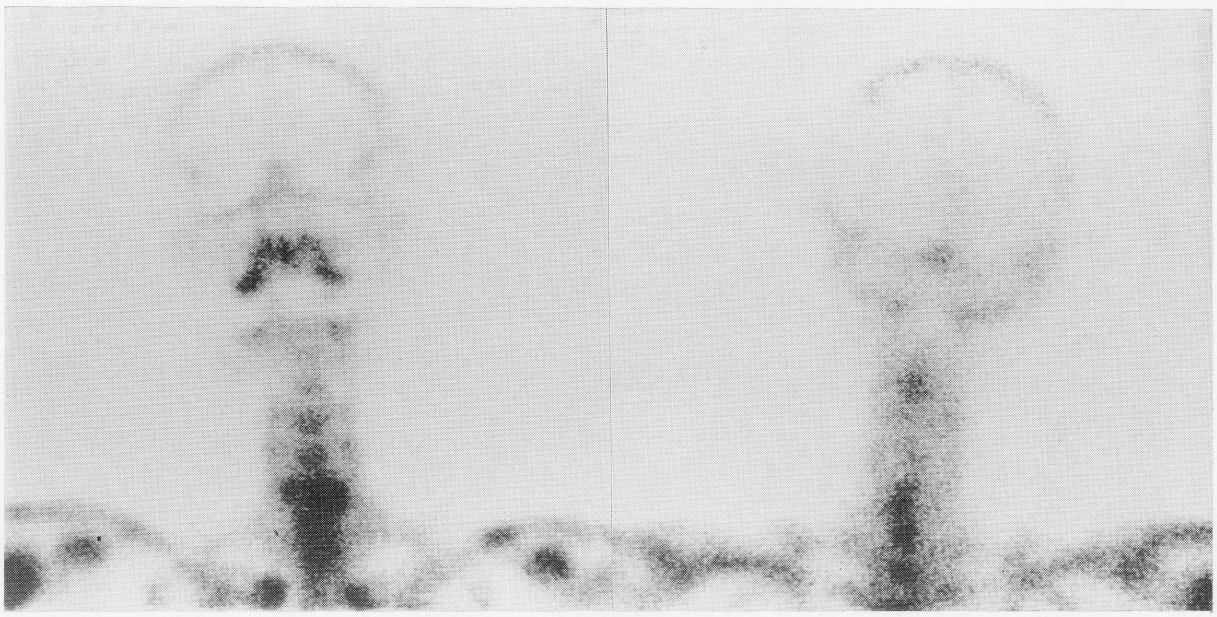

Ant. Post.

**Fig. 3** Case 2. Anterior and posterior images show a marked increased accumulation in the anterior lower neck which is difficult to be identified as a lesion in the skeleton or not.

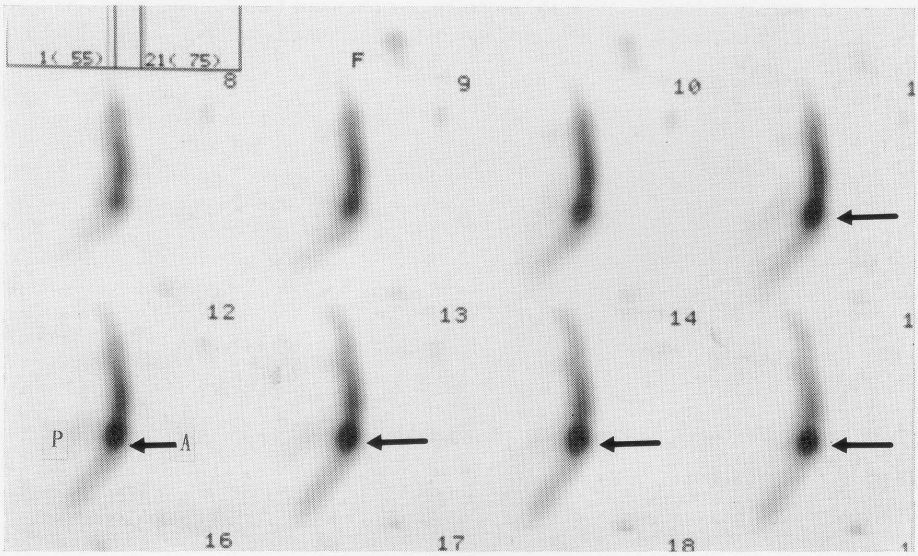


**Fig. 4** SPECT sagittal images show the lesion localized in the lower cervical spine (arrows).

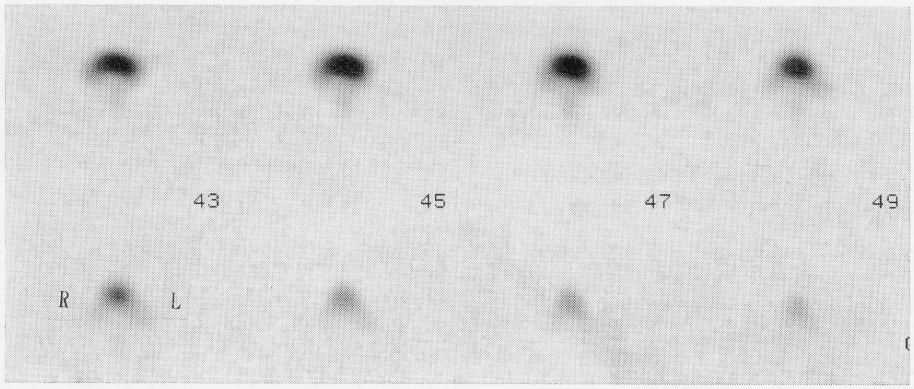


**Fig. 5** SPECT transaxial images also show the uptake to be localized in the anterior part of the vertebral body.

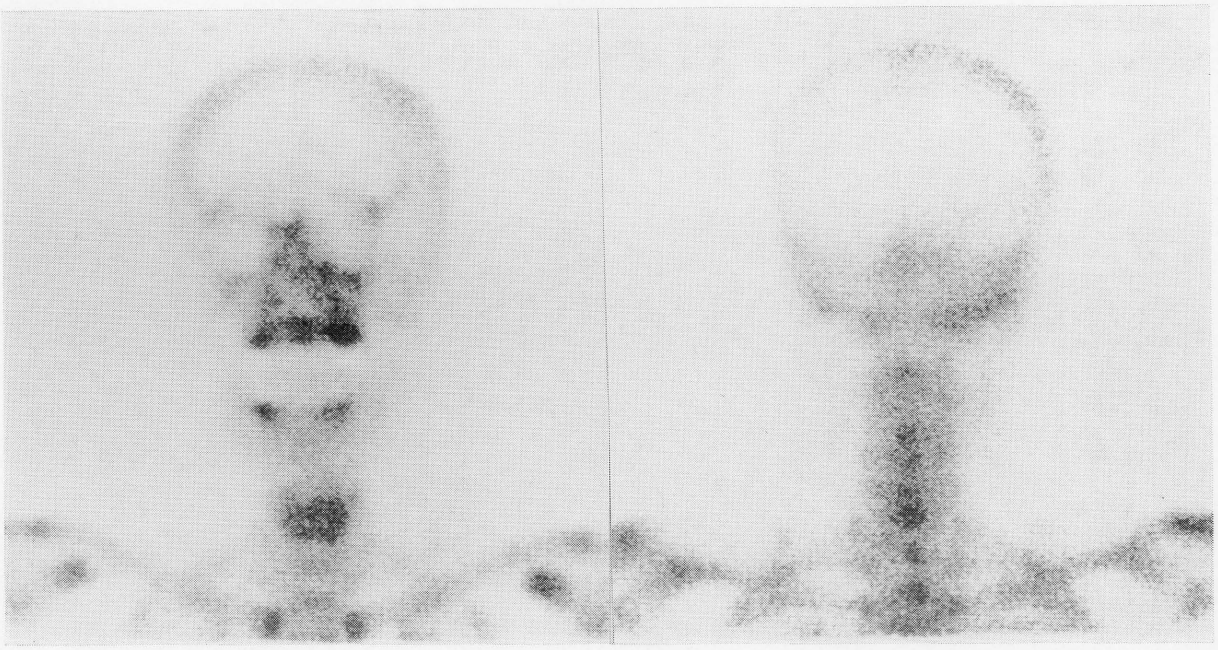

Ant. Post.

**Fig. 6** Case 3. Anterior image shows an increased accumulation in the anterior neck. Posterior image does not show any abnormality.

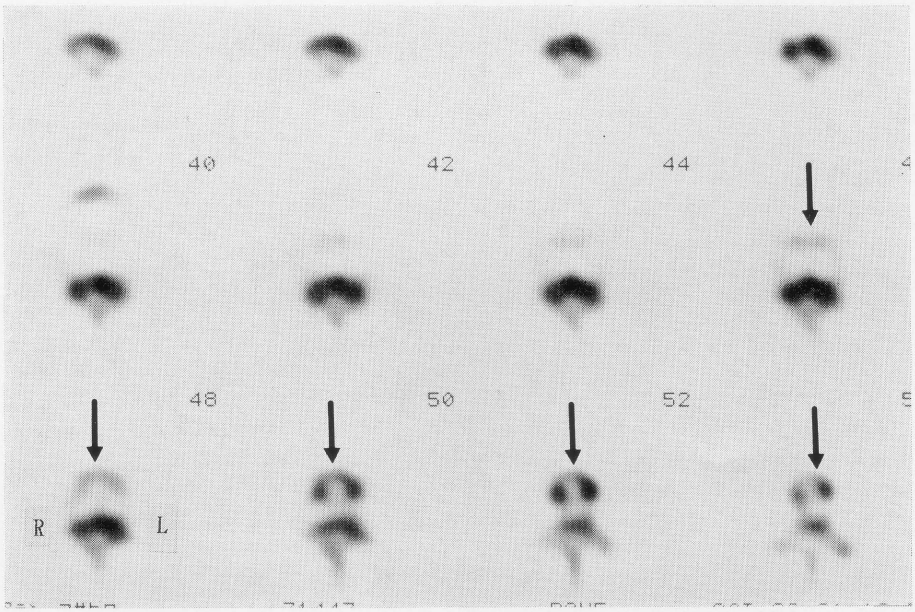


**Fig. 7** SPECT transaxial images show an extraskeletal accumulation shaped in thyroid cartlage (arrows). Images also reveal intraskeletal accumulations in the vertebral bodies.

(Fig. 1). SPECT sagittal images demonstrated that the uptake was located in the skeleton (Fig. 2).

*Case 2*

A 54-year-old male. This patient with lung cancer was examined by bone scintigraphy in a whole body skeletal survey. Planar images showed markedly increased uptake in the neck, but could not differentiate between uptake caused by a skeletal abnormality and that caused by extraskeletal abnormality (Fig. 3). SPECT transaxial and sagittal images showed the uptake to be localized in the spine. No abnormal uptake by extraskeletal tissue was seen (Figs. 4, 5).

*Case 3*

A 47-year-old male. This patient with lung cancer

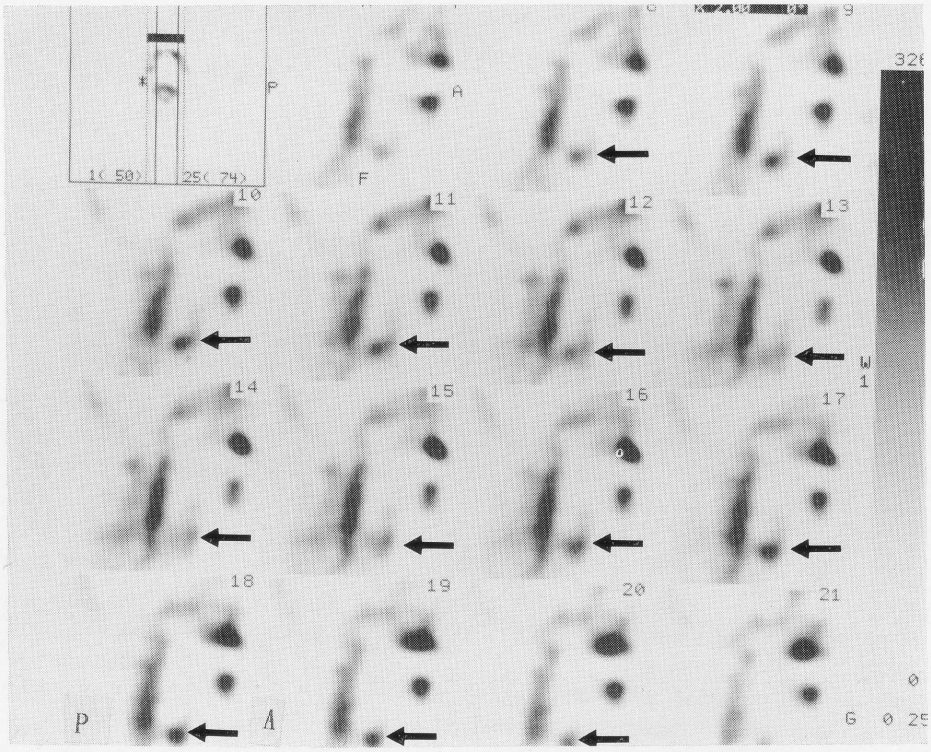


**Fig. 8** SPECT sagittal images demonstrate both the extraskeletal accumulation (arrows) and the increased diffuse uptake by the skeleton.

Ant. Post.

**Fig. 9** Anterior and posterior images show marked high density in the neck which is difficult to differentiate between uptake by a skeletal abnormality and that caused by an extraskeletal accumulation.

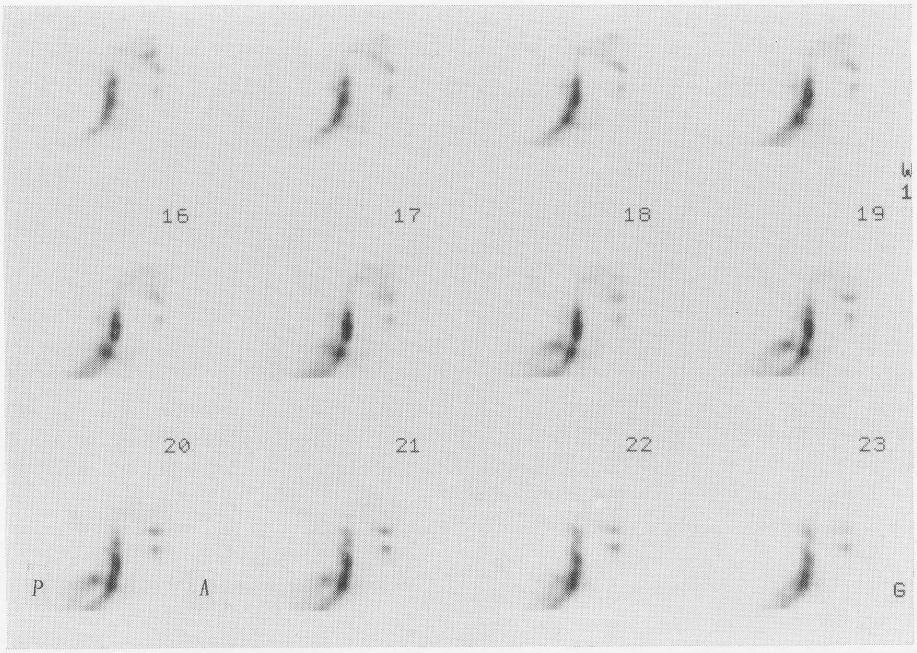


**Fig. 10** SPECT sagittal images identify the lesion of increased uptake by the skeleton. Transaxial images (**Fig. 11**) reveal a ring-shaped extraskeletal accumulation close to the vertebra with suggesting increased uptake by the trachea (arrows).

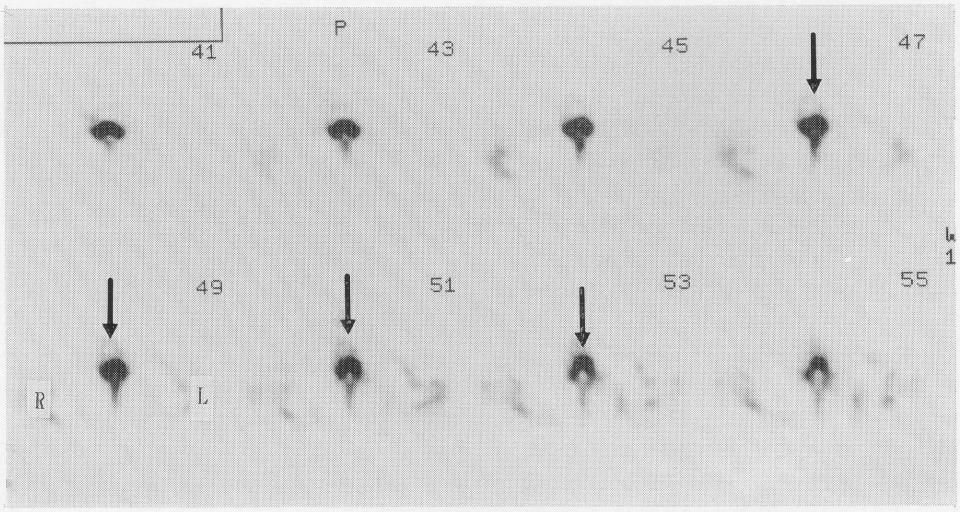


**Fig. 11**

had marked high density in the neck in an anterior projection study. The posterior view did not show any abnormalities (Fig. 6). SPECT transaxial images demonstrated an extraskeletal increased uptake in the shape of thyroid cartilage (Fig. 7). The images also disclosed localized uptake in the lower cervical spine which was covered by the extraskeletal uptake in the planar images. SPECT sagittal images showed diffuse high uptake by the spine with an increased extraskeletal uptake site in front of the lower cervical spine (Fig. 8). A whole body image with no visualization of the salivary glands, lacrimal glands or digestive organs proved that the thyroid gland was not visualized with unlabeled $^{99m}$Tc pertechnetate.

*Case 4*

A 63-year-old male. Planar images of this patient with myeloma showed marked accumulation in the neck and a skeletal abnormality was suspected (Fig. 9). SPECT sagittal images proved the findings to be related to skeletal uptake (Fig. 10). Moreover, SPECT transaxial images revealed anterior ring-shaped localization of the agent close to the spine. The uptake was thought to be caused by the trachea cartilage (Fig. 11).

## DISCUSSION

The cervical spine is one of the most difficult portions to interpret by means of bone scintigraphy. The physiological curvature of the spine does not allow make it possible to position the detector surface close to the bone at the back. In an anterior projection study, unidentified increased density in the neck covers a skeletal abnormality. SPECT is thought to have the ability to detect small lesions not seen in planar imagings. There have been several reports on the usefulness of bone SPECT of the spine,[8–11] but until now cervical spine and extraskeletal neck uptake have not been discussed in terms of early detection of skeletal abnormality and separate visualization of thyroid and trachea cartilage by means of SPECT. In clinical studies we often feel that it is difficult to eliminate a small lesion in the cervical spine, and often find a high density area in the neck of unidentified origin in planar imaging which is indistinguishable from a skeletal lesion. Silberstein et al. reported that trachea and thyroid cartilage caused increased density of the neck based on their experimental study with animals.[1] However, there has been no report describing how the anterior neck density on skeletal scintigraphy was proved to be caused by the thyroid and trachea cartilage. Precise diagnosis of abnormalities of the cervical spine has remained undetermined so far in planar imaging. SPECT enabled the trachea and thyroid cartilage to be visualized separately from the cervical spine. The more frequent increase in these incidences, the older the patient was. These results were thought to relate to calcification of the cartilage. The trachea and thyroid cartilage of the male patients were visualized twice as often as the female patients in all age groups. This fact suggests that the cervical spine should be more carefully interpreted especially in male patients. Concerning the cervical spine, SPECT disclosed 42.7% of skeletal lesion not seen in planar imagings. SPECT also clarified that marked curvature of the spine and diffuse high uptake by the spine itself might cause high density of the neck in a planar image without any pathological change. We have reported the usefulness of bone SPECT in terms of early detection of skull base invasion of nasopharyngeal carcinoma and its superiority to CT and MRI.[12] Separate visualization of overlapping facial bone which has an anatomically complex structure was possible only by utilizing SPECT. The cervical spine is anatomically curved forwards and is also one of the most difficult portions to get clear image of with planar imaging alone because of its distance from the detector. In contrast SPECT makes it possible to visualize the skeletal lesions not seen with planar imagings and to identify the neck density as the trachea and thyroid cartilage by visualization separate from that of the spine. It is concluded that the application of SPECT is very useful for precise identification of lesions in the cervical spine.

## REFERENCES


1. Silberstein EB, Francis MD, Tofe AJ, et al: Distribution of $^{99m}$Tc-Sn diphoshonate and free $^{99m}$Tc-pertechnetate in selected soft and hard tissues. *J Nucl Med* 16: 58–62, 1975
2. Siddiqui AR, Wellman HN, Park H-M, et al: $^{99m}$Tc diphosphonate imaging in the differential diagnosis of thyroid nodules. *Clin Nucl Med* 7: 353–356, 1982
3. Tonami T, Sugihara M, Hisada K: Concentration of $^{99m}$Tc-diphosphonate in calcified thyroid carcinoma. *Clin Nucl Med* 2: 204, 1977
4. Shigeno C, Fukunaga M, Yamamoto I: Accumulation of $^{99m}$Tc phosphorus compounds in medullary carcinoma of the thyroid. *Clin Nucl Med* 7: 297–298, 1982
5. Arbona GL, Antonmattei S, Tetalman MR, et al: $^{99m}$Tc diphosphonate distribution in a patient with hypercalcemia and metastatic calcifications. *Clin Nucl Med* 5: 422, 1980
6. Kim YC: Thyroid uptake in bone scan on a large multinodular non-toxic goiter with calcific degeneration. *Clin Nucl Med* 5: 561–562, 1980
7. Sty JR, Starshak RJ, Oechler HW: Extraosseous uptake of $^{99m}$Tc-MDP in congenital fibromatosis. *Clin Nucl Med* 6: 123, 1981
8. Collier BD, Johnson RP, Carrera GF, et al: Painful spondylolysis or spondylolisthesis studies by radiography and single-photon emission computed tomography. *Radiology* 154: 207–211, 1985
9. Gates GF: SPECT imaging of the lumbosacral spine and pelvis. *Clin Nucl Med* 13: 907–914, 1988
10. Bellah RD, Summerville DA, Treves ST, et al: Low-back pain in the adolescent athletes: Detection of stress injury to the pars interarticularis with SPECT. *Radiology* 180 (2): 509–512, 1991
11. Ryan PJ, Evans PA, Gibson T, Fogelman I: Chronic low back pain: Comparison of bone SPECT with radiography and CT. *Radiology* 183 (3): 849–854, 1992
12. Yui N, Togawa T, Kinoshita F, et al: Assessment of skull base involment of nasopharyngeal carcinoma by bone SPECT using three detectors system. *Kaku-Igaku* 29: 37–47, 1992 (in Japanese)