

## The value of Tc-99m Nanocolloid scintigraphy in the evaluation of infected total hip arthroplasties

İrem BERNAY, Metin AKINCI, Mehmet KİTAÇI,  
Nejat TOKGÖZOĞLU and Günaydın ERBENGİ

*Ondokuzmayıs University, Faculty of Medicine, Department of Nuclear Medicine, Samsun  
Hacettepe University, Faculty of Medicine,  
Departments of Nuclear Medicine and Orthopedics, Ankara, Turkey*

The early diagnosis of loosening is very important, since it provides a chance to protect the bone structure by means of a good postrevision outcome. Although the delayed stage of infected loosening can easily be detected by clinical presentations, significant laboratory data and plain X-rays, diagnosis becomes a problem in the early stage. In this study the value of Tc-99m Nanocolloid (NCol) scintigraphy in the diagnosis of infected loosening was evaluated in 28 patients with painful total hip arthroplasty and 10 controls without any complaint after total hip arthroplasty, by comparing this method with laboratory data, plain X-rays and 3-phase Tc-99m methylene diphosphonate (MDP) scintigraphy. Tc-99m NCol scintigraphy was found out to be a very valuable method with 100% sensitivity, 84% specificity in the diagnosis of infected prosthesis and it was superior to laboratory data, plain X-rays and 3-phase Tc-99m MDP scintigraphy, but requires to be evaluated in conjunction with plain X-rays for more information and in order to prevent false positive results.

**Key words:** Tc-99m Nanocolloid, infection, arthroplasty, hip joint

### INTRODUCTION

INTERCURRENT INFECTION of the hip joint in most patients complaining of persistent pain following total hip arthroplasty (THA), requires to be differentiated from other causes.<sup>1,2</sup> Infected THA loosening in the delayed stage, can easily be detected by clinical presentations, significant laboratory data and/or some abnormalities in plain X-rays.<sup>1</sup> Early persistent pain of the hip joint in post-operative patients with THA, however, presents a major challenge to the diagnostic acumen of the physician.

Early diagnosis of THA loosening will give us a chance to protect the bone structure by means of a good postrevision outcome.

The aim of this study is to determine the value of

technetium-99m Nanocolloid (Tc-99m NCol) scanning in patients with painful THA.

### MATERIALS AND METHODS

Thirty patients who had complained of arthropathy after THA were included in this prospective study during the period 1988-1991, and 33 painful hip prostheses were evaluated (21 women with an age range of 30 to 70 years and 9 men with an age range of 38 to 70 years). Ten patients with THA (5 women and 5 men with the age range of 30 to 70 years) without any complaints were selected at random as a control group for this study. Four of the patients in the control group had cemented total hip prostheses, while 6 of them had non-cemented total hip prostheses. In all the patients, the erythrocyte sedimentation rate (ESR), leukocyte count (WBC), C-reactive protein (C-RP) and plain X-rays were studied.

In the plain radiographs, bone structure changes were subdivided into 7 zones as Gruen described for

---

Received January 25, 1993, revision accepted April 16, 1993.

For reprint contact: İrem Bernay, M.D., Ondokuzmayıs University, Faculty of Medicine, Nuclear Medicine Department, 55139 Samsun, TURKEY.

femoral components<sup>3</sup> and into 3 zones as Charnley de Lee described for acetabular components<sup>4</sup> which are generally used to describe the exact location of the loosening in THA patients. In all cases, 3-phase Tc-99m MDP and Tc-99m NCol scintigraphies were studied and informed consent was obtained from each patient before starting this protocol study. After giving 20 mCi (740 MBq) of Tc-99m MDP intravenously, dynamic images and blood-pool images were taken from the anterior pelvis. Static images were obtained from the posterior and anterior pelvis 3–4 hours later. At least 48 hours after the Tc-99m MDP study, 10 mCi (370 MBq) of Tc-99m NCol (Solco Nuclear) which was prepared according to the manufacturer's instructions was given to the subjects intravenously and anterior pelvic images were obtained 45 minutes later.<sup>5</sup> A Siemens Scintiview II gammacamera with a low energy all purpose (LEAP) collimator was used for both studies.<sup>6</sup>

Gruen's and Charnley de Lee's zones used for the radiographical evaluation were associated with the findings of the scintigraphic images and the results were recorded separately by two observers unaware of the laboratory and radiographic data. The areas with increased uptake were thus recorded in these zones. In the radiographies, if the resorption in the bone consisted of the three described zones in the acetabular component or more than three described zones in the femoral component it was called wide

resorption and was regarded as indicating infected loosening, while resorption in only one, two or three zones was regarded as indicating either infected or noninfected loosening.

The intervals between THA and this study protocol were 8 months to 18 years (medium 11 years) in the group of patients with painful hip prosthesis and 3 months to 12 years (median 3 years) in the control group.

Of the 30 patients (33 painful hips) two patients did not accept revision for arthroplasty after this evaluation, and were therefore excluded from this study group. Another patient died of septic shock before re-operation, but proved to have an infected THA at autopsy, so she was included in this study group.

Culture and smear tests with which pathological examinations were carried out and the gross operative findings were noted. Scintigraphic, radiographic results and laboratory data expressed as percentages, were evaluated by taking pathological and gross operative findings as a gold standard.

## RESULTS

Out of the 31 painful hip joints of the 28 patients with THA, 10 hip joints (7 patients) had infected THA, so the implants were removed except for one patient who died before the removal. Twenty-one

**Table 1** Results of radiographic studies

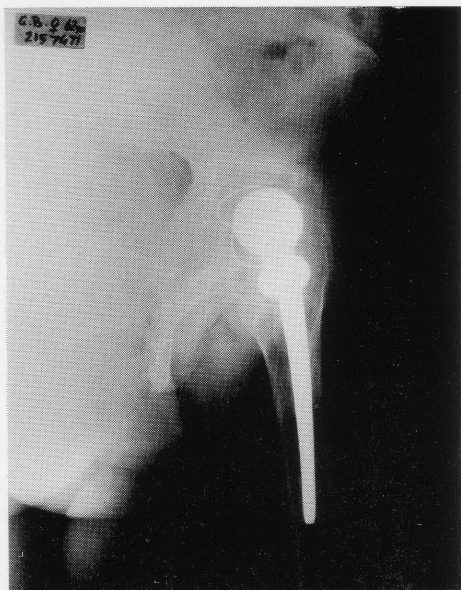
	n	Wide resorption		Resorption in only one, two or three zones		No resorption	
		n	%	n	%	n	%
Control group	10	0	0	6	60	4	40
Noninfected loosening	21	7	33	12	57	2	10
Infected loosening	10	8	80	1	10	1	10

**Table 2** Results of Tc-99m MDP scintigraphy

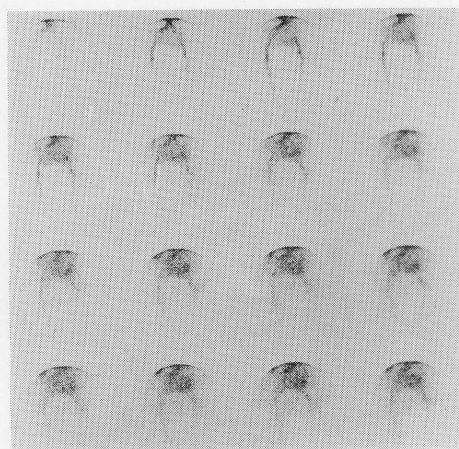
	n	No uptake		Intense uptake		Minimal uptake	
		n	%	n	%	n	%
Control group	10	5	50	3	30	2	20
Noninfected loosening	21	0	0	5	24	16	76
Infected loosening	10	1	10	8	80	1	10

**Table 3** Results of Tc-99m nanocolloid scintigraphy

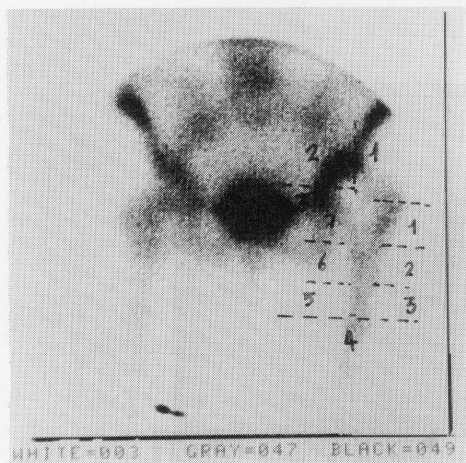
	n	Uptake (–)		Uptake (+)	
		n	%	n	%
Control group	10	8	80	2	20
Noninfected loosening	21	18	86	3	14
Infected loosening	10	0	0	10	100



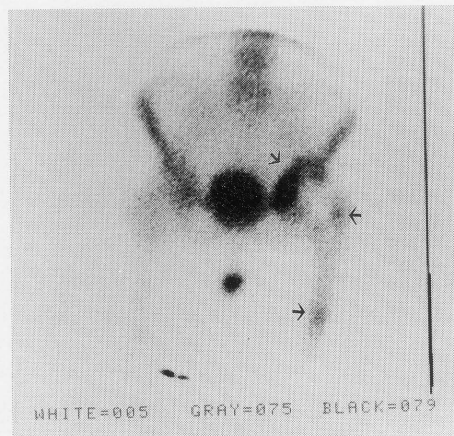
A



B



C



D

**Fig. 1** [A,B,C,D] X-ray, dynamic and static Tc-99m MDP scintigraphy and Tc-99m NCol scintigraphy of a patient with left total hip prosthesis showing infected loosening in the acetabular and femoral components (arrows). The zones described by Gruen and Charnley de Lee are seen in Fig. 1(C).

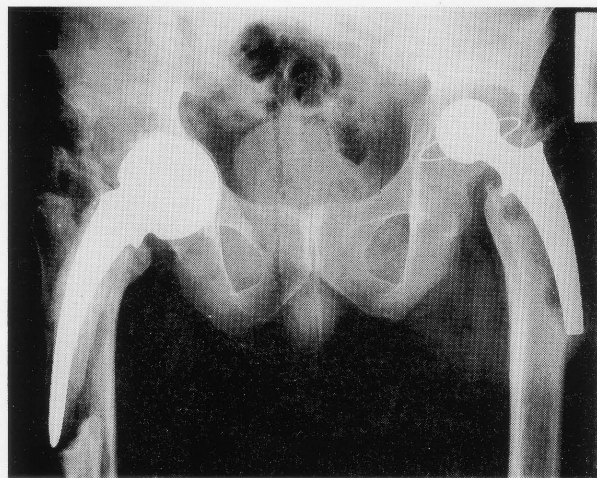
patients had noninfected loosening for which revisions were carried out. The time interval between the last operation and the present studies was 8 months to 7 years in the infected group and 5 to 18 years in the noninfected group.

In the evaluation of the laboratory tests, 41% of the 21 patients who had a noninfected loosening had abnormally high values, whereas 90% of the 7 patients with infected loosening had abnormally high values in at least one laboratory test.

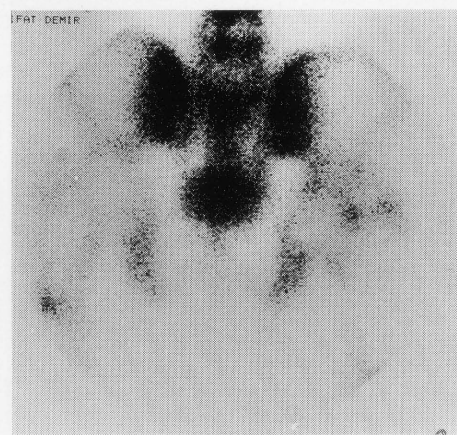
The results of the radiographic evaluations are shown in Table 1. None of the patients in the control group showed signs of wide resorption, while 7 (33%) of the 21 hip joints in the noninfected loosening

group and 8 (80%) of the 10 hip joints in the infected loosening group showed signs of wide resorption. In the 2 joints of the noninfected loosening group, the femoral stems were broken through the lateral cortex distally and another patient with noninfected loosening had a protrusion in the acetabular component of the prosthesis.

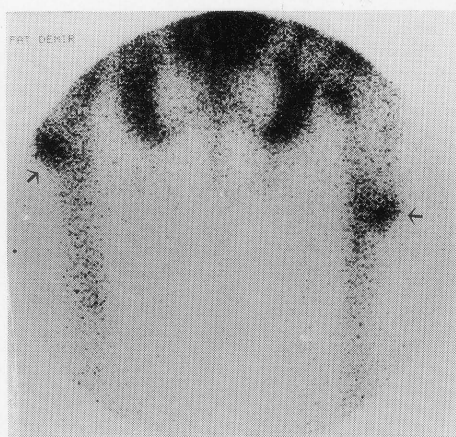Table 2 shows the results of Tc-99m MDP bone scintigraphy. In the control group there were 5 patients who were evaluated in the early 6 months after THA, out of which 3 had abnormally intense tracer accumulation along the edges of the prostheses interpreted as infection, and 2 had focal, minimal tracer accumulation interpreted as noninfective



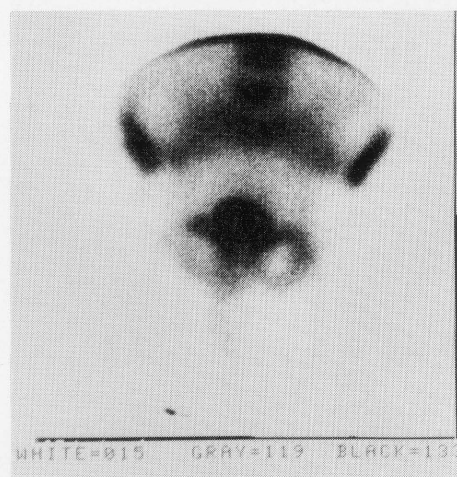
A



B



C



D

**Fig. 2 [A,B,C,D]** X-ray, static Tc-99m MDP scintigraphies and Tc-99m NCol scintigraphy of a patient with bilateral noninfected loosening of the acetabular and femoral components, accompanied by bilateral fracture (arrows) of the femoral cortex at the distal end of the stem.

loosening. In patients with noninfected loosening, 5 had intense uptake which was interpreted as infection. All patients with infected THA had intense radioactivity uptake except for 2. One of the 2 patients was interpreted as normal with no uptake and the other as having noninfected loosening with focal, minimal tracer accumulation.

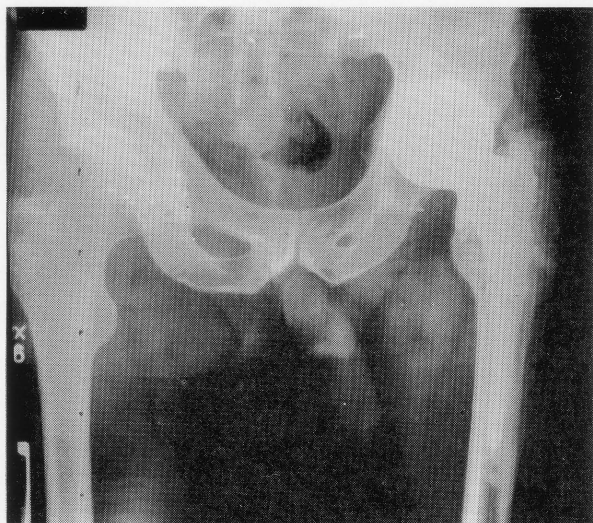Scintigraphy of 10 hip joints in the control group, 2 of which underwent the Tc-99m NCol study within 6 months after THA, showed an increased uptake (Table 3). The remaining 8 hip joints which underwent the scanning 8 months after THA, did not show any increased uptake. Of the 21 hip joints with noninfective loosening, 3 showed accumulation which was interpreted as infection with Tc-99m NCol. In two of the three, the accumulation was found to be within the zone of the broken cortex on X-rays and the other had aggressive granulomatosis as confirmed pathologically. All of the 10 hip joints

with infective THA, displayed intense Tc-99m NCol accumulation. No soft tissue accumulation of Tc-99m NCol was observed in the control or the patient group.

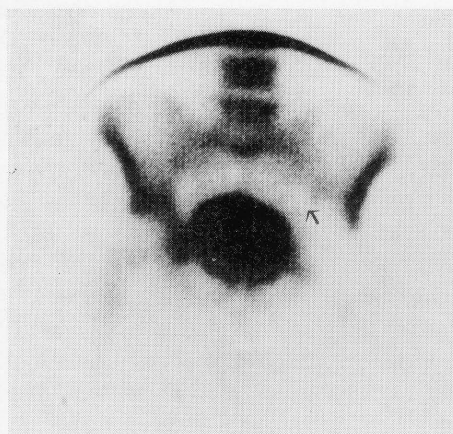
#### *Case Presentation:*

A 62-year-old woman with a left total hip prosthesis had infective loosening. The X-ray revealed loosening in the acetabular component (Fig. 1A). The 3-phase bone scintigraphy showed pathological accumulation of Tc-99m MDP on the sites of the prosthesis in dynamic and blood-pool images and increased radioactivity in the acetabular and the femoral components on static image by Tc-99m MDP as a sign of loosening (Fig. 1B, C) while there was also Tc-99m NCol accumulation in acetabular and femoral components indicating that the loosening was infective (Fig. 1D).

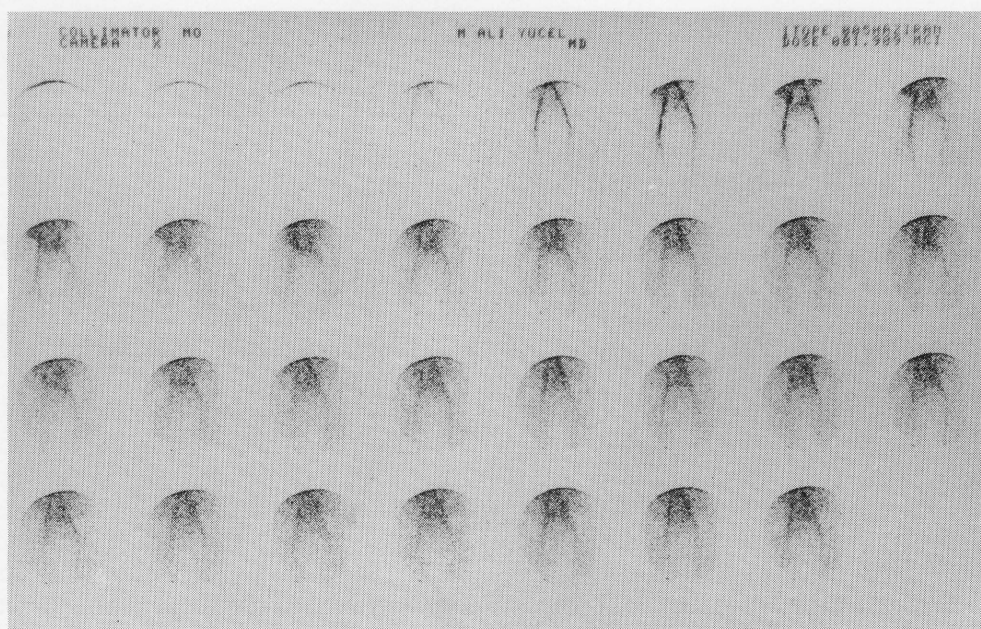




A

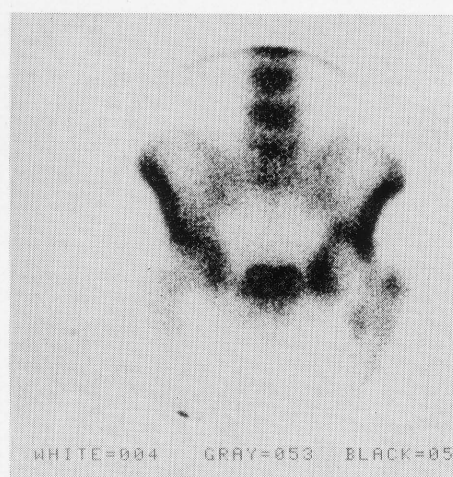


B



C

**Fig. 3 [A,B,C,D]** The X-ray, Tc-99m NCol scintigraphy, kinetic and static Tc-99m MDP images of a patient with noninfected THA loosening, accompanied by protrusion of the acetabular component of the prosthesis. In Fig. 3 (B) it is seen that there is no acetabular activity (arrow) depending on protrusion.



D

#### Case presentation:

Figure 2A shows an X-ray of a 38-year-old man with a right partial and left total hip prosthesis who visited the hospital 14 years after the operation for bilateral increasing pain in the hips. On the X-ray there was a wide radiolucency between the cement and the prosthesis indicating loosening both on the acetabular and the femoral component bilaterally, while there were bilateral fractures at the distal lateral cortex of the femoral components. Tc-99m MDP scintigraphy showed increased radioactivity depending on fractures and/or loosening and was interpreted as bilateral loosening, being unaware of the radiological findings (Fig. 2B, C). Tc-99m NCol scintigraphy revealed no pathological increased accumulation suggesting infection as seen in Figure 2D. The patient was pathologically proved to have bilateral noninfective loosening.

#### Case presentation:

A 48-year-old man with a noninfective loosening of the left partial hip prosthesis had a protrusion on the acetabular component as seen on X-ray (Fig. 3A). Tc-99m NCol scintigraphy did not indicate any acetabular activity depending on protrusion, and revealed no infection (Fig. 3B), while dynamic Tc-99m MDP scintigraphy was normal and its static image showed increased activity at the sites of the femoral and acetabular components (Fig. 3C, D).

The sensitivity and specificity of laboratory tests, radiographic studies, Tc-99m MDP scintigraphy and Tc-99m NCol scintigraphy in the diagnosis of infected THA are listed in Table 4. Sensitivity and specificity were 90 and 63% for laboratory tests, 80 and 77% for radiographic studies, and 80 and 74% for Tc-99m MDP scintigraphy and 100 and 84% for Tc-99m NCol scintigraphy, respectively.

## DISCUSSION

Although the early diagnosis of loosening provides us a chance to protect the bone structure by means of a good post revision outcome, the diagnosis of infected loosening still remains a subject of investigation.<sup>7-10</sup> There are many methods being used for the diagnosis of infected THA. The specificity and sensitivity in detecting infected orthopedic prosthesis in various scintigraphic studies in the literature are summarized in Table 5.<sup>6-8,11-16</sup>

A positive Tc-99m MDP scan indicates inflammation and possible loosening with high specificity,<sup>1</sup> but not always infection of the implant.<sup>2,7,9,17,18</sup> The results obtained with Tc-99m HMPAO labeled leukocyte studies give us almost the same results as those with In-111 labeled leukocytes.<sup>9,19</sup> Disadvan-

**Table 4** Results of our studies in the diagnosis of infected loosening

	Sensitivity %	Specificity %
Laboratory tests	90	63
Radiographic studies	80*	77
Tc-99m MDP scintigraphy	80	74
Tc-99m nanocolloid scintigraphy	100	84

\*: Sensitivity of radiographic studies was calculated by taking patients who showed wide resorption in X-rays as a positive finding as shown in Table 1.

**Table 5** Sensitivity and specificity for detecting infected orthopedic prostheses in the various scintigraphic studies

	Sensitivity %	Specificity %
Tc-99m MDP scintigraphy [1]	73	96
Ga-67 citrate scintigraphy [1]	37	100
In-111 leukocyte scintigraphy [6]	95	90
Tc-99m nanocolloid scintigraphy [5] [in chronic osteomyelitis]	88.5	93.4
In our study	100	84

tages, such as the need for a 48 to 72 hour time lapse for imaging and high radiation dosage with Ga-67 citrate scanning, such tiring and technically demanding work as labeling and obtaining leukocytes for In-111 or Tc-99m HMPAO leukocyte scanning lead us to investigate other scintigraphic techniques for practical use.<sup>2,9,10</sup>

Tc-99m NCol, a very small particle with a mean diameter of 30 nm, accumulates in such areas as bone marrow, focal infection and inflammation sites. Tc-99m NCol was therefore thought to show the infection sites.<sup>5,8</sup> The uptake of this radiopharmaceutical in sites of infection is not due to purely hyperemic conditions as suggested by studies with diffusible tracers such as Tc-99m DTPA or Tc-99m MDP. As inflammation also causes major changes at the level of terminal circulation, including severe local damage to the vascular endothelium and the basement membrane, the injected colloids extravasate into the extracellular space at the infection sites.<sup>5,20,21</sup> In the literature Tc-99m NCol has been reported to have the same accuracy as In-111 labelled leukocytes (93.4% specificity and 88.5% sensitivity) in detecting infection sites.<sup>5,12,20</sup> It provided reliable information on inflammatory and infectious bone and joint diseases in which it had 90% sensitivity and 100% specificity.<sup>21</sup> Because of its simplicity, short waiting time for imaging and a smaller radiation dose, Tc-99m NCol offers a number of advantages over Ga-67 citrate, Tc-99m HMPAO and In-111 labeled leukocytes.<sup>5,20,21</sup> The success of this radiopharmaceutical in confirming bone infection has led us to

use Tc-99m NCol for THA loosening and to compare it with other diagnostic methods.

In our study the laboratory findings proved valuable in indicating the presence of infection, but were not sufficient for diagnosis. Plain radiograms were not specific for infection, but showed such pathologies as loosening, fractures and protrusions, which helps in the interpretation of the cases.

For both Tc-99m MDP and Tc-99m NCol scintigraphies, the accumulation sites within the zones correlated well with the abnormal findings in some radiographic zones.

Tc-99m MDP scanning yielded a sensitivity of 97% and specificity of 50% for infected and non-infected loosening together, whereas; all the scans with pathological activity showed 86% of loosening and scans with normal activity showed 83% of non-loosening. Although Tc-99m MDP scintigraphy showed most of the loosening, it was not specific enough for the diagnosis of infected loosening. In the control group 3 of the 5 patients who were included in our study in their first 6 months post-operatively had pathological MDP accumulations, probably because of the surgical interruption in this area, showing that in this period there could be false positive interpretations. Tc-99m NCol scintigraphy was also false positive in 2 of the patients in the control group, possibly for the same reason. Three of the patients with noninfected loosening had pathological accumulations of Tc-99m NCol in the area of prosthesis, one due to aggressive granulomatosis and two because of fractures at the bone cortex of the distal end of the prosthesis. Although the plain radiographs of two patients with infected loosening were normal, Tc-99m NCol could successfully diagnose the condition. In our study, Tc-99m NCol scintigraphy was found to be 100% sensitive and 84% specific in the diagnosis of infected loosening. Tc-99m NCol scintigraphy for detecting infected THA turned out to be more sensitive, compared with the values reported in the literature.<sup>12</sup> Although sensitivity was higher than those which had been reported for the In-111 labeled leukocyte scintigraphy, the difference is not statistically significant.<sup>5,12,20</sup> False positive values in infected THA were 26% and 16% for Tc-99m MDP and Tc-99m NCol scintigraphy, respectively.

Another outcome of our study is that Tc-99m NCol scintigraphy showed tracer accumulation in the region of the fractures. Aggressive granulomatosis and surgical changes within 6 months after surgery also cause this radiopharmaceutical to accumulate.

It should also be stated that, normal variations in bone marrow distribution could cause false positive interpretations, although there were no such cases in our study group.

In conclusion, it is obvious that Tc-99m NCol scintigraphy is an important and reliable method for the diagnosis of infected loosening with a sensitivity of 100% and specificity of 84%, but requires to be evaluated in conjunction with plain radiographs for more information in order to prevent false positive results. Tc-99m NCol scintigraphy, worked more than six months after THA, highlights the infection sites accurately before any clinical, radiographical and laboratory signs appear.

## REFERENCES

1. Brause BD: Infected orthopedic prosthesis. Infections Associated with Indwelling Medical Devices. B&W. American Society for Microbiology, Washington DC, 1989
2. Rothman RH, Hozack WS: Complications of total hip arthroplasty: Infection. Saunders Co., pp. 38–58, 1988
3. Gruen TA, McNiece GM, Amstutz HC: "Modes of failure" of cemented stem-type femoral components: A radiographic analysis of loosening. *Clin Orthop* 141: 17–27, 1979
4. Amstutz HC, Smith RK: Total hip replacement following failed femoral hemiarthroplasty. *J Bone Jt Surg* 61a: 1161–1166, 1979
5. Schrijver MD, Streule K, Senekowitsch R, et al: Scintigraphy of inflammation with nanometer-sized colloidal tracers. *Nuc Med Commun* 8: 895–908, 1987
6. Wellman NH, Schauwecker DS, Capello WN: Evaluation of metallic osseous implants with nuclear medicine. *Sem Nucl Med* 18/2: 126–136, 1988
7. Aliabadi P, Tumeh SS, Weissman BN, et al: Cemented total hip prosthesis: Radiographic and scintigraphic evaluation. *Radiology* 173: 203–206, 1979
8. Gomez-Luzuriaga MA, Galan V, Villar JM: Scintigraphy with Tc, Ga and In in painful total hip prosthesis. *Int Orthop (SICOT)* 12: 163–167, 1988
9. McAfee JG: Editorial: What is the best method for imaging focal infections? *J Nucl Med* 31: 413–416, 1990
10. Reing CM, Richin PF, Kenmore PI: Differential bone scanning in the evaluation of a painful total joint arthroplasty. *J. Bone Jt Surg* 61A: 933–936, 1979
11. Cunningham DA: Abnormal bone marrow distribution following unsuccessful hip replacement, a potential confusion on white cell scanning. *Eur J Nuc Med* 18: 67–69, 1991
12. Gericke M, Eckart L: Möglichkeiten und Grenzen der nanokolloid-szintigraphie in der diagnostik von infektionen am bewegungsapparat. *Der Nuklearmediziner* 2, 13: 93–105, 1990
13. Guze BH, Webber MM, Hawkins RA, et al: In-111 white blood cell scans: Sensitivity, specificity, accuracy and normal patterns of distribution. *Clin Nucl Med* 15: 8–10, 1990

14. Mokassa LB, Wagner J, Verhas M: Indications des scintigraphies au Gallium-67 et aux leukocytes marqués a l'Indium-111 dans la mise au point des infections postoperatories en chirurgie osteo-articulaire. *Int Orthop (SICOT)* 14: 155-159, 1990
15. Tehranzadeh J, Gubernick I, Blaha D: Prospective study of sequential Tc-99m phosphade and Gallium imaging in painful hip prosthesis (Comparison of diagnostic modalities). *Clin Nuc Med* 13: 229-235, 1988
16. Vorne M, Soini I, Lantto T, et al: Technetium-99m HMPAO-labelled leukocytes in detection of inflammatory lesions: Comparison with Ga-67 citrate. *J Nucl Med* 30 (8): 1332-1336, 1989
17. Jensen JS, Madsen JL: Tc-99m-MDP scintigraphy not informative in painful total hip arthroplasty. *J Arthropl* 5 (suppl): 11-13, 1990
18. Williams ED, Tregonning RJ, Harley PJ: Tc-99m diphosphonate scanning as an aid to diagnosis of infection in total hip joint replacements. *Br J Radiol* 50: 562-566, 1977
19. Southee AE, Lee KJ, McLoughlin AF, et al: Tc-99m white cell scintigraphy in suspected acute infection. *Clin Nuc Med* 15: 71-75, 1990
20. Streule K, Schrijver MD, Fridrich R: Tc-99m labelled HSA-nanocolloid versus In-111 oxime labelled granulocytes in detecting skeletal septic process. *Nuc Med Commun* 9: 59-67, 1988
21. Vorne M, Lantto T, Peakkinen S, et al: Clinical comparison of Tc-99m-HMPAO labelled leucocytes and Tc-99m-Nanocolloid in the detection of inflammation. *Acta Radiologica* 39 (6): 633-637, 1989