

Thallium-201 myocardial SPECT findings at rest in sarcoidosis

Noritaka YAMAMOTO,* Kohshi GOTOH,* Yasuo YAGI,* Yasushi TERASHIMA,*
Kenshi NAGASHIMA,* Toshiyuki SAWA,* Fumiko DEGUCHI,* Masumi NAWADA,*
Haruhito TANAKA,* Tatsuo TSUKAMOTO** and Senri HIRAKAWA*

*The Second Department of Internal Medicine, Gifu University School of Medicine

**The Ibi General Hospital

In 41 patients with sarcoidosis (diagnosed according to criteria recommended by the Committee on Diffuse Pulmonary Disease, Ministry of Health and Welfare, Japan 1988), thallium-201 (^{201}Tl) myocardial SPECT was performed to investigate: (1) the ability of ^{201}Tl SPECT to detect cardiac involvement of sarcoidosis with images recorded at rest and 2 hours later, and (2) the relationships between ^{201}Tl myocardial SPECT findings and the activity of sarcoidosis or endomyocardial biopsy findings. As to the abnormal findings in ^{201}Tl myocardial SPECT, (1) a low density area was seen in 13 of 41 cases (31.7%) and non-uniform uptake was found in 17 cases (41.5%), (2) the mean washout ratio ($n=39$) was $16.5 \pm 7.4\%$, which is significantly ($p < 0.05$) lower than that found in normal subjects, $23.9 \pm 7.5\%$ ($n=10$). Of the 19 patients judged visually to be normal, 5 patients had a reduced mean washout ratio less than 12%. Thus, the incidence of abnormal findings including all types of abnormality, on ^{201}Tl myocardial SPECT in sarcoidosis was 63.4% (26/41 cases). In studying the relationship between ^{201}Tl myocardial SPECT findings and the activity of sarcoidosis (as measured by the serum ACE (angiotensin converting enzyme) or lysozyme level, or the presence of more than 30% symphyocyte fraction in BALF (broncho-alveolar lavage fluid)), 20 (80%) of 25 cases with ^{201}Tl abnormality were judged to be active sarcoidosis, while only 6 (37.5%) of 16 cases with normal findings on ^{201}Tl SPECT were judged to be active. This suggests that there is a significant ($p < 0.01$) relationship between the presence or absence of an abnormal finding on ^{201}Tl myocardial SPECT and the activity of sarcoidosis. Among 13 patients examined by endomyocardial biopsy, 10 patients had abnormal findings on ^{201}Tl myocardial SPECT and 7 of these 10 patients had no histological evidence of cardiac sarcoidosis. In all of these 7 patients, however, sarcoidosis was judged to be active. This suggest that endomyocardial biopsy is of limited value in the diagnosis of cardiac sarcoidosis.

Key words: cardiac sarcoidosis, ^{201}Tl myocardial SPECT, activity of sarcoidosis

INTRODUCTION

SARCOIDOSIS, a granulomatous disorder of unknown etiology, involves various organs, including the heart through which it has often caused death. Cardiac sarcoidosis may involve the myocardium and cause

heart failure. It may also involve the conducting system and cause arrhythmia. However, it remains difficult to make an antemortem diagnosis. Recent studies have shown thallium-201 (^{201}Tl) myocardial SPECT to be useful for diagnosing cardiac sarcoidosis at a relatively early stage.^{1,2} In the present study, ^{201}Tl myocardial SPECT was performed in patients with sarcoidosis (1) to detect cardiac involvement based on an early image obtained at rest and delayed image obtained 2 hours later, and (2) to examine the relationship between the findings on ^{201}Tl myocardial SPECT and the activity of sarcoidosis or the histopathologic findings with endomyocardial biopsy.

Received July 24, 1992, revision accepted October 19, 1992.

For reprints contact: Noritaka Yamamoto, M.D., The Second Department of Internal Medicine, Gifu University School of Medicine, 40 Tsukasamachi, Gifu City, Gifu 500, JAPAN.

SUBJECTS AND METHODS

Patients studied

Forty one cases of definite sarcoidosis were the subjects of this study. Each was diagnosed according to the criteria recommended by the Committee on Diffuse Pulmonary Disease, Ministry of Health and Welfare, Japan 1988, and underwent ^{201}Tl myocardial SPECT. There were 9 men and 32 women, aged 52.5 ± 14.7 years (mean \pm SD). The diagnostic triggered findings included ocular symptoms in 17 patients (many of whom were referred to us by ophthalmologists), arrhythmia in 4, abnormal chest X-ray findings in 6, respiratory symptoms in 6, abdominal pain in 2, subcutaneous nodes in 5 and lymphnode swelling in 1.

^{201}Tl SPECT

^{201}Tl SPECT was performed as we reported previously.³ ^{201}Tl (148 MBq) was injected intravenously while the patients were sitting at rest and imaging was performed twice (at 10 min and at 2 hours after injection; but in 2 cases delayed image was not performed). Data were collected with a rotation type γ -camera (ZLC, Siemens) equipped with a low energy high resolution collimator, and images were recorded in 18 directions (RAO 45°–LPO 45°) at intervals of 10° beginning with the anterior aspect for 50 seconds. We used a digital computer (Scintipack 2400, Shimadzu) to collect data and reconstruct images. Image reconstruction was performed without a filter, and 20% of the counts were cut off as background subtraction for visual assessment. An early image was obtained at 10 min after the administration of ^{201}Tl and delayed image was obtained at 2 hours after the administration. We visually judged the early and delayed images for perfusion abnormalities (low density, non-uniform uptake, redistribution). For more objective quantification, circumferential profile curves were constructed. From the short axis images of the left ventricle obtained at about the middle of the heart, lines were drawn radially in 36 directions at intervals of 10°, with the anterior wall represented at the center. The peak counts on individual radial lines formed the basis of the circumferential profile curves for early and delayed images. The washout ratio $\{(\text{initial count} - \text{delayed count}) / \text{initial count}\} \times 100\%$ was calculated without any background subtraction and a washout ratio curve was constructed. Parenthetically, when the initial count was greater than the delayed count, the washout ratio was considered positive. Redistribution was considered to be positive when segmental ^{201}Tl uptake (more than 3 consecutive points on the circumferential profile curve) in delayed images increased by at least 10% as compared with the ^{201}Tl

uptake in early images. The mean of 36 washout ratios in one short axis image was called the mean washout ratio for the patient. The mean washout ratio obtained from 10 normal subjects in our laboratory was $23.3 \pm 7.5\%$. Any mean washout ratio less than 12.0% (mean -1.5 SD) was considered to be an abnormal ^{201}Tl finding. We looked for the ^{201}Tl myocardial SPECT findings 1) by visual assessment, on low density or non-uniform uptake, 2) on the washout ratio curve. The electrocardiogram was examined for the conduction block, ST-T abnormality or hypertrophy of the left ventricle.

Activity of sarcoidosis

We judged the activity of sarcoidosis by 1) the rise in the serum level of angiotensin converting enzyme (ACE), 2) the rise in the serum level of lysozyme and 3) a lymphocyte differential count fraction exceeding 30% in bronchoalveolar lavage fluid (BALF). Since the BALF lymphocyte differential count fraction tends to be higher in smokers,⁴ analysis of the BALF study was limited to 16 non-smokers in the present study.

Endomyocardial biopsy

An endomyocardial biopsy was performed in 13 patients. With the endomyocardial biotome, 1 to 3 specimens were obtained from the endocardial surface of the left ventricle. From each specimen, 3 sections were prepared, stained with hematoxyline and eosin and examined under a microscope (400 \times). The entire area of each myocardial specimen was examined carefully. The histological diagnosis for cardiac sarcoidosis was done only in the presence of a noncaseous granulomatous lesion. Each of the 13 patients who underwent endomyocardial biopsy was examined for the aforementioned parameters of disease activity, including ECG findings.

Statistical analysis

All data are expressed as the mean \pm SD, and the chisquare test was used to compare measurements. A p value < 0.05 was considered statistically significant.

CASE REPORT

A 22 year-old woman with uveitis and biopsy-proven dermal sarcoidosis visited our Department of Medicine. The ECG showed poor R wave progression in precordial leads V_2 and V_3 . The chest X-ray showed bilateral hilar lymphadenopathy (BHL). An endomyocardial biopsy did not reveal any non-caseous granulomatous lesion. After the administration of corticosteroid, the poor R wave progression improved. The low density of the anterior wall

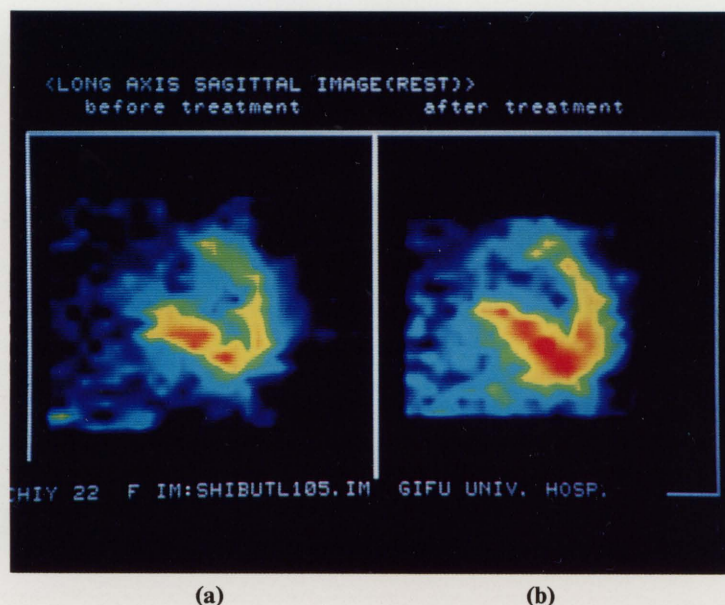


Fig. 1 Vertical long axis image of ^{201}Tl myocardial SPECT before (a) and after (b) steroid therapy.

and the diffuse non-uniform uptake on the vertical long axis ^{201}Tl myocardial SPECT images also improved after the treatment (Fig. 1). The washout ratio curve before the treatment showed large fluctuations; the washout ratio was even negative in parts of the anterior wall. After administering prednisolone (30 mg/day) for 2 months, these local variations in washout diminished and there remained no area with a negative washout ratio (Fig. 2).

RESULTS

(I) ^{201}Tl myocardial SPECT findings

The abnormal findings on ^{201}Tl myocardial SPECT included (1) an area of low density in 13 of 41 patients (31.7%), and non-uniform uptake in 17 patients (41.5%) by visual evaluation, and (2) a mean washout ratio of $16.5 \pm 7.4\%$ ($n=39$), which was significantly ($p<0.05$) lower than that in the normal group (Table 1). There were 5 subjects (12.0%) who had only a decreased mean washout ratio (mean -1.5 SD or less). Thus, an abnormal finding on ^{201}Tl myocardial SPECT was observed in a total of 26 subjects (63.4%), consisting of 4 subjects with only a low

density area, 8 subjects with only non-uniform uptake, and 9 subjects with both abnormalities and 5 subjects with a decreased washout ratio. By visual evaluation, redistribution was observed in the low density area on an early image of 12 of the 13 cases, and in the non-uniform uptake area in 6 of 7 cases (on one case with non-uniform uptake delayed image was not performed). The mean washout ratio showed no significant difference among the cases of low density, only non-uniform uptake and normal perfusion.

(II) Relation between abnormal findings on ECG and ^{201}Tl myocardial SPECT (Table 2)

All of the 6 patients with A-V block and 2 with hemiblock were associated with abnormal findings on ^{201}Tl SPECT, while 3 of 4 patients with ST-T change and normal coronary angiogram had no abnormal ^{201}Tl SPECT finding. In 1 of 4 patients with left ventricular hypertrophy (LVH), an abnormal finding on ^{201}Tl SPECT was observed. Sixteen of our 25 subjects with a normal ECG had abnormal ^{201}Tl SPECT findings. Solitary or scattered sarcoidosis lesions may represent a normal ECG.

Table 1 Findings on ^{201}Tl myocardial SPECT in sarcoidosis

Low density	13/41 (31.7%)
Non-uniform uptake	17/41 (41.5%)
Mean washout Ratio	16.5 ± 7.4 (mean \pm SD, $n=39$) v.s. Normal ($p<0.05$) [Normal 23.3 ± 7.5 , $n=10$]

Table 2 Relation between abnormal findings on ECG and ^{201}Tl myocardial SPECT

Tl abnormality	(+)	(-)
A-V block (6 cases)	6	0
Hemiblock (2 cases)	2	0
ST-T change (4 cases)	1	3
LVH (4 cases)	1	3
WNL (25 cases)	16	9

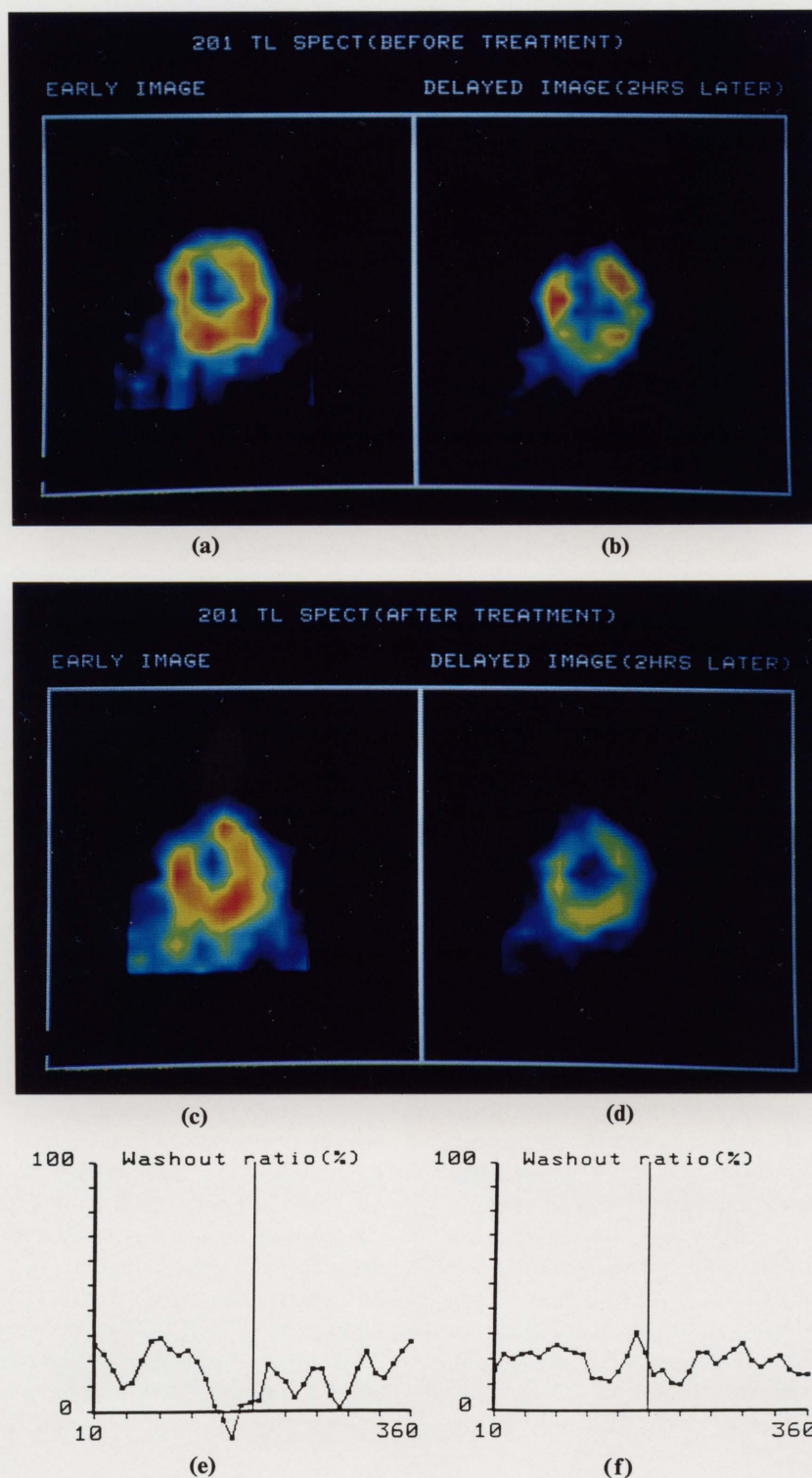


Fig. 2 ^{201}Tl myocardial SPECT short axis image and washout ratio curves before and after the steroid therapy. Early short axis image before the steroid therapy (a) indicates a low density area in the anterior wall, and the delayed short axis image before the therapy (b) shows a redistribution in that area. The washout ratio curve (e), calculated from the value on the images (a) and (b), represents a low washout ratio in that area. After the steroid therapy, however, the anterior wall improved in ^{201}Tl uptake in early short axis image (c) and the redistribution was not prominent in the delayed image (d). Washout ratio curve after the steroid therapy (f) indicates the improvement of the washout ratio in that area.

Table 3 Relation between findings on ^{201}Tl myocardial SPECT and activity of sarcoidosis

	Activity (+)	Activity (-)
Tl abnormality (+)	20	5
Tl abnormality (-)	6	10

$p < 0.01$ in the χ^2 test

Table 4 Relation between findings on ^{201}Tl myocardial SPECT and endomyocardial biopsy

	Endomyocardial biopsy	
	Positive	Negative
Tl abnormality (+)	3	7
Tl abnormality (-)	0	3

N.S. in the χ^2 test

(III) Sarcoidosis activity

In 20 (80%) of 25 patients with ^{201}Tl perfusion abnormality, sarcoidosis was judged to be active at the time of examination. On the other hand, only 6 (37.5%) of 16 cases without a ^{201}Tl perfusion abnormality showed signs of sarcoidosis activity. The presence of an abnormality on ^{201}Tl myocardial SPECT significantly correlated with the sarcoidosis activity ($p < 0.01$ in the χ^2 test) (Table 3). Individual parameters for sarcoidosis activity are described as follows.

(a) Serum ACE level

An increased serum angiotensin converting enzyme (ACE) concentration (21.4 IU/L or more) unrelated ($p > 0.05$) to abnormal ^{201}Tl SPECT findings in 40 subjects. Only in 9 (37.5%) of 24 patients with ^{201}Tl perfusion abnormality, ACE concentration was increased and in 11 (68.8%) of 16 patients with normal ^{201}Tl perfusion, ACE concentration was normal.

(b) Serum lysozyme level

In 19 (86.4%) of 22 patients with ^{201}Tl perfusion abnormality, serum lysozyme concentration was increased (8.6 $\mu\text{g}/\text{ml}$ or more) and in 4 (44.4%) of 9 patients with normal ^{201}Tl perfusion, lysozyme concentration was normal. This relationship was proved not significant in the χ^2 test ($p > 0.05$).

(c) Lymphocytes in broncho-alveolar lavage fluid (BALF)

In the patients with abnormal ^{201}Tl SPECT findings ($n=8$), the total cell count in BALF was 2.7 ± 1.3 ($\times 10^5/\text{ml}$) (mean \pm SD) and in the patients without abnormal ^{201}Tl SPECT findings ($n=8$), it was 3.2 ± 4.0 , with no significant difference. The CD4/CD8 ratio was 5.6 ± 1.6 in the presence of abnormal SPECT findings and 4.0 ± 1.4 in the absence of abnormal SPECT findings, with no significant difference. The lymphocyte differential count was 80.8 ± 14.4 (%) in the presence of abnormal SPECT findings

whereas it was 33.5 ± 26.8 in the absence of abnormal SPECT findings—this difference was significant ($p < 0.01$).

(IV) Endomyocardial biopsy

The 13 patients who underwent endomyocardial biopsy were examined for any relation between ^{201}Tl SPECT findings and histological findings. In only 3 of 10 patients with abnormal ^{201}Tl SPECT findings, endomyocardial biopsy revealed granulomatous lesions, although all of these 10 patients were judged to be active. These 3 cases had a severe scattered low density area. The other 3 patients with normal ^{201}Tl SPECT findings were negative histologically and negative as to sarcoidosis activity (Table 4). No significant correlation was found between abnormal ^{201}Tl findings and histological findings ($p > 0.1$).

DISCUSSION

Diagnosis of cardiac sarcoidosis

Cardiac involvement has been considered to be the most common cause of death in sarcoidosis.⁵ Cardiac sarcoidosis that culminates in death is called fatal myocardial sarcoidosis (FMS).⁶ The rate of correct antemortem diagnosis for FMS is as low as 17% in Japan⁷ and 27% in other countries.⁸ It was also reported that clinical signs of cardiac involvement may be detected in less than 5% of patients with sarcoidosis.⁹ All of these findings attest to the difficulty in making an antemortem diagnosis of cardiac sarcoidosis at an early stage. In FMS death is sudden, preceded by heart failure, which occurs in 36% according to Sekiguchi, et al.¹⁰ or 67% according to Roberts, et al.⁸ With recent developments in pacemaker technology, death due to heart failure has become prominent, a situation which increases the importance of making an antemortem diagnosis of cardiac sarcoidosis. Silverman, et al.¹¹ and Tachibana, et al.¹² found evidence of cardiac involvement in 25% and 52.1%, respectively, of autopsied patients with sarcoidosis, indicating that cardiac involvement is by no means infrequent in patients with sarcoidosis. To detect cardiac involvement in sarcoidosis, ^{201}Tl myocardial scintigraphy is being widely used. The myocardial uptake depends on regional perfusion and extraction. The extraction may be an active process requiring an Na, K-ATPase enzyme system, or may be a passive transport according to the electropotential gradient across the cellular membrane.¹³ Kinney, et al.¹⁴ found perfusion defects in ^{201}Tl myocardial scintigrams obtained at rest in 32% of patients with sarcoidosis. In the present study, we thought that abnormality on ^{201}Tl myocardial scintigraphy in patients with sarcoidosis could be equated with

cardiac involvement. A low density on ^{201}Tl SPECT was found by visual assessment in 13 of 41 subjects (31.7%)—a prevalence similar to that reported by Kinney et al. Non-uniformity of ^{201}Tl uptake was found in 17 of 41 subjects (41.5%). When the wash-out ratio abnormality was also considered, the prevalence in subjects with any one of the three findings suggesting sarcoidosis increased to 63.4%, suggesting that the delayed image was important. Haywood, et al.¹⁵ remarked that the defects in the ^{201}Tl scintigram in sarcoidosis decreased in size during thallium stress imaging, a finding opposite that usually seen in myocardial ischemia. In the present study, where we compared the early image to the delayed image at rest, redistribution occurred in 12 of 13 cases with low density, and in 6 of 7 cases with non-uniform uptake. From these findings one may conclude that cardiac involvement in sarcoidosis is due not only to granulomatous lesions but also to microangiopathy (which may be the main lesion) and that the non-uniformity of ^{201}Tl uptake may represent patchy defects due to vascular lesions.¹⁶ The histological alterations responsible for abnormal ^{201}Tl myocardial SPECT findings may include infiltration of lymphocytes to the myocardium, fibrous degeneration of the myocardium and vascular lesions.^{6,11}

Activity of sarcoidosis and abnormal ^{201}Tl myocardial SPECT findings

As the indices of activity of sarcoidosis, Fanburg, et al.¹⁷ listed alterations in (1) the percentage of lymphocytes in BALF, (2) ^{67}Ga scintigraphy, (3) serum enzyme activities (ACE, lysozyme etc.) and (4) clearance of $^{99\text{m}}\text{Tc}$ -DTPA by the lungs. ACE is produced by endothelial cells and in sarcoidosis the serum ACE level approximately represents the total body granuloma activity. The ACE level is thought to have a sensitivity of 84% and a specificity of 95%, while for lysozyme, the sensitivity is 60% and the specificity is 76% for active sarcoidosis. Therefore, the serum ACE level was found to be revealed useful as an index of disease activity.¹⁸ It is also reported that the lysozyme level, which is thought to represent the activity of giant cells, correlates highly with the efficacy of the treatment. However, the lysozyme level correlates poorly with the serum ACE level or lymphocyte count in BALF.¹⁹ Uptake of ^{67}Ga is considered to be the most useful parameter of activity.²⁰ In the present study, an increase in any one on the 3 parameters—the serum ACE level, serum lysozyme level or percent lymphocyte count in BALF—was considered to indicate sarcoidosis activity. In patients who were judged to be active in this manner, an abnormal ^{201}Tl myocardial SPECT finding was frequently found (Table 3). One may speculate that since sarcoidosis is a systemic disease,

it is possible for a patient with active sarcoidosis to have cardiac involvement. ^{201}Tl myocardial scintigraphy will be useful in detecting cardiac involvement in such a patient. Of 5 subjects with abnormal ^{201}Tl myocardial SPECT findings who were judged inactive, 3 had only a low washout ratio without any visual perfusion abnormality, while the remaining 2 subjects had an extensive defect. These 2 patients were considered to have severe cardiac involvement, such as complete myocardial fibrosis.

Endomyocardial biopsy and abnormal ^{201}Tl myocardial SPECT findings

Endomyocardial biopsy is a useful means of establishing a diagnosis of cardiac sarcoidosis when the biopsy specimen is histologically positive. Endomyocardial biopsy, however, is often insensitive when compared to autopsy findings.^{21,22} In the present study, histological findings of sarcoidosis were confirmed only in a few patients who underwent endomyocardial biopsy and who had abnormal ^{201}Tl myocardial SPECT findings. This suggests that the endomyocardial biopsy does not necessarily cover the entire myocardium or that the diagnosis of sarcoidosis should be based not only on finding granulomatous lesions or fibrotic lesions but also on finding microangiopathy or cellular infiltration which may otherwise indicate a nonspecific change. Alternatively, a ^{201}Tl myocardial SPECT abnormality may represent some alteration which cannot be seen histologically. However, this possibility is remote in view of the fact that there are many reports of cardiac sarcoidosis that were not diagnosed by endomyocardial biopsy but were confirmed on autopsy.^{10,23} Thus it is probable that the endomyocardial biopsy is prone to sampling inadequacy and the diagnostic sensitivity of endomyocardial biopsy must be scrutinized more closely. As long as the endomyocardial bioprobe is used, an endomyocardial biopsy can reach, at most, to a depth of only 2–3 mm below the endocardial surface. It is known that patients with abnormal ^{201}Tl SPECT findings have a better prognosis than patients in whom the diagnosis of cardiac sarcoidosis was confirmed by endomyocardial biopsy. This fact suggests that abnormal ^{201}Tl myocardial scintigraphic findings may, at times, represent nonspecific local alterations and not a granulomatous lesion or a derangement of the microcirculation in the myocardium.²⁴ In the present study, abnormal ^{201}Tl SPECT findings were often associated with evidence of sarcoidosis activity. This suggests that, although abnormal ^{201}Tl SPECT findings may not be ascribed entirely to fibrosis or a granuloma, ^{201}Tl scintigraphy is sensitive for processes which may be associated with sarcoidosis. Therefore, it is important to screen patients with

sarcoidosis for cardiac involvement by ^{201}Tl myocardial SPECT so that the patient may be followed up closely for any premonitory symptoms of lethal arrhythmia.

REFERENCES

1. Bulkley BH, Rouleau JR, Whitaker JQ, et al: The use of ^{201}Tl for myocardial perfusion imaging in sarcoid heart disease. *Chest* 72: 27-32, 1977
2. Sharma OP, Siegel M, Haywood LJ: Role of Thallium-201 scanning in the management of myocardial sarcoidosis. *Arch Monaldi* 36: 79-86, 1981
3. Tsukamoto T, Gotoh K, Yagi Y, et al: Usefulness of resting Thallium-201 delayed imaging for detecting myocardial viability in patients with previous myocardial infarction. *Ann Nucl Med* 7 (2): 79-86, 1993
4. Chretien J, Venet A, Danel C, et al: Bronchoalveolar lavage in sarcoidosis. *Respiration* 48: 222-230, 1985
5. Fleming HA, Bailey SM: The prognosis of sarcoid heart disease in the United Kingdom. *Ann NY Acad Sci* 465: 543-550, 1986
6. Matsui Y, Iwai K, Tachibana T, et al: Clinicopathological study on fatal myocardial sarcoidosis. *Ann NY Acad Sci* 278: 455-469, 1975
7. Ogawa H, Kinoshita N, Omori F, et al: A case of fetal myocardial sarcoidosis. *Jap J Med* 73: 1656-1664, 1984 (in Japanese)
8. Roberts WC, McAllister HA, Ferrans VJ: Sarcoidosis of the heart. A clinicopathologic study of 35 necropsy patients (group 1) and review of 78 previously described necropsy patients (group 2). *Am J Med* 63: 86-108, 1977
9. Wynne J, Braunward E: The cardiomyopathies and myocarditis. Braunward E, eds. *Heart disease; A textbook of cardiovascular medicine, 2nd ed*, Saunders Philadelphia, pp. 1426-1427, 1984
10. Sekiguchi M, Nomao Y, Imai M, et al: Clinical and histopathological profile of sarcoidosis of the heart and acute idiopathic myocarditis. Concepts through a study employing endomyocardial biopsy. I. Sarcoidosis. *Jpn Circ J* 44: 249-263, 1980
11. Silverman KJ, Hutchins GM, Bulkley BH: Cardiac sarcoid. A clinicopathologic study of 84 unselected patients with systemic sarcoidosis. *Circulation* 58: 1204-1211, 1978
12. Tachibana A, Iwai K, Matsui Y, et al: Cause of death in Japanese sarcoidosis. *Committee report of Japanese sarcoidosis research report*: 76, 1979 (in Japanese)
13. Abdulmassih S, Iskandrian MD, A-Hamid Hakki MD: Thallium-201 myocardial Scintigraphy. *Am Heart J* 109: 113-129, 1985
14. Kinney EL, Jackson GL, Reeves WC, et al: Thallium-scan myocardial defect and echocardiographic abnormalities in patients with sarcoidosis without clinical cardiac dysfunction. An analysis of 44 patients. *Am J Med* 68: 497-503, 1980
15. Haywood LJ, Sharma OP, Siegel ME, et al: Detection of myocardial sarcoidosis by Thallium 201 imaging. *J Nat Med Assoc* 74: 959-964, 1982
16. Mikami R, Sekiguchi M, Ryuzin Y, et al: Changes in the peripheral vasculature of various organs in patients with sarcoidosis-Possible role of microangiopathy. *Heart & Vessels* 2: 129-139, 1986
17. Fanburg BL, Pitt EA: Sarcoidosis. Murray JF & Nadel JA, eds. *Textbook of respiratory Medicine*, Saunders Philadelphia, pp. 1486-1500, 1988
18. Baarsma GS, La-Hay E, Glasius E, et al: The predictive value of serum angiotensin converting enzyme and lysozyme levels in the diagnosis of ocular sarcoidosis. *Am J Ophthalmol* 104 (3): 211-217, 1987
19. Nakata Y, Ejiri T, Kishi T, et al: Alveolar lymphocyte proliferation induced by *Propionibacterium acnes* in sarcoidosis patients. *Acta Med Okayama* 40 (5): 257-264, 1986
20. Alberts C, Schoot JB, Broen AS: ^{67}Ga scintigraphy as an indicator of disease activity in pulmonary sarcoidosis. *Eur J Nucl Med* 6: 205-212, 1981
21. Ratner SJ, Fenoglio JJ, Ursell PC, et al: Utility of endomyocardial biopsy in the diagnosis of cardiac sarcoidosis. *Chest* 90: 528-533, 1986
22. Lemery R, McGoon MD, Edwards WD: Cardiac sarcoidosis: A potentially treatable form of myocarditis. *Myo Clin Proc* 60: 549-554, 1985
23. Fujita M, Sasayama S, Hoshino T, et al: Myocardial sarcoidosis with congestive heart failure. *Jpn Circ J* 51: 436-438, 1987
24. Kinney EL, Caldwell JW: Do thallium myocardial perfusion scan abnormalities predict survival in sarcoid patients without cardiac symptoms? *Angiology* 41 (7): 573-576, 1990