

Accumulation of ^{99m}Tc -HM-PAO in photon deficient areas in bone scan of bone metastasis from hepatocellular carcinoma

Nobuaki OTSUKA,* Masao FUKUNAGA,* Koichi MORITA,* Shimato ONO,*
Kiyohisa NAGAI,* Tatsushi TOMOMITSU,* Shinichi YANAGIMOTO,*
Hiroaki MIMURA,* Shinichiro YAMAMOTO** and Yutaka HIRANO**

*Departments of *Nuclear Medicine and **Gastroenterology, Kawasaki Medical School, Okayama, Japan*

To evaluate bone metastasis from hepatocellular carcinoma (HCC), both bone and ^{99m}Tc -HM-PAO scintigraphies were performed in six patients with clinically and pathologically confirmed HCC. Two patients had a bone scintigram which revealed abnormal accumulation in the skull base, pelvic bone and thoracic spine. The ^{99m}Tc -HM-PAO scans of both these patients also showed abnormal accumulation in the same sites. The bone scintigrams in one patient revealed not only abnormal accumulation in the ribs but also photon deficient areas in the sternum, thoracic spine and femur, while ^{99m}Tc -HM-PAO scans showed abnormal accumulation in all these sites. In three patients, bone scintigraphy revealed photon deficient areas in the ribs, pelvic bone and femur, and their ^{99m}Tc -HM-PAO scintigrams showed abnormal accumulation in the same sites. Thus, it was shown that, in the detection of bone metastasis from HCC by means of bone scintigraphy, it was necessary to pay attention to hot and cold lesions, and that a combination study with ^{99m}Tc -phosphorous compounds and ^{99m}Tc -HM-PAO was useful in evaluating these lesions.

Key words: hepatocellular carcinoma, bone metastasis, bone scintigraphy, ^{99m}Tc -HM-PAO scintigraphy

INTRODUCTION

HEPATOCELLULAR CARCINOMA (HCC) often metastasizes to the bone. It is well known that bone scintigraphy with ^{99m}Tc -phosphorous compounds is an excellent method for the detection of bone metastasis.¹⁻³ However, since the accumulation of ^{99m}Tc -phosphorous compounds in bone lesions does not directly indicate the presence of tumor cells but rather accelerated bone formation following osteolysis,^{4,5} bone scintigraphy frequently presents photon deficient findings when tumor growth is not accompanied by bone formation.⁶ Although photon deficient findings of bone metastases on bone scintigraphy have been reported previously in differenti-

ated thyroid cancer⁷ and myeloma,⁸ such findings have not been emphasized in HCC.⁹ ^{99m}Tc -hexamethylpropyleneamine oxime (^{99m}Tc -HM-PAO), which is mainly used for the evaluation of the cerebral blood flow, has also been reported to be useful in detecting bone metastasis.¹⁰ However, such "filling-in" of photon deficient areas in the skeletal metastatic sites with ^{99m}Tc -HM-PAO has not been described reported in the case of HCC.

In the present study, the usefulness of bone and ^{99m}Tc -HM-PAO scintigraphy for the detection of bone metastasis from HCC has been evaluated.

MATERIALS AND METHODS

We studied six patients (age range 50-69) with histologically proven HCC. Bone scintigraphy was performed 3 hr after the administration of 740 MBq (20 mCi) ^{99m}Tc -HMDP. Within one week of the bone scan, planar images obtained with a conventional gamma camera and, in some cases, single

Received February 7, 1992, revision accepted April 8, 1992.

For reprints contact: Nobuaki Otsuka, M.D., Department of Nuclear Medicine, Kawasaki Medical School, 577 Matsushima, Kurashiki, Okayama 701-01, JAPAN.

photon emission computed tomographic images with a rotating gamma camera were scintigraphied 60 min after intravenous administration of 370 MBq (10 mCi) ^{99m}Tc -HM-PAO.

RESULTS

The results of bone and ^{99m}Tc -HM-PAO scans of the six patients are shown in Table 1.

Two patients (cases 1 and 3) had bone scintigrams which revealed abnormal accumulation in the skull base, pelvic bone and thoracic spine. The ^{99m}Tc -HM-PAO scans in both these patients showed abnormal accumulation in the same sites. The bone scintigram of one patient (case 2) revealed not only abnormal accumulation in the ribs but also photon deficient areas in the sternum, thoracic spine and femur, while ^{99m}Tc -HM-PAO showed abnormal accumulation in all these sites. In three patients (cases 4–6), bone scintigraphy revealed photon deficient areas in the ribs, pelvic bone and femur, and their ^{99m}Tc -HM-PAO scintigrams showed abnormal accumulation in the same sites. In three cases, bone metastasis was diagnosed histologically, while in the other four cases it was diagnosed from abnormalities on X-rays and computed tomography.

CASE REPORTS

Case 2

A 62-year-old man was admitted to our hospital with lumbago and anterior chest pain. A chest X-ray film revealed a mass lesion in his left upper lung field (Fig. 1a). Bone scintigraphy showed a cold lesion in the sternum (Fig. 1b). ^{99m}Tc -HM-PAO scintigraphy showed increased accumulation of radioactivity in the sternum (Fig. 1c, d). Six months after admission, he died of gastrointestinal bleeding and liver dysfunction. Findings at autopsy revealed

metastatic lesions of the left first and second ribs and the sternum from well-differentiated HCC.

Case 3

A 59-year-old man has been treated with TAE for HCC. Bone scintigraphy showed a small hot spot in the lower thoracic spine (Fig. 2a). ^{99m}Tc -HM-PAO scintigraphy showed increased accumulation of radioactivity in the thoracic spine (Fig. 2b) and computed tomography (CT) showed slight osteolytic change in the same site (Fig. 2c). Six months after the scintigraphy, he died of the liver dysfunction. Findings at autopsy revealed metastatic lesion of the thoracic spine from HCC.

Case 4

A 55-year-old man was treated with TAE for HCC. Six months after this treatment, as the patient complained of left rib pain, bone scintigraphy was performed. The bone scan disclosed a defect in the 8th left rib (Fig. 3a). On ^{99m}Tc -HM-PAO scintigraphy, increased radioactivity was found in the left 8th rib (Fig. 3b). CT showed osteolytic change in the 8th left rib (Fig. 3c).

Case 5

A 69-year-old man was admitted to our hospital for treatment with TAE for HCC. The patient complained of right rib pain. On bone roentgenogram osteolytic change in the right 10th rib was shown. Bone scintigraphy showed a photon deficient area in the rib (arrow), and a doughnut sign in the left ilium (Fig. 4a). On ^{99m}Tc -HM-PAO scintigraphy, increased radioactivity was found in the right 10th rib and left ilium (Fig. 4b). However, no accumulation was noted in the lower spine. Bone roentgenogram showed senile change in the 5th lumbar vertebra. CT showed liver mass and osteolytic change in the right rib (Fig. 4c).

Table 1 Cases and scintigraphic findings

Case No.	Age	Sex	Metastatic lesions	Scintigram	
				^{99m}Tc -HMDP	^{99m}Tc -HM-PAO
1	50	M	*skull base	Hot	(+)
			pelvic bone (lt. ilium, rt. ischium)	Hot	(+)
2	62	M	*lt. 1st & 2nd rib	Hot	(+)
			*sternum	Photon deficient	(+)
			*lower thoracic spine	Photon deficient	(+)
			*lt. femur	Photon deficient	(+)
3	59	M	*thoracic spine	Small hot spot	(+)
4	55	M	lt. rib	Photon deficient	(+)
5	69	M	rt. rib	Photon deficient	(+)
			lt. pelvic bone (ilium)	Photon deficient	(+)
6	56	M	lt. femur	Photon deficient	(+)

*: Histologically defined

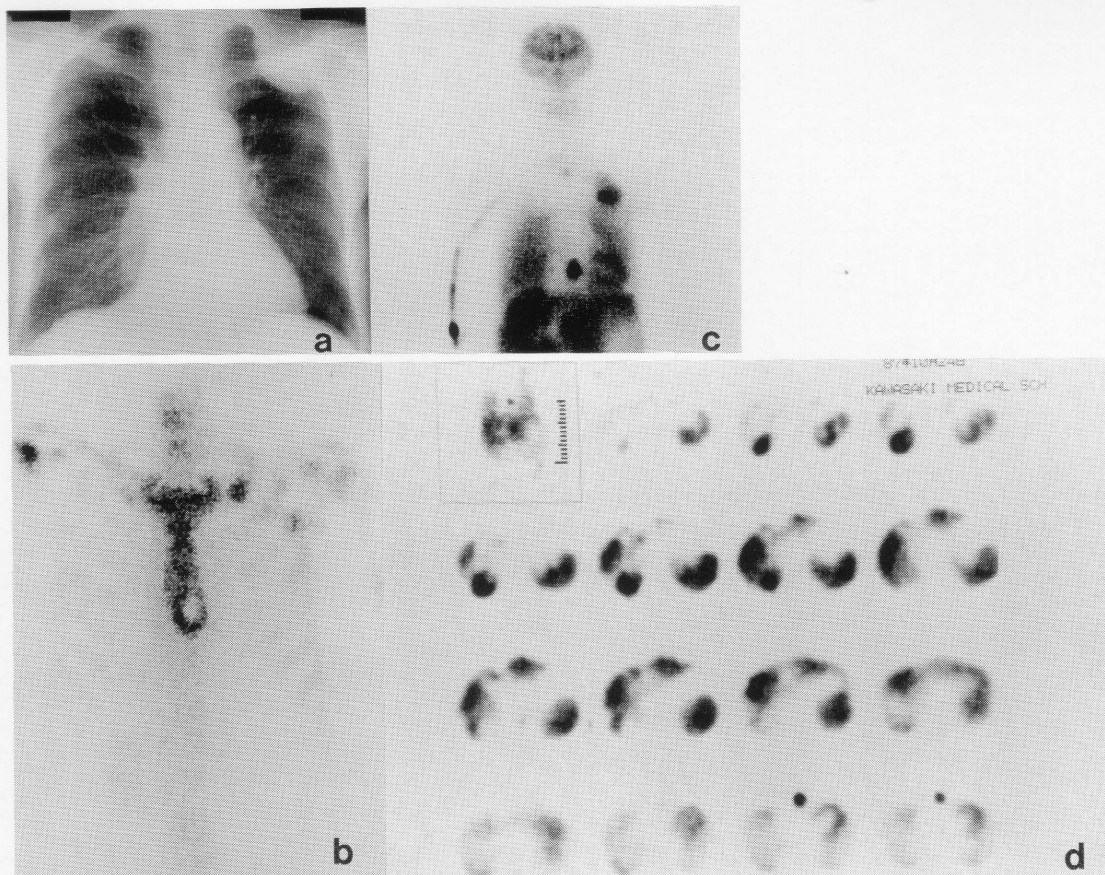


Fig. 1 a Chest x-p: An abnormal shadow is noted in the left upper lung. b Bone scintigraphy: A photon deficient area is noted in the sternum. c ^{99m}Tc -HM-PAO scintigraphy (planar image). d ^{99m}Tc -HM-PAO scintigraphy (SPECT): Increased activity is noted in the sternum.

DISCUSSION

Metastases of HCC occur in approximately half of the patients. The most common site of hematogenous spread is the lung, followed by bone. Scintigraphy with ^{67}Ga and ^{99m}Tc -PMT (^{99m}Tc -Sn-N-pyridoxyl-5-methyltryptophan) is widely used in the imaging of HCC and its metastatic lesions.

Imaging of metastatic bone tumor by bone scintigraphy greatly facilitates its early diagnosis, as compared with bone radiography,¹⁻³ which generally required 30–50% decalcification¹² prior to the recognition of bone destruction by bone X-ray. However, ^{99m}Tc -phosphorous compounds accumulated specifically not in malignant bone tumors but in areas of rapid bone renewal, which reflected the process of repairing bone destruction due directly to a tumor or indirectly to the activation of osteoclasts.^{4,5} When bone formation, resulting from osteosclerotic changes in a metastatic lesion on skeletal radiography, occurs there is strong accumulation of the radionuclide. However, when there occurs minimal bone formation in malignant tumors

such as HCC, little accumulation is usually evident on bone scintigraphy, even if tumor cells are present. This results in an appearance of osteolytic change on skeletal radiography. Thus, normal or photon deficient images are often obtained on bone scans. Therefore, bone scintigraphy alone is not a reliable technique for the detection and diagnosis of metastasis. In 1987, Hammersley et al reported that Tc- 99m -HM-PAO could be used for the estimation of tumor blood flow in experimental models.¹³ Recently, it has been reported that Tc- 99m -HM-PAO is taken up by various tumors.¹⁴ To confirm whether this scintigraphy is useful for the detection of HCC or not, ^{99m}Tc -HM-PAO scintigraphy was performed in six cases with HCC. Increased accumulation of the radioisotope was shown in all the bone metastatic lesions. Although increased uptake was observed in four sites, and photon deficient areas were noted in seven sites in the metastatic lesions on bone scintigraphy, the increased uptake of ^{99m}Tc -HMDP in benign senile bone lesions made it difficult to differentiate them from metastatic lesions. On ^{99m}Tc -HM-PAO scintigraphy, the bone

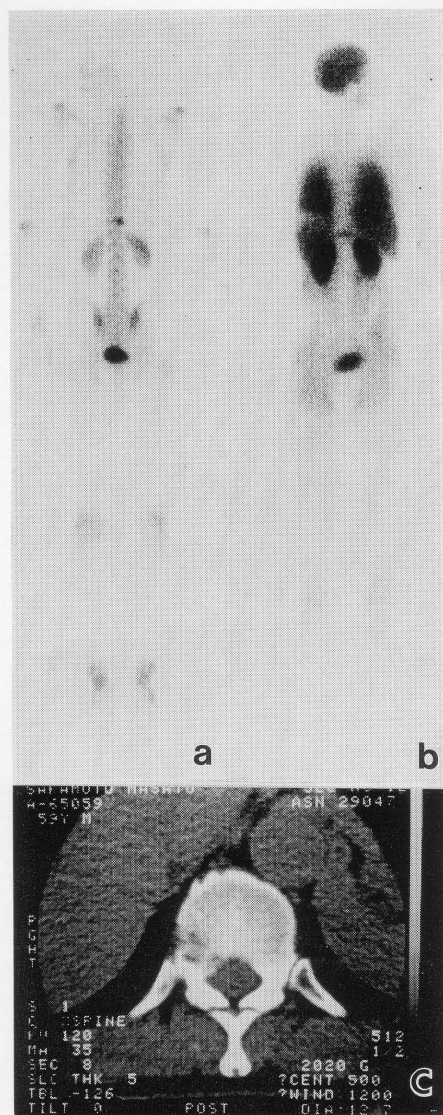


Fig. 2 a Bone scintigraphy: A small hot spot is noted in the lower thoracic vertebra. b ^{99m}Tc -HM-PAO scintigraphy: Increased activity is noted in the lower thoracic vertebra. c Computed tomography: Osteolytic change is present in the thoracic vertebra.

metastatic lesions were clearly delineated, while the benign bone lesions were not. This is most important in diagnosing bone metastasis.

It is well known that bone metastases in HCC produced photon deficient areas on bone scintigraphy.⁹ In our experience, "filling-in" of such areas with ^{99m}Tc -HM-PAO in metastatic sternum, rib, thoracic spine and femur lesions from HCC was observed in four patients. While the precise mechanism of the accumulation of ^{99m}Tc -HM-PAO into the metastatic lesions is not clear, it might be attributed to the fact that tumor accumulation of ^{99m}Tc -HM-PAO was correlated with ^{86}Rb uptake in experimental models,¹³ and that, in a clinical study, the intensity of ^{99m}Tc -HM-PAO uptake cor-

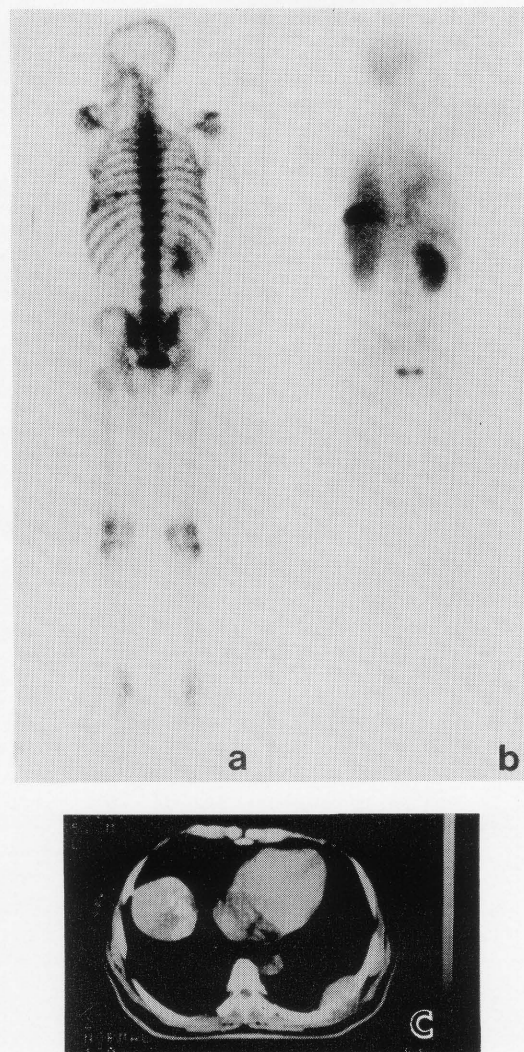


Fig. 3 a Bone scintigraphy: A photon deficient area is noted in the 8th left rib. b ^{99m}Tc -HM-PAO scintigraphy: Increased activity is evident in the 8th left rib. c Computed tomography: Osteolytic change is present in the 8th left rib.

related well with that of the radioactivity at the tumor site in the arterial phase on radionuclide angiography.¹⁴ In our patients with HCC, ^{99m}Tc -HM-PAO might have shown greater activity in the metastatic lesions to the bone, because bone metastatic lesions from HCC are more hypervascular.¹⁵ This intense vascularity is a common feature shared with renal cell carcinomas and their bone metastatic lesions, and these tumors exhibit similar radiographic and scintigraphic changes: Osteolytic change with an expanded cortex and finding of photon deficient defects on the bone scan. Therefore, ^{99m}Tc -HM-PAO might accumulate in bone metastasis from renal cell carcinomas. In this study, the images were obtained at 60 min after i.v. injection of ^{99m}Tc -HM-PAO, and

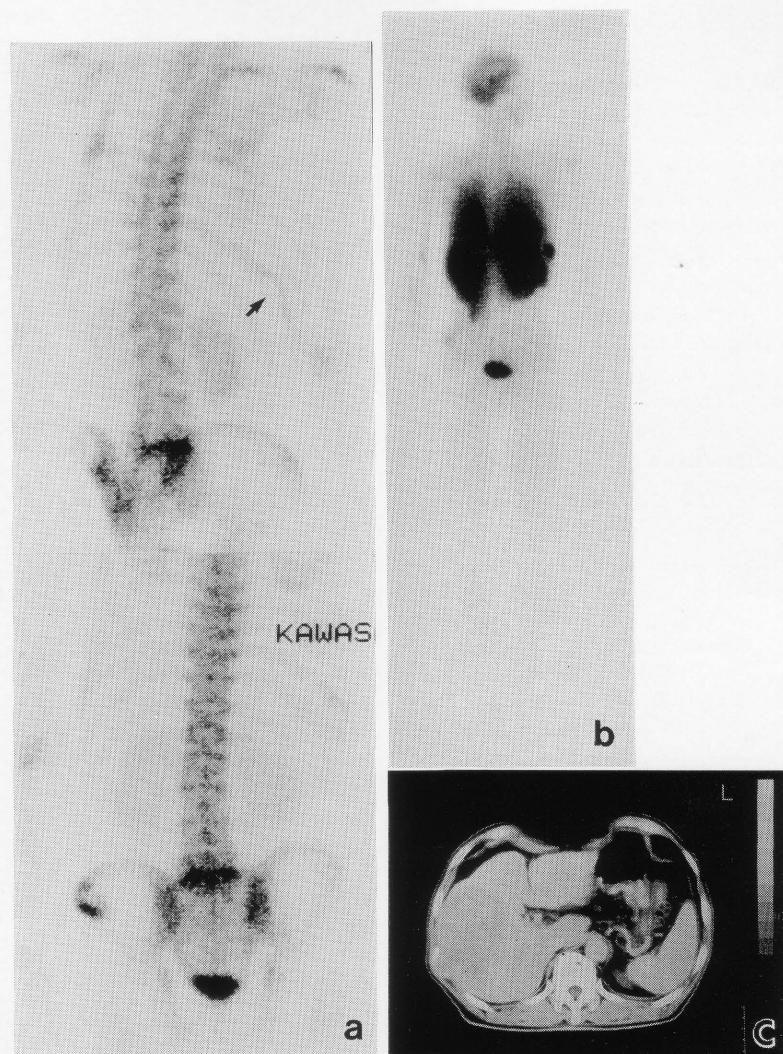


Fig. 4 a Bone scintigraphy (posterior and RPO view): A photon deficient area in the right 10th rib (arrow) and doughnut-like image in the left pelvis are seen. Also, increased activity is noted in the lower lumbar vertebra. b ^{99m}Tc -HM-PAO scintigraphy: Increased activity is shown in the 10th right rib and left pelvis. No accumulation is noted in the lower lumbar vertebra. c Computed tomography: Osteolytic change is evident in the right rib.

lung uptakes were dominant in some cases. Early and delayed imagings of rib lesions are therefore needed in further study. In conclusion, it was shown that, in the detection of bone metastasis from HCC, it was necessary to pay attention to photon deficient areas, and that combination studies with ^{99m}Tc -phosphorous compounds and ^{99m}Tc -HM-PAO were useful for the evaluation of such metastasis.

This study was supported in part by a Research Project Grant (No. 1-801) from Kawasaki Medical School.

REFERENCES

1. Osmond JD, Pendergrass HP, Potsaid MS: Accuracy of ^{99m}Tc -diphosphonate bone scans and roentgenograms in the detection of prostate, breast and lung carcinoma metastases. *Am J Roentgenol Radium Ther Nucl Med* 125: 972-977, 1975
2. Sy WM, Patel K, Faunce H: Significance of absent or faint kidney sign on bone scan. *J Nucl Med* 16: 454-456, 1975
3. Thrupkaew AK, Henkin RE, Quinn JL: False negative bone scans in disseminated metastatic disease. *Radiology* 113: 383-386, 1974
4. Francis MD, Russel RGG, Fleisch H: Diphosphonates inhibit formation of calcium phosphate crystals *in vitro* and pathological calcification *in vivo*. *Science* 165: 1264-1266, 1969
5. Guillemart A, Besnard JC, Pape AL, et al: Skeletal uptake of pyrophosphate labeled with technetium-95m and technetium-96, as evaluated by autoradiography. *J Nucl Med* 19: 895-899, 1978
6. Otsuka N, Morita R, Yamamoto T, et al: A case of synovial sarcoma with bone metastasis identified by

- bone marrow scintigraphy. *Clin Nucl Med* 10: 260–263, 1985
7. Otsuka N, Fukunaga M, Morita K, et al: Detection of bone metastasis from thyroid cancer by bone and ²⁰¹Tl scintigraphy. *Endocr Surg* 7: 411–416, 1990
 8. Otsuka N, Fukunaga M, Sone T, et al: The usefulness of bone and bone-marrow scintigraphy in the detection of bone involvement in patients with multiple myeloma. *Kawasaki Med J* 12: 117–124, 1986
 9. Patricia LT, David C, Ali TI, et al: Photon deficient bone metastasis of hepatocellular carcinoma with avid gallium-67 uptake. *J Nucl Med* 26: 1415–1417, 1985
 10. Hoshi H, Jinnouchi S, Sameshima M, et al: Tc-99m hexamethylpropylene-amine oxime (HM-PAO) uptake in a bone metastasis. *Clin Nucl Med* 13: 595–598, 1988
 11. Hasegawa Y, Nakano S, Ibuka K, et al: Concentration of ^{99m}Tc-Sn-N-pyridoxyl-5-methyltryptophan, a biliary agent, in distant metastases of hepatomas. *Eur J Nucl Med* 10: 255–258, 1985
 12. Borak J: Relationship between the clinical and roentgenological findings in bone metastasis. *Surg Gynecol Obstet* 75: 599–604, 1942
 13. Hammersley PAG, McCready VR, Babich JW, et al: ^{99m}Tc-HM-PAO as a tumor blood flow agent. *Eur J Nucl Med* 13: 90–94, 1987
 14. Fujii H, Hashimoto T, Nakamura K, et al: Tumor imaging using ^{99m}Tc-hexamethylpropyleneamine oxime. *Jpn J Nucl Med* 27: 249–260, 1990
 15. Cornelia G, Hossein F, Mahvash R: Hepatocellular carcinoma with skeletal metastasis. *Radiology* 154: 617–618, 1985