

## Localization of hyperfunctioning parathyroid glands by means of thallium-201 and iodine-131 subtraction scintigraphy in patients with primary and secondary hyperparathyroidism

Mitsuko SUEHIRO and Minoru FUKUCHI

*Department of Nuclear Medicine, Hyogo College of Medicine, Nishinomiya, Hyogo, Japan*

The accuracy of the preoperative localization of hyperfunctioning parathyroid glands by subtraction scintigraphy with  $^{201}\text{Tl}$  and  $^{131}\text{I}$  was evaluated by comparison with the operative findings. The subjects were 67 consecutive patients with hyperparathyroidism (HPT), including 24 with primary and 43 with secondary HPT. In primary HPT, surgery revealed 26 adenomas weighing 0.26–15.80 g (mean  $\pm$  SD;  $3.01 \pm 3.04$  g). Two patients had double adenomas. Scintigraphy correctly localized 25/26 adenomas (96.2%) in primary HPT for a sensitivity, specificity, and accuracy of 96.2%, 98.5%, and 97.9%, respectively. In secondary HPT, 163 hyperplastic glands weighing 0.03–5.08 g ( $0.85 \pm 0.93$  g) were found. Scintigraphy correctly localized 79 glands (48.5%) weighing 0.03–5.08 g ( $1.19 \pm 1.10$  g), but 84 glands (51.5%) weighing 0.04–2.70 g ( $0.51 \pm 0.50$  g) were not detected. Thus, the sensitivity, specificity, and accuracy of scintigraphy were respectively 48.5%, 100%, and 51.2%, in secondary HPT. These results show that scintigraphy with  $^{201}\text{Tl}$  and  $^{131}\text{I}$  can be used to locate abnormal parathyroid glands with an efficacy equal to or better than that of the conventional methods with  $^{201}\text{Tl}$  and  $^{99\text{m}}\text{Tc}$  or  $^{201}\text{Tl}$  and  $^{123}\text{I}$ .

**Key words:** subtraction scintigraphy, parathyroid gland,  $^{131}\text{I}$ ,  $^{201}\text{Tl}$ , hyperparathyroidism

### INTRODUCTION

THE PREOPERATIVE LOCALIZATION of hyperfunctioning parathyroid glands is a vital step in the treatment of hyperparathyroidism (HPT). Since Fukunaga et al.<sup>1</sup> first reported on the accumulation of thallium-201 ( $^{201}\text{Tl}$ ) in parathyroid adenomas, parathyroid subtraction scintigraphy with  $^{201}\text{Tl}$  and thyroid imaging agents has been applied clinically.<sup>2–11</sup> Such scintigraphy is now most commonly performed with  $^{201}\text{Tl}$  and technetium-99m ( $^{99\text{m}}\text{Tc}$ ),<sup>2–9</sup> and to a lesser extent with  $^{201}\text{Tl}$  and iodine-123 ( $^{123}\text{I}$ ).<sup>10,11</sup> Thyroid imaging is commonly performed with  $^{123}\text{I}$ ,  $^{99\text{m}}\text{Tc}$ , or occasionally iodine-131 ( $^{131}\text{I}$ ). However, parathyroid subtraction scintigraphy with  $^{201}\text{Tl}$  and  $^{131}\text{I}$  has not previously been reported.

In this paper, we describe the results of parathyroid subtraction scintigraphy with  $^{201}\text{Tl}$  and  $^{131}\text{I}$  in a series of 67 preoperative patients with primary or secondary HPT.

### MATERIALS AND METHODS

#### *Patients*

We studied 67 patients with HPT, including 24 with primary HPT (20 females and 4 males aged 21–83 years; mean age: 51.8 years) and 43 hemodialysis patients with secondary HPT due to chronic renal failure (24 females and 19 males aged 24–62 years; mean age: 43.1 years). They were all referred to our department for the preoperative localization of hyperfunctioning parathyroid glands. All the patients were diagnosed as having HPT on the basis of clinical signs and biochemical data.

#### *Imaging procedure*

A gamma camera (Starcam 400 AC/T, GE, Milwaukee, WI, U.S.A.) with a pinhole collimator

Received January 8, 1992, revision accepted April 4, 1992.

For reprints contact: Mitsuko Suehiro, M.D., Department of Nuclear Medicine, Hyogo College of Medicine, 1-1, Mukogawacho, Nishinomiya, Hyogo 663, Japan.

was used.  $^{131}\text{I}$  (3.7 MBq, 0.1 mCi) was given orally as sodium iodide to each patient after pretreatment with a low-iodine diet for one week. Twenty-four hours later, scintigraphy of the anterior neck was performed. At first, scattering data for  $^{131}\text{I}$  were acquired via the  $^{201}\text{Tl}$  window ( $71\text{ KeV} \pm 10\%$ ) of a pulse height analyzer (PHA), and these data were fed into the computer for 5 minutes to allow subtraction of the  $^{131}\text{I}$  scattering image from the  $^{201}\text{Tl}$  image. Then, 74 MBq (2 mCi) of  $^{201}\text{Tl}$  chloride was given intravenously by bolus injection. Two minutes later,  $^{201}\text{Tl}$  and  $^{131}\text{I}$  data were simultaneously acquired at the neck with a  $128 \times 128$  matrix and a PHA with a  $^{201}\text{Tl}$  window and another PHA with a  $^{131}\text{I}$  window ( $364\text{ KeV} \pm 10\%$ ), and the data were fed into the computer for 15 minutes. The patients remained motionless during scintigraphy, with the neck supported on a specially designed pillow. Subtraction images were obtained as follows. First, the  $^{131}\text{I}$  scattering image was subtracted from the  $^{201}\text{Tl}$  image and then the background was subtracted from

the  $^{201}\text{Tl}$  image. Next,  $^{131}\text{I}$  and  $^{201}\text{Tl}$  images were produced with an identical number of counts in each region of interest (ROI), and finally the  $^{131}\text{I}$  image was subtracted from the  $^{201}\text{Tl}$  image to give a parathyroid subtraction image (Figs. 1 and 2). The results of scintigraphy were compared with the data obtained by surgical exploration of the neck.

## RESULTS

### Primary HPT

All the patients were found to have abnormal parathyroid activity in the neck on scintigraphy. At operation, 26 adenomas were found in the 24 patients in this group. These tumors weighed from 0.26 to 15.80 g ( $3.01 \pm 3.04$  g) and 2 patients had double adenomas. All but one of the adenomas (96.2%) were correctly localized by scintigraphy, including the double adenomas. Thus, in primary HPT scintigraphy was true positive for 25 hyperfunctioning glands, true negative for 67 normal glands, false positive for 1 normal gland, and false negative for

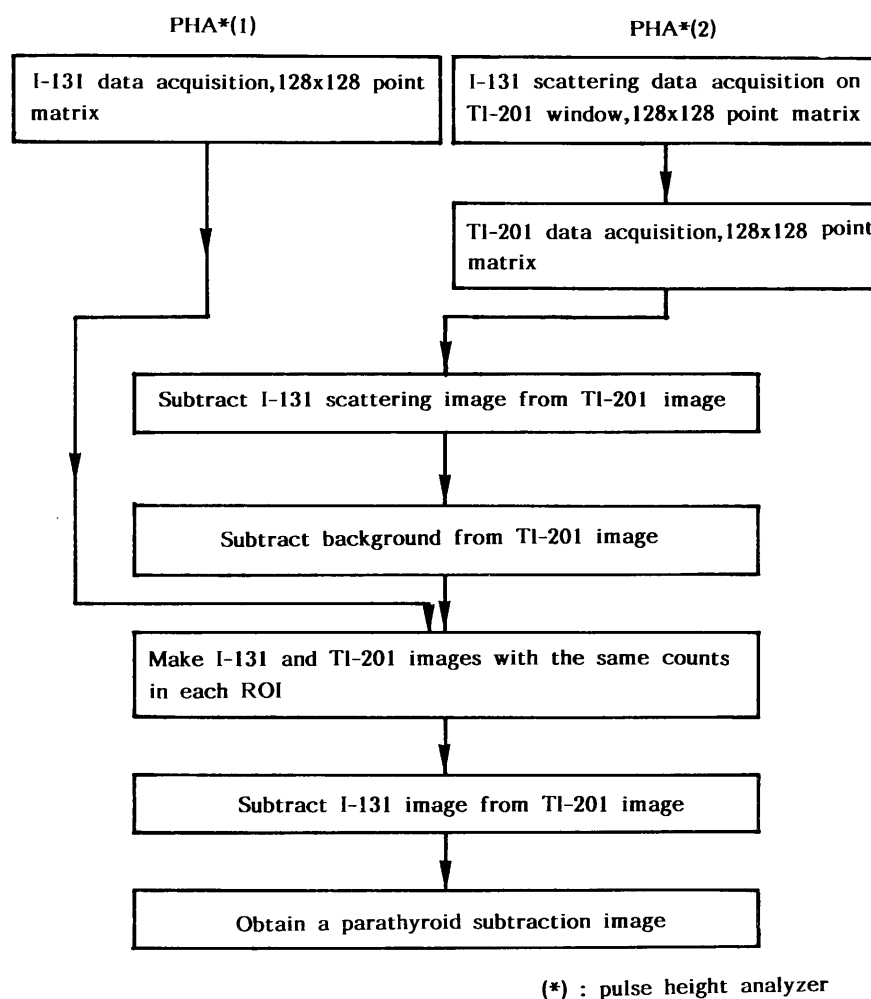
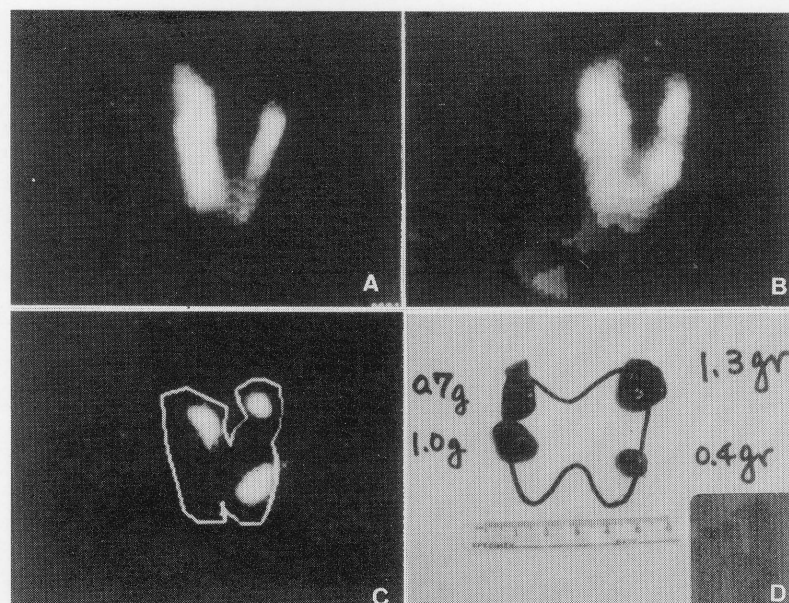


Fig. 1 Procedure for parathyroid subtraction scintigraphy using  $^{201}\text{Tl}$  and  $^{131}\text{I}$ .



**Fig. 2** Parathyroid subtraction scintigraphy using  $^{201}\text{Tl}$  and  $^{131}\text{I}$  in a patient with secondary HPT. A:  $^{131}\text{I}$  thyroid image, B:  $^{201}\text{Tl}$  thyroid image after background subtraction, C: subtraction image with abnormal parathyroid activity in the neck, and D: location of abnormal parathyroid glands found at surgery.

**Table 1** Scintigraphy data and operative findings in 67 patients with primary and secondary HPT

Patient	Number of patients	Surgical exploration	True		False		Evaluation (%)		
		Abnormal glands	Positive	Negative	Positive	Negative	Sensitivity (#)	Specificity (##)	Accuracy (###)
Primary HPT*	24	26	25	67	1	1	96.2	98.5	97.9
Secondary HPT*	43	163	79	9	0	84	48.5	100	51.2

(\*)=hyperparathyroidism

$$(\#) = \frac{(\text{true-positive})}{(\text{true-positive}) + (\text{false-negative})} \times 100$$

$$(\##) = \frac{(\text{true-negative})}{(\text{true-negative}) + (\text{false-positive})} \times 100$$

$$(\###) = \frac{(\text{true-positive}) + (\text{true-negative})}{(\text{true-positive}) + (\text{false-negative}) + (\text{true-negative}) + (\text{false-positive})} \times 100$$

1 hyperfunctioning gland. Therefore, the sensitivity, specificity, and accuracy were 96.2%, 98.5%, and 97.9%, respectively (Table 1).

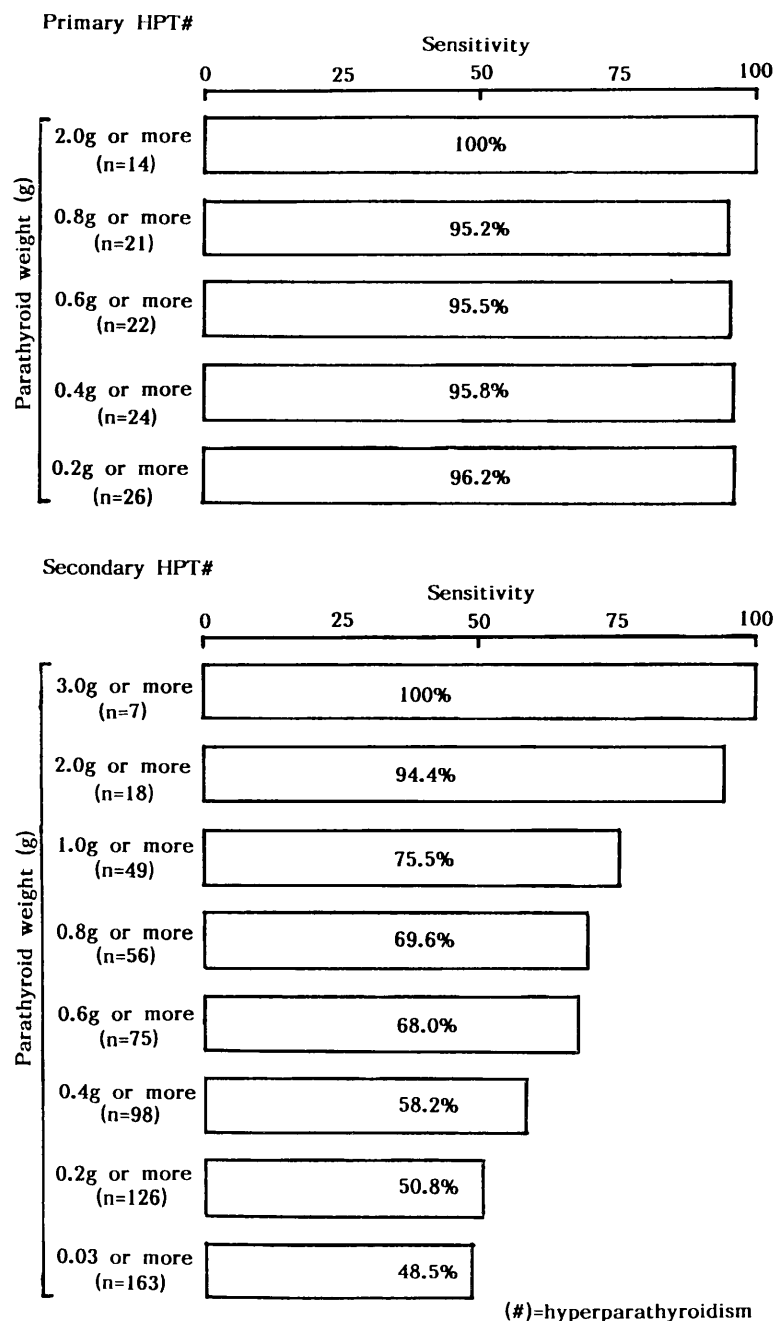
#### Secondary HPT

Forty-one of the 43 patients (95.3%) were found to have abnormal parathyroid activity in the neck by scintigraphy, and in the other 2 patients (4.7%) there appeared to be no hyperplastic glands in the neck. At operation, 163 hyperplastic glands weighing from 0.03 to 5.08 g ( $0.85 \pm 0.93$  g) were found in the 43 patients. Scintigraphy correctly localized 79/163 glands (48.5%) weighing from 0.03 to 5.08 g ( $1.19 \pm 1.10$  g), but 84 hyperplastic glands (51.5%) weighing from 0.04 to 2.70 g ( $0.51 \pm 0.50$  g) were not detected. At least one gland was correctly localized in 41

patients (95.3%), while two or more glands were detected in 28 patients (65.1%), three or more glands were found in 8 patients (18.6%), and four glands were seen in 2 patients (4.7%). Thus, in secondary HPT scintigraphy was true positive for 79 hyperplastic glands, true negative for 9 normal glands, and false negative for 84 hyperplastic glands. There were no false positive results. Therefore, the sensitivity, specificity, and accuracy were 48.5%, 100%, and 51.2%, respectively (Table 1).

#### Sensitivity and parathyroid weight

The sensitivity of scintigraphy was compared with the weight of the respected hyperfunctioning parathyroid glands in all the patients. In primary HPT, the sensitivity of scintigraphy was not related to the



**Fig. 3** Comparison between the sensitivity of detection by scintigraphy and the weight of the abnormal parathyroid glands determined by surgical exploration.

weight of the hyperfunctioning gland (Fig. 3). However, in secondary HPT, there was a good relationship between detection by scintigraphy and the weight of the hyperplastic gland (Fig. 3).

## DISCUSSION

Computer-assisted subtraction imaging is generally performed for clinical parathyroid scintigraphy with  $^{201}\text{Tl}$  and  $^{99\text{m}}\text{Tc}$ ,<sup>2-9</sup> and to a lesser extent with  $^{201}\text{Tl}$  and  $^{123}\text{I}$ .<sup>10,11</sup> In this study, we investigated computer-

assisted parathyroid subtraction scintigraphy with  $^{201}\text{Tl}$  and  $^{131}\text{I}$ .  $^{131}\text{I}$  is a relatively suitable radionuclide for parathyroid subtraction scintigraphy, despite its long half-life, beta emissions that increase the radiation dose to the thyroid tissue, and the high energy of the principal gamma photons (364 KeV). The long half-life of  $^{131}\text{I}$  allows sufficient neck counts to be accumulated in the ROI for effective parathyroid subtraction scintigraphy and the high energy of the principal photons can be effectively controlled with a pinhole collimator. In fact, the

penetration of high energy photons (up to 480 KeV) was only 5.0% with a pinhole collimator and our instruments. The radiation dose to the thyroid gland is only 0.439 mGy when 74 MBq (2 mCi) of  $^{201}\text{Tl}$  is injected for parathyroid subtraction scintigraphy in euthyroid patients. Therefore, the radiation dose to the thyroid is mainly due to the companion radionuclide ( $^{99\text{m}}\text{Tc}$ ,  $^{123}\text{I}$ , or  $^{131}\text{I}$ ). The dose provided with 3.7 MBq (0.1 mCi) of  $^{131}\text{I}$  for parathyroid subtraction scintigraphy in euthyroid patients is very much higher (1,291.8 mGy) than that obtained with 148 MBq (4 mCi) of  $^{99\text{m}}\text{Tc}$  (7.96 mGy) or with 7.4 MBq (0.2 mCi) of  $^{123}\text{I}$  (27.9 mGy). Therefore, the clinical application of scintigraphy with  $^{201}\text{Tl}$  and  $^{131}\text{I}$  requires circumspection.  $^{131}\text{I}$  was widely used for routine thyroid scintigraphy in patients with various thyroid disorders between 1952 and 1979 in Japan without causing adverse reactions.<sup>12</sup> In addition, Holm et al.<sup>13</sup> reported that a diagnostic dose of  $^{131}\text{I}$  did not increase the incidence of thyroid malignancy in their retrospective study of 10,133 patients. Although  $^{131}\text{I}$  is perhaps generally considered an undesirable radionuclide for thyroid scintigraphy when compared with  $^{123}\text{I}$  or  $^{99\text{m}}\text{Tc}$ , we believe that there is no reason to completely abandon its clinical use. For example, when  $^{131}\text{I}$  is used for parathyroid subtraction scintigraphy, it is relatively inexpensive (1/14 of the cost of  $^{123}\text{I}$  and 1/11 of that of  $^{99\text{m}}\text{Tc}$ ). In addition, simultaneous acquisition of the neck counts for  $^{201}\text{Tl}$  and  $^{131}\text{I}$  (which possess different photon energies of  $71\text{ KeV} \pm 10\%$  and  $364\text{ KeV} \pm 10\%$ , respectively) can be performed with two PHAs without influencing the data for the other radionuclide. The sensitivity of detection of abnormal parathyroid glands by this method was 96.2% in primary HPT and 48.5% in secondary HPT. It is well known that detection sensitivity depends upon the size of the gland being imaged, and that smaller glands are more difficult to detect by nuclear medical techniques. At surgical exploration, 163 hyperplastic parathyroid glands were observed in the 43 patients with secondary HPT, weighing from 0.03 to 5.08 g (mean; 0.85 g). However 84 of these hyperplastic glands (51.5%) were quite small and weighed only 0.50 g or less. Therefore, it seems that the lower sensitivity of scintigraphy in the patients with secondary HPT was probably due to the smaller size of their abnormal parathyroid glands, which were close to the limit of resolution for our gamma camera. The sensitivity of scintigraphy was not related to the weight of the hyperfunctioning gland in primary HPT (Fig. 3). However, we found a good relationship between the sensitivity of detection and gland weight in secondary HPT (Fig. 3). Primary HPT is due to the excessive autonomous secretion of parathormone from one or more of the parathyroid tumor(s).<sup>14</sup> On

the other hand, secondary HPT arises because of chronic hypocalcemia, which acts as a stimulus to parathormone secretion and enlargement of the parathyroid glands.<sup>15</sup> Therefore, the different characteristics of the two diseases may have led to different results in our study. In addition, it should be noted that at least one lesion was correctly localized in all of the primary HPT patients and 95.3% of the secondary HPT patients (with 100% specificity). The detection sensitivity of parathyroid subtraction scintigraphy with  $^{201}\text{Tl}$  and  $^{99\text{m}}\text{Tc}$  is 42%–96% in primary HPT and 32%–100% in secondary HPT<sup>2-9</sup> and the sensitivity with  $^{201}\text{Tl}$  and  $^{123}\text{I}$  is reported as 72.0%<sup>10</sup> or 87.5%<sup>11</sup> for all types of HPT.

In conclusion, combined  $^{201}\text{Tl}$  and  $^{131}\text{I}$  scintigraphy can be used to locate abnormal parathyroid glands with an efficacy equal to or better than that of the conventional methods with  $^{201}\text{Tl}$  and  $^{99\text{m}}\text{Tc}$  or  $^{201}\text{Tl}$  and  $^{123}\text{I}$ .

#### ACKNOWLEDGMENTS

We thank the Clinical Nuclear Medicine Technologists of our Department (K. Tachibana, K. Onoue, K. Hamada, Y. Maeda and H. Narita) for their invaluable technical assistance. We also thank Drs. T. Fujita, M. Fukase and H. Baba of the Kobe University Medical School, and Drs. S. Inoue, Y. Fujita and F. Ikoma of the Hyogo College of Medicine for their invaluable cooperation and helpful discussion. The typing of the manuscript by Miss Takako Ikeda is gratefully acknowledged.

#### REFERENCES

1. Fukunaga M, Fujita T, Yonekura Y, et al: Visualization of parathyroid tumor with  $^{201}\text{Tl}$ -chloride. *Jpn J Nucl Med* 16: 327–330, 1979
2. Young AE, Gaunt JI, Croft DN, et al: Location of parathyroid adenomas by thallium-201 and technetium-99m subtraction scanning. *Br Med J* 286: 1384–1386, 1983
3. Ferlin G, Borsato N, Cameran W, et al: New perspectives in localizing enlarged parathyroids by technetium-thallium subtraction scan. *J Nucl Med* 24: 438–441, 1983
4. Corcoran MO, Seifacian MA, George SL, et al: Location of parathyroid adenomas by thallium-201 and technetium-99m subtraction scanning. *Br Med J* 286: 1751–1752, 1983
5. Sandrock D, Merino MJ, Norton JA, et al: Parathyroid imaging by Tc/Tl scintigraphy. *Eur J Nucl Med* 16: 607–613, 1990
6. Okerlund MD, Sheldon K, Corpuz S, et al: A new method with high sensitivity and specificity for localization of abnormal parathyroid glands. *Ann Surg* 200: 381–388, 1984
7. Wheeler MH, Harrison BJ, French AP, et al: Preliminary results of thallium 201 and technetium 99m

- subtraction scanning of parathyroid glands. *Surgery* 96: 1078-1082, 1984
8. Percival RC, Blake GM, Urwin GH, et al: Assessment of thallium-pertechnetate subtraction scintigraphy in hyperparathyroidism. *Br J Radiol* 58: 131-135, 1985
  9. Gooding GAW, Okerlund MD, Stark DD, et al: Parathyroid imaging: comparison of double-tracer (Tl-201, Tc-99m) scintigraphy and high-resolution US. *Radiology* 161: 57-64, 1986
  10. MacFarlane SD, Hanelin LG, Taft DA, et al: Localization of abnormal parathyroid glands using thallium-201. *Am J Surg* 148: 7-13, 1984
  11. Picard D, D'Amour P, Carrier L, et al: Localization of abnormal parathyroid gland(s) using thallium-201/iodine-123 subtraction scintigraphy in patients with primary hyperparathyroidism. *Clin Nucl Med* 12: 60-64, 1987
  12. Subcommittee of Safety Issue for the Radiopharmaceuticals, Medical and Pharmaceutical Committee, Japan Radioisotope Association: The report on survey of the adverse reaction to radiopharmaceuticals. 1975-1989
  13. Holm LE, Lundell G, Walinder G: Incidence of malignant thyroid tumors in humans after exposure to diagnostic doses of iodine-131. I. Retrospective cohort study. *J Natl Cancer Instit* 64: 1055-1059, 1980
  14. Habener JF, Potts JT Jr: Primary hyperparathyroidism. Clinical features. In *Endocrinology*, Second edition, Vol 2, DeGroot LJ (ed), Philadelphia, W.B. Saunders Company, pp 954-966, 1989
  15. Segre GV, Potts JT Jr: Differential diagnosis of hypercalcemia. Methods and clinical applications of parathyroid assays. In *Endocrinology*, Second edition, Vol 2, DeGroot LJ(ed), Philadelphia, W.B. Saunders Company, pp 984-1001, 1989