

## Transient thyrotoxicosis in a patient with a functioning nodule; A possible occurrence of silent thyroiditis

Kanji KASAGI, Sumiaki MATSUMOTO, Ryo Takeuchi, Takashi MISAKI  
and Junji KONISHI

*Department of Nuclear Medicine, Kyoto University Hospital, Kyoto*

A 48-year-old woman with diffuse goiter presented with typical symptoms and signs of thyrotoxicosis. Thyroid scanning with I-123 revealed a localized accumulation of the radio-nuclide in the left lobe which corresponded to a small nodule later detected by ultrasono-graphy, with suppression of the remaining tissues. Owing to the overall reduced radioactivity in the thyroid, she was suspected of having silent thyroiditis causing thyrotoxicosis. Mean-while, the thyrotoxicosis subsided concurrently with an increase in radioactivity in the extranodular area that had initially been suppressed. The histology of thyroid tissues obtained at the time of operation revealed follicular adenoma or hyperplasia in the area of the localized I-123 uptake and findings similar to those in Hashimoto's thyroiditis in the remaining tissues, supporting our clinical diagnosis of silent thyroiditis together with a functioning nodule.

**Key words:** silent thyroiditis, functioning thyroid nodule, thyrotoxicosis

### INTRODUCTION

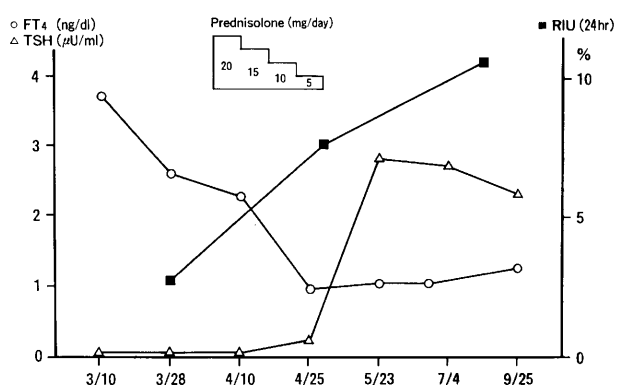
THYROID SCANNING with Tc-99m or radioiodine is known to be useful for the differential diagnosis of thyroid diseases causing thyrotoxicosis. We have recently seen a thyrotoxic patient with a functioning nodule, in whom the thyrotoxicosis was caused by concomitant silent thyroiditis. This paper presents her scintigraphic findings, which may support the diagnoses.

### CASE REPORT

A 48-year-old woman visited Kyoto University Hospital, because she had noticed general fatigue, palpitation and shortness of breath on effort, excessive sweating, and weight loss of 3-4 kg over past 4 months. Physical examination revealed a diffusely enlarged soft goiter, hand tremor, moist skin, tachy-

cardia (120/min) and systolic hypertension (180/80). Neither exophthalmos nor ophthalmopathy was present. She had no fever or tenderness in the anterior neck region.

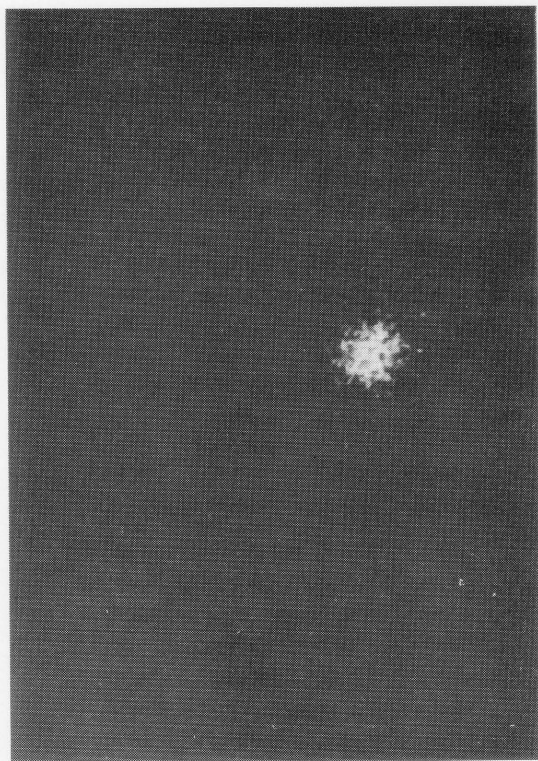
*In vitro* thyroid function tests performed on March 10 revealed high serum T4 concentrations of 16.3  $\mu\text{g}/\text{dL}$  (normal range, 5.0-11.0), free T4 of 3.7 ng/dL (normal, 0.99-1.92), T3 of 238 ng/dL (normal, 90-170), and free T3 of 9.0 pg/mL (normal, 2.2-5.0). The serum TSH level was undetectably low ( $<0.03 \mu\text{U}/\text{mL}$ ).



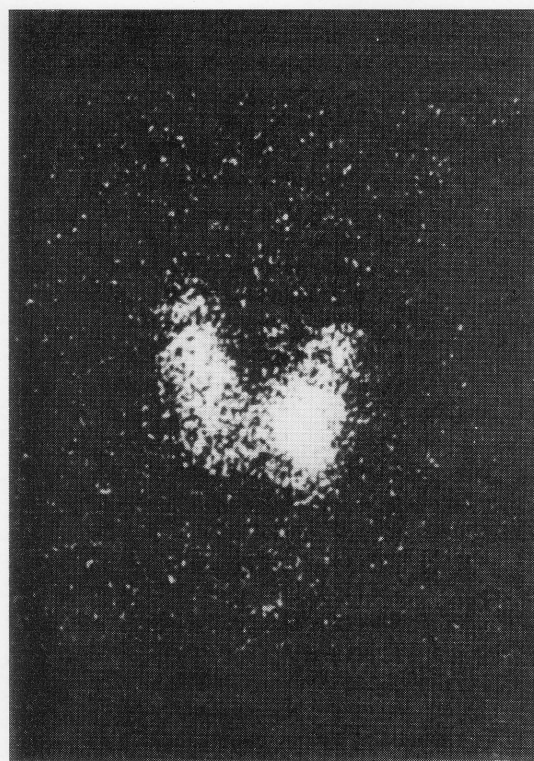
**Fig. 1** The clinical course. As thyrotoxicosis subsided,  $^{123}\text{I}$  thyroidal uptake increased. RIU: radioactive iodine uptake.

Received December 13, 1991, revision accepted February 3, 1992.

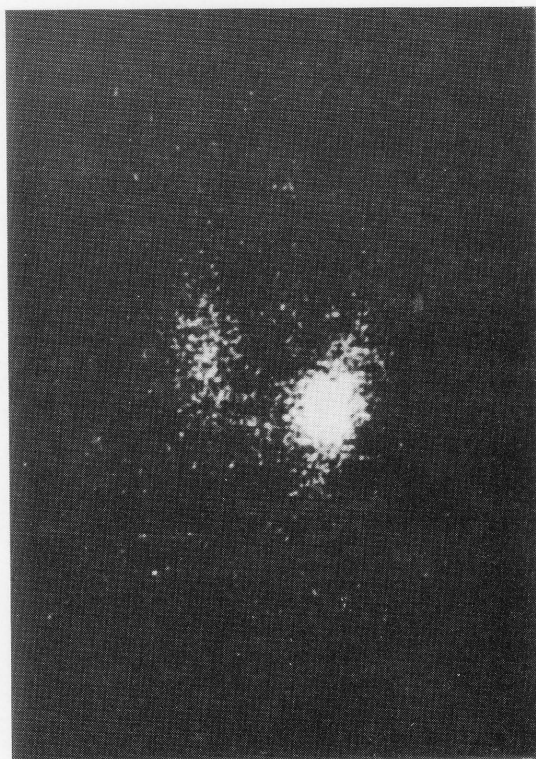
For reprints contact: Kanji Kasagi, M.D., the Department of Nuclear Medicine, Kyoto University Hospital, 54, Kawahara-cho, Shogoin, Sakyo-ku, Kyoto 606, JAPAN.



a



c



b

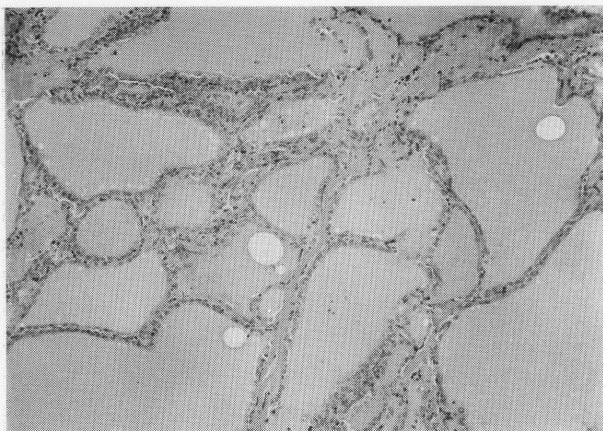
**Fig. 2** Thyroid scanning with  $^{123}\text{I}$  performed on March 28 revealed the presence of a hot nodule in the left lobe with suppression of the remaining tissues (a). The overall  $^{123}\text{I}$  thyroidal uptake value 24 hours after oral administration of 7.4 MBq of  $^{123}\text{I}$  was 2.7% (normal, 7–35). There was a gradual increase in radioactivity during the course of the illness in the extranodular tissues which had initially been suppressed. The overall  $^{123}\text{I}$  thyroidal uptake values at 24 hours were 7.6% on April 27 (b) and 10.5% on August 24 (c).

(TBII) nor thyroid stimulating antibodies (TSAb) were detected in the serum.<sup>1</sup> CRP was negative. No other abnormal findings were obtained.

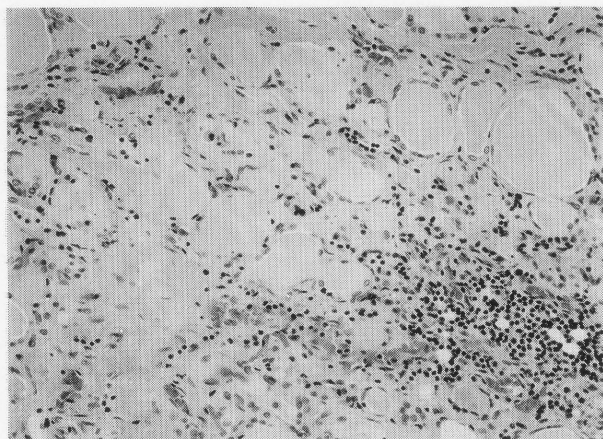
Ultrasonographic examination revealed diffuse enlargement of the thyroid and a small, round hypoechoic area 2.0 cm in diameter in the lower and anterior part of the left lobe. Thyroid scanning with I-123 revealed a small area of localized uptake in the lower part of the left lobe, corresponding to the hypoechoic lesion, with reduced radioactivity in the remaining thyroid tissues.

Overproduction of thyroid hormones by the hot nodule seemed unlikely as a cause of thyrotoxicosis, since I-123 thyroidal uptake was substantially reduced at 2.7% (24 hours after oral administration of 3.7 MBq of I-123; normal, 7–35) (Fig. 1 & 2). Consequently, silent thyroditis was thought to be responsible for the thyrotoxicosis, and she received 120 mg/day metoprolol ( $\beta$ -antagonist). The clinical course is illustrated in Fig. 1. Prednisolone was used

mI; normal, 0.3–3.9). The serum TBG concentration was 19.2  $\mu\text{g}/\text{ml}$  (normal, 14.2–30.5). Antibody titers against thyroglobulin and microsomes were positive, both at dilutions of 1:1600 (normal, both 1: <100). Neither TSH binding inhibitor immunoglobulins



a



b

**Fig. 3** Histological findings in thyroid tissues obtained at the time of operation. There was a firm mass measuring 2 cm in diameter, surrounded by a fibrous capsule. Variable sized follicles with epithelial hyperplasia were observed in the mass (a), while follicular degeneration, lymphocytic infiltration and fibrosis were seen in the extranodular tissues (b). The pathological diagnoses were follicular adenoma or hyperplasia and Hashimoto's thyroiditis, respectively.

for a short period in order to suppress the putative inflammatory process. Although the effects of prednisolone was uncertain, she became euthyroid in parallel with a gradual increase in I-123 thyroidal uptake. Figure 2 demonstrates that the overall increase in I-123 thyroidal uptake is attributable to the increase in radioactivity in the extranodular tissues which was initially suppressed and that the accumulation of I-123 in the nodule itself did not change substantially during the course of the illness. Since the pathological examination of the nodule by fine needle aspiration biopsy showed it to be class IV in the Papanicolau classification, she underwent left hemithyroidectomy, which gave us a chance to make a pathological diagnosis. Microscopically, variable

sized follicles with epithelial hyperplasia were observed in the nodule, while follicular degeneration, lymphocytic infiltration and fibrosis were observed in the remaining tissues (Fig. 3). The pathological diagnoses were follicular adenoma or hyperplasia, and Hashimoto's thyroiditis, respectively.

## DISCUSSION

The patient was suspected of having Graves' disease at her first visit. A low T3/T4 ratio (14.6),<sup>2</sup> negative TBII and TSAb activities, and low thyroidal uptake of I-123, however, suggested that the thyrotoxicosis was of a destruction-induced type. Subacute thyroiditis could be ruled out, considering her lack of fever or anterior neck pain and negative CRP. Although she was diagnosed as having silent thyroiditis and a functioning nodule, a differential diagnosis from toxic nodular goiter or destruction-induced thyrotoxicosis following hemorrhagic infarction in the functioning nodule<sup>4</sup> could not be definitely made. Results of the patient's history, physical examination and other tests excluded the possibility of other thyroid diseases causing thyrotoxicosis, such as hCG-producing tumors, metastatic functioning thyroid cancer, TSH-producing tumor, pituitary resistance to thyroid hormones, excessive intake of thyroid hormones and struma ovarii.

The diagnoses of silent thyroiditis and a functioning nodule became more and more convincing during the course of the illness, because serial changes in serum thyroid hormone concentrations, the I-123 thyroidal uptake value and the thyroid scan image seemed to reflect the healing process of silent thyroiditis. The histological diagnosis was adenoma or hyperplasia with Hashimoto's thyroiditis, supporting the clinical diagnoses. There were none of the cystic lesions in the nodule which can be produced following hemorrhagic infarction.

The reported incidence of adenomas in Hashimoto's thyroiditis is as high as 8.3–25.0%.<sup>5</sup> On the other hand, the association of functioning nodules with Hashimoto's thyroiditis, to our knowledge, has never been reported. Although a functioning nodule coincident with silent thyroiditis may be uncommon, the present case report at least has confirmed the usefulness of thyroid scintigraphy for the diagnosis of thyroid diseases causing thyrotoxicosis.

## REFERENCES

1. Kasagi K, Tamai H, Morita T, et al: Role of thyrotropin receptor antibodies in the development of hyperthyroidism: follow-up studies on nine patients with Graves' disease. *J Clin Endocrinol Metab* 68: 1189–1194, 1989.

2. Amino N, Yabu Y, Miki T, et al: Serum ratio of triiodothyronine to thyroxine, and thyroxin-binding globulin and calcitonin concentrations in Graves' disease and destruction-induced thyrotoxicosis. *J Clin Endocrinol Metab* 53: 113-116, 1981
3. Gluck FB, Nusynowitz ML, Plymate S: Chronic lymphocytic thyroiditis, and low radioactive iodine uptake. *N Engl J Med* 293: 624-628, 1975
4. Hamburger JI, Taylor CI: Transient thyrotoxicosis associated with acute hemorrhagic infarction of autonomously functioning thyroid nodules. *Ann Intern Med* 91: 406-409, 1979
5. Holmes HB, Kreutner A, O'Brien PH: Hashimoto's thyroiditis and its relationship to other thyroid diseases. *Surg Gynecol Obstet* 144: 887-890, 1977