

Preoperative evaluation of myocardial viability by thallium-201 imaging in patients with old myocardial infarction who underwent coronary revascularization

Hitoshi NARUSE,* Mitsumasa OHYANAGI,* Tadaaki IWASAKI,*
Takashi MIYAMOTO** and Minoru FUKUCHI***

**The First Department of Internal Medicine, **Department of Thoracic Surgery,
***Department of Nuclear Medicine, Hyogo College of Medicine, Nishinomiya, Japan*

The myocardial uptake and redistribution in thallium scintigraphy and the regional wall motion by echocardiography were evaluated by a semi-quantitative method in 42 patients who previously had myocardial infarction (50 target vessels) and underwent coronary revascularization. The aim of this study was to elucidate the significance of the initial image, delayed image and redistribution on thallium-201 scintigraphy for clinical diagnosis of the myocardial viability. As a semi-quantitative analysis, we used a bull's-eye display for thallium image and centerline method for echocardiographic wall motion, and compared the results before and after revascularization. As a result, the thallium grade improved postoperatively in all 17 areas which preoperative had showed redistribution, and also in 11 of the 32 areas without preoperative redistribution. The sensitivity, specificity and accuracy of preoperative thallium redistribution for predicting myocardial viability were 61%, 100% and 78%, respectively, when the postoperative improvement in the thallium grade was used as the standard. The postoperative probability of improvement in the thallium grade increased in proportion to the preoperative thallium grade (delayed image) ($p < 0.01$). There was no correlation between the preoperative thallium delayed image and postoperative improvement in wall motion. Postoperative improvement in thallium image and wall motion could not be predicted from the preoperative wall motion. Thus, postoperative improvement in thallium images can be anticipated if redistribution is present on the preoperative thallium image, and the preoperative thallium delayed image is useful for predicting myocardial viability. Improvement in wall motion could not be predicted preoperatively by these methods.

Key words: thallium-201 exercise myocardial scintigraphy, bull's-eye display, coronary revascularization, myocardial viability

INTRODUCTION

THE INDICATIONS for coronary revascularization, such as coronary artery bypass surgery (CABG) and percutaneous transluminal coronary angioplasty

(PTCA), are determined by the coronary angiographic findings in patients with coronary artery disease. In addition, in patients with prior myocardial infarction, myocardial viability should be evaluated preoperatively. Generally we used redistribution on exercise thallium-201 myocardial scintigraphy and regional wall motion examination by echocardiography or left ventriculography.¹⁻³ However, even a myocardium not exhibiting redistribution may require coronary revascularization, as indicated by such clinical factors as exercise-induced chest pain or ischemic ST-T changes on electrocardiography

Received July 3, 1991, revision accepted December 11, 1991.

For reprints contact: Hitoshi Naruse, The First Department of Internal Medicine, Hyogo College of Medicine, 1-1 Mukogawa-cho, Nishinomiya-shi, Hyogo 663, JAPAN.

and poor exercise tolerance due to left ventricular dysfunction. Postoperative improvement has frequently been found in the regional wall motion and myocardial blood flow in such cases.⁴⁻⁶ The results from these two methods generally differ, but a little work has been done in terms of establishing a reliable method of preoperative evaluation of myocardial viability and postoperative follow-up. We therefore tried to design a method that would make possible pre- and postoperative evaluation semi-quantitatively and multilaterally, using thallium-201 imaging and different methods, such as wall motion. We reevaluated the significance of the initial image, delayed image and redistribution on thallium scintigraphy.

SUBJECTS AND METHODS

Study population

The study group comprised 42 patients with previous myocardial infarction who underwent CABG or PTCA for coronary revascularization (a total of 50 vessels). The group included 39 men and 3 women (mean age \pm standard deviation: 59 ± 9 years). Target vessels were certified to be patent by postoperative coronary (or graft) angiography. Twenty-two subjects underwent bypass grafting to the 30 stenosed vessels (a single vessel in 14 patients, and two vessels in eight patients). In 20 subjects, the 20 stenosed vessels were treated by PTCA (all single-vessel). Preoperative stenosed vessels included 11 right coronary arteries, 32 left anterior descending arteries, and seven left circumflex arteries. A clinical diagnosis of acute myocardial infarction was accepted only if all of the following were present: typical chest pain for more than 30 minutes, increased serum creatine kinase and development of abnormal q waves on electrocardiography. The period from acute myocardial infarction to coronary revascularization ranged from 1 month to 4 years (mean: 9 months). The period from coronary revascularization to postoperative echocardiography and thallium scintigraphy studies ranged from 23 to 57 days (mean: 36 days).

Exercise testing thallium-201 single-photon emission computed tomography (SPECT)

All patients underwent exercise testing on a 25 W/3 min graded bicycle ergometer. In the tests before and after revascularization, they were exercised to a symptom-limited end point and/or ischemic ST-segment depression (>2 mm, horizontal or downward sloping) on the electrocardiogram. A dose of 111 MBq (3 mCi) of thallium-201 was given intravenously, followed by a 10 ml/saline flush, when the patient reached at the end point of the exercise test.

Exercise was continued for an additional 60 seconds if symptoms, electrocardiographic changes and blood pressure were stable. A StarCam (General Electric; Milwaukee, USA) was used for data acquisition and analysis. Thirty-two planar acquisitions were performed for 30 seconds each over a 180-degree arc extending from the 45-degree right anterior oblique to the 45-degree left posterior oblique projection. The initial stress image acquisitions were performed within 10 min after tracer injection, and delayed imaging was obtained 180 min later. Using a filtered back projection, transaxial slices (6 mm thick) were reconstructed parallel to the vertical and horizontal long axes and the short axis of the left ventricle. Both stress and delayed SPECT images were evaluated visually by three experts without patients' information, and the severity of the perfusion defect was classified into four grades as follows:

grade 0=complete defect; grade 1=severe hypoperfusion; grade 2=mild hypoperfusion; grade 3=no defect (normal).

Bull's-eye display and semi-quantitative analysis

A bull's-eye polar map was constructed by the method described by Depasquale et al.⁷ The maximal count density was measured in 9° wedges extending 360° around each short axis. Tomographic slices were plotted with rectangular coordinates, and these profiles were then reconstructed on polar coordinates (the bull's-eye display). Profiles were plotted concentrically, with the apical profile at the center of the bull's-eye and the basal profile at the periphery. Fifteen layers were created on the bull's-eye display, the first and 15th layers corresponding to the apex (center) and base (periphery), respectively. We considered the 3rd+4th, 8th+9th, and 13th+14th layers to represent the apex, mid-portion, and base, respectively. A 45° area of these two layers nearest to the center of the perfusion defect was designated as the region of interest (ROI) (Fig. 1). This ROI corresponded to 1/60 of the total left ventricle on the bull's-eye display. By comparing Emory's normal file for each ROI on the bull's-eye display, the severity of the perfusion defect was represented as a standard deviation value, and graded as follows: grade 0 \leq mean - 5SD, grade 1 = mean - 5SD \sim mean - 3SD, grade 2 = mean - 3SD \sim mean - 2SD, grade 3 \geq mean - 2SD (normal).

Two-dimensional echocardiography

An ultrasonic apparatus, Model Toshiba SSH-60A or SSH-160A, was used for two-dimensional echocardiography, and the parasternal short axial view on expiration in the left semi-recumbent position was recorded on videotape. The regional wall motion was evaluated visually by three experts, and the

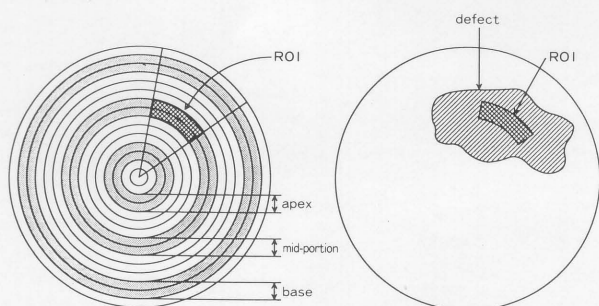


Fig. 1 Creation of ROI on a bull's-eye display. A 45° area of the apex, mid-portion, or basal layers nearest to the center of the defect was designated as the ROI.

Table 1 Comparison between visual and semi-quantitative evaluation of preoperative thallium grade

		thallium grade (semi-quantitative)			
		0	1	2	3
thallium grade (visual)	3 : normal				3
	2 : mild hypoperfusion		5	12	2
	1 : severe hypoperfusion	5	14		
	0 : defect	8	1		

$r = 0.86$ $p < 0.01$

Table 2 Comparison between visual and semi-quantitative evaluation of preoperative grade of wall motion

		wall motion grade (semi-quantitative)			
		0	1	2	3
wall motion grade (visual)	3 : normal			3	8
	2 : hypokinesis		2	15	1
	1 : akinesis	2	7	2	
	0 : dyskinesis	8	1		

$r = 0.86$ $p < 0.01$

Table 3 Relationship between preoperative thallium image and wall motion

		wall motion grade (quantitative)			
		0	1	2	3
thallium grade (quantitative)	3			4	1
	2	2	3	4	3
	1	4	7	7	2
	0	4	1	5	3

$r = 0.14$ NS

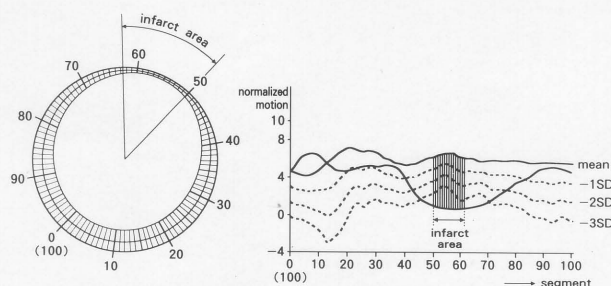


Fig. 2 Centerline method in the short axial view on two-dimensional echocardiography. Normalized motion in the 13 chords at the center of the infarcted area (left) was compared with the normal file, and a grading system of 1 to 4 was created (right).

Table 4 Relationship between postoperative improvement in thallium image and wall motion

		wall motion	
		improved	unimproved
thallium	improved	10	11
	unimproved	8	10

NS

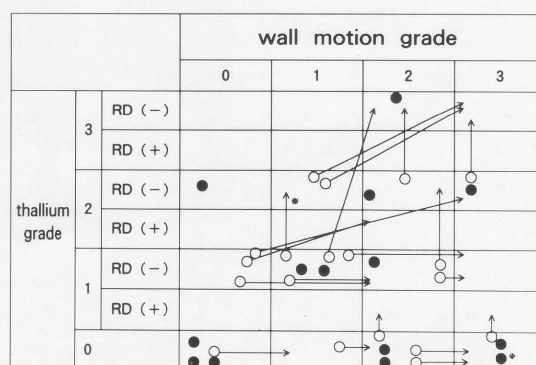
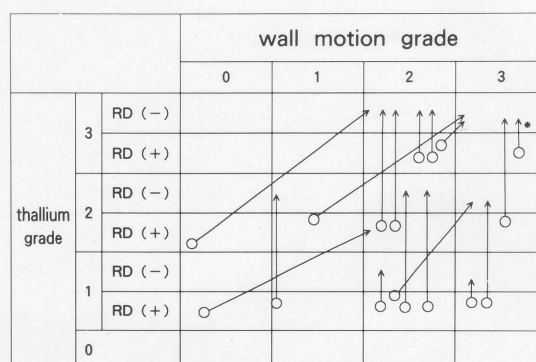


Fig. 3 Changes in thallium delayed image and wall motion before and after revascularization. Upper, cases with redistribution; lower, cases without redistribution. RD: redistribution, ○: cases with improvement, ●: cases without improvement.

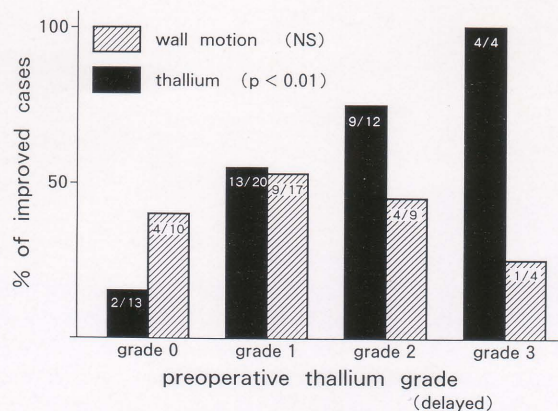


Fig. 4 Relationship between the preoperative grades of thallium delayed image and % of postoperative improved cases in thallium image and wall motion.

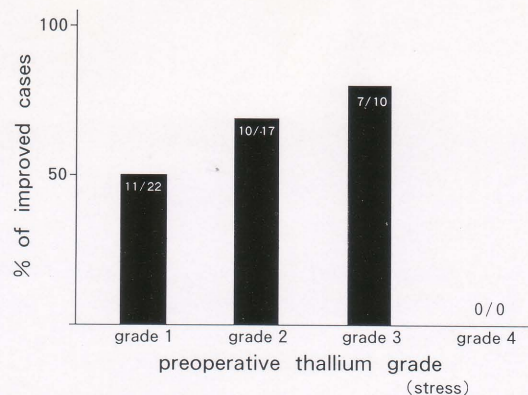


Fig. 5 Relationship between the preoperative grades of thallium stress image and % of postoperative improved cases in thallium image.

Table 5 Relationship between the preoperative grades of wall motion and % of postoperative improved cases in wall motion and thallium image

	preoperative Wall motion			
	grade0	grade1	grade2	grade3
wall motion improved cases (%)	6/10 (60%)	7/10 (70%)	5/20 (25%)	0/0
thallium improved cases (%)	4/10 (40%)	6/11 (55%)	12/19 (63%)	6/9 (67%)

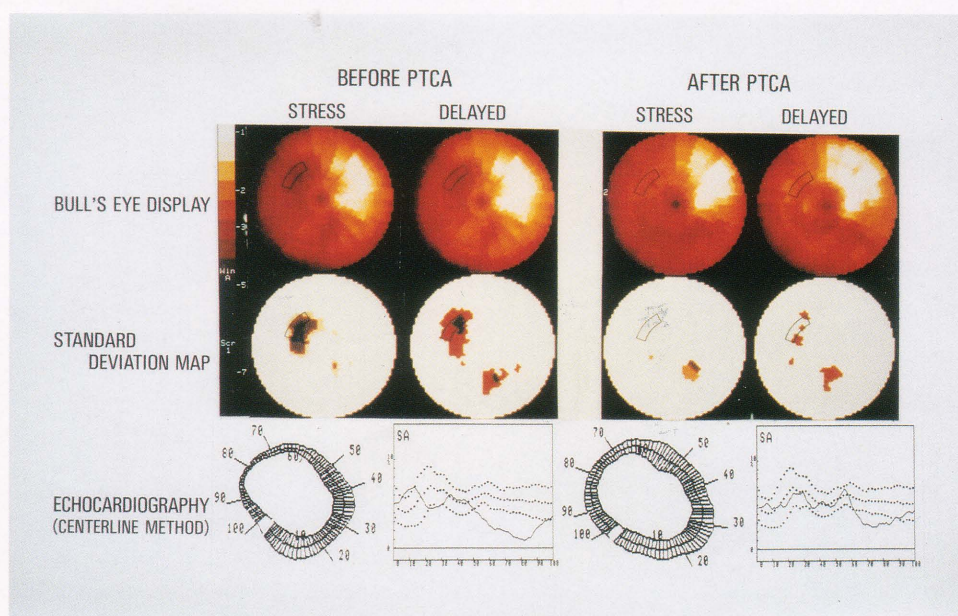


Fig. 6 A representative picture of a case demonstrating postoperative improvement in both thallium image and wall motion.

severity was classified into four grades as follows: grade 0=dyskinesis; grade 1=akinesis; grade 2=hypokinesis; grade 3=normal.

For semi-quantitative computer analysis, Mipron (Kontron Elektronik; München, Germany) was used. Analysis by means of the centerline method was described by Sheehan et al.⁸ In each of the parasternal short axial slices at the level of the mitral valve, papillary muscle and apex, the end-diastolic and end-systolic left ventricular contours and the centerline were constructed midway between the two contours by the computer. The regional wall motion, measured along 100 chords constructed perpendicular to the centerline, was normalized at each chord by the end-diastolic perimeter to yield a shortening fraction. The "normalized motion" was then obtained with the following formula:

$$\text{normalized motion} = \frac{\text{length of wall motion}}{\text{length of end-diastolic perimeter}}$$

The location of the echocardiographic short axis slice was adjusted to the bull's-eye display, considering the starting point of the right ventricular free wall from the left ventricle. Each normalized motion was compared with the normal file in 13 continuous chords corresponding to the ROI on the bull's-eye display and graded by the mean value for SD as follows: grade 0 \leq mean - 3SD; grade 1 = mean - 3SD \sim mean - 2SD; grade 2 = mean - 2SD \sim mean - 1SD; grade 3 \geq mean - 1SD (normal) (Fig. 2).

Judgment of postoperative improvement

We assume that the infarcted myocardium is viable if one or more of the following is satisfied postoperatively: 1) improvement by one grade or more in the grading of wall motion by echocardiography, 2) improvement by one grade or more in the grade of myocardial perfusion by thallium delayed image, 3) no change in the grade of thallium delayed image postoperatively, but disappearance of the transient perfusion defect (redistribution) on exercise at a level similar to before revascularization. We established the following indices for preoperative evaluation of the myocardial viability: redistribution of the thallium image, grade of thallium uptake (stress and delayed image), and grade of wall motion by echocardiography. These factors were then studied for their ability to predict postoperative improvement. The evaluation of redistribution was considered significant if the thallium uptake improved by one grade or more, when the stress and the delayed images were compared.

Statistics

The chi-square test was used to evaluate the relation-

ship between each index and postoperative improvement, and Spearman's rank correlation coefficient was used to evaluate the relationship between the visual and semi-quantitative judgments, and between the scintigraphic and echocardiographic methods. A p value of <0.05 was considered significant.

RESULTS

Comparison of semi-quantitative and visual analysis of thallium image and wall motion

Good correlations were found when the semi-quantitative preoperative thallium image and wall motion by compared with visual evaluation yielding coefficients of correlation of 0.86 ($p < 0.01$) and 0.86 ($p < 0.01$), respectively (Tables 1, 2). However, no relationship was found between the grade of the preoperative thallium image and wall motion ($r = 0.14$, Table 3), or between the grade of postoperative improvement in thallium image and that of wall motion (Table 4). The changes in thallium delayed image and wall motion after revascularization in all subjects are shown in Fig. 3. In the study of improvement in postoperative wall motion, echocardiography was evaluated only in 40 areas, excluding seven cases in which preoperative wall motion was normal and three cases in which the recording was poor. The postoperative thallium grade improved in 28 of the 50 revascularized areas, and the postoperative grade of wall motion improved in 12 of 40 revascularized areas.

Preoperative redistribution and postoperative improvement in thallium image and wall motion

The thallium image improved postoperatively in all 17 areas which exhibited redistribution of the 49 revascularized areas. Judgement was impossible for one area preoperatively. However, 11 of 32 areas which did not show redistribution also showed improvement. The sensitivity, specificity, and accuracy of preoperative thallium redistribution for predicting myocardial viability were 61%, 100% and 78%, respectively, when postoperative thallium improvement was used as the standard. When postoperative improvement of wall motion was used as the standard, sensitivity was 28%, specificity was 64% and accuracy was 48%.

Preoperative thallium grade and postoperative improvement in thallium image and wall motion

Although any grade of thallium delayed image could improve (Fig. 4), the probability of postoperative improvement with thallium perfusion increased in proportion to the preoperative thallium delayed image with $p < 0.01$. However, postoperative improvement in thallium findings could not be predicted

from preoperative thallium stress image (Fig. 5). Also, there was no correlation between the preoperative thallium delayed image and postoperative improvement in wall motion (Fig. 4).

Preoperative wall motion and postoperative improvement in the thallium image and wall motion

Cases with preoperative wall motion of grade 1 showed the highest rate of improvement (70%) in wall motion. There was no correlation between preoperative wall motion and postoperative improvement in wall motion. Postoperative improvement tended to increase in proportion to the preoperative wall motion, but not with statistical significance (Table 5).

Case example

A 42-year-old male underwent PTCA of the left anterior descending artery (segment 6) with reduction of the target vessel stenosis from 90% to 50%. The thallium image improved from grade 1 (no redistribution) to grade 3, and wall motion improved from grade 1 to grade 2 (Fig. 6).

DISCUSSION

Thallium-201 myocardial scintigraphy, as an imaging method representing blood flow, has been widely used for diagnosis of ischemic heart disease and for evaluation of myocardial damage.^{9,10} It is also used for evaluation of myocardial viability before coronary revascularization^{2,3} and in postoperative follow-up of patients with ischemic heart disease.¹¹⁻¹⁵ The development of equipment and software has led to marked improvement in the validity of the diagnosis of ischemic heart disease by means of myocardial SPECT.¹⁶ Recently, thallium-201 myocardial scintigraphy results have been displayed as polar maps (bull's-eye display),⁷ which have the advantages of displaying the entire myocardium as a single image and of permitting selection of spatial regions of interest (ROI). Since contrast left ventriculography and two-dimensional echocardiography have been studied by the centerline method,⁸ wall motion can now be evaluated and compared in detail. However, minor changes without clinical significance can be overestimated by quantitative methods of thallium scintigraphy such as circumferential profile analysis¹⁷ and washout rate.⁵ Conversely, visual judgment by the conventional method is not always objective. Therefore, a semi-quantitative method using simple grading would be advantageous from the standpoint of both clinical usefulness and objectiveness. We therefore compared the results of visual and semi-quantitative judgment of the thallium image and wall motion, and found high correlations of $r=0.86$ (thallium image)

and $r=0.86$ (wall motion). The semi-quantitative method is especially valuable when visual judgment is difficult, as in borderline cases. On the other hand, the preoperative thallium grade did not agree with the grade of wall motion, and there was no correlation between postoperative improvement in the thallium image and wall motion (Table 3, 4). This lack of correlation may have arisen from subtle differences in position between the bull's-eye display and two-dimensional echocardiography, and also because of the delay of up to several months until improvement appears in the thallium image.¹⁸ However, these differences could be expected since the two methods examine different phenomena.

Next, we examined the relationships between myocardial viability and preoperative redistribution, thallium image and wall motion, separately. The myocardium in the infarcted area may not be in a state of complete fibrosis or necrosis, and it may include sections of intermingling viable myocardium. Improvement could be recognized in clinical cases if such myocardium could be revascularized.¹⁹ Thus, CABG and PTCA have been actively performed not only in cases of angina, but also in cases of previous myocardial infarction. On the other hand, the myocardial blood flow recorded by thallium-201 scintigraphy and wall motion determined by echocardiography have been studied to obtain an objective standard of myocardial viability. However, there has been no study of the same subjects by more than one method. This led us to assess the preoperative myocardial viability by means of both thallium scintigraphy with a bull's-eye display and echocardiography with the centerline method, in a semi-quantitative grading system. The "redistribution" has been used as an index of myocardial viability for decisions on indications for CABG and PTCA.^{1,2,3} However, some patients with myocardial infarction but without redistribution have undergone coronary revascularization for clinical reasons, i.e., refractory chest pain, heart failure and poor exercise tolerance, and sometimes showed postoperative improvement even in myocardium without redistribution, as reported by Gibson et al.⁶ and Liu et al.⁴ The latter report attributes the phenomenon caused to delayed redistribution which could not be detected within 3 hours. However, a clear delayed image could not be obtained for more than several hours. Although repeating thallium imaging at rest would be ideal, its high cost and the exposure of the patient to radiation are disadvantageous. In our study, all 17 areas with redistribution showed improvement irrespective of the grades of thallium delayed image and wall motion, and moreover, 11 of 32 areas (34%) without redistribution also showed improvement. With the thallium image, lack of postoperative improvement

was difficult to predict in myocardium not showing redistribution. Improvement in wall motion could not be predicted since it was not related to preoperative redistribution. We propose the following mechanisms for the improvement in the myocardium without redistribution; 1) deconditioning caused by long-term recumbency, 2) late redistribution²⁰, 3) underestimation of myocardial viability²¹ in thallium scintigraphy.

These findings show that myocardial viability should not be evaluated from the redistribution alone. Thus, it is important to clarify the usefulness of thallium-201 exercise scintigraphy, especially in cases without redistribution. We used the thallium delayed image, which may be nearly equal to the resting image regardless of redistribution. As a result, the probability of postoperative improvement in thallium perfusion increased in proportion to the preoperative thallium delayed image, as shown in Fig. 4. The borderline between the viable and non-viable myocardium cannot be decided only from these results, for all thallium grades have the possibility of improvement. However, thallium delayed image can be applied to predict the probability of postoperative improvement.

The thallium stress image and wall motion showed no statistical significance in their ability to predict improvement in thallium, although they were able to indicate tendencies, as shown in Fig. 5. These findings suggest that the thallium stress image represents not myocardial viability, but myocardial blood flow or exercise-induced ischemia. Wall motion may be influenced by many factors, such as afterload, preload, myocardial stunning and hibernation, in addition to myocardial blood flow. In addition to this, it was considered that the thallium image and wall motion showed improvement in different phases after coronary revascularization. So a difference between the thallium image grade and the wall motion grade is quite probable. We believe that the standard of myocardial viability was postoperative improvement in thallium image and/or wall motion, and each method should be analyzed separately in such a study.

When myocardial damage was classified into "extent" and "severity," this study evaluated improvement in the severity at the center of the infarcted area. Our data on severity indicated that the thallium grade was superior to the wall motion grade as an index of myocardial viability, but the thallium grade and wall motion grade could not be predicted by each other. Improvement in extent was not assessed, since the bull's-eye display does not represent the correct area. Thus the study (including wall motion) presents a very intriguing field for future research. Interestingly, the thallium grade improved postoperatively even in two cases for which the initial rating was

grade 0 without redistribution. This indicated that sometimes viable myocardium cannot be detected by thallium scintigraphy alone.

We concluded that (1) postoperative improvement in the thallium image can be anticipated if redistribution is present in the preoperative thallium image, (2) the probability of improvement in the thallium image increases in proportion to the preoperative thallium delayed image, and (3) improvement in wall motion cannot be predicted preoperatively.

REFERENCES

1. Strauss HW: Thallium redistribution: Mechanisms and clinical utility. *Semin Nucl Med* 10: 70-93, 1980
2. Rozanski A, Berman DS, Gray R, et al: Use of thallium-201 redistribution scintigraphy in the preoperative differentiation of reversible and non-reversible myocardial asynergy. *Circulation* 64: 936-944, 1981
3. Pohost GM, Zir LM, Moore RH, et al: Differentiation of transiently ischemic from infarcted myocardium by serial imaging after a single dose of thallium-201. *Circulation* 55: 294-301, 1977
4. Liu P, Kiess MC, Okada RD, et al: The persistent defect on exercise thallium imaging and its fate after revascularization: does it represent scar or ischemia? *Am Heart J* 110: 996-1001, 1985
5. Naruse H, Ohyanagi M, Iwasaki T, et al: Indications for coronary revascularization and the postoperative evaluations using thallium-201 exercise myocardial scintigraphy and a bull's eye display. *Am J Noninvas Cardiol* 4: 352-357, 1990
6. Gibson RS, Watson DD, Taylor GJ, et al: Prospective assessment of regional myocardial perfusion before and after coronary revascularization surgery by quantitative thallium-201 scintigraphy. *J Am Cardiol* 1: 804-815, 1983
7. Depasque EE, Nody AC DePuey, et al: Quantitative rotational thallium-201 tomography for identifying and localizing coronary artery disease. *Circulation* 77: 316-327, 1988
8. Sheehan FH, Bolson EL, Dodge HT, et al: Advantages and applications of the centerline method for characterizing regional ventricular function. *Circulation* 74: 293-305, 1986
9. Rigo P, Bailey IK, Griffith LSC, et al: Value and limitation of segmental myocardial imaging for localization of coronary artery disease. *Circulation* 61: 973-981, 1980
10. Ritchie JL, Trobaugh GB, Hamilton GW, et al: Myocardial imaging with thallium-201 at rest and during exercise. Comparison with coronary arteriography and resting and stress electrocardiography. *Circulation* 56: 66-71, 1977
11. Kolibash AJ, Call TD, Bush CA, et al: Myocardial perfusion as an indication of graft patency after coronary bypass surgery. *Circulation* 61: 882-887, 1980

12. Shabaro JA, Karunatne H, Cantez S, et al: Thallium-201 imaging in assessment of aortocoronary bypass graft patency. *Br Heart J* 42: 552-561, 1979
13. Scholl JM, Chaitman BR, David PR, et al: Exercise electrocardiography and myocardial scintigraphy in the serial evaluation of the results of percutaneous transluminal coronary angioplasty. *Circulation* 66: 380-399, 1982
14. Hirzel HO, Nuesch K, Gruenzig AR, et al: Short and long term changes in myocardial perfusion after percutaneous transluminal coronary angioplasty assessed by thallium-201 exercise scintigraphy. *Circulation* 63: 1001-1007, 1981
15. Wainwright RJ, Brennaud-Roger DA, Maisey MN, et al: Exercise thallium-201 myocardial scintigraphy in the follow up of aortocoronary bypass graft surgery. *Br Heart J* 43: 56-66, 1980
16. Goodwin PN: Recent developments in instrumentation for emission computed tomography. *Semin Nucl Med* 10: 322-334, 1980
17. Burow RD, Pond M, Schafer AW, et al: "Circumferential profiles: "A new method for computer analysis of thallium-201 myocardial perfusion images. *J Nucl Med* 20: 771-777, 1979
18. Manyari DE, Knudtson M, Kloiber R, et al: Sequential thallium-201 myocardial perfusion studies after successful percutaneous transluminal coronary angioplasty: delayed resolution of exercise-induced scintigraphic abnormalities. *Circulation* 77: 86-95, 1988
19. Bodenheimer MM, Banka VS, Hermann GA, et al: Reversible asynergy. Histopathologic and electrocardiographic correlations in patients with coronary artery disease. *Circulation* 53: 792-796, 1976
20. Gutman J, Berman DS, Freeman M, et al: Time to complete redistribution of thallium-201 in exercise myocardial scintigraphy: Relationship to the degree of coronary artery stenosis. *Am Heart J* 106: 989-995, 1983
21. Tamaki N, Yonekura Y, Senda M, et al: Value and limitation of stress thallium-201 single photon emission computed tomography: Comparison with nitrogen-13 ammonia positron tomography. *J Nucl Med* 29: 1181-1188, 1988