

Physiologic capacity of well-developed collaterals in patients with isolated left anterior descending artery disease

Kazuyuki SAKATA,* Hiroshi YOSHIDA,* Norihisa ONO,* Seiji OHTANI,* Noriko MORI,*
Shoichi YOKOYAMA,* Tsuneo HOSHINO,* Tsuneo KABURAGI* and Chinori KURATA**

**Department of Cardiology, Shizuoka General Hospital*

***The Third Department of Internal Medicine, Hamamatsu University School of Medicine, Shizuoka, Japan*

To assess the physiologic significance of well-developed collaterals, 34 patients, with isolated left anterior descending artery disease (LAD) and without overt prior myocardial infarction, underwent cardiac catheterization and exercise thallium-201 emission computed tomography. The patients were divided into 3 groups; 11 patients with 90% stenosis of the proximal LAD and without collaterals (group 1), 11 with 99% stenosis of the proximal LAD, and without collaterals (group 2) and 12 with a total occlusion of the proximal LAD which was completely filled by well-developed collaterals (group 3). On left ventriculography, shortening fractions of the anterior wall were significantly reduced in group 2 as compared to group 1 and 3 (group 1 vs group 2: $p < 0.01$, group 2 vs group 3: $p < 0.05$), which reflected the lower ejection fraction of group 2 ($p < 0.01$ and $p < 0.05$, respectively). The perfusion defects of the anterior wall on both the initial and the delayed images were severer in groups 2 and 3 than in group 1 (group 1 vs group 2 and group 1 vs group 3 on the initial image: $p < 0.01$, for both, group 1 vs group 2 and group 1 vs group 3 on the delayed image: $p < 0.05$, for both). However, recovery of the perfusion defects from the initial image to the delayed image was better in group 3 than in groups 1 and 2 (group 1 vs group 2 and group 1 vs group 3: $p < 0.05$, for both). Therefore, coronary blood flow through well-developed collaterals was considered to be comparable to the flow through a diseased vessel with 90% stenosis at rest. During maximal exercise, blood flow through well-developed collaterals was considered to be comparable to the flow through a diseased vessel with 99% stenosis, although the blood flow through well-developed collaterals was considered to be better than that through 99% stenosis during the recovery period. These findings suggest that patients with well-developed collaterals must be treated like those with severe stenosis.

Key words: well-developed collaterals, exercise thallium-201 scintigraphy

INTRODUCTION

THE PHYSIOLOGICAL importance of collateral vessels has been emphasized in preserving the left ventricular function after acute myocardial infarction,¹⁻⁴ in preventing myocardial ischemia at rest^{5,6} and exercise-induced ischemia,^{1,6-8} although some studies

on the role of collateral vessels visualized at angiography have produced conflicting results. The collateral vessels bringing about these beneficial effects on the heart are, in large part, well-developed collaterals. Therefore, it is important to evaluate the functional capacity of well-developed collateral vessels and the coronary blood flow delivery to the compromised myocardium through well-developed collaterals.

As pointed out by several investigators,^{6,9,10} several factors such as the number of diseased vessel, prior myocardial infarction or the degree of stenosis of the diseased artery, make the functional role of

Received August 14, 1991, revision accepted November 15, 1991.

For reprints contact: Dr Kazuyuki Sakata, The Department of Cardiology, Shizuoka General Hospital, 4-27-1 Kitaando, Shizuoka 420, Japan.

collateral vessels unclear. Therefore, adequate patient selection is critical in a study on the functional role of collateral vessels. In the present study, we selected patients with isolated left anterior descending artery (LAD) disease and no overt evidence of prior myocardial infarction. To determine the physiologic capacity of well-developed collaterals, we compared patients with a total obstruction of the LAD, which was completely filled by well-developed collaterals, to patients with significant stenosis of the LAD without collaterals.

METHODS

Patient

Thirty-four patients (28 men and 6 women) with single coronary arterial stenosis equal to or greater than 90% of the luminal diameter in the proximal LAD and no prior myocardial infarction, were included in the present study. All patients underwent coronary angiography, left ventriculography and stress-redistribution thallium-201 myocardial scintigraphy. They were divided into three groups. Table 1 summarizes the patients' characteristics. Group 1 consisted of 11 patients who had 90% stenosis of the proximal LAD and without angiographically visualized collaterals. Group 2 consisted of 11 patients who had 99% stenosis of the proximal LAD without angiographically visualized collaterals. Group 3 consisted of 12 patients with a total occlusion of the proximal LAD which was completely filled by well-developed collaterals from the right coronary artery.

Cardiac catheterization

All patients underwent cardiac catheterization by the Sones or Judkins technique. Coronary angiography in multiple projections and left ventriculography in the right anterior oblique projection were performed at a filming rate of 30 or 60 frames/sec. Before coronary angiography, a 0.3 mg dose of sublingual nitroglycerin was given. A consensus of opinion of three observers, who were given no information regarding the clinical data, was taken for visual assessment of both the severity of the stenosis and the extent of collateralization. On angiography, well-developed collaterals were defined as the complete filling of the epicardial segment via collateral vessels. The degree of stenosis of the LAD was expressed as 90%, 99% (hair-line) and 100% according to the AHA classification.¹¹ Left ventriculography was analyzed by the centerline method.¹² Two left ventricular silhouettes (end-diastole and end-systole) were traced with a sonic digitizing device by an observer who was unaware of the data from coronary angiography. The left ventricular volumes were calculated by a modification of the formula of

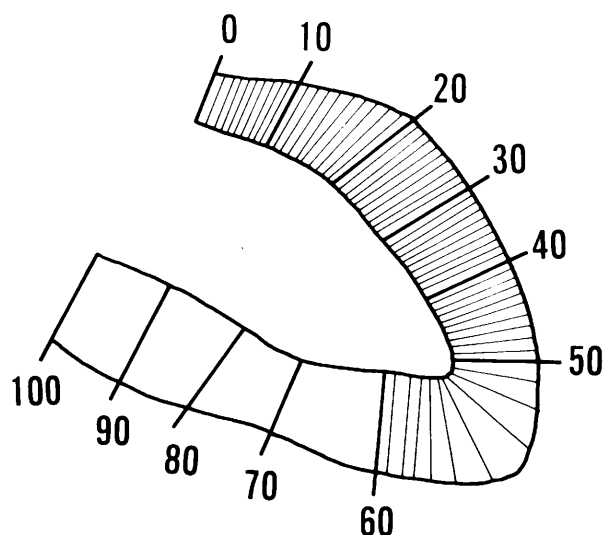


Fig. 1 The regional wall motion of the left ventricle was analyzed by the centerline method. The left ventricle was divided into 100 chords. Sixty chords (1–60) of 100 chords were considered to represent the segmental motion of the anterior wall. The shortening fraction (chord length \times 100/end diastolic perimeter) was calculated. Location of the heart is shown as follows: No. 1–20, anterobasal; No. 21–40, anterolateral; No. 41–60, apical.

Kennedy et al.¹³ As shown in Figure 1, wall motion was measured along 100 chords constructed perpendicular to a centerline drawn midway between the end-diastolic and end-systolic contours. The measured motion of the 100 chords was normalized for the heart size by dividing by the length of the end-diastolic perimeter, which resulted in a dimensionless shortening fraction. Of the 100 chords, 60 chords (No. 1 to No. 60) in the anterior segment were used to denote the wall motion of the LAD territory, which were divided into 3 segments: basal anterior (No. 1 to No. 20), anterolateral (No. 21 to No. 40) and apical segments (No. 41 to No. 60). Regional wall motion was considered to be normal when every dimensionless shortening fraction was within the mean \pm 2SD of that of the corresponding area, which was calculated from 15 normal subjects (8 men and 7 women).

Myocardial scintigraphy

Symptom-limited treadmill exercise thallium-201 emission computed tomography (TI-201 ECT) employing the Bruce protocol was performed in a fasting state within 2 weeks of cardiac catheterization. All medications were discontinued at least 12 hours before the study with the exception of sublingual nitroglycerin for relief of chest pain. Standard 12-lead ECG and blood pressure were recorded at rest, every 3 minutes and at peak exercise during exercise, and every minute after exercise. The exercise

end points included chest pain, dyspnea, leg fatigue, hypotension, or frequent ventricular arrhythmia. At peak exercise, 111 MBq of Tl-201 was injected intravenously and patients were encouraged to continue exercising for an additional minute. Criteria for significant ST depression were horizontal or downsloping depression of 0.1 mV or more or junctional depression of 0.2 mV or more for 0.08 seconds after the J point in more than 3 contiguous beats in comparison with the resting ECG. To rule out the presence of prior myocardial infarction, all patients in group 3 performed rest-redistribution Tl-201 ECT in a fasting state within 2 weeks after cardiac catheterization.

Myocardial images were obtained with a large field-of-view rotating gamma camera (SNC 500R, Shimadzu) equipped with a high resolution, parallel-hole collimator and interfaced with a computer system (Scintipac 700, Shimadzu). Thirty-two projections over 180 degrees from the 45-degree right anterior oblique position to the 45-degree left posterior oblique position were recorded using a 64×64 matrix with a 38 cm field of view for 30 seconds per image. Initial imaging was begun within 5 minutes after completion of the exercise or Tl-201 injection at rest. Delayed images were obtained 4 hours after injection. No attenuation or scatter correction was used. Orthogonal images were generated by oblique-angle reconstruction producing vertical long-axis, short-axis, and horizontal long-axis slices, each 6 mm thick.

Analysis of Tl-201 ECT

Visual analysis of the myocardial perfusion defect was performed with the method previously described.¹⁴ The vertical long-axis slice was divided into 3 segments, the basal and apical short-axis

slices were each divided into 4 segments and the horizontal slice was divided into 5 segments (Fig. 2). Of the total 9 segments, 5 segments were defined as the LAD territory. In both the initial and delayed images, the uptake score of Tl-201 was visually determined for each of the total of 5 segments according to a four-point scoring system: 3=normal, 2=mildly reduced, 1=moderately reduced, and 0=markedly reduced. When a segment had an abnormal washout rate which was defined as less than 2SDs below the mean normal value obtained from 15 normal subjects and its uptake score had increased from the initial image to the delayed image, we defined the segment as a transient defect, which was interpreted as that representing exercise-induced ischemia. In each patient with a transient defect, we calculated the Δ visual uptake score by subtracting the total uptake score for 5 segments in the initial image from the total uptake score for the corresponding 5 segments in the delayed image to assess the severity of exercise-induced ischemia and the degree of recovery from exercise-induced ischemia. Each set of initial and delayed images was read independently by two experienced observers without other clinical or catheterization information. Visual assessment of Tl-201 uptake in the 556 myocardial segments by two experienced observers in our laboratory showed an interobserver agreement of 87% for identical grading of the severity of thallium-201 perfusion defects and 83% for identical grading of the degree of changes from initial to delayed images. Final readings reported represent total agreement or a consensus opinion of the two observers.

No evidence of prior myocardial infarction

In the present study, all patients were considered to have had no prior myocardial infarction. Prior

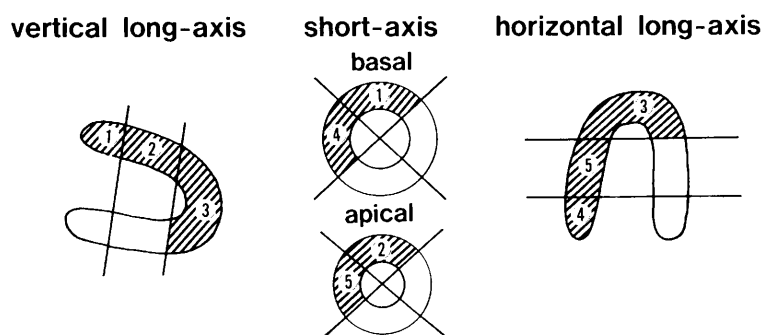


Fig. 2 Segment of thallium-201 emission computed tomographic images for visual analysis. The vertical long axis image was divided into five segments. Two short-axis images obtained from basal and apical portions of the heart were divided into eight segments. The horizontal long axis was divided into five segments. Five of the nine segments were considered to represent the left anterior descending artery territory. Numbers on each image show the location of the heart as follows: 1, basal anterior; 2 mid anterior; 3, apical; 4, basal septal; 5, mid septal.

infarction was considered absent when no significant Q waves or ST-T changes were present on the ECG and the shortening fraction which represented the regional wall motion was within the mean \pm 2.5SD of that for the 15 normal subjects, and no history of chest pain with a duration of 20 minutes or more was documented. In addition, all patients in group 3 had normal delayed images on rest-redistribution myocardial scintigraphy.

Statistics

All results are expressed as the mean \pm SD. Statistical comparisons were performed by a one-way analysis of variance and appropriate t-test. Fisher's exact test was also used to determine the significance of difference in observed rates of occurrence when appropriate. Statistical significance was assigned to the $p < 0.05$ level.

RESULTS

Group characteristics

The mean age, prevalence of the type of angina on admission and coronary risk factors, and the time interval between the onset of anginal pain and admission were similar in all 3 groups (Table 1).

Hemodynamics and global left ventricular function

Table 2 shows the hemodynamics and global left ventricular function at cardiac catheterization. There were no significant differences in heart rate, end-diastolic pressure and cardiac index in the 3 groups. The left ventricular end-diastolic and end-systolic

volumes were also similar for the 3 groups. The left ventricular ejection fraction was significantly lower in group 2 than in groups 1 and 3 (group 2 vs group 1; $p < 0.01$, group 2 vs group 3; $p < 0.05$).

Left ventricular wall motion

Figure 3 shows the shortening fraction of antero-basal, anterolateral and apical regions in the 3 groups. In the anterobasal region, the shortening fraction was significantly lower in group 2 ($4.1 \pm 1.1\%$) than in groups 1 ($5.9 \pm 0.5\%$) and 3 ($5.3 \pm 1.0\%$) (group 2 vs group 1: $p < 0.01$, group 2 vs group 3: $p < 0.05$). In the anterolateral region, the shortening fraction was also significantly lower in group 2 ($3.4 \pm 1.3\%$) than in groups 1 ($5.2 \pm 1.4\%$) and 3 ($4.6 \pm 1.3\%$) (group 1 vs group 2: $p < 0.01$, group 1 vs group 3: $p < 0.05$). In the apical region, there was no significant difference in the shortening fraction among the 3 groups.

Exercise TI-201 ECT

Table 3 summarizes the exercise variables in the 3 groups. Although the peak heart rate was significantly lower in group 3 than in group 1 ($p < 0.05$), there were no differences in peak systolic pressure, systolic pressure-rate product and exercise duration among the 3 groups. The frequencies of chest pain and ischemic ST changes were similar among the 3 groups. Figure 4 shows changes in the visual uptake score on the initial and delayed images for the 3 groups. The visual uptake score in the initial image was much higher in group 1 (10.3 ± 4.1) than in group 2 (3.4 ± 3.6) and group 3 (2.2 ± 3.3) (group 1

Table 1 Group characteristics

Group	Age (year-old)	Type of angina			Risk factor					Duration of angina (month)
		Rest (n)	Effort (n)	Unstable (n)	SM (n)	DM (n)	FH (n)	HL (n)	HU (n)	
Group 1	58 ± 10	4	9	4	4	6	3	3	0	8.2 ± 8.6
Group 2	65 ± 8	4	11	6	4	5	2	7	0	14.5 ± 28.9
Group 3	60 ± 7	3	12	4	4	3	3	6	0	19.8 ± 30.6

Abbreviations. SM, smoking; DM, diabetes Mellitus; FH, family history; HL, hyperlipidemia; HU, hyperuricemia. Values are expressed as the mean \pm SD.

Table 2 Hemodynamics and global left ventricular function

Group	HR (beats/min)	CI (L/min m ²)	LVEDP (mmHg)	LVEDV (ml/m ²)	LVESV (ml/m ²)	EF (%)
Group 1	70 ± 10	3.0 ± 0.4	10 ± 2	100 ± 16	30 ± 13	$71 \pm 7^*$
Group 2	72 ± 11	3.1 ± 0.9	10 ± 6	91 ± 23	30 ± 13	62 ± 2
Group 3	70 ± 8	2.9 ± 0.5	12 ± 3	111 ± 19	34 ± 14	$68 \pm 4^\dagger$

Abbreviations. HR, heart rate; CI, cardiac index; LVEDP, left ventricular end-diastolic pressure; LVEDV, left ventricular end-diastolic volume; LVESV, left ventricular end-systolic volume; EF, ejection fraction. * $p < 0.01$, $^\dagger p < 0.05$ as compared to Group 2. Values are expressed as the mean \pm SD.

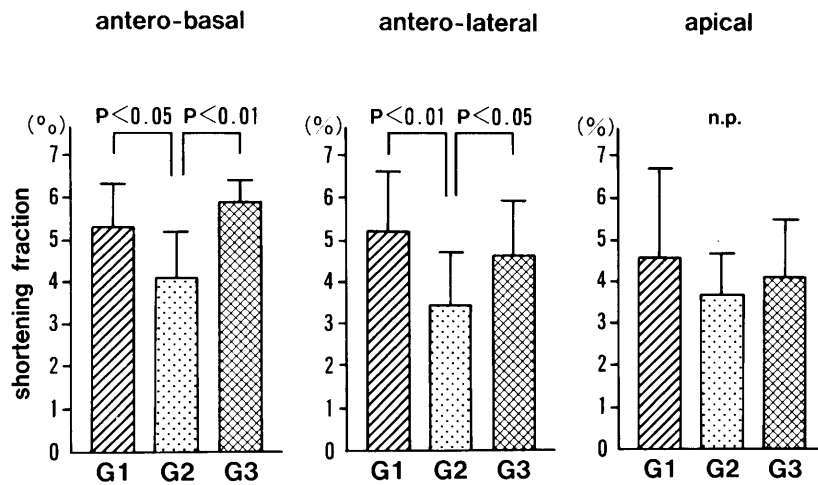


Fig. 3 Comparison of the shortening fraction in the anterior wall in the three groups.

Table 3 Results of exercise testing

Group	Peak HR (beats/min)	Peak systolic BP (mmHg)	Peak PRP (mmHg·beats/min)	Exercise duration (sec)	Ischemic ST change (n)	Chest pain (n)
Group 1	150±15	181±20	26,899±4,154	462±165	5	6
Group 2	136±20	173±25	23,739±5,489	358±97	8	8
Group 3	134±14*	189±25	24,977±3,385	350±103	5	10

Abbreviations. HR, heart rate; BP, blood pressure; PRP, systolic blood pressure-rate product.

*p<0.05 as compared to Group 1. Values are expressed as the mean±SD.

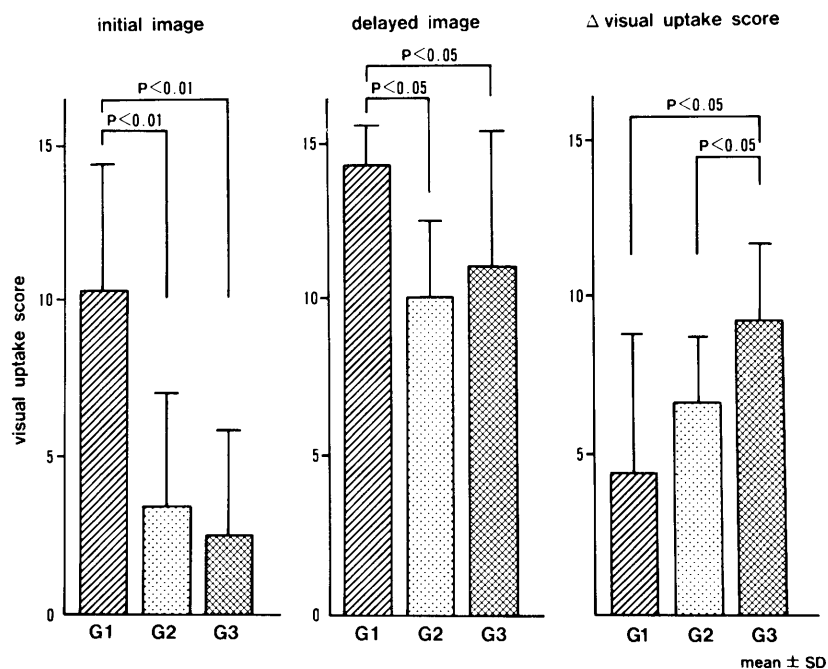


Fig. 4 Comparison of visual uptake score in the three groups.

vs group 2: $p < 0.01$, group 1 vs group 3: $p < 0.05$), although no difference between groups 2 and 3 was observed in the visual uptake score in the initial image. Also, the visual uptake score in the delayed image was significantly higher in group 1 (14.3 ± 1.3) than in groups 2 (10.0 ± 2.5) and 3 (11.2 ± 4.4) (group 1 vs group 2 or group 3; $p < 0.05$ for both). There was no difference between groups 2 and 3 in the visual uptake score in the delayed image. In contrast, Δ visual uptake score was significantly higher in group 3 (9.3 ± 2.2) than in group 1 (4.4 ± 4.4) and group 2 (6.6 ± 2.1) (group 3 vs group 1 or group 2: $p < 0.05$, for both). But no difference between groups 1 and 2 was observed in the Δ visual uptake score.

DISCUSSION

In the present study, we selected patients with a total coronary occlusion of the isolated LAD disease without prior myocardial infarction, who, it was suggested, were the optimal subset of patients in which to study human coronary collaterals.^{1,10} These patients had well-developed collaterals from the right coronary artery sufficient to protect them from myocardial infarction.

Clinical aspects of patients with well-developed collaterals

Some investigators^{2,15} emphasized the significance of the duration of anginal pain in the development of collaterals. In an experimental study,⁸ it has been shown that the full development of collateral pathways requires a gradual occlusion. Chilian et al.¹⁶ demonstrated that ischemia, per se, was a sufficient stimulus to induce coronary collateral development. Fujita et al.¹⁵ also suggested that high frequency of pre-infarction angina in patients with post-infarction angina might result in promoting collateral circulation which decreases the infarct size. In the present study, however, no differences in duration from the onset of chest pain and other clinical findings were observed between patients with well-developed collaterals and patients with severe stenosis (99%) and angiographically not visualized collaterals. Freedman et al.⁹ found that at least the duration of angina was similar in the patients with and without collateral flow. Rentrop et al.¹⁷ found that growth of collateral channels occurred after sustained coronary occlusion. On angiography, therefore, it is most likely that the presence of the antegrade flow of the diseased vessel might be reflected in the assessment of the development of collaterals promoted by ischemia and other factors.^{18,19} In addition, all patients with well-developed collaterals had symptoms before admission. Although Gregg et al.¹⁰ suggested that some patients with well-developed collaterals

might be asymptomatic, most patients with a total occlusion of the proximal LAD and well-developed collaterals and without local factors,¹⁴ such as prior myocardial infarction and the less severity of inducible ischemia, had some symptoms in their daily lives. The majority of the patients with a total occlusion of the proximal LAD and well-developed collaterals were therefore considered to be not completely free from myocardial ischemia in their daily lives, even though they had overcome myocardial infarction.

Coronary flow through collaterals at rest

Lambert et al.⁸ have demonstrated that in the normal and collateral-dependent regions perfusion is the same under resting conditions. In the present study, the regional wall motion in left ventriculography showed that patients with a total occlusion and well-developed collaterals had better regional wall motion than patients with 99% stenosis. The regions of depressed wall motion in patients with 99% stenosis were considered to be caused by severe stenosis which could not supply a sufficient blood flow to maintain the integrity of the myocardium and to prevent frequent ischemic insults, resulting in hibernating myocardium. This concept was supported by the fact that 9 of 11 patients in group 2 had significantly improved regional wall motion and normal Ex Tl-201 ECT after successful percutaneous transluminal coronary angioplasty (data not shown). In contrast, patients with 90% stenosis and patients with well-developed collaterals preserved good wall motion. Although well-developed collaterals could supply coronary blood flow sufficiently to preserve good wall motion at rest, it was considered that resting coronary blood flow through well-developed collaterals was comparable to antegrade coronary blood flow through 90% stenosis.

Coronary flow through collaterals during exercise

Using exercise electrocardiography, several investigators¹⁹⁻²¹ have shown that the presence of extensive collaterals to stenosed vessels is not associated with a decreased likelihood of ST segment depression. The present study also showed that the frequency of ischemic ST depression in patients with well-developed collaterals was similar to other patients with significant coronary stenosis. Also, the frequency of chest pain was similar in all 3 groups. As for the protective effect of collateral on exercise-induced ischemia, it has been reported that mature collaterals can provide normal perfusion to the myocardium until a certain level of exercise is reached.⁸ However, at submaximal or maximal exercise, many investigators^{9,22,23} have shown that the presence of collateral flow does not prevent exercise-induced

ischemia, as judged by exercise TI-201 scintigraphy. We also demonstrated that even if a well-developed collaterals exists, the extent of exercise-induced ischemia judged by the TI-201 visual uptake score on the initial TI-201 images did not differ from that in patients with 99% stenosis. Cooper et al.²⁴ have demonstrated that a significant association exists between the redistribution of TI-201 and the presence of vascular disease with functional collaterals to the involved area in patients with transient myocardial ischemia. In this study, the recovery of TI-201 uptake on the delayed images obtained 4 hours after exercise in patients with well-developed collaterals was significantly better than that in patients with 99% stenosis. Therefore, the coronary flow through well-developed collaterals was considered to be better than that through 99% stenosis during the recovery period after maximal exercise. Although the coronary blood flow through well-developed collaterals at maximal exercise was considered to be comparable to antegrade flow through 99% stenosis, the blood flow would increase during the recovery period and finally return to the flow comparable to that through 90% stenosis. The capacity of an increase in blood flow of well-developed collaterals might help to preserve myocardial function in the jeopardized myocardium.

In conclusion, well-developed collaterals cannot prevent myocardial ischemia completely because of their limited blood flow delivery capacity, although it has some beneficial effects on the ischemic myocardium.

ACKNOWLEDGEMENT

We thank Mamoru Mochizuki NMT, Yasunori Matsumoto NMT, Mitsuru Takezawa NMT and Masami Yoshimura NMT for their expert technical assistance. We also thank Mrs. Sanae Onoda for her secretarial assistance.

REFERENCES

- Eng C, Patterson RE, Horowitz SF, et al: Coronary collateral function during exercise. *Circulation* 66: 209-316, 1982
- Juilliere Y, Danchin N, Grentzinger A, et al: Role of previous angina pectoris and collateral flow to preserve left ventricular function in the presence or absence of myocardial infarction in isolated total occlusion of the left anterior descending coronary artery. *Am J Cardiol* 65: 277-281, 1990
- Levin DC: Pathways and functional significance of coronary collateral circulation. *Circulation* 83: 831-837, 1974
- Hanby RI, Aintablian A, Schwartz A: Reappraisal of the functional significance of the coronary collateral circulation. *Am J Cardiol* 38: 305-309, 1976
- Kolibash AJ, Bush CA, Wepsic RA, Schroeder DP, Tetelman MR, Lewis RP: Coronary collateral vessels: Spectrum of physiologic capabilities with respect to providing rest and stress myocardial perfusion, maintenance of left ventricular function and protection against infarction. *Am J Cardiol* 50: 230-238, 1982
- Rigo P, Becker LC, Griffith LSC, et al: Influence of coronary collateral vessels on the results of thallium-201 myocardial stress imaging. *Am J Cardiol* 44: 452-458, 1979
- Fujita M, Sasayama S, Asanoi H, Nakajima H, Sakai O, Ohno A: Improvement of treadmill capacity and collateral circulation as a result of exercise with heparin pretreatment in patients with effort angina. *Circulation* 77: 1022-1029, 1988
- Lambert PR, Hess DS, Bache RJ: Effect of exercise on perfusion of collateral-dependent myocardium in dogs with chronic coronary artery occlusion. *J Clin Invest* 59: 1-8, 1977
- Freedman SB, Dunn RF, Bernstein L, Morris J, Kelly DT: Influence of coronary collateral blood flow on the development of exertional ischemia and Q wave infarction in patients with severe single-vessel disease. *Circulation* 71: 681-686, 1985
- Gregg DE, Patterson RE: Functional importance of the coronary collaterals. *N Eng J Med* 303: 1404-1406, 1980
- Austen WG, Edwards JE, Frye RL, et al: A reporting system on patients evaluated for coronary artery disease. *Circulation* 51: 5-40, 1975
- Sheehan FH, Bolson EL, Dodge HT, Mathey DG, Schofer J, Woo HW: Advantages and applications of the centerline method for characterizing regional ventricular function. *Circulation* 74: 293-305, 1986
- Kennedy JW, Trenholme SE, Kasser IS: Left ventricular volume and mass from single plane angiogram: a comparison of anteroposterior and right anterior oblique methods. *Am Heart J* 80: 343-352, 1970
- Kurata C, Sakata K, Taguchi T, Kobayashi A, Yamazaki N: Exercise-induced silent myocardial ischemia by thallium-201 emission computed tomography. *Am Heart J* 119: 557-567, 1990
- Fujita M, Sasayama S, Araie E, Ohno A, Yamashita K, Hirai T: Significance of pre-infarction angina for occurrence of post-infarction angina. *Eur Heart J* 9: 159-164, 1988
- Chilian WM, Mass HJ, Williams SE, Layne SM, Amith EE, Scheel KW: Microvascular occlusions promote coronary collateral growth. *Am J Physiol* 258: H1103-H1111, 1990
- Rentrop KP, Feit F, Sherman W, Thornton JC: Serial angiographic assessment of coronary artery obstruction and collateral flow in acute myocardial infarction: Report from the second Mount Sinai-New York University: Reperfusion trial. *Circulation* 80: 1166-1175, 1989
- Cuttino JT, Bartrum RJ, Hollenberg NK, et al: Collateral vessel formation: Isolation of a transferable factor promoting a vascular response. *Basic Res*

Cardiol 70: 568–573, 1975

19. Barath P, Jakbowski AT, Cao J, et al: Feasibility of heart neovascularization by intracoronary fibroblast growth factor. *Circulation* 78 (suppl II): II-57, 1988
20. Martin CM, McConahay DR: Maximal treadmill exercise electrocardiography: Correlation with coronary arteriography and cardiac hemodynamics. *Circulation* 46: 956–962, 1972
21. Fuster V, Frye RL, Kennedy M, Connolly DC, Mankin HT: The role of collateral circulation in the various coronary syndromes. *Circulation* 59: 1137–1144, 1979
22. Goldberg HL, Goldstein J, Borer JS, Moses JW, Collins MB: Functional importance of coronary collateral vessels. *Am J Cardiol* 53: 694–699, 1984
23. Berger B, Watson DD, Taylor GJ, Burwell LR, Martin RP, Beller GA: Effect of coronary collateral circulation on regional myocardial perfusion assessed with quantitative thallium-201 scintigraphy. *Am J Cardiol* 40: 365–370, 1980
24. Cooper R, Puri S, Francis CK, Spencer RP: Role of coronary artery disease and collateral circulation in redistribution of thallium-201. *Clin Nucl Med* 5: 292–298 1980