

Gallium-67 citrate scintigraphy in the pre-operative evaluation of soft tissue tumors of the extremities

Takeyoshi IMAEDA,* Matsuzo SEKI,* Yasuhiro SONE,* Gen IINUMA,* Masayuki KANEMATSU,* Ryozyo MOCHIZUKI,* Shoji TAKEUCHI,** Yutaka NISHIMOTO** and Kuniyasu SHIMOKAWA***

Departments of Radiology, **Orthopaedics and *Laboratory Medicine, University of Gifu School of Medicine*

We conducted a study of 90 patients with soft tissue tumor in their arms or legs, in order to determine the usefulness of scintigraphy with gallium-67 citrate as a diagnostic means. All patients had adequate scan images, and tumor tissues had been histologically confirmed by surgical resection.

The subjects consisted of 19 patients with malignant tumors, 55 patients with benign tumors, and 16 patients with other disorders in which soft tissue tumor-like lesions occurred.

When the activity of the tumor was more than the activity of the normal region of the contralateral extremity, it was estimated to be positive.

The positive rate was found in 78% (15/19) of patients with malignant tumors, in 25% (14/55) of patients with benign tumors and in 31% (5/16) of patients with other disorders. Classified by diseases, high positive rates were observed in liposarcoma, leiomyosarcoma, malignant lymphoma, neurinoma, extra-abdominal desmoid and sarcoidosis.

Out of 7 patients in which the activity of the tumor was equal to, or higher than that of the liver, 6 patients had malignant tumors and one patient was diagnosed as having an abscess.

It seemed possible to distinguish between liposarcoma and lipoma by means of a gallium-67 scan.

Furthermore, the gallium-67 scan was useful in detecting lesions of sarcoidosis as well as in evaluating the response to treatment.

Key words: gallium-67 scan, soft tissue tumors, extremities

INTRODUCTION

EMBRYOLOGICALLY, SOFT TISSUE is derived principally from the mesoderm, with some contribution from the neuroectoderm.

Soft tissue tumor can be defined as a tumor arising from a non-epithelial tissue of the body which excludes solid tissues such as skeletal tissue and cartilaginous tissue, and the reticuloendothelial system. It is represented by tumors of the voluntary

muscles, fat, fibrous tissues, and peripheral nervous system, along with tumors of the vessels serving these tissues.¹ Furthermore, soft-tissue tumors also include, as tumor-like lesions, those disorders in which it is not clear whether the disorder is derived from neoplasm or inflammation.

Thus, the soft-tissue tumor occurs in a wide range of diseases and conditions.

The first reports of successful soft tissue tumor scanning with gallium-67 were from the Oak Ridge group in 1969. And it was noted that the isotope became concentrated in lymphomatous tissue during the investigation of gallium as a potential bone-scanning agent.² Since then, many investigators have been studying the ability of gallium-67 to accumulate at the site of a neoplasm.

Received March 26, 1991, revision accepted August 14, 1991.

For reprints contact: Takeyoshi Imaeda, M.D., Department of Radiology, University of Gifu School of Medicine, Tsukasamachi 40, Gifu 500, JAPAN.

To the best of our knowledge, there has been no systematic study in a large series of patients on the utility of scintigraphy with gallium-67 in whole soft tissue tumors of the extremities.

This report appears to be the first systematic account of gallium-67 citrate scan findings in extremity-located soft tissue tumors.

MATERIALS AND METHODS

During the last 10 years, 90 patients with adequate scan images and with a diagnosis of extremity-located soft tissue tumor which was histologically confirmed by surgical resection were seen by the orthopaedic oncology service at the University of Gifu.

There were 38 men and 52 women with ages ranging from 6 to 76 years (mean age; 43 years). The subjects consisted of 19 patients with malignant tumors, 55 patients with benign tumors, and 16 patients with other disorders. Among the 19 patients with malignant tumors, 15 patients had tumors in their legs and the remaining 4 patients had tumors in their arms.

On the other hand, among the 55 patients with benign tumors, 30 patients had tumors in their legs and the remaining 25 patients had tumors in their arms. Ten patients with other disorders had tumor-like lesions in their legs and the remaining 6 patients had tumor-like lesions in their arms.

Four of the malignant tumors were less than 5.0 cm in diameter, eight were 5.1 to 10.0 cm, and seven were more than 10.1 cm.

Twenty-four of the benign tumors were less than 5.0 cm in diameter, seventeen were 5.1 to 10.0 cm, and fourteen were more than 10.1 cm.

Nine of the other disorders were less than 5.0 cm in diameter and seven were 5.1 to 10.0 cm. When the patients had more than a single lesion, the diameter of the largest lesion was measured.

All patients underwent scintigraphy with gallium-67 citrate as an initial diagnostic procedure.

All scans were performed 48 hr and 72 hr after intravenous injection of 1 to 3 mCi (37–111 MBq) of gallium-67 citrate with a Searle large field-of-view scintillation camera with a medium-energy parallel-hole collimator, and 20% precalibrated spectrometric windows at 93, 185, and 300 keV.

The anterior and posterior spot-views of the whole body were consistently imaged. First, 50,000 to 100,000 counts were collected for the bilateral upper or lower extremity including the area of the tumorous lesion, and then images of other anatomic regions were integrated for the same time and intensity. The intensity of the gallium uptake of the tumor observed on the scintigram was graded subjectively as com-

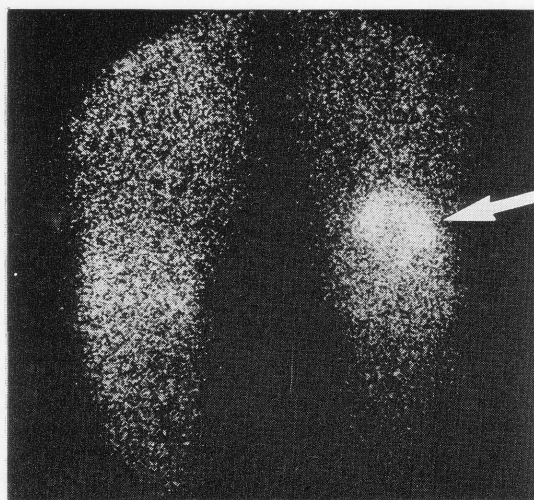
pared with that of the liver on a scale of (–), (+), (++) in which a score of (++) indicated an intensity almost equal to or more than that of the liver; (+) indicated an intensity more than that of the normal region of the contralateral extremity, but less than that of the liver; and (–) indicated a normal gallium scintigram. Grading was done on the basis of subjective evaluation by two observers.

Antineoplastic agents were not administered before the initial scintigraphy with gallium-67 citrate. The follow-up scintigraphy was performed after treatment in patients with malignant tumor or sarcomatosis.

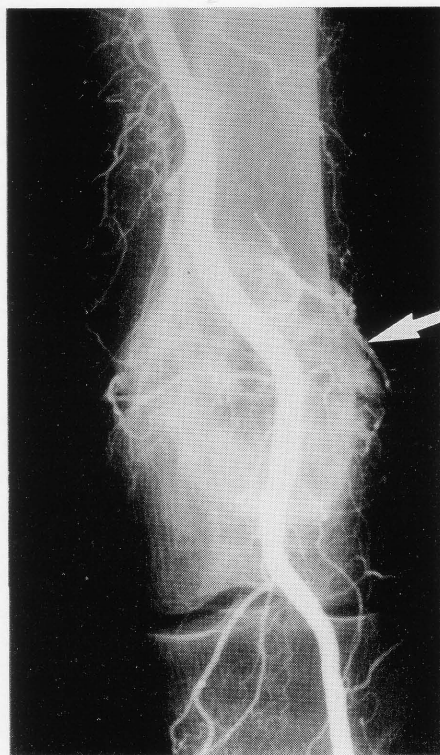
Other diagnostic studies usually included conventional radiography, xeroradiography, ultrasonography and computerized tomography of the affected limb. Bone scintigraphy, angiography and other miscellaneous studies were also performed if necessary.

Table 1 Results of gallium-67 uptake in soft-tissue tumors on initial scintigram

Histological type	No. of patients	Gallium-67 uptake		
		++	+	—
A. Malignant tumor				
Metastatic cancer	5	1	2	2
Liposarcoma	3		3	
Leiomyosarcoma	2	1	1	
Malignant lymphoma	2	1	1	
Synovial sarcoma	2	1		1
Malignant schwannoma	2		1	1
Hodgkin's disease	1	1		
Rhabdomyosarcoma	1	1		
Malignant fibrous histiocytoma	1		1	
B. Benign tumor				
Lipoma	15			15
Haemangioma	13		1	12
Extra-abdominal desmoid	9		5	4
Neurinoma	6		4	2
Neurofibroma	3		1	2
Fibrolipoma	3		1	2
Angiolipoma	2			2
Myxoma	1		1	
Giant cell tumor of tendon sheath	1		1	
Dermatofibroma	1			1
Calcifying epithelioma	1			1
C. Other disorder				
Ganglion	6			6
Sarcoidosis	5		4	1
Bursitis	4			4
Abscess	1	1		
Total	90			

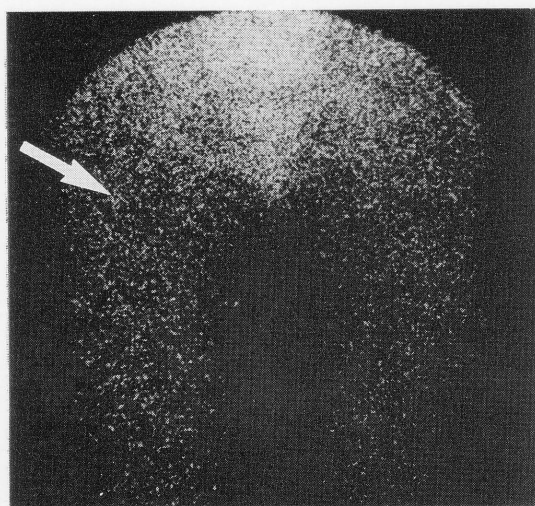


(A)

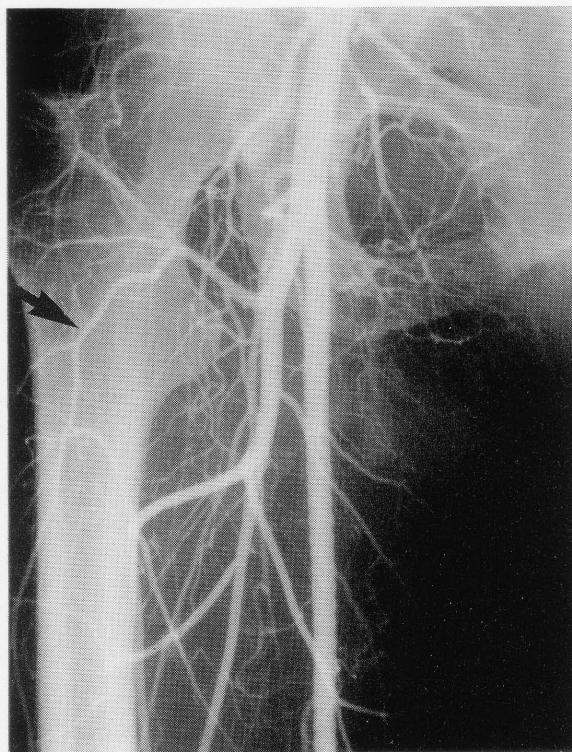


(B)

Fig. 1 A 74-year-old woman with a liposarcoma of the left thigh. (A). An anterior image of both thighs shows an area of abnormal increased uptake of gallium-67 with a cold zone due to necrosis in the left distal thigh (arrow). (B). The femoral arteriogram demonstrates a large hypervascular mass with tumor vessels, staining, and an avascular area corresponding to abnormal lesion seen in (A) (arrow).

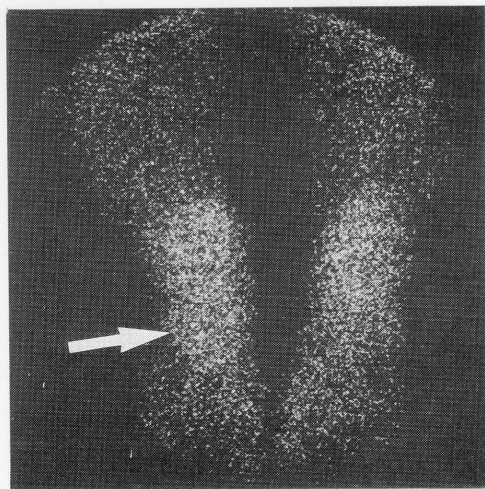


(A)

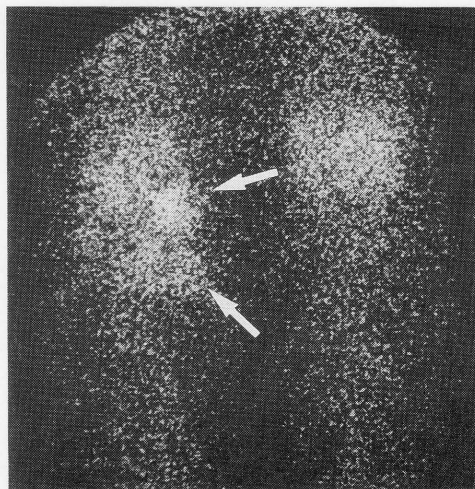


(B)

Fig. 2 A 43-year-old woman with a lipoma of the right proximal thigh. (A). An anterior image of both thighs shows a normal scan (arrow). (B). The femoral arteriogram demonstrates a hypovascular mass (arrow).



(A)



(B)

Fig. 3 A 24-year-old woman with an extra-abdominal desmoid of the left foot. (A). A posterior image of the feet shows an area of abnormal increased uptake of gallium-67 in the left foot (arrow). After this scan, the affected site was removed by surgical operation. (B). Three and a half years later, a posterior image of the lower legs demonstrates distant metastases in the left proximal lower leg (arrows).

RESULTS

Results of gallium-67 uptake in various untreated soft-tissue tumors of the extremities are detailed in Table 1.

A positive rate was found in 78% (15/19) of patients with malignant tumors, in 25% (14/55) of patients with benign tumors and in 31% (5/16) of patients with other disorders. Out of 7 patients in which the gallium-67 uptake of the tumor was rated as (+), 6 patients had malignant tumors and one patient was diagnosed as having an abscess.

Three (75%) of four malignant tumors ≤ 5.0 cm in diameter had a positive finding on imaging with gallium-67. On the other hand, twelve (80%) of fifteen malignant tumors ≥ 5.1 cm in diameter had positive scans.

There was not a significant difference between the positive rate for the tumors ≤ 5.0 cm in diameter and that for the tumors ≥ 5.1 cm in diameter.

The four malignant tumors that had a negative finding on imaging with gallium-67 included one malignant schwannoma, one synovial sarcoma, and two metastatic carcinomas.

Abnormally increased uptake of gallium-67 was mainly observed in malignant tumors such as liposarcoma (3/3), leiomyosarcoma (2/2), and malignant lymphoma (2/2); in benign tumors such as neurinoma (4/6) and extra-abdominal desmoid (5/9); and in other disorders such as sarcoidosis (4/5).

Gallium-67 imaging showed that all 3 patients with liposarcoma had a gallium-67 uptake intensity of

(+), whereas all 15 patients with lipoma had an intensity of (—). Therefore, it was considered possible to distinguish between liposarcoma and lipoma by means of gallium-67 scintigraphy (Figs. 1 and 2).

In one out of 9 patients with extra-abdominal desmoid, we detected distant metastases for the first time by using gallium-67 scintigraphy (Fig. 3).

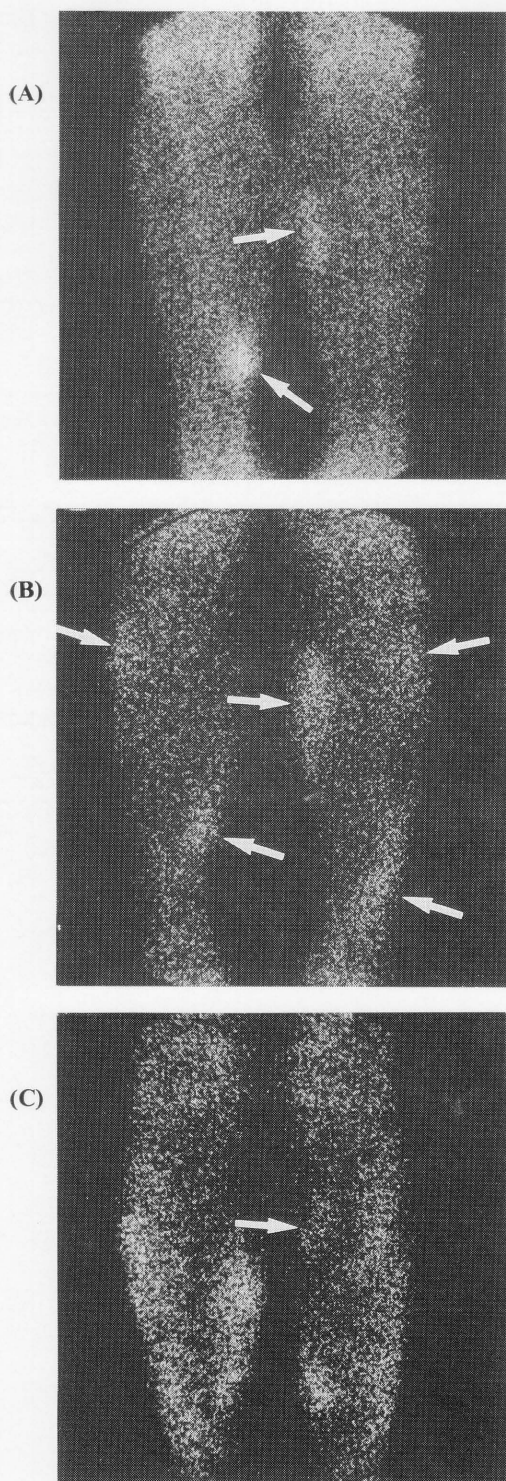
In 4 out of 5 patients with intermuscular sarcoidosis, the gallium-67 scintigraphy was not only useful in detecting the lesions, but also in evaluating the response to treatment (Fig. 4).

DISCUSSION

Although it is almost impossible to determine the incidence of soft tissue tumors, especially the relative frequency of benign to malignant tumors accurately, it has been reported that benign soft tissue tumors outnumber malignant tumors by about 100 to 1 in a hospital population.¹

The annual incidence of benign soft tissue tumors is approximately 300 per 100,000 population.¹ On the other hand, malignant soft tissue tumors, compared with carcinomas and other neoplasms, are relatively rare. The average annual incidence is 1.35–2.00 per 100,000 population.¹

Soft tissue sarcomas can arise anywhere in the body, with a frequency of 40% in the legs, 29% in the trunk, 19% in the arms, and 11% in the head and neck.³ Soft tissue sarcomas occur at any age, but like carcinomas, are more common in older patients; about 40% affect persons being older than 55 years, but on the other hand, about 15% affect



←**Fig. 4** A 72-year-old woman with an intermuscular sar-
coidosis of both lower legs. (A) An anterior image shows
an area of abnormal increased uptake of gallium-67 in
both lower legs (arrows). (B) One year and 9 months later,
an anterior image demonstrates an increase in number
and size of areas of abnormal increased uptake (arrows),
and after this scan, the site of abnormal increase uptake
in the left proximal lower leg was removed by surgical
operation. Other affected sites were not removed. (C)
Three years later, an anterior image reveals greater uptake
in other affected sites, although the abnormal uptake of
the operated site decreased (arrow).

in detecting local recurrence and distant extrapul-
monary metastases. Therefore, gallium-67 scinti-
graphy should be used as an initial diagnostic
procedure.

In various series of patients with soft tissue sar-
comas, gallium-67 images have been reported to be
abnormal in 100% of malignant schwannomas, 80-
86% of rhabdomyosarcomas, 50-100% of liposar-
comas, 25-100% of malignant fibrous histiocytomas,
0-67% of synovial sarcomas, and 33% of leiomyo-
sarcomas.⁴⁻⁸

Although imaging with gallium-67 citrate is sensi-
tive for soft tissue sarcomas, it is not specific. It has
been generally said that acute inflammatory lesions
as well as some benign neoplasms also have abnor-
mal gallium-67 images and cannot be differentiated
from malignant lesions by gallium-67 imaging alone.
In this study, however, the tumorous lesions in which
the gallium-67 uptake indicated an intensity almost
equal to or more than that of the liver, were all
malignant except for one abscess.

There is still no general agreement on the exact
mechanisms of gallium-67 localization in neoplastic
and inflammatory lesions, and the reason for
gallium-67 uptake variation among these various
disorders is unknown. However, several local factors
influencing gallium-67 uptake have been proposed.
They include tumor viability, high tumor vascularity,
hyperpermeability due to inflammation and neovas-
cularization or to increased membrane pore size in
tumors, accumulation by tumor histiocytes, gallium
dissociation and binding of the ionic gallium by
tumor proteins as a result of a local decrease in pH
in the tumorous region, and the exchange of extra-
cellular gallium with the intracellular calcium pool.⁹

In the past, the differential diagnosis of liposar-
coma and lipoma has been based on imaging with
technetium-99m pyrophosphate or methylene
diphosphonate as the radionuclide. It was generally
admitted that the accumulation of these radio-
nuclides was observed in liposarcoma, but not in
lipoma.¹⁰ But, in a patient whose lipoma is accom-
panied by calcification, these radionuclides were

persons younger than 15 years.¹

Variant non-invasive imaging procedures, in-
cluding gallium-67 scintigraphy, xeroradiography,
ultrasonography, computerized tomography, and
magnetic resonance imaging, are now used to detect
soft tissue tumors.

Among these, gallium-67 scintigraphy is not only
useful in determining the severity of lesions but also

found to accumulate in the lipoma.

It had been difficult, therefore, to distinguish between liposarcoma and lipoma by means of these radionuclides alone.

In this study, however, gallium-67 accumulated only in liposarcoma, and it was not observed in lipoma. From this finding, it seems that gallium-67 can be used in the differential diagnosis of these two types of tumors. And furthermore, gallium-67 scintigraphy was reported to be not only useful for the detection of the lesions of intermuscular sarcoidosis, but also for the evaluation of the response to treatment.¹¹

When the intensity of the gallium-67 uptake of the tumor is almost equal to or more than that of the liver, that suggests malignancy and indicates the need for further evaluation by computerized tomography or magnetic resonance imaging.

REFERENCES

1. Enzinger FM, Weiss SW: General considerations. In *Soft Tissue Tumors*, Enzinger FM and Weiss SW (eds), St. Louis, C. V. Mosby Company, pp 1-18, 1988.
2. Edwards CL, Hayes RL: Tumor scanning with ⁶⁷Ga citrate. *J Nucl Med* 10: 103-105, 1969.
3. Chang AE, Rosenberg SA: Clinical evaluation and treatment of soft tissue tumors. In *Soft Tissue Tumors*, Enzinger FM and Weiss SW (eds), St. Louis, C.V. Mosby Company, pp 19-42, 1988.
4. Bitran JD, Bekerman C, Golomb HM, et al: Scintigraphic evaluation of sarcomata in children and adults by ⁶⁷Ga citrate. *Cancer* 42: 1760-1765, 1978.
5. Levine E, Huntrakoon M, Wetzel LH: Malignant nerve-sheath neoplasms in neurofibromatosis. *AJR* 149: 1059-1064, 1987.
6. Teates CD, Bray ST, Williamson BRJ: Tumor detection with ⁶⁷Ga-citrate: A literature survey (1970-1978). *Clin Nucl Med* 12: 456-460, 1978.
7. Finn HA, Simon MA, Martin WB, et al: Scintigraphy with gallium-67 citrate in staging of soft-tissue sarcomas of the extremity. *J Bone and Joint Surg* 69-A: 886-891, 1987.
8. Zazzaro PF, Bosworth JE, Schneider V, et al: Gallium scanning in malignant fibrous histiocytoma. *AJR* 135: 775-779, 1980.
9. Larson SM, Camargo EE, Keenan AM: Tumors. In *Textbook of Nuclear Medicine, Volume II: Clinical applications*, Harbert J and Rocha AFG (eds), Philadelphia, Lea & Febiger, pp 635-662, 1984.
10. Chew FS, Hudson TM: Radionuclide imaging of lipoma and liposarcoma. *Radiology* 136: 741-745, 1980.
11. Edan G, Bourguet P, Delaval P, et al: Gallium-67 imaging in muscular sarcoidosis. *J Nucl Med* 25: 776-778, 1984.