

## A study of ventricular contraction sequence in complete right bundle branch block by phase analysis

Tohoru TAKEDA,\* Hinako TOYAMA,\*\* Kaname IIDA,\* Takeshi MASUOKA,\* Ryuichi AJISAKA,\*  
Keisuke KUGA,\* Motohiro SATOH,\* Shinji SUGAHARA,\* Wu JIN,\* Nobuyoshi ISHIKAWA,\*  
Yasuro SUGISHITA\* and Takao AKATSUKA\*\*\*

*\*Institute of Clinical Medicine, University of Tsukuba, Ibaraki, Japan*

*\*\*Tokyo Metropolitan Institute of Gerontology, Tokyo, Japan*

*\*\*\*Department of Information Engineering, University of Yamagata, Yamagata, Japan*

Twenty-four patients with complete right bundle branch block (CRBBB) combined with and without left axis deviation (LAD) on ECG, were compared with 17 normal subjects to evaluate the right ventricular contraction sequence and pattern in detail. Blood pool scintigrams were obtained in the left anterior oblique projection, and these images were analyzed by first component Fourier harmonics.

In the normal subjects, the phase value distribution representing the pattern of ventricular contraction was almost homogeneous in both the right and left ventricles (RV&LV). In the CRBBB patients without LAD, the phase images showed apparent phase delay in the right ventricle. In the CRBBB patients with LAD, the phase images showed many different contraction patterns varying from normal to RV phase delay, owing to the effects of the hemiblock. Quantitative analysis of the absolute values, showed that the mean (RV-LV) value was  $6.6 \pm 8.4$  msec in the normal subjects. In the CRBBB patients without LAD, the duration of the QRS complex correlated with the mean (RV-LV) value, whereas no difference was observed between the duration of the QRS complex and the standard deviation of the right ventricle. Using phase analysis the degree of the RBBB can be determined from the phase images, and can be quantitatively analyzed as in electrical studies.

**Key words:** phase analysis, first harmonic Fourier method, right bundle branch block, multigated blood pool scintigram, ventricular contraction sequence

### INTRODUCTION

EQUILIBRIUM multiple-gated blood pool scintigraphy is established as a noninvasive method of assessing ventricular size, wall motion, and function.<sup>1,2</sup> The first harmonic Fourier method (phase analysis) is also widely used to evaluate cardiac function,<sup>3</sup> with its greatest benefit being an ability to reveal the timing of contraction of the ventricles. This allows abnormalities of ventricular contraction to be easily

detected such as in bundle branch block (BBB),<sup>4-6</sup> Wolff-Parkinson-White (WPW) syndrome,<sup>7</sup> and ischemic heart disease.<sup>8</sup> In this study, the temporal sequence and contraction patterns of the right ventricle were analyzed in detail using the first harmonic Fourier method in patients with complete right bundle branch block (CRBBB).

### MATERIALS AND METHODS

#### *Subjects*

The study was performed using both normal subjects and patients with CRBBB. The normal subjects consisted of 10 men and 7 women aged from 22 to 70 years old ( $53.1 \pm 12.2$  years, mean  $\pm$  SD). These subjects had normal cardiac wall motion, normal

Received May 16, 1990, revision accepted January 7, 1991.

For reprints contact: Institute of Clinical Medicine, University of Tsukuba, 1-1-1 Tennodai, Tsukuba-shi, Ibaraki-ken 305, JAPAN.

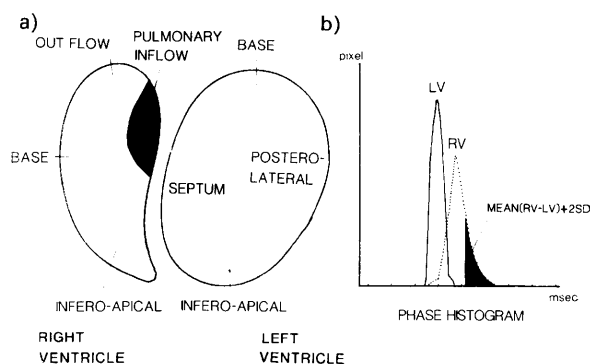
cardiac function with an ejection fraction of 55% or greater ( $63.1 \pm 5.8\%$ ), and a normal 12-lead electrocardiogram (ECG). They all had normal findings on physical examination, chest X-ray, and echocardiogram.

The CRBBB patients consisted of 18 men and 6 women aged from 34 to 78 years old ( $54.3 \pm 20.1$  years, mean  $\pm$  SD). CRBBB was confirmed by ECG (wide S in lead I and V6, rSR complex in V1, and QRS duration  $\geq 120$  msec), and the patients were divided into those having CRBBB with left axis deviation  $< -30^\circ$  (LAD) and CRBBB without LAD (isolated CRBBB). Six of the patients had LAD, comprising 4 men and 2 women aged from 43 to 73 years old ( $56.5 \pm 11.2$  years, mean  $\pm$  SD). Physical examination was normal in all cases. The wall motion and amplitude of excursion of both the right ventricle (RV) and the left ventricle (LV) were normal, and there was no evidence of volume overload of the RV.

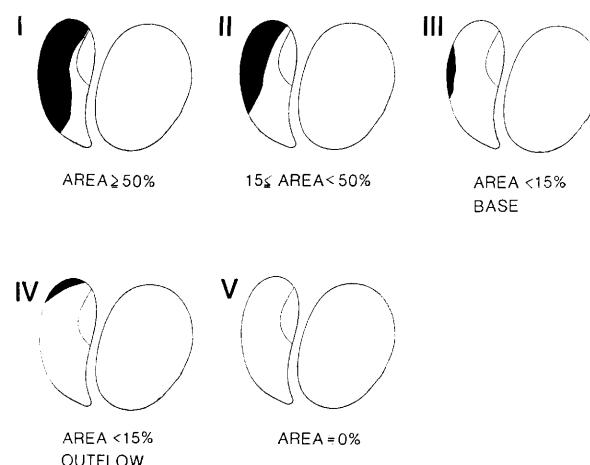
### Methods

Radionuclide examination was performed using multigated blood pool scintigraphy, with images being obtained in the modified left anterior oblique projection. Gated cardiac imaging was performed after *in vivo* RBC labeling with an intravenous (IV) injection of 6 mg of stannous chloride pyrophosphate dissolved in 3 ml of saline, followed about 20 minutes later by the IV injection of 555–740 MBq (15–20 mCi) of technetium (Tc)-99m pertechnetate.<sup>9</sup> Patients were imaged using a low-energy mobile (LEM) gamma camera with a slant hole, high resolution, and a low-energy collimator. Images were obtained in the modified left anterior oblique (LAO) position, with a 15-degree caudal tilt to diminish the overlapping of cardiac structures. The following acquisition parameters were used: an energy window of 20%, peak at 140 keV, 25 frames/minute (40 msec interval after the R wave), and 10% rejection of abnormal beats corresponding to about 600 beats. Data were processed with a SCINTIPAC 1200 (Shimazu Co. Ltd., Japan) computer system as  $64 \times 64$  matrix images.

Phase analysis of equilibrium multiple-gated blood pool scintigrams was performed by first component Fourier harmonics to fit a cosine curve to the time-activity curve of each pixel. Phase histograms of the RV and LV were constructed from the phase images obtained in the modified LAO projection. The borders of each ventricle were manually determined and superimposed on the amplitude image. At this time, the area of pulmonary inflow was eliminated (Fig. 1a). The mean phase value (averaged values of phase for the RV and LV) and the standard deviation for each ventricle were calculated from these histograms. These parameters were represented as



**Fig. 1** Regional phase assessment. a) Diagram of the right and left ventricular areas of interest in the left anterior oblique projection of a multiple-gated blood pool scintigram. The shaded area is not measured (pulmonary inflow). b) A sample phase histogram. The shaded values on the histogram represent the mean (RV-LV) + 2SD for the normal right ventricle. The histogram relates phase values on the abscissa to the number of pixels at any phase value on the ordinate.



**Fig. 2** The five patterns of phase delay in normal controls and CRBBB patients.

the absolute value in msec so as to allow correlation with the electrocardiogram.

The shaded area on the RV histogram shown in Fig. 1b was set as the value greater than the mean (RV-LV) + 2SD (phase standard deviation of the RV in the normal subjects). From analysis of the normal subjects, the threshold value to distinguish the region of phase delay was determined to be 49 msec.

The phase images obtained in the patients with CRBBB and the normal subjects were classified as five patterns (types I–V) according to the area and the direction of phase delay in the RV (Fig. 2). Type V was defined so that the area was almost zero. The normal range of the area was  $4.7 \pm 5.2\%$  of the total right ventricular area, and an area of more than 15% was defined as abnormal. Among patients with

a normal area, the phase images were classified by the direction of contraction of the RV, i.e., basal (type III) or outflow (type IV). In type I, the area was more than 50% and RBBB was thought to be almost complete in electrical meaning.<sup>10,11</sup>

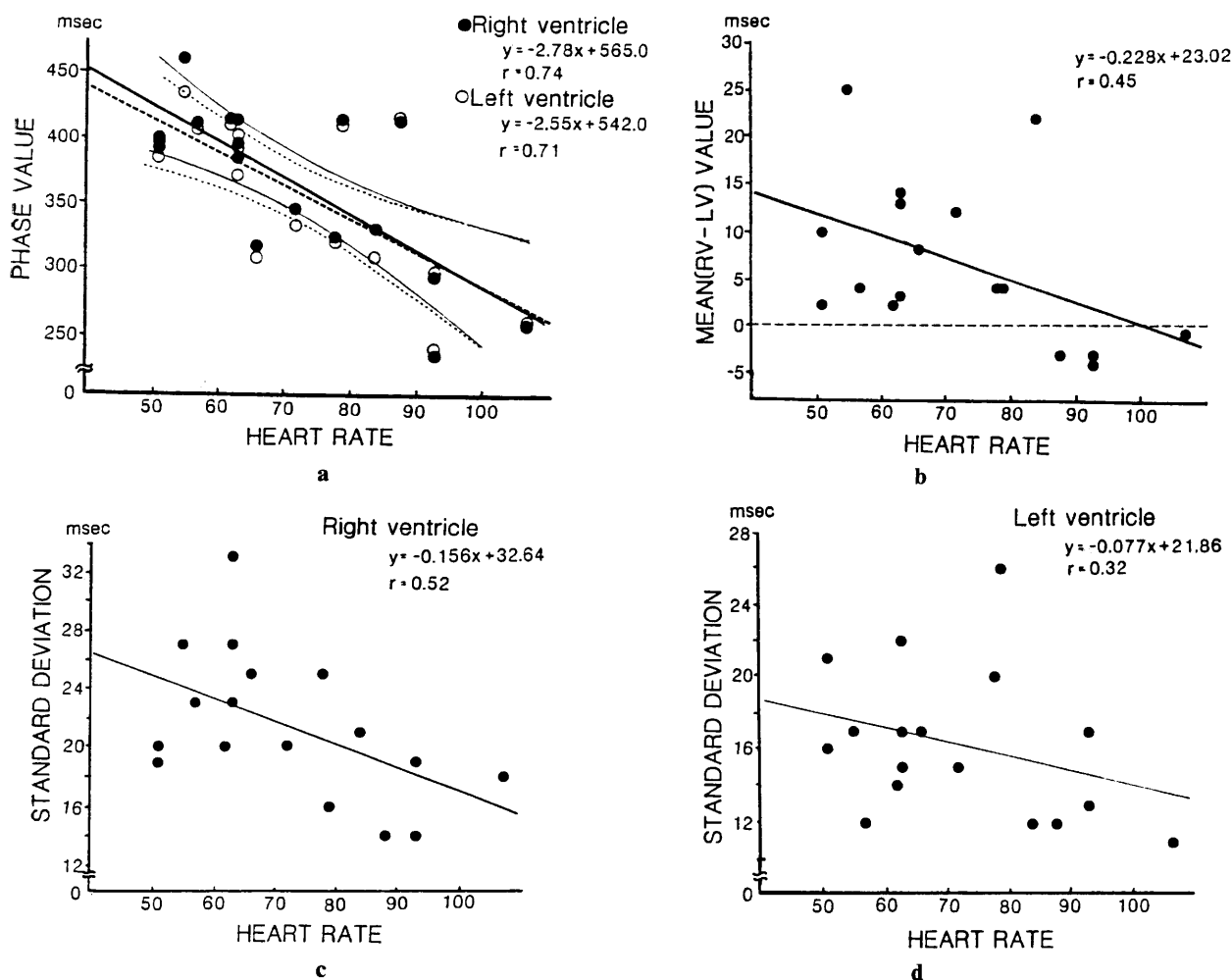
#### Statistical analysis

Data are presented as the mean $\pm$ SD. Student's t-test for paired variables was used. Linear regression analysis by the least squares method was performed to analyze the relations between the heart rate and the mean phase values, the standard deviation for both ventricles, and between the area of phase delay and the mean (RV-LV) value for the right ventricle. A value of  $p < 0.05$  was considered to indicate a significant difference.

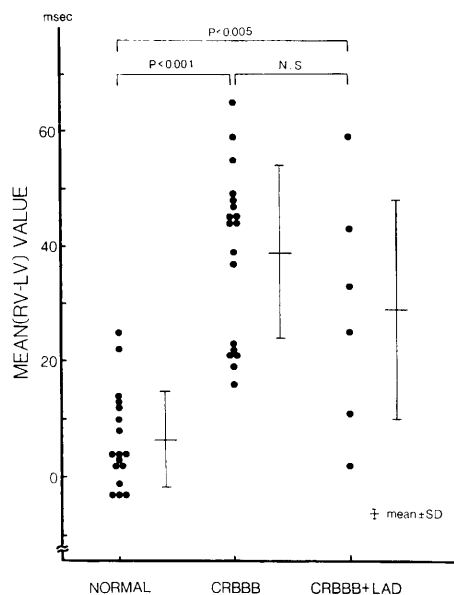
## RESULTS

Blood pool scintigrams were analyzed in a total of

41 subjects. The absolute time (msec) was determined in this study and the relationships between the heart rate, mean phase value, and standard deviation of phase for both the RV and LV were analyzed. All subjects were in sinus rhythm. The heart rate ranged from 51 to 107 beats/min ( $72.1 \pm 16.5$ , mean $\pm$ SD) in the normal subjects, from 51 to 83 beats/min ( $63.7 \pm 7.8$ , mean $\pm$ SD) in the patients with isolated CRBBB, and from 62 to 93 beats/min ( $73.2 \pm 12.4$ , mean $\pm$ SD) in the patients with CRBBB+LAD. When the heart rate increased, the mean phase values for both ventricles decreased linearly in the normal controls (Fig. 3a), and there was little difference between the LV and the RV (Fig. 3b). The standard deviation of phase for the RV tended to shorten more than that for the LV as the heart rate increased (Figs. 3c, d). In the isolated CRBBB patients, the range of heart rates was very narrow (51–83 beats/min), so correction of the absolute value for changes in the heart rate was not performed in this study.



**Fig. 3** The relationship between the phase value and the heart rate (beats/min) in the normal control subjects. a) The relation between the absolute phase value and the heart rate. b) The relation between the mean (RV-LV) value and the heart rate. c, d) The relation between the standard deviation and the heart rate for both the right and left ventricles.



**Fig. 4** Differences between the right and left ventricular phase values in 17 normal control subjects and 24 patients with CRBBB.

In the 17 subjects with normal blood pool scintigrams and a normal electrocardiogram, the phase image revealed an almost homogeneous ventricular contraction pattern of blue shade without regions of gross phase delay, but with a small difference between the LV and the RV phase values. The phase value for the RV was greater than that for the LV, and the mean (RV-LV) value was  $6.6 \pm 8.4$  msec (Fig. 4). The averaged standard deviation of the left ventricular phase was  $16.3 \pm 4.1$  msec, while that of the right ventricular phase was  $21.4 \pm 5.0$  msec (Fig. 5), indicating a significantly greater phase range in the normal RV than those in the normal LV ( $p < 0.05$ ).

In the CRBBB patients, the phase images of the LV were almost homogeneous, as shown in Fig. 8, whereas those of the RV had nonhomogeneous areas of green shade. This indicated that the phase values for the RV were greater than those for the LV. The mean (RV-LV) value in CRBBB patients without and with LAD was  $38.8 \pm 15.0$  msec, and  $28.8 \pm 20.9$  msec respectively (Fig. 4). And a good correlation between the mean (RV-LV) value and the area of phase delay in the RV was observed (Fig. 6,  $r = 0.94$ ). Furthermore, the degree of phase delay was directly related to the duration of the QRS complex (Fig. 7). The phase standard deviation of the RV in isolated CRBBB was much greater than in the normal subjects, whereas the phase standard deviation of the LV was almost the same in both the normal subjects and the isolated CRBBB patients (Fig. 5). And there are no differences between the duration of

the QRS complex and the standard deviation of the RV (Fig. 7).

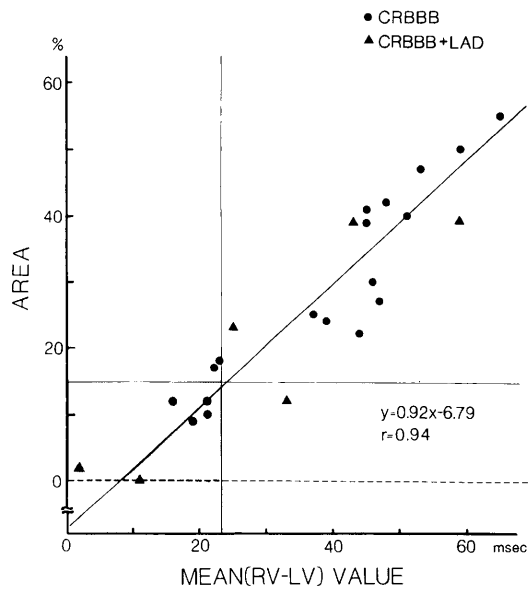
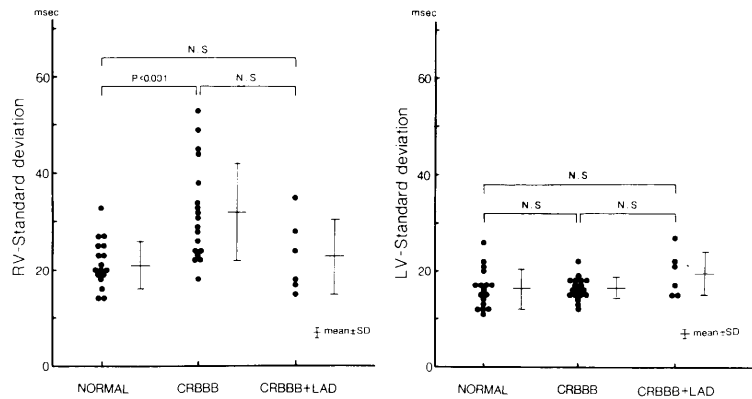
The phase standard deviation in CRBBB patients with LAD was slightly greater than in the normal subjects, but was not statistically significantly different (Fig. 5). Statistical analysis (Student's t-test) of differences in the QRS duration, mean (RV-LV) value, and RV standard deviation was not performed for this group of patients, because of the small number.

Typical images are shown in Fig. 8. Table 1 shows the number of subjects with each of the phase patterns. Normal subjects had type III (24%), IV (29%), and V (47%) patterns. Patients with isolated CRBBB showed all patterns except type V, with type II being the most common (67%, 12/18). Type III and IV comprised 22% of these patients. Only the patients with CRBBB+LAD had a type V pattern (33%, 2/6).

## DISCUSSION

The phase image can be interpreted to represent the sequential pattern of ventricular contraction, and cardiac mechanical activity corresponds closely to cardiac electrical activity.<sup>12,13</sup> The phase image would thus be expected to mirror the pattern of electrical conduction in the absence of primary contraction abnormalities. Previous studies of phase images have shown that they paralleled the conduction sequence in patients with normal conduction, implanted pacemakers, and bundle branch block.<sup>4-6,14,15</sup> The mean phase value represents the averaged contraction timing, and the standard deviation shows the heterogeneity of ventricular contraction.<sup>16-19</sup> In the case of RBBB, phase delay is known to occur in the RV,<sup>4-6,20</sup> but the contraction sequence has not been evaluated in detail yet. Accordingly, phase images from a control group with normal wall motion on blood pool scintigrams and a normal electrocardiogram, were compared with those from patients with CRBBB.

This study used the absolute time (msec) to analyze the degree of phase delay. The heart rate reflects the value of the phase delay, because the phase value mainly represents the ejection time.<sup>4,21</sup> Thus, when the heart rate increased, the phase value for both the RV and the LV decreased linearly in the normal control subjects. However, the mean (RV-LV) value did not show any significant correlation with the heart rate and it seems that the effects of the heart rate might be cancelled out for the mean (RV-LV) value as described in other reports.<sup>18,19</sup> Within the range of heart rates investigated in this study (51-83 beats/min in the isolated CRBBB patients), the standard deviation of both the RV and the LV did not change significantly with changes in the heart



(Top)

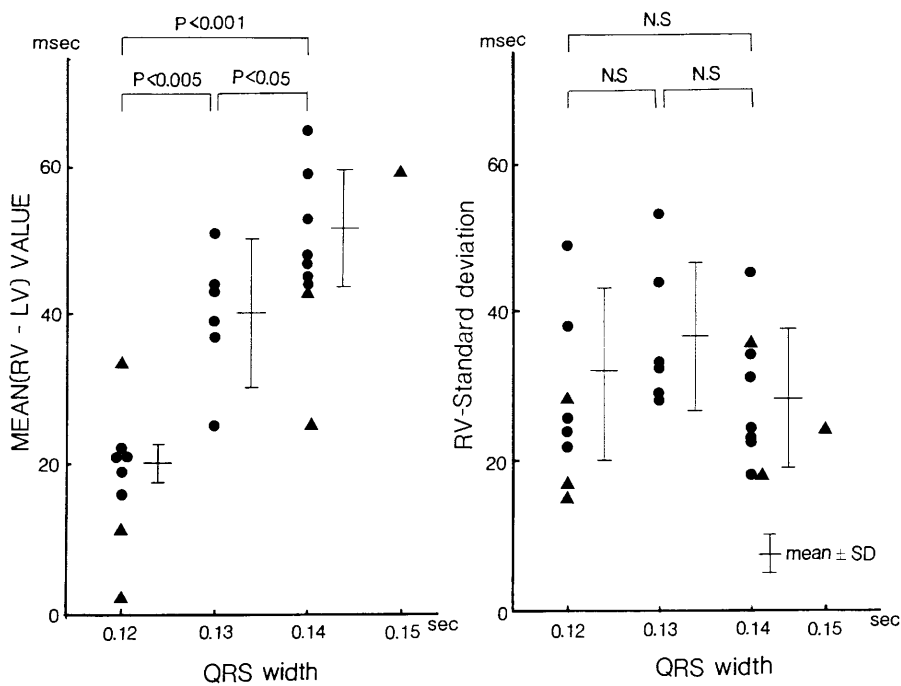
**Fig. 5** The standard deviations of the right and left ventricles in the normal control subjects and the patients with CRBBB.

(Right)

**Fig. 6** The relation between the area of phase delay and the mean (RV-LV) value of the right ventricle. Triangle; the CRBBB patients with LAD. The shaded area represents the range of normal values.

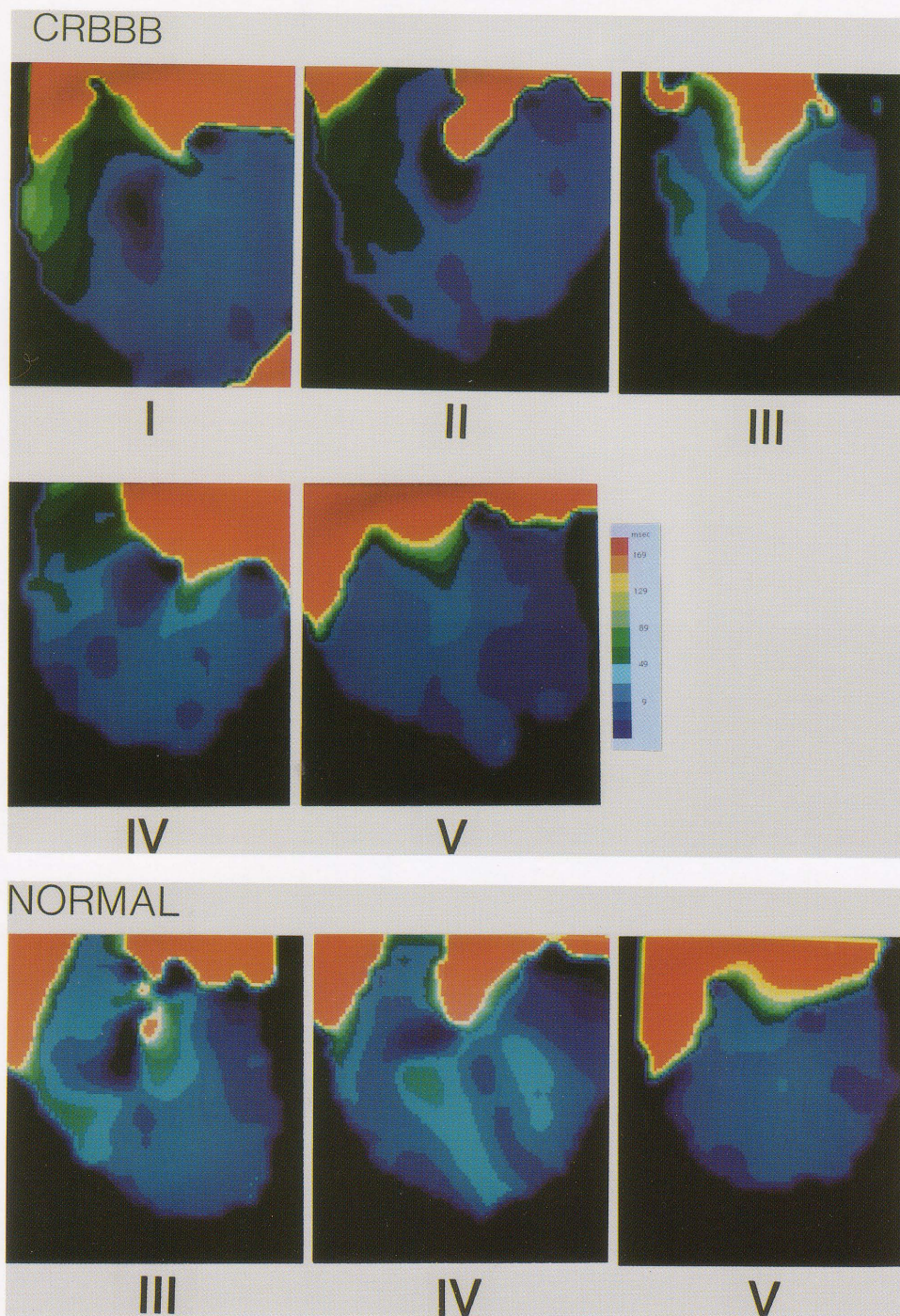
(Bottom)

**Fig. 7** The relations between the width of the QRS complex and mean (RV-LV) value, or the RV standard deviation. Triangles; CRBBB with LAD.



**Table 1** The distribution of the five different phase image patterns in the normal control subjects and the CRBBB patients with and without left axis deviation (LAD)

Disease	Pattern I	II	III	IV	V
Normal	0	0	4	5	8
CRBBB	2	12	2	2	0
CRBBB+LAD	0	3	0	1	2



**Fig. 8** Phase images of normal control subjects and patients with CRBBB. Each color step is set as 20 msec, and the green area corresponds to phase values above 49 msec.

rate. Accordingly, the absolute time was used to allow the phase analysis to be used as an electrical study.

In normal subjects, a phase delay of about 6.6 msec was noted in the RV compared to the LV. Durrer et al. studied the activation sequence of the isolated human heart and showed that the right endocardial surface was normally activated at the anterior papillary muscle 5 to 10 msec after the onset of left ventricular cavity activation.<sup>22</sup> Thus the mechanical contraction revealed by phase analysis can reflect electrical conduction delay exactly. We found that the mean standard deviation of the right ventricular phase or the duration of right ventricular activation was significantly greater than that of the LV. Overall, these results are consistent with the known temporal relationship between right and left ventricular conduction and contraction, as determined by both electrical and Fourier methods.<sup>4,6,10,22</sup> In agreement with other observations,<sup>4,13,22,23</sup> the mean direction of the spread of activity on the right septal surface is directed upward and somewhat posteriorly, as the phase images shown in Fig. 8.

In the case of isolated CRBBB, significant phase delay was shown in the RV compared to that in normal subjects ( $38.8 \pm 15.0$  vs.  $6.6 \pm 8.4$  msec,  $p < 0.001$ ). This value resembles that determined by electrical studies (48 msec).<sup>10</sup> Electrical activation occurred after 25–85 msec (average: 54) at the right ventricular apex compared to 0–30 msec (average: 6) at the left ventricular apex, and the duration of the QRS on the ECG correlated well with the degree of phase delay.<sup>10</sup> The standard deviation of the RV in isolated CRBBB was much greater than in the normal subjects, but it did not show any correlation with the duration of the QRS. This means that although various abnormalities might exist in the conduction system, the duration of the QRS appears to be mainly decided by the degree and site of the RBBB in the septum. Previous pathological studies have shown that the fibrosis and fatty degeneration commonly occurs in the bundle branch in the elderly, even without underlying ischemia or inflammation. The RBB was subdivided into three portions in these studies, designated as the first, second, and third portions. The first portion extends from the bifurcation to the proximal part of the trabecula septomarginalis, the second portion follows an intramyocardial course until it is distal to the trabecula septomarginalis, and the third portion runs in the subendocardial layer to terminate in the base of the anterolateral papillary muscle. Varying degrees of damage were seen in the conduction system such as His bundle, both right and left bundle branches, with severe damage to the RBB being found in about 83% of patients who had isolated CRBBB, and this

damage was especially severe in the first or second portions.<sup>24,25</sup> In patients with a wide QRS, it has been found that the damage occurred in the proximal portion of the RBB.<sup>25</sup> Although CRBBB is traditionally said to be present when the QRS duration is more than 120 msec, clinical electrocardiographic findings suggest otherwise. Scher has estimated by extrapolation from canine studies that for CRBBB to be complete, the QRS width would have to be 160 msec.<sup>26</sup> Therefore, hardly any RBBB patients may have a complete block, although the electrical speed of conduction may be reduced remarkably in the conduction system of the RBB. Complex variation in the block sites and the electrical conduction speed produce various degrees of conduction delay in RBB.

In CRBBB with LAD, the difference between the right and left ventricular mean phase value was smaller than in isolated CRBBB. The concept of left hemiblock (impaired conduction within the anterior and posterior divisions of the left bundle branch (LBB)) was originally established by electrocardiographical studies.<sup>27–29</sup> However histological studies have revealed that the LBB was a diffuse fanlike structure broadly distributed over the septal surface, which has branches covering the median region.<sup>30,31</sup> Patients with LAD of less than  $-30$  degree show damage to the LBB that extends broadly over anterior and median fascicles.<sup>32</sup> In them, electrical contraction may start in the posterior paraseptal region about one third of the distance from the apex to the base of the LV,<sup>22</sup> and then spread forward to the anterior wall of the ventricle. Thus, phase delay occurring in the LV would diminish the mean (RV-LV) value.<sup>33</sup> Two of our CRBBB+LAD patients had a completely normal contraction pattern (type V). The anterior and median fascicles might have been severely damaged in these patients, with the phase delay occurring in the posterior portion of the LV being obscured by its geometrical position in the LAO projection. The standard deviation of left ventricular contraction in CRBBB+LAD tended to be greater than that of the normal controls and isolated CRBBB patients, but the difference was not statistically significant. The standard deviation of right ventricular contraction was less than that in isolated CRBBB ( $p = \text{N.S.}$ ), and resembled that for left ventricular contraction ( $22.8 \pm 7.7$  vs  $19.5 \pm 4.7$  msec). This phenomenon might also be explained by the cancelling effects of phase delay owing to the geometrical position of the ventricles. That is, ventricular contraction which occurs in the posterior wall of the RV could not be accurately detected, because the changes detected by the sensor were cancelled out by overlap from base to apex. Other important causes of variation in the standard devia-

tion could have been variation in the electrical activation sequence, ventricular volume, and myocardial fiber orientation.<sup>13</sup> And previous pathological studies in CRBBB+LAD have shown that damage occurred in the RBB (80%), the anterior fascicle of the LBB (73%), and the posterior fascicle of the LBB (40%) with degenerative changes.<sup>24,25</sup> These complex disturbances of the conduction system may affect the conduction sequence.

The phase value is not specifically related to the time of onset of contraction. Errors in calculation may result from problems of curve fitting, overlapping structures, cardiac motion, and several other causes. However, this study showed that the contraction sequence shown by phase analysis correlated well with the speed of electrical conduction in the ventricles. In the case of isolated CRBBB, the contraction sequence could be analyzed quantitatively, and the degree of blocking of the RBB could be determined from the phase images.

#### ACKNOWLEDGEMENT

The authors express their thanks to Rokuro Hatakeyama RT, Hirobumi Nemoto RT and Noboru Chiba RT for their technical assistance.

#### REFERENCES

1. Rigo P, Murray M, Strauss HW, et al: Scintiphotographic evaluation of patients with suspected left ventricular aneurysm. *Circulation* 50: 985-991, 1974
2. Salel AF, Berman DS, DeNardo GL, et al: Radionuclide assessment of nitroglycerin influence on abnormal left ventricular segmental contraction in patients with coronary heart disease. *Circulation* 53: 975-982, 1976
3. Adam WE, Tarkowska A, Bitter F, et al: Equilibrium (Gated) radionuclide ventriculography. *Cardiovascular radiology*, 2: 161-173, 1979
4. Fraix MA, Botvinick EH, Shosa DW, et al: Phase image characterization of ventricular contraction in left and right bundle branch block. *Am J Cardiol* 50: 95-105, 1982
5. Botvinick EH, Fraix MA, Shosa DW, et al: An accurate means of detecting and characterizing abnormal patterns of ventricular activation by phase image analysis. *Am J Cardiol* 50: 289-298, 1982
6. Underwood SR, Walton S, Laming PJ, et al: Patterns of ventricular contraction in patients with conduction abnormality studied by radionuclide angiocardiology. *Br Heart J* 51: 568-574, 1984
7. Botvinick EH, Fraix M, O'Connell W, et al: Phase image evaluation of patients with ventricular pre-excitation syndromes. *J Am Coll Cardiol* 3: 799-814, 1984
8. Ratib O, Henze E, Schon H, et al: Phase analysis of radionuclide ventriculograms for the detection of coronary artery disease. *Am Heart J* 104: 1-12, 1982
9. Pavel DG, Zimmer AM, Patterson VN: *In vivo* labeling of red blood cells with Tc-99m: A new approach to blood pool visualization. *J Nucl Med* 18: 305-308, 1977
10. Kastor JA, Goldreyer BN, Moore N, et al: Intraventricular conduction in man studied with an endocardial electrode catheter mapping technique. *Circulation* 51: 786-796, 1975
11. Castellanos AJ, Agha AS, Befeler B, et al: A study of arrival of excitation at selected ventricular sites during human bundle branch block using close bipolar electrodes. *Chest* 63: 208-213, 1973
12. Hotta S: The sequence of mechanical activation of the ventricle. *Jpn Circ J* 31: 1568-1572, 1967
13. Clayton PD, Bulawa WF, Klausner SC, et al: The characteristic sequence for the onset of contraction in the normal human left ventricle. *Circulation* 59: 671-679, 1979
14. Pavel D, Swiryn S, Lam W, et al: Ventricular phase analysis of radionuclide gated studies. (Abst) *Am J Cardiol* 45: 398, 1980
15. Swiryn S, Pavel D, Byrom E, et al: Sequential regional phase mapping of radionuclide gated biventriculograms in patients with left bundle branch block. *Am Heart J* 102: 1000-1010, 1981
16. Tamaki N, Mukai T, Ishii Y, et al: Quantitative evaluation of asynchrony of the left ventricle using phase analysis. *Kakuigaku* 18: 1241-1248, 1981 (abstract in English)
17. Matsushima H, Kawai N, Suzuki A, et al: The clinical usefulness of the phase analysis of Tc-99m blood-pool imaging in patients with old myocardial infarction complicated with bundle branch block. *Kakuigaku* 23: 801-809, 1986 (abstract in English)
18. Takeda K, Maeda H, Yamaguchi N, et al: Fourier analysis of multi-gated blood-pool data in patients with congenital heart disease. *Kakuigaku* 20: 803-814, 1983 (abstract in English)
19. Takeda K: Ventricular performance in congenital left-to-right shunt: Temporal Fourier analysis of gated blood-pool data. *J Nucl Med* 24: 829-834, 1983
20. Rosenbush SW, Ruggie N, Turner DA, et al: Sequence and timing of ventricular wall motion in patients with bundle branch block. *Circulation* 66: 1113-1119, 1982
21. Weissler AM, Harris WS, Schoenfeld CD: Systolic time intervals in heart failure in man. *Circulation* 37: 149-159, 1968
22. Durrer D, Van Dam RT, Freud GE, et al: Total excitation of the isolated human heart. *Circulation* 41: 899-912, 1970
23. Amer NS, Stuckey JH, Hoffman BF, et al: Activation of the interventricular septal myocardium studied during cardiopulmonary bypass. *Am Heart J* 59: 224-237, 1960
24. Sugiura M, Okada R, Hiraoka K, et al: Histological studies on the conduction system in 14 cases of right bundle branch block associated with left axis deviation. *Jpn Heart J* 10: 121-132, 1969
25. Ohkawa S: An electrocardiographic and histological correlation study on atrioventricular conduction dis-

- turbances in the aged. *The Tokyo J of Medical Science* 85: 143–166, 1978
26. Scher AM: Excitation of the heart. In Handbook of physiology, Section 2. *Circulation* 1: 287, 1962
  27. Rosenbaum MB, Elizari MV, Lazzari JO: Los hemibloqueos. Buenos Aires, Ed Paidos, 1968
  28. Rosenbaum MB: Types of left bundle branch block. *J Electrocardiol* 2: 197–206, 1969
  29. Rosenbaum MB: The hemiblock: diagnostic criteria and clinical significance. *Mod Concepts Cardiovasc Dis* 39: 141–146, 1970
  30. Kulbertus HE: Concept of hemiblocks revisited: A histological and experimental study. *Adv Cardiol* 14: 126–135, 1975
  31. Massing GK, James TN: Anatomical configuration of the His bundle and bundle branches in the human heart. *Circulation* 53: 609–621, 1976
  32. Demoulin J, Simar LJ, Kulbertus HE: Quantitative study of left bundle branch fibrosis in left anterior hemiblock; A stereologic approach. *Am J Cardiol* 36: 751–756, 1975
  33. Sakurai M, Watanabe Y, Kondo T, et al: Left axis deviation investigated by body surface mapping and phase image analysis. *J Cardiography* 16: 207–216, 1986 (abstract in English)