

## Technetium-99m MDP scintigraphy of rhabdomyolysis induced by exertional heat stroke: A case report

Teruhito MOCHIZUKI,\* W. Newlon TAUXE,\* and Joshua A. PERPER\*\*,\*\*\*

*University of Pittsburgh School of Medicine,*

*\*Department of Radiology, Division of Nuclear Medicine,*

*\*\*Department of Epidemiology, and \*\*\*Allegheny County Coroner's Office, Pittsburgh, PA, USA*

A case of rhabdomyolysis induced by exertional heat stroke in a police officer recruit is reported. Technetium-99m methylene diphosphonate scintigraphy demonstrated marked uptake of the injured skeletal muscle. This bone-scanning agent provided an excellent means of localizing and evaluating the muscle injury of rhabdomyolysis. Nuclear medicine physicians should be aware of the special conditions and causes in which bone scan may demonstrate striking findings.

**Key words:** rhabdomyolysis,  $^{99m}\text{Tc}$ -methylene-diphosphonate ( $^{99m}\text{Tc}$ -MDP), heat stroke, exercise

### INTRODUCTION

RHABDOMYOLYSIS, a clinical and laboratory syndrome, can be caused by many conditions (Table 1) and is the result of lysis of skeletal muscle with release of cell contents, such as myoglobin and muscle enzymes.<sup>1,2</sup>

Although technetium-99m methylene diphosphonate ( $^{99m}\text{Tc}$ -MDP) is a widely used bone-scanning radiopharmaceutical, such phosphonate bone-scanning agents are also very useful for the evaluation of the myocardial<sup>3</sup> and skeletal muscle<sup>4-13</sup> injury.

We report a case of rhabdomyolysis induced by heat stroke whereby skeletal muscle injury was strikingly demonstrated by  $^{99m}\text{Tc}$ -MDP scintigraphy.

Nuclear medicine physicians should be aware of the conditions which may cause rhabdomyolysis and of its remarkable  $^{99m}\text{Tc}$ -MDP findings.

### CASE REPORT

A 25-year-old male police officer recruit performed intense physical exercise on the first day of training. The outdoor temperature was 27°C, and he was severely dehydrated. After several hours of hard training, and while running, he collapsed into convulsions and was pale and unresponsive. On arrival at a nearby hospital, he was unconscious, and his body temperature was 40.5°C.

Physical and laboratory examination revealed muscle swelling, myoglobinuria and increased creatinine phosphokinase (CPK). A diagnosis of exertional heat stroke with rhabdomyolysis was made at that time. On the fifth day after collapse, the patient was comatose, anuric, and his general condition was poor. Laboratory findings were as follows: urine myoglobin (+), RBC  $320 \times 10^4/\text{mm}$ , CPK  $> 32,000$  IU/l, T. Bilirubin 11.0 mg/dl, sGOT 5,191 IU/ml, sGPT 7,276 IU/ml. He developed acute renal failure, fulminant liver failure and encephalopathy.

On the seventh day after collapse, he was sent to our hospital, for evaluation of the liver, and if indicated, liver transplantation. Since the liver insufficiency was severe, a liver transplantation was performed on the 8th day. Over the next two weeks, he became responsive and his overall conditions improved to some extent.

Received June 26, 1990, revision accepted August 29, 1990.

For reprints contact: W. Newlon Tauxe, M.D., Division of Nuclear Medicine, Department of Radiology, Presbyterian University Hospital of Pittsburgh, DeSoto at O'Hara Streets, Pittsburgh, PA 15213

**Table 1** Etiology of Rhabdomyolysis (references #)

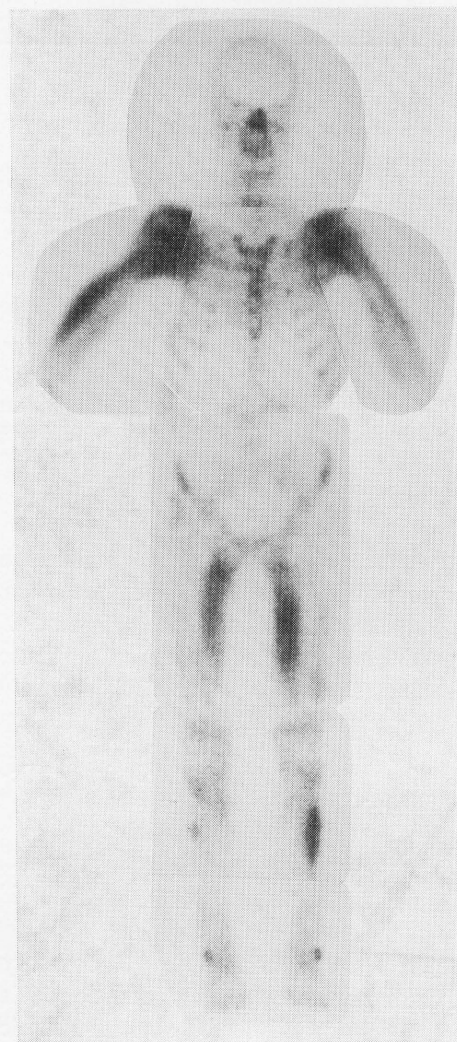
Extrinsic (traumatic, exertional)	
crush injury	(5)
prolonged compression (during operation)	(5)
exercise (overload)	(6)
seizure	
ischemia (embolism)	(7)
electric shock/burn	(8)
radiation (?)	(9)
Temperature-related	
heat stroke	(17)
malignant hyperthermia	(10, 17)
frostbite/cold weather	(11, 18)
Infection	
"flu"	(12)
sepsis	(1, 2)
Drug and toxin	
alcohol	(13)
cocaine	(19)
heroin (morphine)	(20)
snake bite	
Related muscular disease which may show positive scan	
polymyositis	
myositis ossificans	
dermatomyositis	
myophosphorylase deficiency (McArdle synd)	
phosphofructokinase deficiency	
carnitine palmityl transferase deficiency	

On the 23rd day, the patient underwent  $^{99m}\text{Tc}$ -MDP scintigraphy for the evaluation of muscle injury. The scan demonstrated marked uptake of the injured skeletal muscles (Fig. 1). Two days later (25th day), a biopsy from left deltoid muscle was obtained. Electron microgram revealed numerous myofibers under going disruption of sarcomeres and fragmentation of Z-bands. Intracellular vacuoles were noted in some myofibers. The CPK levels were plotted as a reference of muscle injury in Figure 2.

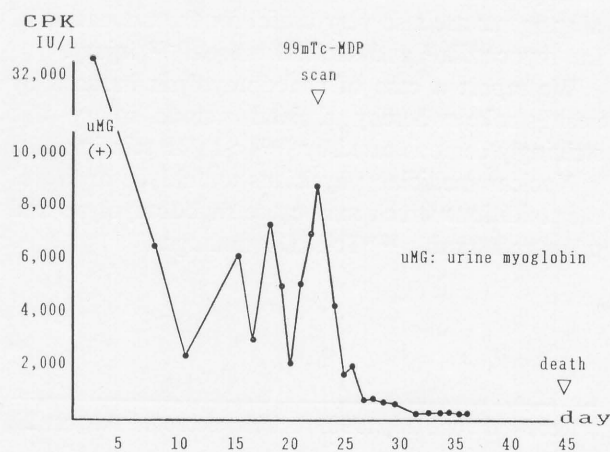
On the 45th day, the patient died from other complications, namely cerebellar hemorrhage from mycotic aneurysm, sepsis, renal failure, pancreatitis and pneumonia.

## DISCUSSION

Many conditions may cause rhabdomyolysis (Table 1). Excessive physical exercise is one of the common cause,<sup>5,6</sup> and may be more common in military recruits<sup>14</sup> or in persons who are required to perform excessive physical exercise. Martin<sup>6</sup> reported that 10 out of 11 runners who participated in a 50- to 100-mile "ultramarathon" showed  $^{99m}\text{Tc}$ -pyrophosphate uptake as a result of muscle injury during the 24- to 48-hour period after the race. After such extreme



**Fig. 1**  $^{99m}\text{Tc}$ -MDP scan demonstrates strong uptake in shoulders, upper and lower extremities, suggesting recent muscular injury as a result of rhabdomyolysis.



**Fig. 2** CPK levels are plotted. At the point of  $^{99m}\text{Tc}$ -MDP scan on the 23rd day, CPK level was still high, indicating that some degree of muscle injury continued and/or recurred.

exercise, the incidence of exertional rhabdomyolysis might not be so rare.

In addition to the primary symptoms of muscle swelling or edema, myalgia and pigmenturia, multi-organ complications may develop related with rhabdomyolysis. As shown in our case, severe exertional heat stroke accompanied by dehydration is more likely to cause renal failure, liver dysfunction, and central nervous system (cerebellar) damage, since these organs are particularly sensitive to heat exposure. Acute renal failure due to myoglobin plugs<sup>15</sup> requires immediate therapy (diuretics or dialysis, both of which were required for our patient); however, renal failure is usually reversible if the patient survives the acute phase. Hypokalemia is another condition that may develop, especially during the first three days, and it may cause lethal dysrhythmia. In most cases, liver damage is not severe; however, our patient developed fulminant liver failure. The central nervous system, especially the cerebellum, is well known to be very sensitive to heat.<sup>16</sup>

To avoid these complications, early diagnosis is required. <sup>99m</sup>Tc-phosphate scintigraphy is very sensitive to muscle injury. Since the incidence of positive findings decreased gradually after a week, the nuclear medicine physicians should be aware of the duration of these findings so that proper interpretation may be made. The degree to which the scan is positive also depends on the severity of the injury. Moreover, the muscle injury may continue and/or recur. In such cases, prolonged visualization of the injured muscle can be observed. These findings are similar to those of acute myocardial infarction which shows positive during the first to sixth day.<sup>3</sup> Some of these scans show prolonged uptake.

Our patient underwent <sup>99m</sup>Tc-MDP scintigraphy on the 23th day after the principal muscle injury occurred. Although the serum myoglobin was negative and aldolase was at the upper limit of the normal range at this time, CPK was still high (6,000–9,000 IU/l) (Fig. 2). Therefore, some degree of muscle damage seemed to be continuing. If the patient had received the scan earlier, uptake in the lesions may have been even more striking.

We demonstrated a severe case of rhabdomyolysis caused by exertional heat stroke with multi-organ complications. Muscle injury was strikingly visualized with <sup>99m</sup>Tc-MDP scintigraphy.

#### ACKNOWLEDGMENT

The authors thank Ms. Meg Sachse and Ms. Judith K Holden for their kind and fine reviewing and preparing the manuscript.

#### REFERENCES

1. Farmer JC: Rhabdomyolysis. In *Critical Care*, Civetta JM, Taylor RW, Kirby RR, (eds). Philadelphia, J B Lippincott Company, pp. 1569–1573, 1988
2. Gabow PA, Kaehny WD, Keller SP: The spectrum of rhabdomyolysis. *Medicine* 61: 141–152, 1982
3. Parkey RW, Bonte FJ, Meyer SL, et al: A new method for radionuclide imaging of acute myocardial infarction in humans. *Circulation* 50: 540–546, 1974
4. Siegel BA, Engel WK, Derrer EC: <sup>99m</sup>Tc-diphosphonate uptake in skeletal muscle: a quantitative index of acute damage. *Neurology* 25: 1055–1058, 1975
5. Frymoyer PA, Giammarco R, Farrar FM, et al: Technetium-99m medronate bone scanning in rhabdomyolysis. *Arch Intern Med* 145: 1991–1995, 1985
6. Matin P, Lang G, Carretta R, et al: Scintigraphic evaluation of muscle damage following extreme exercise: concise communication. *J Nucl Med* 24: 308–311, 1983
7. Floid JL, Prather JL: <sup>99m</sup>Tc-EHDP uptake in ischemic muscle. *Clin Nucl Med* 2: 281–282, 1977
8. Hunt J, Lewis S, Parkey RW, et al: The use of technetium-99m stannous pyrophosphate scintigraphy to identify muscle damage in acute electric burns. *J Trauma* 19: 409–413, 1979
9. Bekier A: Extrasosseous accumulation of Tc-99m pyrophosphate in soft tissue after radiation therapy. *J Nucl Med* 19: 225–226, 1978 (letter)
10. Murakawa M, Hatano Y, Mori K, et al: Technetium-99m pyrophosphate scintigraphy in a patient with malignant hyperthermia. *J Nucl Med* 30: 718–719, 1989 (letter)
11. Rosentall L, Kloiber R, Gagnon R, et al: Frostbite with rhabdomyolysis and renal failure: radionuclide study. *AJR* 137: 387–390, 1981
12. Akashi T, Aikawa N, Uchiyama F, et al: A case of rhabdomyolysis demonstrated by <sup>99m</sup>Tc methylene diphosphonate bone scan. *Kaku Igaku* 23: 1479–1483, 1986
13. Silberstein EB, Bove KE: Visualization of alcohol-induced rhabdomyolysis: a correlative radiotracer, histochemical, and electronmicroscopic study. *J Nucl Med* 20: 127–129, 1979
14. Olerud JE, Homer LD, Carroll HW: Incidence of acute exertional rhabdomyolysis: serum myoglobin and enzyme levels as indicators of muscle injury. *Arch Intern Med* 136: 692–697, 1976
15. Nimmo GR, Lambie AT, Cumming AD: Rhabdomyolysis and acute renal failure. *Intensive Care Med* 15: 486–487, 1989
16. Farmer JC: Temperature-related injuries. In *Critical Care*, Civetta JM, Taylor RW, Kirby RR, (eds.), Philadelphia, J B Lippincott Company, pp 693–700, 1988
17. Raifman MA, Berant M, Lenalsky C: Cold weather and rhabdomyolysis. *J Pediatr* 93: 970–971, 1978
18. Singhal P, Horowitz B, Quinones MC, et al: Acute renal failure following cocaine abuse. *Nephron* 52: 76–78, 1989
19. D'Agostino RS, Arnett EN: Acute myoglobinuria and heroin snorting. *JAMA* 241: 277, 1979