

## A case of intermittent bleeding Meckel's diverticulum

Takeyoshi IMAEDA,\* Masayuki KANEMATSU,\* Yasuhiro SONE,\* Gen IINUMA,\*  
Yoshiaki HIROSE,\* Kiichi MIYA,\*\* and Kuniyasu SHIMOKAWA\*\*\*

*\*Departments of Radiology, \*\*Second Surgery and \*\*\*Laboratory Medicine,  
University of Gifu School of Medicine*

The initial technetium-99m pertechnetate abdominal scintigraphy revealed equivocal or normal results. However, a second scintigraphy without pentagastrin demonstrated a focal area of persistently increasing radioactivity in the right lower quadrant of the abdomen.

At surgery, Meckel's diverticulum was confirmed, and histological examination of the excised specimen revealed that it was lined with ectopic gastric mucosa.

It has not been satisfactorily explained why the initial imaging failed to demonstrate the ectopic gastric mucosa. The necessity to perform repeated scintigraphy must be emphasized because 50 to 91 percent of bleeding Meckel's diverticula in the pediatric age group are said to contain gastric mucosa.

**Key words:** Meckel's diverticulum, intermittent bleeding, repeated scintigraphy

### INTRODUCTION

MECKEL'S diverticulum, a remnant of the omphalomesenteric duct, is generally acknowledged to be the most common congenital anomaly of the small intestine. It is a true diverticulum, containing all layers of the gut wall, and is usually found on the antimesenteric border within 100 cm proximal to the ileocecal valve. The common symptoms are intestinal obstruction, inflammation or lower intestinal hemorrhage. The last is the most common in the pediatric age group, and obstruction and inflammation predominate in the adult.

This report describes an interesting case of intermittent lower intestinal hemorrhage in an infant and reviews the literature on Meckel's diverticulum.

### CASE REPORT

A 7-month-old male infant was hospitalized on April 21, 1989, because of tarry stool during the

preceding 24 hours. The skin and mucous membranes were pale. The abdomen was soft and non-tender, and no masses were palpable. Initial laboratory data obtained on admission revealed marked hypochromic and microcytic anemia (MCV; 75.8 fl, MCH: 25.1 pq), with a red blood cell count of  $363 \times 10^4/\text{mm}^3$ , hematocrit of 27.4% and hemoglobin of 9.2 g/dl. The occurrence of chronic blood loss was suspected from these symptoms. Coagulation studies were normal.

No mass shadow or abnormal gas was found in conventional roentgenogram of the abdomen. The results of barium enema with air contrast, upper gastrointestinal series and small-bowel series with barium, and colonofiberscopy were normal. Occult blood in the stool turned negative on the 7th hospital day. On the 11th hospital day, after a period of overnight fasting and intravenous injection of 2 mCi (74 MBq) of technetium-99m pertechnetate, a dynamic study of the abdomen was performed with a gamma camera and a high-resolution collimator, at 3-sec intervals for 60 sec to examine blood flow and blood-pool patterns.

Static images of the abdomen were then taken at 15-min intervals for 60 min and then at 1-hour intervals for 6 hours, with 200,000 counts of accumulation of radioactivity attained for the first image.

Received June 21, 1990, revision accepted August 1, 1990.

Reprint contact: Takeyoshi Imaeda, M.D., Department of Radiology, University of Gifu School of Medicine, 40 Tsukasamachi, Gifu City, 500, JAPAN.

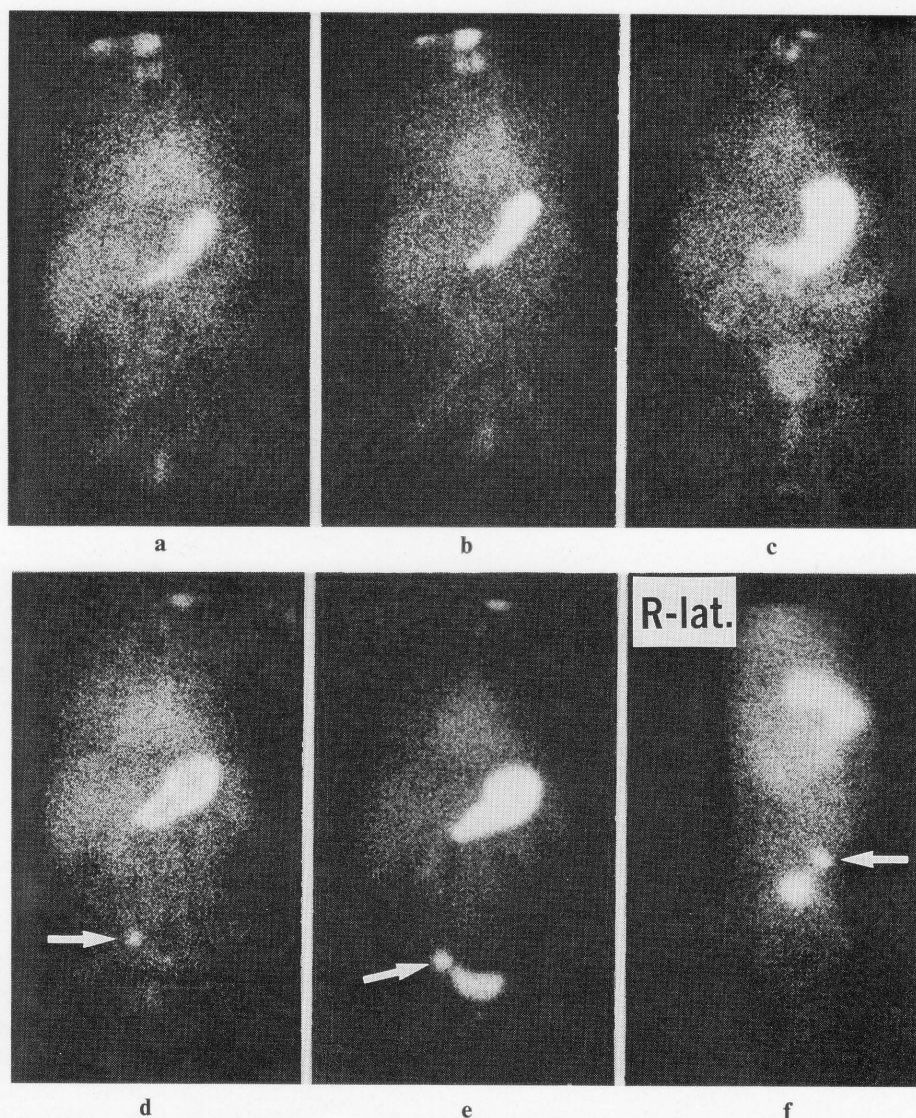
The subsequent images were taken under the same conditions of times and intensity as the first. No dosage of cathartic or potassium perchlorate was administered as premedication at that time.

This serial scintigraphy did not reveal any focal area of persistently increasing radioactivity in the right lower quadrant of the abdomen (Fig. 1a-c). Occult blood in the stool was persistently negative after the 7th hospital day and no etiology of tarry stool could be confirmed by various studies. The patient was discharged 12 days after admission.

However, a stool was found containing bright red bleeding on the 43rd day after discharge and the patient was hospitalized again.

Hemoglobin level was 7.8 g/dl at that time. The second technetium-99m pertechnetate abdominal imaging was performed on the 7th day after the rehospitalization and showed a focal, almost round area of persistently increasing radioactivity in the right lower quadrant of the abdomen. It appeared simultaneously with increasing radioactivity in the stomach at 10 min after injection of the radionuclide and radioactivity increased in parallel in both areas (Fig. 1d-e). Occult blood in the stool became negative again on the 16th day after the second hospitalization.

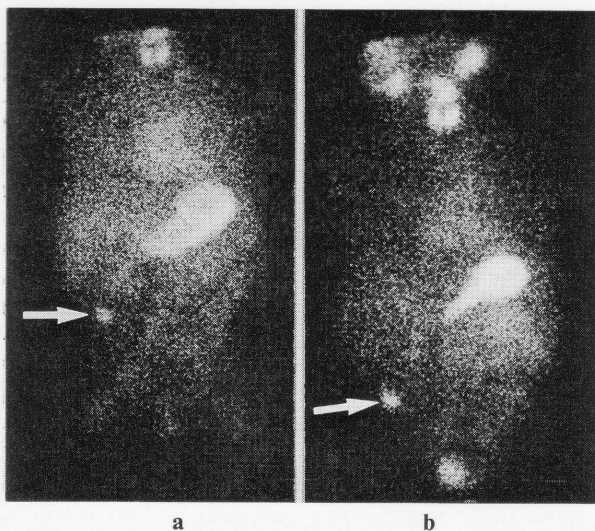
The third technetium-99m pertechnetate abdominal imaging was performed on the 59th day after rehospitalization to confirm reproducibility.



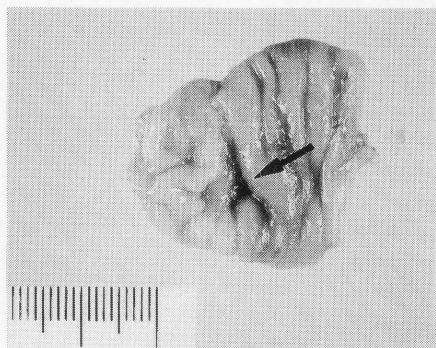**Fig. 1** An initial abdominal survey at 10 min (a), 45 min (b), and 6 hr (c) after injection of radiopertechnetate is interpreted as normal or minimally suspicious (upper row). 49 days later, another study at 10 min (d) without using pentagastrin reveals a well-defined, small, almost rounded area of increasing radioactivity (arrow) in the right lower quadrant of the abdomen, and it gradually became more evident with the passage of time in parallel with increasing radioactivity in the stomach at 45 min (e, f) (arrow) (lower row).

The area of increasing radioactivity had shifted to near the umbilicus as compared to that in the second imaging and the activity had become more evident with time (Fig. 2). From these symptoms, we diagnosed it as Meckel's diverticulum.

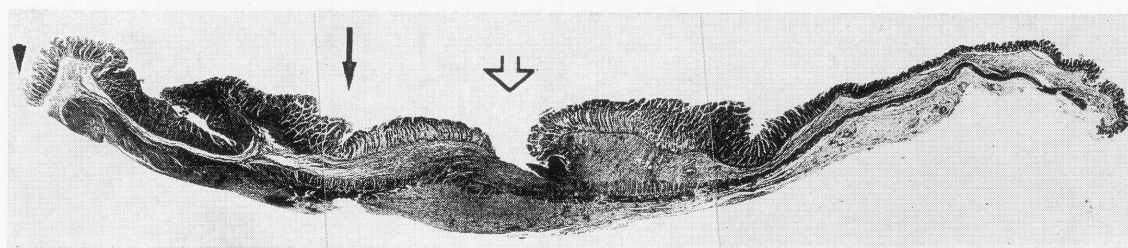
Surgery was performed on the 66th day after re-hospitalization.



**Fig. 2** The 3rd scintigrams at 10 min (a) and 45 min (b) show that the focal area of increasing radioactivity has changed in position to a more cranial region, compared with the 2nd study (arrow).



**Fig. 3** An ulceration is identified in Meckel's diverticulum (arrow).



**Fig. 4** Photomicrograph of surgical resected specimen shows ectopic gastric mucosa (between arrow and arrow-head). Peptic ulcer seen in the ileal mucosa was the cause of hemorrhage (open-arrow).

A Meckel's diverticulum 4 cm × 2 cm in size was identified approximately 50 cm proximal to the ileocecal valve, and it was resected.

The gross surgical specimen contained a 3 mm × 7 mm reddish fresh ulcer.

Histological examination revealed that the ulcer was located in the ileal mucosa, while the remainder of the diverticulum was lined with ectopic gastric mucosa (Fig. 3). The rectal bleeding was attributed to the ulcer.

The patient was discharged on the 75th day after rehospitalization with hemoglobin of 11.6 g/dl, and there have been no further episodes of bleeding over a follow-up period of more than 10 months.

## DISCUSSION

The incidence of Meckel's diverticulum has been reported to be about 1 to 3 percent in an autopsy series.<sup>1-3</sup> The male to female ratio in asymptomatic cases found incidentally at surgery or autopsy is almost equal, but in symptomatic cases it is more common in males in ratios ranging from 1.8: 1 to 5: 1.<sup>3-5</sup>

Meckel's diverticulum is found within 100 cm proximal to the ileocecal valve in more than 90 percent of the cases.<sup>6</sup> Anatomically, the diverticulum is always found on the antimesenteric border of the small bowel and the structure exhibits all three layers of the intestinal wall.<sup>7</sup>

Meckel's diverticulum usually contains ileal mucosa, but heterotopic tissue may be present, such as gastric, duodenal or colonic mucosa, or pancreatic tissue.

The incidence of heterotopic tissue in Meckel's diverticulum is 31 to 57 percent in the symptomatic cases, compared to only 6 to 16 percent in the asymptomatic cases in whom Meckel's diverticulum is found incidentally.<sup>4,8</sup>

The incidence of ectopic gastric mucosa in patients with intestinal hemorrhage is estimated to be between 50 and 91 percent.<sup>9-11</sup>

Intestinal hemorrhage results from mucosal ulcera-

tion in the diverticulum or adjacent ileum caused by HCL and pepsin. Other common complications are diverticulitis, perforation or intestinal obstruction either due to volvulus around the peritoneal bands connecting Meckel's diverticulum to the umbilicus or to intussusception with the diverticulum as the lead point. The incidence of clinical symptoms secondary to Meckel's diverticulum is approximately 15 to 40 percent.<sup>7,12</sup>

Age, the amount of gastric mucosa, the length and width of Meckel's diverticulum, and the presence of mesodiverticular bands seem to be the determining factors in the likelihood of symptoms developing.<sup>4,13,14</sup>

Technetium-99m pertechnetate is selectively accumulated and subsequently excreted into the bowel lumen by the mucoid surface cells of the gastric mucosa.<sup>15</sup> The accumulation of detectable amounts of technetium-99m pertechnetate is dependent on adequate blood flow to the mucosa, the size of the mucosal area and its excretory capability.

The critical area necessary for scintigraphic detection in animal experiments was estimated to be a 1.0 cm cuff or 1.8 sq cm of normal gastric mucosa.<sup>16,17</sup> In a clinical study, the length of the ectopic gastric mucosal area ranges from 10 to 40 mm (average 21 mm) in positive cases, and from 5 to 13 mm (average 9 mm) in negative cases.<sup>18</sup>

The sensitivity of technetium-99m pertechnetate scans in surgically confirmed Meckel's diverticulum ranges from 75 to 85 percent. The specificity and accuracy has been reported to be 79 to 100 percent and 78 to 90 percent, respectively, in several studies.<sup>15,18,19</sup>

The absence or a small amount of gastric mucosa, dilution and wash-away of the activity by hemorrhage or bowel hypersecretion and/or motility, impaired blood flow and suboptimal scan technique have been reported as possible causes of a false negative scan.

This present case does not seem to have been caused by any of the above mentioned.<sup>15</sup> The reason why the abnormality could not be detected on the initial scintigraphy was not determined.

However, a clear image of Meckel's diverticulum was demonstrated through repeated scintigraphy without the use of pentagastrin in this case.

## REFERENCES

1. Sloan RD, Stafford ES, Singewald ML, et al: Meckel's diverticulum. *AJR* 71: 64-75, 1954.
2. Jay GD, Margulis RR, McGraw AB, et al: Meckel's diverticulum. A survey of one hundred and three cases. *Arch Surg* 61: 158-169, 1950.
3. McParland FA, Kiesewetter WB: Meckel's diverticulum in childhood. *Surg Gynecol Obstet* 106: 11-14, 1958.
4. Leijonmarck CE, Bonman-Sandelin K, Frisell J, et al: Meckel's diverticulum in the adult. *Brit J Surg* 73: 146-149, 1986.
5. Michas CA, Cohen SE, Wolfman EF Jr: Meckel's diverticulum. Should it be excised incidentally at operation?. *Am J Surg* 129: 682-685, 1975.
6. Kiesewetter WB: Meckel's diverticulum in children. *Arch Surg* 75: 914-919, 1957.
7. Castleden WM: Meckel's diverticulum in an umbilical hernia. *Brit J Surg* 57: 932-934, 1970.
8. Rutherford RB, Akers DR: Meckel's diverticulum: A review of 148 pediatric patients, with special reference to the pattern of bleeding and to mesodiverticular vascular bands. *Surgery* 59: 618-626, 1966.
9. Ho JE, Konieczny KM: The sodium pertechnetate Tc-99m scan: An aid in the evaluation of gastrointestinal bleeding. *Pediatrics* 56: 34-40, 1975.
10. Weinstein EC, Cain JC, ReMine WH, et al: Meckel's diverticulum: 55 years of clinical and surgical experience. *JAMA* 182: 251-253, 1962.
11. Meguid MM, Wilkinson RH: Futility of barium sulfate in diagnosis of bleeding Meckel diverticulum. *Arch Surg* 108: 361-362, 1974.
12. Kilpatrick ZM: Scanning in diagnosis of Meckel's diverticulum. *Hosp Pract* 9: 131-138, 1974.
13. Brown CK, Olshaker JS: Meckel's diverticulum. *Am J Emerg Med* 6: 157-164, 1988.
14. Mackey WC, Dineen P: A fifty year experience with Meckel's diverticulum. *Surg Gynecol Obstet* 156: 56-64, 1983.
15. Sfakianakis GN, Conway JJ: Detection of ectopic gastric mucosa in Meckel's diverticulum and in other aberrations by scintigraphy: II. Indications and methods- A 10-year experience. *J Nucl Med* 22: 732-738, 1981.
16. Safaie-Shirazi S, Chaudhuri TK, Chaudhuri TK, et al: Visualization of isolated retained antrum by using technetium-99m. *Surgery* 73: 278-283, 1973.
17. Priebe CJ Jr, Marsden DS, Lazarevic B: The use of <sup>99m</sup>Tc pertechnetate to detect transplanted gastric mucosa in the dog. *J Pediatr Surg* 9: 605-613, 1974.
18. Fries M, Mortensson W, Robertson B: Technetium pertechnetate scintigraphy to detect ectopic gastric mucosa in Meckel's diverticulum. *Acta Radiol Diagn* 25: 417-422, 1984.
19. Conway JJ: The sensitivity, specificity and accuracy of radionuclide imaging of Meckel's diverticulum. *J Nucl Med* 17: 553, 1976.