

## Accumulation of Technetium-99m MDP in pseudomyxoma peritonei

Toshiyuki KIDA,\* Fukumi TSUDA,\* Yuhji FUJITA,\*\* Shiro MUNAKATA\*\* and Mikindo SASAKI\*\*

\*Department of Radiology, Division of Nuclear Medicine, Kyushinkai Cardiovascular Disease Hospital

\*\*Department of Radiology, Division of Nuclear Medicine, Ohta's Nishinouchi General Hospital

An ovarian mucinous cystadenocarcinoma which moderately accumulated Tc-99m MDP was imaged during a whole body bone scan. The primary tumor and its implants in the peritoneal cavity were both visualized and correlated with US and TCT scan findings. As a result, the radiopharmaceutical distribution accurately delineated the primary tumor and the region of tumor involvement within the peritoneal cavity. Therefore, a whole body bone scan offers a potential method for assessing neoplastic size and spread.

**Key words:** Whole body bone scan, Tc-99m-MDP, Pseudomyxoma peritonei, Mucinous cystadenocarcinoma, Ovary

### INTRODUCTION

PSEUDOMYXOMA peritonei is a rare complication of mucocoele or adenocarcinoma of the appendix and cystadenoma or cystadenocarcinoma of the ovary. It occurs when these mucin-producing lesions rupture into the peritoneum, releasing their mucinous contents into the abdominal cavity.

Conventional radiological findings of pseudomyxoma peritonei are elusive and nonspecific, and preoperative diagnosis is extremely difficult.<sup>1</sup> The advent of transmission computed tomography (TCT) and ultrasonography (US) of the body has now made it possible to suggest the correct preoperative diagnosis.<sup>2,3</sup>

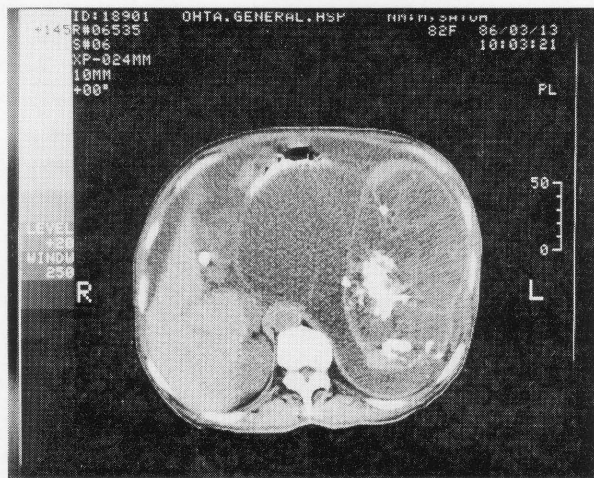
In this paper, we report that Tc-99m methylene diphosphonate (MDP) accumulated moderately in the primary tumor site and focally in the abdominal cavity in a case in whom, in the preoperative diagnosis, the site of origin and pseudomyxoma peritonei was confirmed by means of TCT and US.

Received November 17, 1989, revision accepted July 31, 1990.

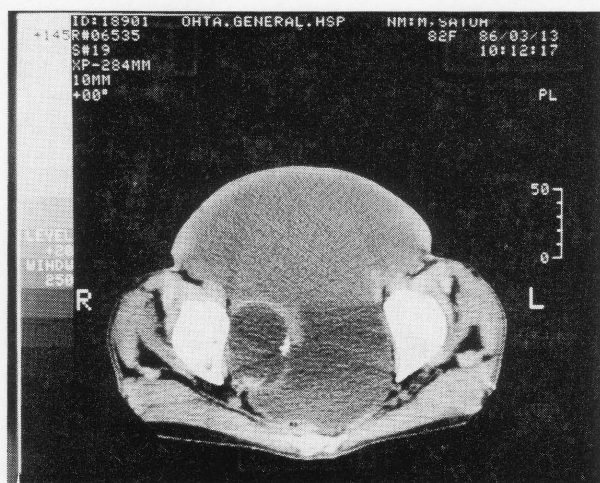
For reprints contact: Toshiyuki Kida, M.D., Department of Radiology, Division of Nuclear Medicine, Kyushinkai Cardiovascular Disease Hospital, 20-1 Tsujinouchi, Hohkida-Aza, Fukushima-city, Fukushima 960, JAPAN.

### CASE REPORT

An 82-year-old woman had a history of gradual weight loss, decreased appetite, and a bloating abdomen. Physical examination revealed a large mass in the left upper quadrant and in the middle lower regions respectively, of the abdomen, muscle wasting, clinical signs of ascites and edema of the lower extremities. An upper GI series and a barium enema were normal except for displacement of the stomach to the right side and of the transverse colon to the lower side consistent with the intraperitoneal masses. Abdominal US revealed a gallstone, septations throughout the huge spleen and a collection of a large amount of viscous ascitic fluid (not shown). Paracentesis produced 3,000 ml of mucinous fluid with no malignant cells seen on cytological examination. In the search for the primary lesion, TCT of the abdomen and pelvis was performed. TCT of the abdomen revealed mucinous ascites associated with scalloping of the right lateral border of the liver without intrinsic hepatic involvement, and the greatly enlarged spleen occupied by multilocular cystic masses with calcifications (Fig. 1). TCT of the pelvis revealed that the right ovarian cyst was characterized by an attenuation value similar to that of water but slightly less than soft-tissue and had a calcified wall (Fig. 2). However, there were no calcifications or active bone formations anywhere within the peritoneal cavity except for splenic calcifications. A

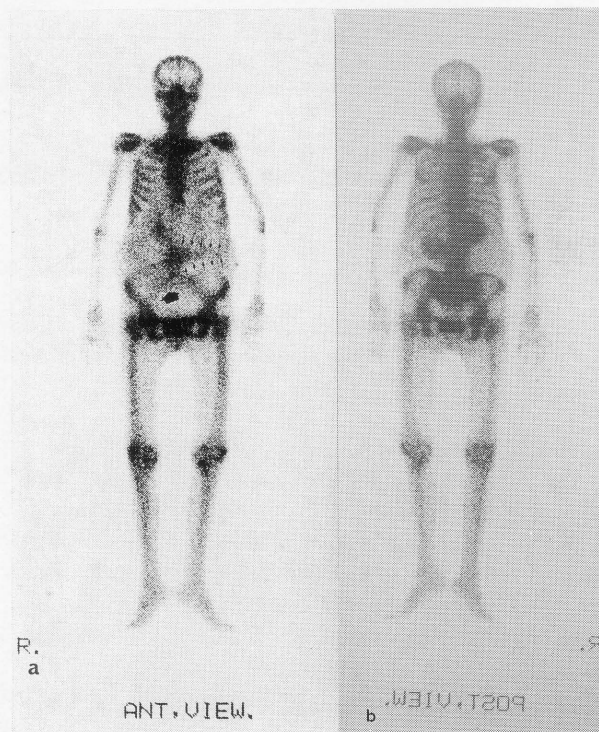


**Fig. 1** TCT of mid-abdomen shows mucinous material in peritoneal cavity, scalloping of the right lateral border of the liver without intrinsic hepatic involvement and greatly enlarged spleen occupied by multilocular cystic masses with calcifications.



**Fig. 2** TCT of pelvis shows right ovarian cyst with partially calcified wall.

liver-spleen scan obtained following intravenous administration of 5 mCi (185 MBq) Tc-99m-phytate showed a slightly enlarged liver with the suggestion of an extrinsic photon-attenuating process overlying the left lobe of the liver but without intrinsic hepatic involvement. The delineation of the enlarged spleen was poor and only its margin was delineated in the left lateral view (not shown). A bone scan performed 3 hours after an intravenous injection of 20 mCi (740 MBq) Tc-99m-MDP demonstrated no abnormal skeletal uptake except for an accumulation of radioactivity due to hydronephrosis of the right kidney (Fig. 3a, b). However, a moderate accumulation of Tc-99m MDP was demonstrated in the primary tumor site and focused in the region corresponding

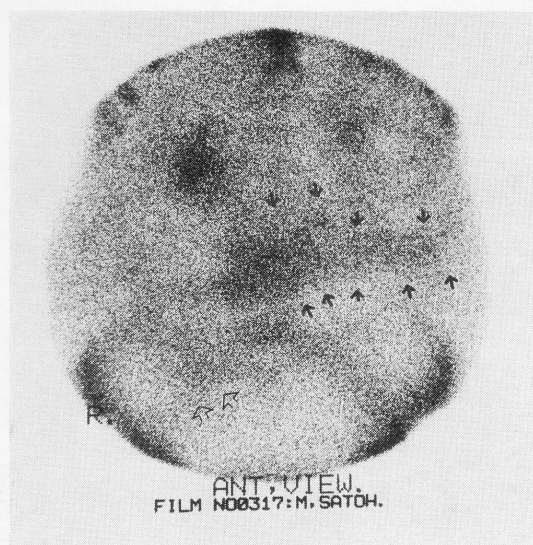


**Fig. 3** Tc-99m-MDP bone scan. **a:** Anterior view demonstrates focally increased activity in the middle lower abdomen (arrows) and moderately active focus in the primary tumor site (large black arrow). **b:** Posterior view demonstrates no abnormal skeletal uptake except for accumulation of radioactivity due to hydronephrosis of the right kidney.

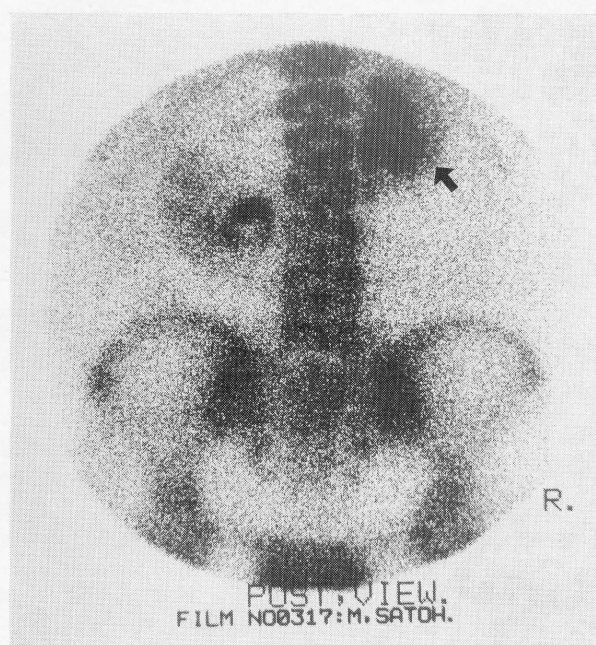
to a palpable mass in the middle lower abdomen (Fig. 4a, b). An exploratory laparotomy revealed a mucinous cystadenocarcinoma of the right ovary as well as a large volume of free mucinous material. In addition, several semi-solid gelatinous masses coated the entire surface of the peritoneum, including the bowel loops and omentum. The focally increased activity visualized in the middle lower abdomen (Fig. 4a) was confirmed to be due to bowel loops.

## DISCUSSION

The terms pseudomyxoma peritonei, first coined by Werth<sup>4</sup> in 1884, refers to the accumulation of large amounts of mucinous material within the peritoneal cavity. It is characterized by multiple, usually massive implants containing abundant gelatinous or myxomatous material, either benign or malignant, which are distributed over the peritoneal surfaces of the abdominal wall and intra-abdominal viscera in the form of multiple cysts, or of rarely homogeneous sheets. The most common primary sites are the ovary and appendix, although other sites such as the colon,



a



b

**Fig. 4** Spot-image of the lower abdomen and pelvis. **a:** Anterior view demonstrates accumulation of MDP moderately in the right ovarian region (open arrow) and focally in the region corresponding to a palpable abdominal mass in the middle lower abdomen (small arrows). **b:** Posterior view demonstrates accumulation of the radioactivity due to hydronephrosis of the right kidney (arrow)

stomach, uterus and pancreas have been reported. Often the site of origin is not clear due to extensive organ involvement.

The conventional radiographic findings of pseudomyxoma peritonei are non-specific. Pugh<sup>5</sup> reported a case of pseudomyxoma peritonei characterized radiographically by soft-tissue masses and calci-

fications scattered about the abdomen. In case where the distinctive calcific deposits are absent, plain abdominal films, excretory urograms, or barium study of the gastrointestinal tract may show evidence of soft-tissue masses but are generally nondiagnostic.

Recently, sonographic and computed tomographic findings of pseudomyxoma peritonei have been described.<sup>1,2,3</sup> The characteristic sonographic and computed tomographic findings, according to Seshul and Coulam, are peritoneal scalloping of the liver margin due to pressure from adjacent peritoneal implants and the presence of septations within the mucinous ascitic fluid. Both of these findings were present on the sonography and the TCT scan of our patient and our patient's condition strongly suggests pseudomyxoma peritonei.

The interesting bone radionuclide scan finding in this case, that is, the increased localized activity in the middle lower abdomen and the right side of the pelvis, was diagnostically significant and supported the clinical impressions in US and TCT.

Soft-tissue uptake of bone-seeking radiopharmaceuticals has been well recognized in the literature. Although the exact mechanism of the uptake is still not clear, numerous factors have been suggested as potential causes affecting accumulation in nonosseous sites. Most reports agree that hypercalcemia<sup>6</sup> and metastatic calcification<sup>6-9</sup> are almost always present in sites accumulating Tc-99m-phosphate compounds. It is generally believed that these compounds are localized by chemisorption to the hydroxyapatite crystals of calcifying structures.<sup>10</sup> The process, however, fails to elucidate the mechanism of extrasosseous uptake of these radio-pharmaceuticals, when neither calcifications nor active bone formations are demonstrable.

An accumulation of Tc-99m-diphosphonate in malignant pleural effusion was initially reported by Siegel et al,<sup>11</sup> but these authors did not describe its mechanism. Aprile et al<sup>12</sup> suggested that the localization of Tc-99m-pyrophosphate could be related to the presence of calcium and acid phosphatase and they supported the so-called enzymatic receptor theory proposed by Schmitt et al<sup>13</sup> and Zimmer et al.<sup>14</sup> Silberstein et al<sup>15</sup> reported that there was a correlation between tissue accumulation of Tc-99m-diphosphonate and the calcium content in tissues, but at present there is no universal agreement on the association between the amount of calcium present in the soft-tissue and the degree of uptake of Tc-99m-phosphate compounds. In our study,<sup>16</sup> the radiopharmaceutical accumulated in pleural effusion was proved to be Tc-99m-MDP itself by radiochromatography, and the contents of the effusion were proved to be similar to those of peripheral blood by chemical analysis. Thus we concluded that it would seem more



reasonable to assume as an explanation for the accumulation mechanism of Tc-99m-MDP in serous effusions that the radiopharmaceutical exudes directly from peripheral vessels to the serous cavity along with the increased blood flow, the increased vascularity and vascular permeability.

Meanwhile, Teplick et al,<sup>17</sup> Gates<sup>18</sup> and Vorne<sup>19</sup> described cases of uptake of bone-seeking radiopharmaceuticals in sites of peritoneal metastases from ovarian carcinoma. According to Vorne and Saukko, two ovarian carcinomas were seen as moderately active foci in the primary tumor site; metastases of ovarian carcinomas of two patients accumulated MDP focally in the abdominal cavity; and in three patients with metastases of carcinoma of the ovary, a diffuse widespread abdominal cavity was seen due to the accumulation of the radiopharmaceutical in the peritoneum and/or ascitic fluid. With regards to mucinous adenocarcinoma, Kirby et al<sup>20</sup> reported one case of mucinous adenocarcinoma of the rectum with metastases to the liver. On the other hand, Gorden et al<sup>21</sup> reported seven cases of malignant ascites which showed a diffuse accumulation of Tc-99m-MDP over the abdomen, but there were no cases with pseudomyxoma peritonei.

The only report on the uptake of Tc-99m-MDP in pseudomyxoma peritonei is that of Tu'meh et al<sup>22</sup>, to our knowledge. Therefore, this case presents an additional example of non-osseous accumulation of Tc-99m phosphate compounds in the metastatic lesions from ovarian mucinous cystadenocarcinoma. However, the exact mechanism of non-osseous accumulation of bone scanning agents is still unclear; although there have been several proposed mechanisms, including increased blood flow and vascularity, altered capillary permeability, and binding of phosphate to the bone matrix and focal areas of calcification.<sup>23,24</sup> As none of the tumor deposits in our case contained detectable calcifications, increased blood flow and vascular permeability seem more reasonable explanations for the accumulation of Tc-99m-MDP within pseudomyxoma peritonei.

Our results suggest that Tc-99m-MDP whole body bone scan is a potential means of assessing the primary tumor and its implants in the peritoneal cavity. However, one must also remember that it is not easy to see the pathological accumulation in ovaries because the uptake in the pelvic bones and sacroiliac joints has a considerable disturbing effect.

## REFERENCES

- Mayes GB, Chuang VP, Fisher RG: CT of pseudomyxoma peritonei. *AJR* 136: 807-808, 1981
- Seshul MB, Coulam CM: Pseudomyxoma peritonei: computed tomography and sonography. *AJR* 136: 803-806, 1981
- Yeh HC, Shafir MK, Slater G, et al: Ultrasonography and computed tomography in pseudomyxoma peritonei. *Radiology* 153: 507-510, 1984
- Werth R, Cited by Balthazar EJ, Javors BR: Pseudomyxoma peritonei, clinical and radiographic features. *Am J Gastroenterol* 68: 501-509, 1977
- Pugh DG: A roentgenologic aspect of pseudomyxoma peritonei. *Radiology* 39: 320-322, 1941
- Arbona GL, Antonmatte S, Tetelman MR, et al: Tc-99m-diphosphonate distribution in a patient with hypercalcemia and metastatic calcifications. *Clin Nucl Med* 5: 422, 1980
- Delcourt E, Boudoux M, Neve P: Tc-99m-MDP bone scanning detection of gastric calcification. *Clin Nucl Med* 12: 546-547, 1980
- de Graff P, Schinct IM, Pauwels EKJ, et al: Bone scintigraphy in uremic pulmonary calcification. *J Nucl Med* 20: 201-206, 1979
- Rosenthal DL, Chandler HL, Azizi F, et al.: Uptake of bone imaging agents by diffuse pulmonary metastatic calcification. *AJR* 129: 871-874, 1977
- Francis MD, Slough CL: Factors affecting uptake and retention of technetium-99m-diphosphonate and 99m-pertechnetate in osseous, connective, and soft tissue. *Calcif Tissue Res* 20: 303-311, 1976
- Siegel ME, Walker WJ, Jr. Cambel JL: Accumulation of Tc-99m-diphosphonate in malignant pleural effusions: detection and verification. *J Nucl Med* 16: 883-885, 1975
- Aprile C, Bernardo G, Carena et al: Accumulation of Tc-99m pyrophosphate in pleural effusions. *Eur J Nucl Med* 3: 219-222, 1978
- Schmitt GH, Holmes RA, Isitman AT, et al: A proposed mechanism for Tc-99m-labeled polyphosphate and diphosphate uptake by human breast tissue. *Radiology* 112: 733-735, 1974
- Zimmer AM, Isitman AT, Holmes RA: Enzymatic inhibition of diphosphonate: a proposed mechanism of tissue uptake. *J Nucl Med* 16: 352-356, 1975
- Silberstein EB, Francis MD, Tofe AJ, et al: Distribution of Tc-99m-Sn-diphosphonate and free Tc-99m-pertechnetate in selected soft and hard tissues. *J Nucl Med* 16: 58-61, 1975
- Kida T, Hujita Y, Sasaki M, et al: Accumulation of Tc-99m-methylene diphosphate in malignant pleural and ascitic effusion. *Oncology* 41: 427-430, 1984.
- Teplick JG, Haskin ME, Alavi A: Calcified intraperitoneal metastases from ovarian carcinoma. *AJR* 127: 1003-1006, 1976
- Gates GF: Ovarian carcinoma imaged by Tc-99m-pyrophosphate: Case report. *J Nucl Med* 17: 29-30, 1976
- Vorne M, Saukko T: Detection of malignant soft tissue tumors in bone imaging. *Eur J Nucl Med* 9: 180-184, 1984
- Kirby JC, Bartow JH, Dressor TP, et al: Accumulation of MDP in hepatic metastases from mucinous adenocarcinoma of the colon. *Clin Nucl Med* 7: 25-27, 1982

21. Gordon L, Shabel SI, Holland RD, et al: Tc-99m-methylene diphosphonate accumulation in ascitic fluid due to neoplasm. *Radiology* 139: 699-702, 1981
22. Tu'meh SS, Polak JF, Kaplan WD: Uptake of Tc-99m-MDP by pseudomyxoma peritonei: A case report. *Eur J Nucl Med* 8: 364-366, 1983
23. Jones AG, Francis MD, Davis MA: Bone scanning: radionuclidic reaction mechanisms. *Semin Nucl Med* 6: 3-18, 1976
24. Kim EE, Domstad PA, Choy YC, et al: Accumulation of Tc-99m phosphate complexes in metastatic lesions from colon and lung carcinoma. *Eur J Nucl Med* 5: 299-301, 1980