

A large degenerated subserous leiomyoma of the uterus: uncommon scintigraphic and ultrasonographic findings

Hiromi INOUE,* Nobuyuki AIZAWA,** Tomikazu MIZUNO,*** Tsunehiro AKASHI,**
Toshio SHIMIZU,** Yasuyoshi FUKUSHIMA* and Yutaka SUZUKI****

*Department of Obstetrics and Gynecology Chigasaki Tokushukai Medical Center
Chigasaki, Kanagawa Prefecture, Japan 253

**Department of Internal Medicine Chigasaki Tokushukai Medical Center
Chigasaki, Kanagawa Prefecture, Japan 253

***Department of Radiology St. Luke's International Hospital Tokyo, Japan 104

****Department of Nuclear Medicine Tokai University School of Medicine
Isehara, Kanagawa Prefecture, Japan 259-11

Bone imaging is commonly used as a sensitive indicator of metastatic bone diseases or other bone pathology. Furthermore, it is now generally known that technetium-99m (^{99m}Tc) phosphonates tend to concentrate in various tissues other than bones. Ultrasonography is also widely used for the evaluation of pelvic masses. Ultrasonography is especially useful for detecting a cystic mass.

We present a case where the uptake of ^{99m}Tc phosphonate compounds occurred in the entire abdomen, and ultrasonography suggested a diagnosis of pseudomyxoma peritonei, but the condition was later proven to be degeneration of giant subserous leiomyoma of the uterus.

We have found two interesting features in this case. One is the ^{99m}Tc phosphonate concentration in the large cystic and hyaline degeneration of subserous leiomyoma of the uterus without calcification, and the other is the sonographic finding of a large echogenic mass with innumerable small anechoic areas.

To our knowledge, no cases of ^{99m}Tc phosphonate concentration in non-calcified leiomyoma of the uterus have been demonstrated.

Key words: ^{99m}Tc -MDP, Ultrasonography, Leiomyoma, Uterus, Degeneration

CASE REPORT

A 43-year-old woman, gravida 2, para 2, was admitted to the Chigasaki Tokushukai Medical Center on February 25, 1986 with bilateral leg edema and abdominal distension for the previous one month.

Her past medical history disclosed a right oophorectomy and an appendectomy at the age of 39. Her menstrual history was normal.

On physical examination, height was 160 cm,

weight 56 kg, temperature 36.2°C, pulse rate 72 and regular, and blood pressure 100/52. The abdomen was soft, but slightly distended without tenderness. Pelvic examination revealed an elastic mass of an indefinite size in the pelvic cavity, and it was difficult to distinguish the uterus from the large mass. An abdominal roentgenogram suggested a large soft tissue mass in the lower abdomen without calcification.

Ultrasound examination revealed a large echogenic mass with innumerable small anechoic areas. The mass was separated from the normal uterus. The possibility of a pseudomyxoma peritonei, a hydatidiform mole, cystic teratoma, or ovarian mucinous cystadenocarcinoma was considered (Figs. 1A and 1B).

An X-ray computed tomography (X-CT) showed

Received February 3, 1988; revision accepted July 6, 1988.

For reprints contact: Hiromi Inoue, Department of Obstetrics and Gynecology, Shohnan Kamakura Medical Center, 1202-1 Yamazaki, Kamakura 247, JAPAN.

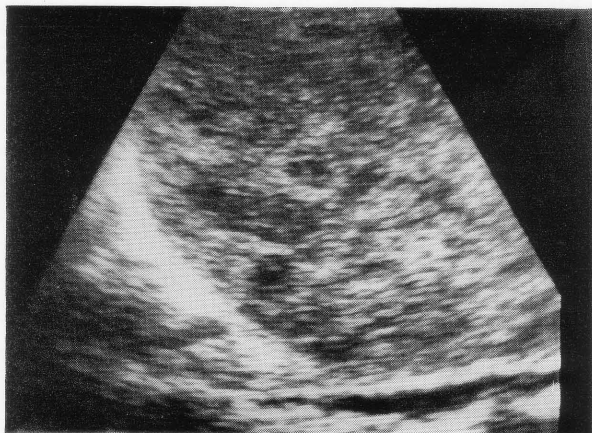


Fig. 1A Longitudinal sonogram of the upper abdomen. Degenerative changes in a part of a large subserous leiomyoma mimicking the sonographic findings of molar gestation.

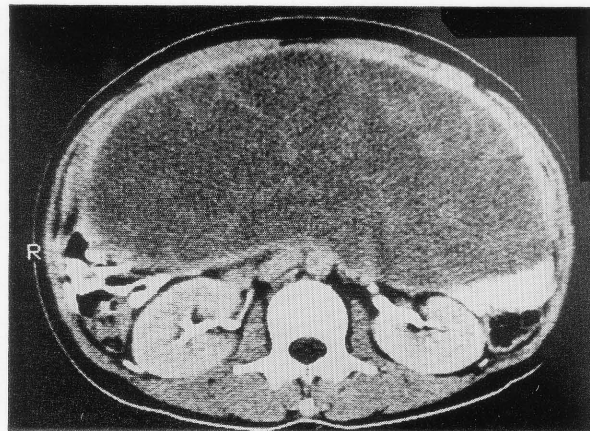


Fig. 2 CT scan. A low density mass with scattered soft tissue densities occupying the abdomen.

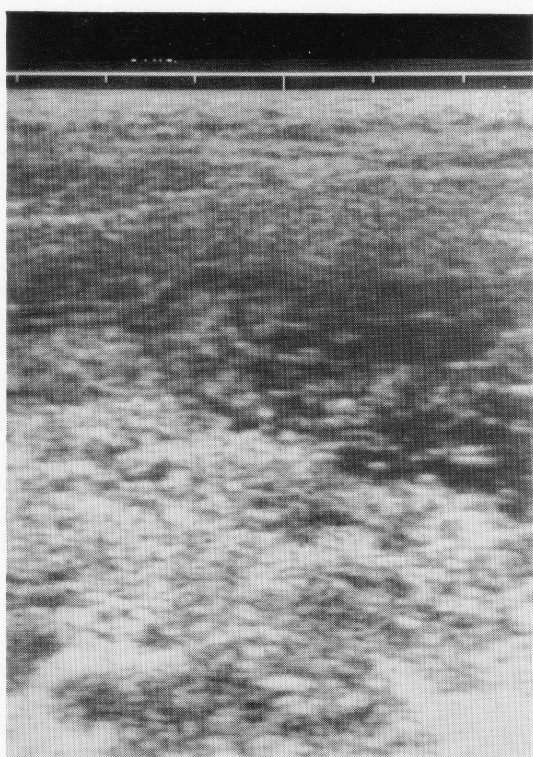


Fig. 1B Transverse sonogram of lower abdomen. Many small anechoic areas in a large echogenic mass.

a large low density mass with intrinsic scattered soft tissue densities in the abdomen (Fig. 2).

Bone imaging was performed with ^{99m}Tc methylene diphosphonate (MDP) to evaluate the large abdominal mass. After the intravenous injection of 20 mCi of ^{99m}Tc MDP, images were obtained with a gamma camera (Toshiba GCA-90A Gamma Camera). The images 3 hours after injection showed homogenous uptake in the mass occupying the entire abdomen (Fig. 3).

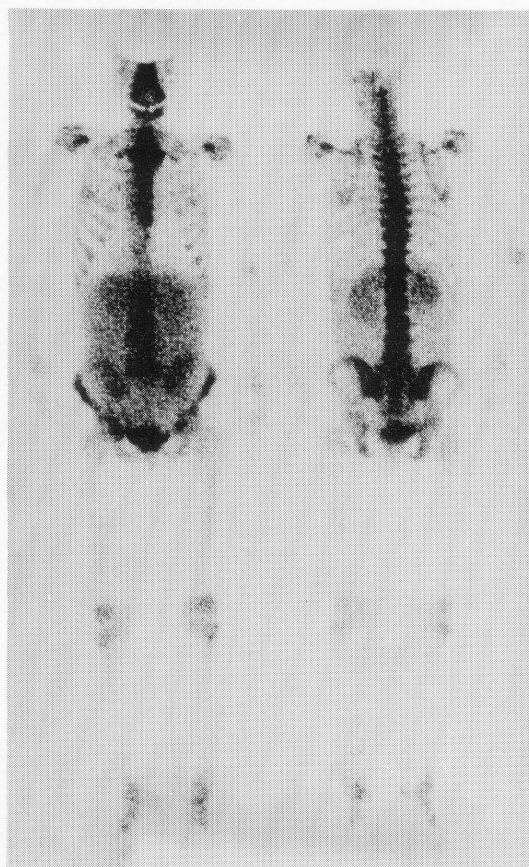

Fig. 3 Whole-body bone scan (20 mCi of ^{99m}Tc -MDP) 3 hours after injection. Abnormal increased uptake corresponding to the large mass in the abdomen.

Laboratory studies were as follows: WBC 5,200/ μl with 16% bands, hematocrit 34.6% and platelet count $26 \times 10^4/\mu\text{l}$. Electrolytes and liver function test were within the normal range. Serum urea nitrogen was 12.9 mg/dl, serum creatinine 0.7 mg/dl and blood glucose 110 mg/dl. Carcinoembryonic antigen (CEA) was 0.6 ng/ml, Alpha fetoprotein (AFP)

1.7 ng/ml and CA-125, 32 U/ml. The urine HCG was negative. Papanicolaous smear of the cervix was normal.

At this stage, it was decided to perform exploratory laparotomy. At surgery, a large subserous leiomyoma was disclosed. A total abdominal hysterectomy and left salpingo-oophorectomy were performed.

The histology of the tumor was hyaline and cystic degeneration of leiomyoma. No calcium was seen by light microscopy using the von Kossa method. Her postoperative course was uneventful.

DISCUSSION

Ultrasonography is remarkably accurate for establishing diagnoses of gynecologic disorders representing cystic lesions. Some diseases are easily diagnosed by ultrasonography on the basis of their typical echographic patterns. For example, the sonographic appearance of a hydatidiform mole is demonstrated as a "snowstorm pattern", and the "tip of the iceberg" sign is one characteristic feature of teratoma. In this case, the sonographic examination revealed a complex internal pattern containing both hypoechoic and echogenic areas. These sonographic features resemble the "snowstorm pattern." However, there are few reports describing the sonographic features of cystic and hyaline degeneration of leiomyoma of the uterus mimicking those of hydatidiform mole,^{1,2} and the biochemistry and history of this case are against a hydatidiform mole. Our differential diagnoses were pseudomyxoma peritonei, ovarian multilocular mucinous cystadenocarcinoma, and cystic teratoma.

Recently, many cases of ^{99m}Tc phosphonate deposition in a variety of nonosseous tissues in various conditions have been reported. A positive concentration of ^{99m}Tc phosphonate was observed in a patient with a calcified myoma of the uterus.³ The mechanisms of leiomyoma calcification are not entirely clear. In most cases, either gross or microscopic calcification can be identified.⁴ However, in our case, no calcium deposit was shown in sections stained by the von Kossa.

The mechanism of the concentration of ^{99m}Tc phosphonate in non-calcified myoma is still unknown.

Two significant features in this case are the "snowstorm pattern" on sonography and the concentration of ^{99m}Tc phosphonate, which has been caused by hyaline and cystic degeneration of the large leiomyoma of the uterus.

REFERENCES

1. Levin S, Feingold M, Brook I, et al: False positive ultrasonography diagnosis of molar pregnancy. *Acta Obstet Gynecol Scand* 60: 435-436, 1981
2. Rinehart JS, Hernandez E, Rosenskein NB, et al: Degenerating leiomyomata uteri: An ultrasonic mimic of hydatidiform mole. *J Reprod Med* 26: 142-144, 1981
3. Ell PJ, Breitfellner G, Meixner M: ^{99m}Tc-HEDP concentration in calcified myoma. *J Nucl Med* 17: 323-324, 1976
4. Buja LM, Parkey RW, Dees JH, et al: Morphologic correlates of technetium-99m stannous pyrophosphate imaging of acute myocardial infarcts in dogs. *Circulation* 52: 596-607, 1975