

Quantification of area and percentage of infarcted myocardium by single photon emission computed tomography with thallium-201: A comparison with serial serum CK-MB measurements

Tomoaki NAKATA, Tetsuya NOTO, Kikuya UNO, Atsushi WADA, Nobuichi HIKITA,
Shigemichi TANAKA, Tetsuro SHOJI,* Masahiro KUBOTA,** Takatoshi TSUDA,**
Kazuo MORITA** and Osamu IIMURA

*The Second Department of Internal Medicine, *Division of Emergency and Critical Care and
**Department of Radiology, Sapporo Medical College*

In order to quantify the size of the infarcted myocardium, two kinds of data processing techniques were applied to single photon emission computed tomography (SPECT) with thallium-201 and its clinical reliability was evaluated by comparing it with the infarct sizing procedure with the serial serum creatine kinase-MB measurements in 14 patients with acute myocardial infarction. After maximum-count circumferential profile analysis, short axis images were reformatted into an unfolded surface map and a bull's eye view map. The SPECT-determined infarct size was defined as the area or the percentage of hypoperfused myocardium of which the profile count was less than the mean minus 2SD derived from 8 normal subjects. The infarct area was calculated from the number of pixels with an abnormal count and expressed in an unfolded surface map. The percentage was calculated from the number of abnormal profile points and displayed in a bull's eye view map. A high linear correlation was observed between the enzymatically determined infarct size and the infarct area or the percentage ($r=.947$, $r=.872$, respectively), despite underestimations in 2 patients with accompanying right ventricular infarction and overestimations in 2 patients with prior anterior infarction. Moreover, a close negative correlation was found between the left ventricular ejection fraction and the infarct area or the percentage ($r=.836$, $r=.821$, respectively).

Thus, the semiautomatic techniques for processing thallium-201 SPECT images might contribute to the quantitative estimation and display of infarcted myocardium and have high clinical reliability.

Key words: Thallium-201, Single photon emission computed tomography, Infarct size, Quantitative analysis, Circumferential profile analysis

INTRODUCTION

THE MEASUREMENT of the extent of myocardial infarction has important clinical significance in prognosis¹⁻³ and in the assessment of therapeutic interventions, such as thrombolytic therapy or angioplasty, to limit the infarct size. A radionuclide imaging technique with Tc-99m pyrophosphate or thallium-

201 is currently used for this purpose. In particular, single photon emission computed tomography (SPECT) has contributed to three-dimensional visualization and detailed analysis of regional abnormalities in coronary heart diseases.³⁻²⁰ However, the data processing procedures have not been necessarily suitable for clinical use because SPECT imaging provided such a large number of slices to be analyzed that they have proven to be complicated.

In this study, two kinds of semiautomatic data processing techniques using maximum-count circumferential analysis, a bull's eye view method¹² and an unfolded surface mapping technique recently

Received December 24, 1987; revision accepted April 18, 1988.

For reprints contact: Tomoaki Nakata, M.D., Second Department of Internal Medicine, Sapporo Medical College, S-1, W-16, Chuo-ku, Sapporo 060, JAPAN.

Table 1 Clinical data

Pt	Age	Sex	Infarct site	LVEF (%)	Complications
1	49	M	I(re)+A	40	LVA
2	44	M	PL	53	(-)
3	55	F	AS	28	LVA
4	48	M	I	60	RVI
5	62	M	AS (non-Q)	61	(-)
6	78	M	I(re)+A	43	(-)
7	77	M	AS	(-)	Af, LVA
8	57	F	AS	48	(-)
9	51	M	I	52	RVI
10	53	M	ext. A	36	LVA
11	64	M	AS	38	LVA
12	59	F	I (non-Q)	69	(-)
13	53	M	PL	37	(-)
14	56	M	ext. A	30	LVA

A=anterior, AS=anteroseptal, I=inferior, PL=posterolateral, ext. A=extensive anterior, re=rear-tack, non-Q=non-Q wave (nontransmural) infarction, LVEF=left ventricular ejection fraction, LVA=left ventricular aneurysm, RVI=right ventricular infarction, Af=atrial fibrillation.

reported by Kubota et al.,²¹ were applied to thallium-201 SPECT images. In addition, it was tested whether the scintigraphic procedures could accurately quantify the size of myocardial necrosis in patients with acute myocardial infarction by a comparison with an enzymatically estimated infarct size.

MATERIALS AND METHODS

Study population

Fourteen patients, 11 males and 3 females, admitted to the Division of Emergency and Critical Care, Sapporo Medical College, between April 1986 and April 1987 with acute myocardial infarction were studied (Table 1). The diagnosis of acute myocardial infarction was established by typical chest pain, electrocardiographic changes and serial increase in creatine kinase (CK). The mean age of the patients was 57.6 ± 2.7 years. There were 5 patients with anteroseptal infarction, 2 patients with extensive anterior infarction, 5 patients with inferior infarction and 2 patients with posterolateral infarction. Non-transmural (non-Q wave) infarction was found in 2 of the 14 patients, one with anterior infarction and the other with inferior infarction. The other 12 patients had transmural (Q wave) infarction. Two of the 5 patients with acute inferior infarction also had right ventricular infarction diagnosed by electrocardiograms, echocardiographic assessment, hemodynamics and Tc-99m pyrophosphate uptake. The other 2 patients with inferior infarction had previous

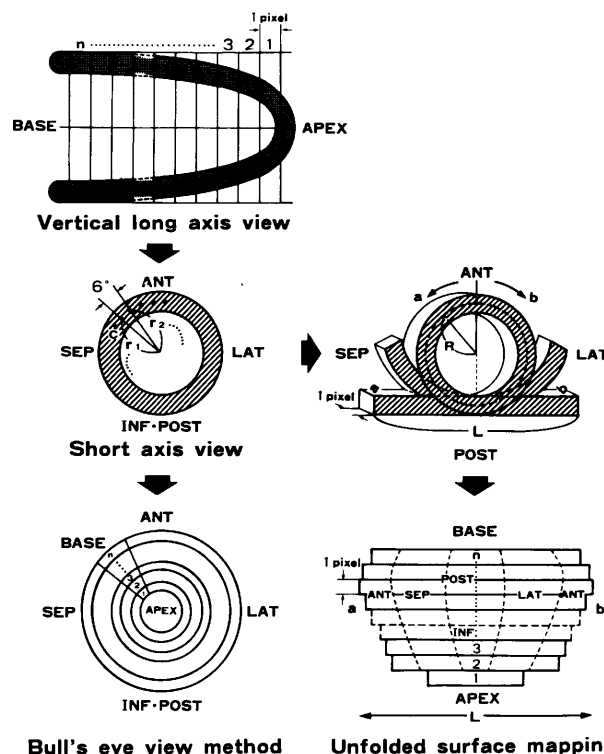


Fig. 1 A schematic representation of the display format and analysis of thallium-201 SPECT image. After reconstruction of the short axis images from the vertical long axis image, maximum-count circumferential profile analysis is performed every 6 degrees in each short axis slice from apex to base. The bull's eye view image is presented as a series of rings by the concentric arrangement of the maximum-count profile data per slice as shown on the bottom left. In the unfolded surface mapping, the length (L) of the circumference is determined in each short axis slice. Then, the unfolded surface map is obtained by arranging the pixel lines with the length (L) and one-pixel thickness from cardiac apex to base shown on the bottom right. ANT=anterior, SEP=septal, LAT=lateral, INF=inferior, POST=posterior. See the text for details.

anterior infarction as revealed by analysis of electrocardiograms and past histories. Six of the 14 patients had left ventricular aneurysm which could be diagnosed by echocardiography and contrast left ventriculography. Eight normal subjects without ventricular hypertrophy or any other recognizable cardiovascular disease were used as the control for this study.

Thallium-201 SPECT imaging

SPECT was performed within 10 days after admission. Myocardial imaging began 10 minutes after the intravenous injection of four millicuries of thallium-201. A large-field-of-view gamma camera (Siemens ZLC 75) equipped with a high resolution parallel hole collimator rotated over 180 degrees from 45-degree left posterior oblique to 45-degree right an-

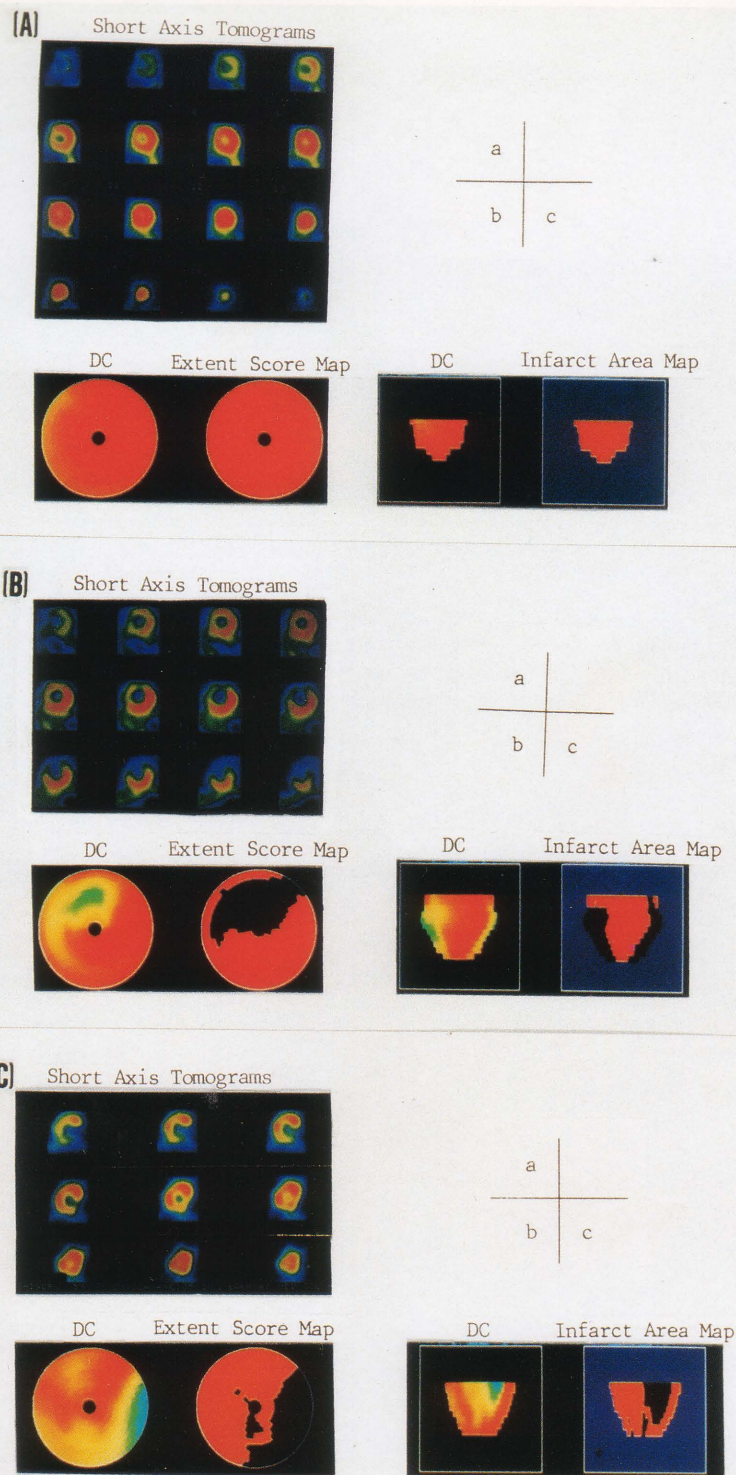


Fig. 2 Demonstration of thallium-201 SPECT imaging, short axis tomograms (a), bull's eye view map (b) and unfolded surface map (c). (A) A typical image in a normal case. The septal segment seems to be a slightly hypoperfused area in the direct count (DC) image because of the existence of the membranous portion of the septum, while the bull's eye view map and unfolded surface map appear uniformly red. (B) SPECT images from a 57-year-old female patient with anteroseptal infarction. The infarct area is 27cm^2 and the extent score is 40%. (C) SPECT images from a 53-year-old male patient with posterolateral infarction. The infarct area is 34cm^2 and the extent score is 31%.

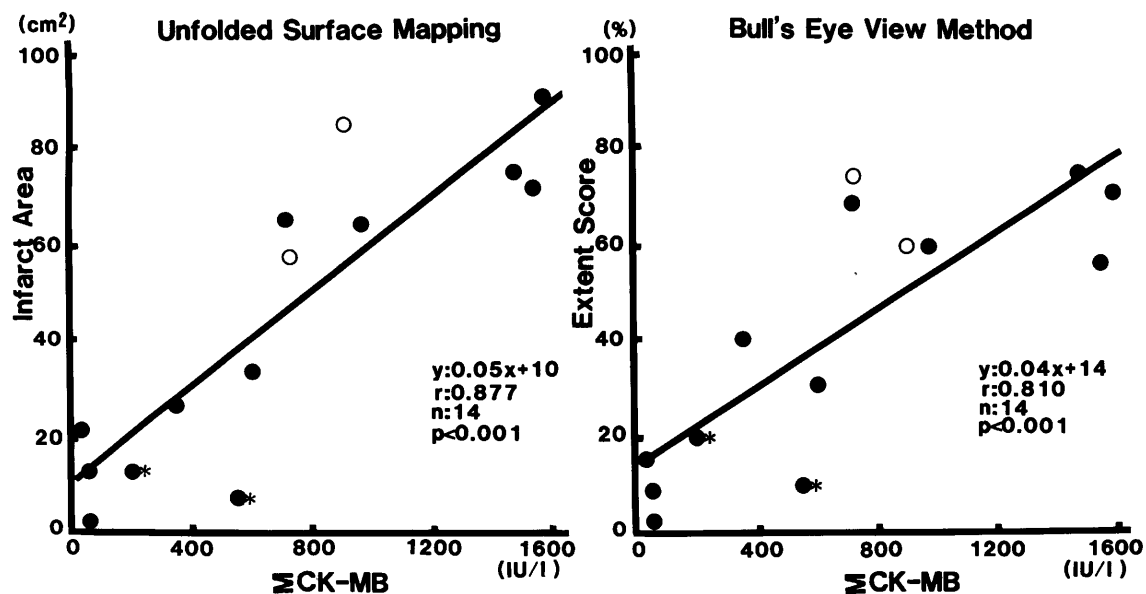


Fig. 3 Relationship between the total CK-MB release (Σ CK-MB) and infarct area or extent score. The infarct area was calculated by unfolded surface mapping, and the extent score by the bull's eye view method. *=the case accompanying right ventricular infarction, solid circles=the first attack cases, open circles=the reattack cases with previous anterior infarction.

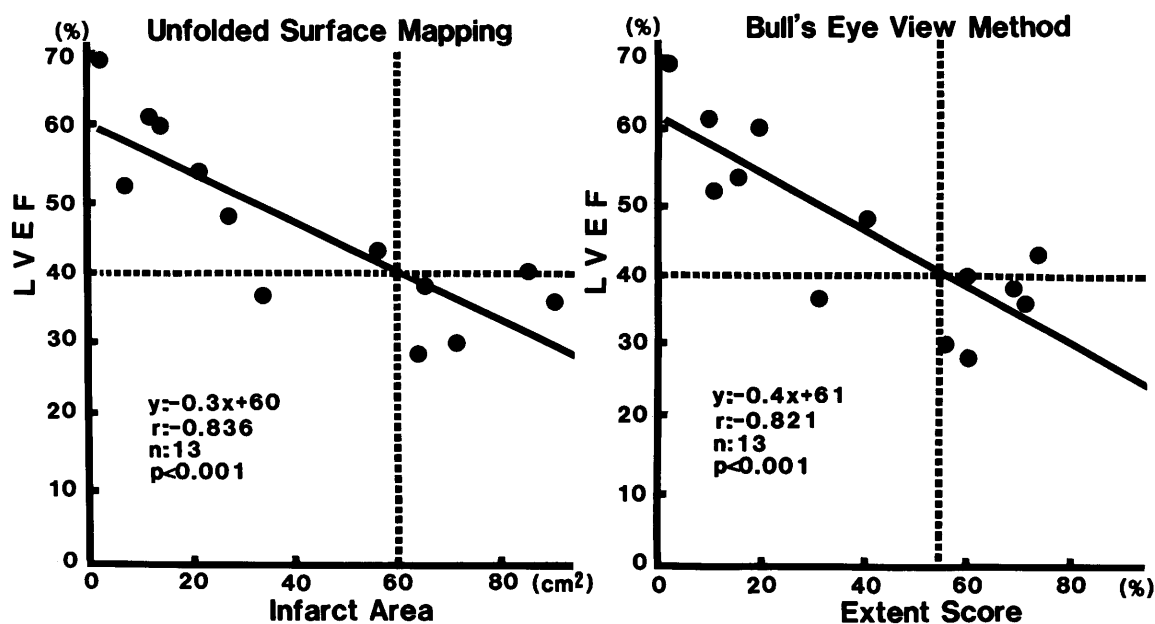


Fig. 4 Relationship between left ventricular ejection fraction (LVEF) and infarct area or extent score. In 6 cases with left ventricular aneurysm and/or whose LVEF is 40% or less, the infarct area is more than 60 cm² and the extent score is 55% or greater.

terior oblique. The data were acquired from 36 projections every 5 degrees for 30 seconds each and stored as 64×64 matrices in the memory of a dedicated nuclear medicine computer system (Shimadzu Scintipac 2400). The total imaging time for thallium-201 SPECT was about 18 minutes. No attenuation correction was attempted. Transverse tomograms were first reconstructed by filtered backprojection with a Shepp and Rogan's filter. Subsequently, the vertical long axis and short axis sections were obtained.

Display and assessment of infarct size by thallium-201 SPECT

Myocardial activity was analyzed from the short axis profiles over 60 points spaced at 6 degrees for the determination of maximum-counts per point for each slice from apex to base.

The bull's eye view method was performed as follows. The distribution of maximum-count profile data per slice was reformatted into a series of concentric circles as shown at the bottom left in Fig. 1 (bull's eye view map). The apical slice is in the center of the image, the subsequent slices are arranged peripherally and the basal slice is located at the edge. All maximum-count data were first presented in the direct count (DC) image with a color scale in which, for example 0% is black and 100% is red (Fig. 2). Then, the infarct size was measured as an extent score which was defined by the percentage of circumferential profile points which fell below the lower limit (mean minus 2SD) of the normal range derived from 8 normal subjects. The perfusion defects were displayed as a black region while the normal region appeared uniformly red (Fig. 2). Therefore, in order to assess the left ventricular infarct size, the number of abnormal profile points on each short axis slice was found and divided by the total number of left ventricular profile points from apex to cardiac base as shown by the following formula:

$$\text{Extent Score (\%)} = \frac{\text{Number of profile points with abnormal count}}{60 \times (\text{Number of short axis slices})}$$

where 60=number of points per short axis slice.

Like this, the bull's eye view method in this study was based on the technique developed by Caldwell.¹² However, edge detection by the threshold technique was not attempted.

The unfolded surface mapping technique was performed using the method previously described by Kubota et al.²¹ Following the maximum-count circumferential profile analysis, the distance (r) from the center of a short axis tomogram to each profile point (c) was measured and its circumference (L) was calculated. The profile data were plotted on the

pixel line with the length (L) and one-pixel thickness. The lines were arranged in turn from apex to base as shown on the bottom right in Fig. 1 (unfolded surface map). The area of myocardial infarction was calculated by the number of pixels for which the profile count was less than the lower normal limit. The infarct area was displayed as a black region (Fig. 2):

$$\text{Infarct Area (cm}^2\text{)} = 0.03 \times (\text{Number of pixel with abnormal count})$$

where 0.03=area of one pixel (0.1 cm \times 0.03 cm) in this study.

The infarct size was estimated with two indexes, the extent score in the bull's eye view method and the area in the unfolded surface mapping technique. All three-dimensional data obtained from SPECT imaging were visually presented as a single two-dimensional image. Figure 2 demonstrates these display formats in a normal subject and patients with acute myocardial infarction.

Infarct sizing procedure by CK-MB measurement

Serial venous blood specimens were taken at the time of admission, every four hours for 48 hours, and then every twelve hours until normalization of the activity for measurement of creatine kinase (CK) by UV rate assay using NADP. MB isoenzyme was measured by electrophoresis. Infarct size was calculated with the following formula based on the method established by Roberts (1) and presented as the total amount of CK-MB activity released by the heart up to time T in association with irreversible injury.

$$\begin{aligned} \text{Total CK-MB release (IU/l)} &= \int_0^T f(t) dt \\ &= E(T) + Kd \int_0^T E(t) dt \end{aligned}$$

where $E(t)$ =CK-MB activity in blood (IU/l), $f(t)$ =rate of change of CK-MB activity due to the enzyme being released by the heart (IU/(ml min)), Kd =fractional rate of disappearance of CK-MB activity from blood (/min).

Radionuclide ventriculography

To evaluate cardiac function, radionuclide ventriculography with ^{99m}Tc -pertechnetate (20 mCi) was performed for all patients except one with atrial fibrillation. After the patient's red cells were labeled *in vivo* and the radioactivity had been equilibrated, the data were collected in a multiple gated mode of 500 cardiac cycles. The scintillation camera (Searle LFOV, large-field-of-view) was equipped with a low-energy, all-purpose, parallel-hole collimator and positioned at about a 45-degree left anterior oblique projection with a 5 to 10 caudal tilt. The gated blood-pool data were processed with the computer system

Table 2 Enzymatic and scintigraphic data

Pt	Peak CK (IU/l)	Enzymatic IS		Scintigraphic IS	
		Peak CK-MB (IU/l)	Total CK- MB release (IU/l)	Infarct area (cm ²)	Extent score (%)
1	5,320	575	911	85	60
2	528	24	12	21	15
3	3,088	593	956	64	60
4	1,160	122	197	13	19
5	372	32	48	12	9
6	2,381	531	726	57	73
7	3,669	1,104	1,465	75	75
8	1,430	173	350	27	40
9	3,050	291	545	9	10
10	4,174	512	1,568	90	71
11	1,717	406	713	65	68
12	269	22	50	2	1
13	5,510	429	596	34	31
14	6,910	885	1,536	72	55

IS=infarct size.

and the left ventricular ejection fraction was calculated.

Statistical analysis

All values are presented as the mean \pm SE. Infarct size determined by thallium-201 SPECT imaging was compared to that estimated enzymatically by linear regression analysis. For the statistical comparison of correlation coefficients, the paired t-test was used.

RESULTS

Thallium-201 SPECT images of 3 typical cases are presented in Fig. 2. The top panels are from a normal subject. No perfusion defect is found in the short axis images (a), the bull's eye view map (b) or the unfolded surface map (c). The middle panels are from a 57-year-old patient. Perfusion defects are found in the anteroseptal region of all three images. The scintigraphically calculated infarct area and extent score are 27 cm² and 40%, respectively. The bottom panels from a 53-year-old patient show perfusion defects in the posterolateral region. The infarct area is 34 cm² and the extent score is 31%.

The left ventricular ejection fraction ranged from 28 to 69% with a mean of 46 \pm 3% (Table 1). The enzymatic and scintigraphic data for all patients are shown in Table 2.

There was a significant linear correlation between the total CK-MB release (Σ CK-MB) and the infarct area calculated by unfolded surface mapping technique or the extent score by bull's eye view method, with a correlation coefficient of .877 ($p<0.001$) and

.810 ($p<0.001$), respectively (Fig. 3). Of the 5 patients with acute inferior infarction, 2 patients had prior anterior infarction and the other 2 patients suffered from accompanying right ventricular infarction (Table 1). Therefore, compared to the enzymatic determination, both the scintigraphic techniques underestimated the infarct size in the patients with accompanying right ventricular infarction and overestimated that in the reattack cases. When 10 patients other than these 4 cases were analysed, a better correlation was found, i.e., $r=.947$ ($p<0.001$) with a regression line of $y=0.046x+12.5$ in the unfolded surface mapping and $r=.872$ ($p<0.001$) with a regression line of $y=0.038x+14.8$ in the bull's eye view method. There was no significant difference between the two scintigraphic techniques in the ability to size infarction, but the infarct area calculated by unfolded surface mapping technique was more closely related to the enzymatically estimated infarct size than the extent score by the bull's eye view method ($r=.947$ vs $r=.872$, $p<0.1$).

Figure 4 illustrates the relationship between the left ventricular ejection fraction and the scintigraphically determined infarct size. For the two methods, a significant negative correlation was found between the variables, $r=.836$ ($p<0.001$) in the unfolded surface mapping and $r=.821$ ($p<0.001$) in the bull's eye view method. In the 6 cases who had left ventricular aneurysm and/or a left ventricular ejection fraction of 40% or less, the infarct area was more than 60 cm² and the extent score was 55% or greater.

DISCUSSION

In this study, two kinds of data processing methods, the unfolded surface mapping technique recently developed by one of us, Kubota,²¹ and the bull's eye view method,¹² were attempted for quantification of myocardial perfusion abnormalities. The results demonstrate that these two techniques are clinically useful for estimating infarct size as an area or a percentage of the left ventricle. In particular, the infarct area calculated by unfolded surface mapping seems more accurate than the extent score from the bull's eye view method.

Although the enzymatic method established by Roberts¹ is not the gold standard for the measurement of infarct size, it has often been used in clinical studies because there are no other clinically acceptable methods for making comparisons. However, this method is not available unless a proper serial blood sampling or an accurate measurement of CK-MB is performed. Several clinical studies reported that infarct size by pyrophosphate SPECT correlated well with CK-MB estimates of the infarct size.^{3,4,7,8} There is, however, the possibility that the pyro-

phosphate scanning technique labels noninfarcted tissue and overestimates the extent of infarction because of its pharmaceutical characteristics.^{16,24} Furthermore, the pyrophosphate scan has to be done within the first 2 to 4 days after the onset of chest pain to obtain high-quality images. Therefore, the estimation of infarct size by SPECT with Tc-99m pyrophosphate or by CK-MB analysis is possible only during the acute phase of myocardial infarction but not in the recovery or remote stage. If rapid reperfusion with thrombolytic therapy or angioplasty is performed, the accurate estimation of infarct size may be more difficult to ascertain because these procedures affect CK-MB release from the myocardium and the ideal timing of SPECT imaging with pyrophosphate.^{8,22,23}

In this regard, myocardial perfusion scintigraphy with thallium-201 is suitable not only at an early stage of myocardial infarction but also at a later stage. Although previous studies reported that SPECT with thallium-201 was feasible for quantifying infarct size,⁸⁻¹⁷ their techniques were so complicated because many slices had to be analyzed that widespread clinical use has been precluded. Caldwell et al.¹² measured a relative myocardial perfusion defect in dogs using 180 degrees acquisition which showed a good correlation ($r=.88$) between the SPECT and anatomic estimates of relative reduced perfusion volume. Although the index they used is slightly different from that in this study, it has the same implication as the extent score in this study, which is significantly ($r=.87$, $p<0.001$) related to the enzymatically determined infarct size. Thus, this investigation showed that quantitating the size of relative myocardial perfusion defects by maximum-count circumferential profile analysis was very reliable in a clinical study.

However, there are some limitations to infarct sizing by thallium-201 images. First, no attenuation correction was attempted in this study since no adequate technique is presently available for SPECT imaging with thallium-201. Attenuation correction did not necessarily seem useful when the projections were over 180 degrees as Jansen had pointed out.⁸ In addition, attenuation losses were corrected in the comparative study with the normal range determined by the same technique as attempted in the present study since the losses in normal subjects should be similar to those in patients.¹² Second, it is impossible to estimate the size of small perfusion defects,⁵ non-transmural infarction or right ventricular infarction because SPECT imaging per se has a limitation in spatial resolution. Third, it is difficult to distinguish newly established myocardial necrosis from the previously infarcted area in a reattack case because thallium-201 imaging is not for infarct-avid scin-

tigraphy but for myocardial perfusion scintigraphy. Fourth, the bull's eye view method is useful in expressing infarct size as a percentage of the total left ventricular mass for interpatient comparisons because of variations in left ventricular size among patients.^{12,17} However, it is necessary to accurately measure the total amount of the left ventricle and to develop algorithms accounting for the difference in the myocardial slice mass from apex to base as pointed by Prigent.¹⁵ In other words, the relative assessment by the bull's eye view method has a tendency to overestimate the relative contribution of the apical part of the left ventricle and, conversely, to underestimate that of the mid and basal portions. This is particularly important because apical involvement is often found in a case with anterior infarction. Therefore, it seems that quantification by unfolded surface mapping as attempted in the present study was more reasonable and more accurate because the size of each short axis image was calculated. As a matter of fact, the geometric surface area of myocardial infarction measured by this method was well correlated with the enzymatically estimated infarct size. Fifth, if a large perfusion defect is located in the apex, no slices are obtained and, therefore, the infarcted myocardium cannot be recognized in the thallium-201 SPECT images. This means that thallium-201 imaging may underestimate the infarct size in such a case. In order to solve this problem, an alternative approach, such as analysis of the horizontal or vertical long axis image or the use of tomographic gated blood pool imaging, might be necessary to find the defect area.

The display formats obtained by the unfolded surface mapping technique and bull's eye view method can present all the three-dimensional scintigraphic data in a single two-dimensional image. The bull's eye view map may make it easier to anatomically recognize the ventricular segments. However, the unfolded surface mapping may be able to more accurately display the extent and distribution of perfusion abnormalities because it takes into consideration the differences in myocardial slices, while in the bull's eye view method the perfusion defect in the basal portion is more emphatically expressed than that in the apical segment.

In conclusion, the unfolded surface mapping technique and the bull's eye view method can contribute to accurate quantification and visualization of myocardial perfusion abnormalities. In particular, the unfolded surface mapping technique appears to make up for the limitations of the bull's eye view method and other conventional procedures and, moreover, may be used in the noninvasive assessment of early reperfusion therapy.

REFERENCES

1. Roberts R, Henry PD, Sobel BE: An improved basis for enzymatic estimation of infarct size. *Circulation* 52: 743-754, 1975
2. Sobel BE, Bresnahan GF, Shell WE, et al: Estimation of infarct size in man and its relationship to prognosis. *Circulation* 46: 640-648, 1972
3. Holman BL, Goldhaber SZ, Kirsch CM, et al: Measurement of infarct size using single photon emission computed tomography and technetium-99m pyrophosphate: a description of the method and comparison with patient prognosis. *Am J Cardiol* 50: 503-511, 1982
4. Corbett JR, Lewis SE, Wolfe CL, et al: Measurement of myocardial infarct size by technetium pyrophosphate single photon tomography. *Am J Cardiol* 54: 1231-1236, 1984
5. Keyes JW Jr, Leonard PF, Brody SL, et al: Myocardial infarct quantification in the dog by single photon emission computed tomography. *Circulation* 58: 227-232, 1978
6. Lewis SE, Devous MD, Corbett JR, et al: Measurement of infarct size in acute canine myocardial infarction by single photon emission tomography with technetium-99m pyrophosphate. *Am J Cardiol* 54: 193-199, 1984
7. Tamaki S, Kadota K, Kambara H, et al: Emission computed tomography with technetium-99m pyrophosphate for delineating location and size of acute myocardial infarction in man. *Br Heart J* 52: 30-37, 1984
8. Jansen DE, Corbett JR, Wolfe CL, et al: Quantification of myocardial infarction: a comparison of single photon-emission computed tomography with pyrophosphate to serial plasma MB-creatine kinase measurements. *Circulation* 72: 327-333, 1985
9. Wolfe CL, Lewis SE, Corbett JR, et al: Measurement of myocardial infarction fraction using single photon emission computed tomography. *J Am Coll Cardiol* 6: 145-151, 1985
10. Keyes JW Jr, Brody TJ, Leonard PF, et al: Calculation of viable and infarcted myocardial mass from thallium-201 tomograms. *J Nucl Med* 22: 339-343, 1981
11. Tamaki S, Nakajima H, Murakami T, et al: Estimation of infarct size by myocardial emission computed tomography with thallium-201 and its relation to creatine kinase-MB release after myocardial infarction in man. *Circulation* 66: 994-1001, 1982
12. Caldwell JH, Williams DL, Harp GD, et al: Quantitation of size of relative myocardial perfusion defect by single-photon emission computed tomography. *Circulation* 70: 1048-1056, 1984
13. Thompson CJ, Mena I, Maublant JC: Thallium-201 tomographic estimation of left ventricular mass in normal and infarcted canine hearts using a new automated edge-detection program (abstract). *J Am Coll Cardiol* 4: 533, 1985
14. Prigent F, Maddahi J, Sato Y, et al: Quantification of myocardial infarct size in the dog using single-photon emission computerized tomography: slice-by slice comparison of Tl-201 tomograms and pathology (abstract). *Circulation* 70: II-450, 1984
15. Prigent F, Maddahi J, Garcia EV, et al: Comparative methods for quantifying myocardial infarct size by thallium-201. *J Nucl Med* 28: 325-333, 1987
16. Khaw BA, Gold HK, Yasuda T, et al: Scintigraphic quantification of myocardial necrosis in patients after intravenous injection of myosin-specific antibody. *Circulation* 74: 501-508, 1986
17. Johnson LL, Lerrick KS, Coromilas J, et al: Measurement of infarct size and percentage myocardium infarcted in a dog preparation with single photon-emission computed tomography, thallium-201, and indium 111-monoclonal antimyocin Fab. *Circulation* 76: 181-190, 1987
18. Maublant J, Bailly P, Mestas D, et al: Feasibility of gated single photon emission transaxial tomography of the cardiac blood pool. *Radiology* 146: 837-839, 1983
19. Barat JL, Brendel AJ, Colle JP, et al: Quantitative analysis of left ventricular function using gated single photon emission tomography. *J Nucl Med* 25: 1167-1174, 1984
20. Nakata T, Murakami H, Inoue M, et al: Qualitative determination of infarct segment by Fourier analysis using gated cardiac pool emission computed tomography. *J Cardiogr* 16: 331-342, 1986 (in Japanese)
21. Kubota M, Tsuda T, Akiba H, et al: Estimation of infarct size by three-dimensional surface display method of myocardial single photon emission CT with 201Tl. *Jpn J Nucl Med* 24: 1677-1682, 1987 (in Japanese)
22. Parkey RW, Kulkarni P, Lewis S, et al: Effect of coronary blood flow and site of injection on Tc-99m-PPI detection of early canine myocardial infarcts. *J Nucl Med* 22: 133-137, 1981
23. Wheelan K, Wolfe C, Corbett J, et al: Early positive technetium-99m stannous pyrophosphate images as a marker of reperfusion after thrombolytic therapy for acute myocardial infarction. *Am J Cardiol* 56: 252-256, 1985
24. Holman BL: Infarct-avid scintigraphy. In Freeman and Johnson's clinical radionuclide imaging, Volume I, Freeman LM (ed), New York, Grune & Stratton, 1984, pp. 540-543