

Contribution of ^{99m}Tc -sestamibi infusion SPECT to the characterization of fixed perfusion defects

Ali T. AKPINAR, Ibrahim BARAN, Sumeyye GULLULU, Nese GUNES,
Yelda SALTAN, Eray ALPER and Bulent OZDEMIR

Departments of Nuclear Medicine and Cardiology, Uludag University Medical Faculty, Bursa, Turkey

In patients with coronary artery disease, the distinction between scar and viable myocardium by means of myocardial perfusion imaging (MPI) sometimes can be difficult because of the equivocal meaning of fixed perfusion defects. In this study we examined whether addition of a ^{99m}Tc -sestamibi infusion study to the standard MPI could provide extra information regarding the fixed defects. Thirty-seven patients underwent standard MPI and an extra SPECT study in which ^{99m}Tc -sestamibi was given as a prolonged constant infusion. Of 324 myocardial segments available for analysis, 134 had fixed or resting perfusion abnormalities on standard MPI studies, of which 25% (33/134) in 12 patients showed partial improvement in the perfusion pattern whereas in 6% (8/134) the improvement was very significant in infusion studies. In 19 patients who were also examined with dobutamine echocardiography, 13 showed concordance between echocardiography and infusion MPI. This study suggests that infusion MPI may provide complementary information to the conventional scintigraphy with regard to interpretation of standard myocardial perfusion scans with fixed defects.

Key words: myocardial perfusion imaging, fixed defects, myocardial viability

INTRODUCTION

IN PATIENTS with chronic coronary artery disease (CAD) and impaired left ventricular (LV) function, the distinction between ventricular dysfunction arising from myocardial fibrosis and ischemic, but viable, myocardium has important clinical implications because viable myocardium may show functional recovery after revascularization, with improvement in ejection fraction and, as reported, in survival.¹⁻⁴ Improvement of function after revascularization is still considered the gold standard for viability assessment. Dysfunctional but viable myocardium has different characteristics including intact perfusion, cell membrane integrity, intact mitochondria, preserved glucose and (possibly) fatty acid metabolism, and contractile

reserve.⁵ Among the noninvasive techniques for differentiating viable from nonviable myocardium and for identifying zones with reversible dysfunction using these characteristics, echocardiography with low dose dobutamine infusion (LDDE) and radionuclide methods using single photon emitters have gained widespread acceptance.

Myocardial perfusion imaging (MPI) with single photon emission computed tomography (SPECT) using either ^{201}Tl or ^{99m}Tc -sestamibi is an excellent technique for viability assessment. Quantitative demonstration of >50% (or >60%) uptake of these tracers in an area of severe myocardial asynergy is reflective of viability.⁶ Thallium-201 is the imaging agent most often used with SPECT imaging for determination of myocardial viability. Compared with ^{201}Tl , ^{99m}Tc -sestamibi emits higher energy photons (140 keV), and the shorter half life of ^{99m}Tc allows the administration of a higher dosage. A higher dose and energy result in better count statistics in the images and better image quality. Although earlier studies indicate that ^{201}Tl cardiac imaging with rest reinjection is superior to ^{99m}Tc -sestamibi myocardial scintigraphy in identifying viable myocardium,^{7,8} a substantial body of

Received January 10, 2006, revision accepted May 9, 2006.

For reprint contact: A. Tayyar Akpınar, M.D., Uludag Universitesi Tıp Fakültesi, Nükleer Tıp Anabilim Dalı, 16059 Gorukle, Bursa, TURKEY.

E-mail: atakp@uludag.edu.tr

This study was supported by the Research Fund of The University of Uludag.

Table 1 Baseline characteristics of the patient group

Age (years)	56 ± 9
Male/Female	35/1
Diabetes mellitus	7 (19%)
Previous MI	27 (75%)
Angina pectoris	8 (22%)
Previous CABG*	3 (8%)
Two-vessel disease	12 (33%)
Three-vessel disease	7 (19%)
Resting LVEF**	34 ± 8%

*CABG: Coronary Artery Bypass Grafting; **LVEF: Left Ventricular Ejection Fraction

Table 2 Relationship between perfusion improvement on infusion study and perfusion defect severity

Uptake score	Uptake improvement on infusion study		
	No improvement*	Partial*	Remarkable*
2	31	28	3
3	48	5	5
4	14	0	0

*Number of segments.

evidence now indicates that ^{99m}Tc -sestamibi may also be a good viability marker.^{9,10} Fixed defects with severely decreased tracer activity on a standard stress/rest ^{99m}Tc -sestamibi scintigraphy may indicate either scar or viable tissue in which blood flow is severely impaired and tracer delivery is reduced. In this situation, interpretation of scans may sometimes be difficult, even for experienced physicians. In this study, we examined whether addition of an extra ^{99m}Tc -sestamibi infusion study to the standard myocardial perfusion study could provide extra information regarding the fixed defects. The hypothesis was, instead of standard bolus injection, prolonged infusion of ^{99m}Tc -sestamibi, hence extending the presence of the radiopharmaceutical in the blood, might enhance its uptake by severely ischemic but viable myocardial tissue, and this may contribute to the interpretation of standard myocardial perfusion scans with fixed defects.

MATERIALS AND METHODS

Thirty-six patients (one female, 35 males, mean [± SD] age 56 ± 9 years, age range 37–74 years) with CAD and left ventricular dysfunction (ejection fraction ≤45%) referred to us for viability and/or ischemia assessment were studied. Table 1 shows the baseline characteristics of the patient group. CAD was documented by coronary angiography, previous myocardial infarction, or both. Left ventricular dysfunction was detected by either contrast ventriculography or by echocardiography. In 18 patients standard two-day stress-rest followed by infusion and in the remaining 19 patients only rest and infusion imaging

Table 3 Relationship between uptake improvement on infusion study and response to low dose dobutamine on a per patient basis

Uptake improvement in infusion study	Response to low dose dobutamine	
	Viable	Nonviable
Positive	5	1
Negative	5	8

Table 4 Relationship between regional uptake on conventional MIBI rest study and response to low dose dobutamine on a per patient basis

Uptake score	Response to low dose dobutamine	
	Viable	Nonviable
2	1	3
3	7	5
4	1	2

protocols were performed. In one patient who was referred for myocardial viability and additional ischemia assessment because of the known presence of critical coronary artery stenosis and LV dysfunction, MPI was found to be completely normal, and then excluded from the study. In 22 patients, MPI studies were performed using the gated SPECT technique. Within the same week of the MPI study, either LDDE (19 patients, dobutamine was infused at doses of 5 and 10 micrograms/kg/min) or resting echocardiography (5 patients) was performed. In LDDE, viable myocardium was considered as abnormal wall motion at rest with progressive increase in wall thickening and contractility during dobutamine infusion. Patients with unstable angina pectoris, recent myocardial infarction, important valvular disease, serious arrhythmia, end-stage extra-cardiac disease, and congestive heart failure were excluded. Standard two-day stress-rest MPI and rest MPI studies were performed using 750–950 MBq ^{99m}Tc -sestamibi. SPECT or, if possible, gated-SPECT images were acquired with a dual-head gamma camera (Millennium VG, GE Medical Systems) equipped with low energy-high resolution collimators. On the following day, the same dose of ^{99m}Tc -sestamibi in 100 ml was infused over 45 minutes using a constant infusion pump under resting conditions, and imaging was performed 45 minutes after completion of the infusion. Reconstruction, processing and interpretations were performed by two experienced independent Nuclear Medicine physicians. Oblique slices, bull's-eye plots, gated slices and quantitative gated processed data were analyzed. Special attention was paid to possible artifacts and attenuations. Data analysis was performed using a 9-segment model, and segmental perfusion was graded using a semi-quantitative five-point system (0 = normal uptake, 1 = mildly reduced tracer uptake, 2 = moderately reduced uptake, 3

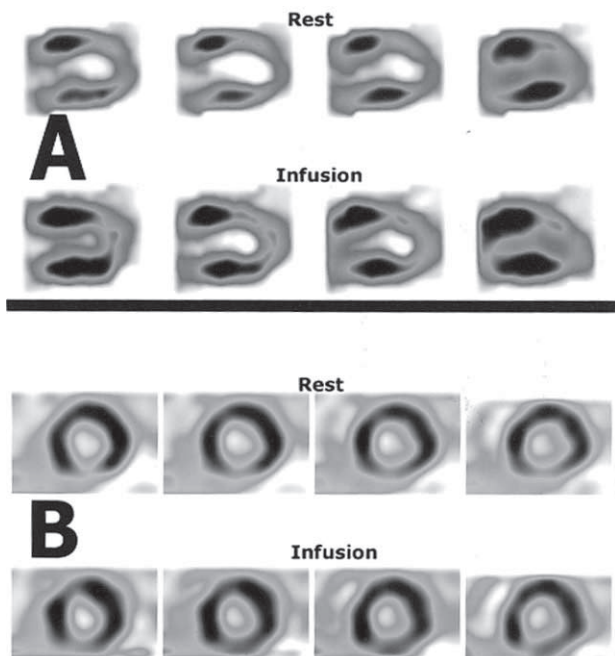


Fig. 1 Examples of radiopharmaceutical uptake enhancement after prolonged infusion of ^{99m}Tc -sestamibi.

= severely reduced uptake, and 4 = absent uptake). In gated SPECT evaluation, presence of systolic wall thickening and/or inward wall motion were accepted as indicative of the presence of myocardial viability.

All patients gave written informed consent before the study protocol, which had been approved by the Institutional Ethical Committee.

RESULTS

There were both reversible and fixed perfusion defects on two-day studies in some patients. In this case, completely reversible perfusion abnormalities were not taken into account for this study. Of 324 segments analyzed, the ^{99m}Tc -sestamibi perfusion pattern at rest was normal in 190 segments (59%) and showed moderate (grade 2) perfusion defects in 62 segments (19%), severe (grade 3) defects in 58 segments (18%), and absent uptake (grade 4) in 14 segments (4%).

Ninety-three segments (69% of 134 total resting perfusion defects) in 19 patients (53% of 36 patients) showed no improvement in infusion MPI. However, 33 segments (25%) in 12 patients (33%) showed partial (Fig. 1-A), and 8 segments (6%) in 5 patients (14%) showed remarkable (Fig. 1-B) radiopharmaceutical uptake improvement. Table 2 shows a detailed representation of the relationship between segmental perfusion score and improvement on infusion study. Briefly, 31 (50%) of the segments that had moderately reduced uptake, and 10 (17%) of the segments that had severely diminished uptake demonstrated either partial or marked radiopharmaceutical uptake improve-

ment. None of the 14 segments that had shown absent uptake improved with infusion imaging.

Among the 19 patients who had undergone LDDE, in 13 patients (68%) there was agreement between regional uptake improvement on infusion study and response to low dose dobutamine (Table 3). However, there was lower agreement (10 of 19 patients [53%]) between the LDDE and conventional rest MIBI results, even when severely diminished MIBI uptake areas were regarded as viable (Table 4). There was also concordance in 5 patients between resting echocardiography and regional perfusion on infusion study.

DISCUSSION

Interpretation of myocardial perfusion scans with moderate or severe fixed, or resting, perfusion defects sometimes can be difficult because not all fixed perfusion defects indicate scar tissue. Perfusion-scan fixed defects may result from soft tissue attenuation. Because most (91%) fixed defects with normal systolic function occurred in women with anterior fixed defects (48%) or men with inferior fixed defects (43%), these were most likely attenuation artifacts.¹¹ Therefore, we carefully examined both raw and processed data, and used, when needed, techniques such as prone acquisition, gating, and breast elevation to eliminate such technical artifacts. Because an artifactual defect would show normal contraction (wall motion or thickening) on a gated image, artifacts can be differentiated from a true infarct.¹² In addition to differentiation of fixed defects, ECG gating of images provides additional information on function and may potentially enhance accuracy to detect viable myocardium.¹³ Whereas preservation of function is clearly proof of viability, absence of function does not necessarily indicate absence of viability. This is because chronically ischemic myocardium may have greatly reduced or absent systolic function.¹² On the other hand, interpretation of systolic wall motion or thickening in segments with severely reduced perfusion can sometimes be impossible because it is difficult to differentiate passive movement from active contraction. In this situation, demonstration of augmentation of resting radiopharmaceutical uptake with time, like in the case of the present study or ^{201}Tl redistribution, may be more valuable.

In a total of 17 patients (47%), we were able to demonstrate either partial or prominent radiopharmaceutical uptake improvement in infusion MPI studies. This finding supports our hypothesis that under low flow condition, ischemic but viable myocardial tissue may demonstrate higher uptake in the extended presence of radiopharmaceutical in the blood than in single bolus injection. The likely explanation for various different degrees of radiopharmaceutical uptake improvement could probably be the various amounts of viable myocytes in different segments. A couple of reports have appeared in the medical

literature with regard to the use of infusion MPI in patients with CAD.^{14–17} In a study comparing the results of ²⁰¹Tl reinjection and ^{99m}Tc-sestamibi infusion, concordant results were observed in 22 of 25 patients, and the authors concluded that ^{99m}Tc-sestamibi infusion might provide information about the presence of viable myocardium.¹⁵ Similar to our findings, they observed enhanced radiopharmaceutical uptake on infusion studies in 13 cases (52%).

Of the 19 patients who underwent LDDE, 13 (68%) studies showed concordance between the presence or absence of regional uptake augmentation on infusion studies and the presence or absence of contractile reserve on LDDE studies. Some discrepancies can be observed between MPI and LDDE because nuclear techniques (²⁰¹Tl or ¹⁸F-fluorodeoxyglucose positron emission tomography) have higher sensitivity and negative predictive value, and dobutamine echocardiography has higher specificity and positive predictive value, with post-revascularization improvement in ventricular function used as the judging standard.¹⁸ This may be due to both methodological differences and the amount of viable myocytes in that region because more viable cells were found to be required for a segment to exhibit viability by stress echocardiography than by radionuclide imaging techniques.^{19,20}

It is generally accepted that dysfunctional segments with tracer uptake higher than 50–60% of maximal ^{99m}Tc-sestamibi uptake are considered viable.²¹ These values correspond to grades 1 and 2 of our five-point semi-quantitative evaluation scale. However, we preferred to include patients with grade 3 (severe) perfusion defects on standard resting MIBI for this comparison because using lower (35%) threshold values in the attenuation regions ^{99m}Tc-sestamibi has been reported to show higher positive and negative predictive value for improvement of left ventricular function.²² Comparison of LDDE and conventional rest MIBI studies including the patients with grade 2 and 3 perfusion abnormalities showed lower agreement than that between LDDE and infusion studies.

Our study suggests that in patients with moderate or severe fixed or resting perfusion abnormalities on standard ^{99m}Tc-sestamibi MPI studies, an extra imaging with prolonged infusion of ^{99m}Tc-sestamibi may provide complementary information to the conventional scintigraphy with respect to myocardial viability. Additional large-scale studies are warranted to determine the efficacy of this technique.

REFERENCES

1. Braunwald E, Rutherford JD. Reversible ischemic left ventricular dysfunction: evidence for the “hibernating myocardium.” *J Am Coll Cardiol* 1986; 8: 1467–1470.
2. Bonow RO, Dilsizian V, Cuocolo A, Bacharach SL. Identification of viable myocardium in patients with chronic

coronary artery disease and left ventricular dysfunction. Comparison of thallium scintigraphy with reinjection and PET imaging with ¹⁸F-fluorodeoxyglucose. *Circulation* 1991; 83: 26–37.

3. Piscione F, De Luca G, Perrone-Filardi P, Prastaro M, Pace L, Galasso G, et al. Relationship between contractile reserve, Tl-201 uptake, and collateral angiographic circulation in collateral-dependent myocardium: Implications regarding the evaluation of myocardial viability. *J Nucl Cardiol* 2003; 10: 17–27.
4. Chaudhry FA, Tauke JT, Alessandrini RS, Vardi G, Parker MA, Bonow RO. Prognostic implications of myocardial contractile reserve in patients with coronary artery disease and left ventricular dysfunction. *J Am Coll Cardiol* 1999; 34: 730–738.
5. Bax JJ, van der Wall EE, Harbinson M. Radionuclide techniques for the assessment of myocardial viability and hibernation. *Heart* 2004; 90 (Suppl V): v26–v33.
6. Beller GA. Myocardial hibernation: a clinician’s perspective. *Ital Heart J* 2002; 3: 291–293.
7. Cuocolo A, Pace L, Ricciardelli B, Chiariello M, Trimarco B, Salvatore M. Identification of viable myocardium in patients with chronic coronary artery disease: comparison of thallium-201 scintigraphy with reinjection and technetium-99m methoxyisobutyl isonitrile. *J Nucl Med* 1992; 33: 505–511.
8. Bonow RO, Dilsizian V. Thallium-201 and technetium-99m-sestamibi for assessing viable myocardium. *J Nucl Med* 1992; 33: 815–818.
9. Dakik HA, Howell JF, Lawrie GM, Espada R, Weilbaecher DG, He ZX, et al. Assessment of myocardial viability with ^{99m}Tc-sestamibi tomography before coronary bypass graft surgery: correlation with histopathology and postoperative improvement in cardiac function. *Circulation* 1997; 96: 2892–2898.
10. Kauffman GJ, Boyne TS, Watson DD, Smith WH, Beller GA. Comparison of rest thallium-201 imaging and rest technetium-99m sestamibi imaging for assessment of myocardial viability in patients with coronary artery disease and severe left ventricular dysfunction. *J Am Coll Cardiol* 1996; 27: 1592–1597.
11. DePuey EG, Rozanski A. Using gated technetium-99m-sestamibi SPECT to characterize fixed myocardial defects as infarct or artifact. *J Nucl Med* 1995; 36: 952–955.
12. Paul AK, Nabi HA. Gated myocardial perfusion SPECT: Basic principles, technical aspects, and clinical applications. *J Nucl Med Technol* 2004; 32: 179–187.
13. Levine MG, McGill CC, Ahlberg AW, et al. Functional assessment with electrocardiographic gated single-photon computed tomography improves the ability of technetium-99m sestamibi myocardial perfusion imaging to predict myocardial viability in patients undergoing revascularization. *Am J Cardiol* 1999; 83: 1–5.
14. Derebek E, Kozan O, Durak H, Kaya D, Capa G, Ozbilek E, et al. Infusion Versus Bolus Injection of Tc-99m Tetrofosmin in the Identification of Viable Myocardium. *Clin Nucl Med* 1998; 23 (3): 146–149.
15. Miron SD, Finkelhor R, Bahler R, Sodee B, Mellon EM. Use of Tc-99m sestamibi infusion for detection of hibernating myocardium. *Clin Nucl Med* 1995; 20: 440–445.
16. Tsuchida T, Yonekura Y, Takahashi N, Nakano A, Lee JD,

- Sadato N, et al. A trial for the quantification of regional myocardial blood flow with continuous infusion of Tc-99m MIBI and dynamic SPECT. *Ann Nucl Med* 1999; 13: 61–64.
17. Worsley DF, Fung AY, Jue FJ, Burns RJ. Identification of viable myocardium with technetium-99m-MIBI infusion. *J Nucl Med* 1995; 36: 1037–1039.
 18. Bax JJ, Poldermans D, Elhendy A, et al. Sensitivity, specificity, and predictive accuracies of various noninvasive techniques for detecting hibernating myocardium. *Curr Probl Cardiol* 2001; 26: 141–188.
 19. Travin MI, Bergman SR. Assessment of myocardial viability. *Semin Nucl Med* 2005; 35: 2–16.
 20. Baumgartner H, Porenta G, Lau Y, et al. Assessment of myocardial viability by dobutamine echocardiography, positron emission tomography and thallium-201 SPECT. Correlation with histopathology in explanted hearts. *J Am Coll Cardiol* 1998; 32: 1701–1708.
 21. Bax JJ, van der Wall EE, Harbinson M. Radionuclide techniques for the assessment of myocardial viability and hibernation. *Heart* 2004; 90: 26–33.
 22. Schneider CA, Voth E, Gawlich S, et al. Significance of rest technetium-99m sestamibi imaging for the prediction of improvement of left ventricular dysfunction after Q wave myocardial infarction: importance of infarct location adjusted thresholds. *J Am Coll Cardiol* 1998; 32: 648–654.