

## Pathologic hepatic Tc-99m-MDP uptake in polyostotic fibrous dysplasia

Ersoy KEKILLI,\* Cengiz YAGMUR,\* Akin KUZUCU,\*\* Omer SOYSAL,\*\*  
Ayse Sertkaya ÇIKIM\*\*\*\* and Kadir ERTEM\*\*\*

*Departments of \*Nuclear Medicine, \*\*Thoracic Surgery, \*\*\*Endocrinology and \*\*\*\*Orthopedic and Traumatology, Inonu University, Turgut Ozal Medical Center, Malatya, Turkey*

Fibrous dysplasia of bone is a congenital, sporadic developmental disorder characterized by immature fibrous connective tissue and bone deformities. Hepatic Tc-99m-MDP uptake is a rare, serendipitous finding during bone scanning studies. The present patient was a 25-year-old male who had severe polyostotic fibrous dysplasia. On Tc-99m-MDP (methylene diphosphonate) bone scintigraphy, increased activity accumulations were seen on multiple ribs, vertebrae and base of the cranium. In addition, diffuse increased pathologic uptake of Tc-99m-MDP in the liver was shown. Intravenous pamidronate was administered monthly for two months. In the third week of the last administration Tc-99m-MDP bone scintigraphy was performed again, but despite sustained bone involvement, pathologic hepatic uptake was not seen on the scan. We thought that pathologic hepatic Tc-99m-MDP accumulation, may be related to the formation and aggregation of calcium oxalate and phosphate crystals which improved with pamidromat treatment.

**Key words:** fibrous dysplasia, hepatic, extra-osseous

### INTRODUCTION

FIBROUS DYSPLASIA of bone is a congenital, sporadic, developmental condition.<sup>1</sup> The pathogenetic abnormality is an expanding fibrous lesion of bone-forming mesenchyma.<sup>2</sup> Fibrous dysplasia occurs with somatic activating mutations of the gene encoding the G $\alpha$  subunit of the G protein that couples hormone receptors to adenylate cyclase. The disease affects either sex and is generally diagnosed in childhood or adolescence. The clinical picture of fibrous dysplasia can be monostotic or polyostotic. Some patients have characteristic hyperpigmented skin macules called cafe-au lait spots and endocrine hyperfunction (i.e., McCune-Albright Syndrome). The endocrinopathy is usually manifested as pseudoprecocious puberty in girls and less commonly thyrotoxicosis, Cushing syndrome, acromegaly, hyperprolactinemia, or hyperparathyroidism.<sup>3</sup> Although serum calcium and phosphate levels are normal, serum alkaline phosphatase activity can

be increased. Monostotic disease is more common, but any bone can be affected. The femur, tibia, ribs, and facial bones are most frequently involved. Spontaneous improvement does not occur. Skeletal lesions may progress, and new ones may appear, but in most patients mild disease stays quiescent.<sup>4</sup> No established medical treatment exists for the skeletal disease; however promising responses have been reported with intravenous administration of pamidronate.<sup>5</sup> Increased uptake of radiopharmaceuticals is usually observed on affected bones scintigraphically but hepatic uptake is an unexpected finding. Here we present a case of fibrous dysplasia with diffuse hepatic uptake detected on bone scan.

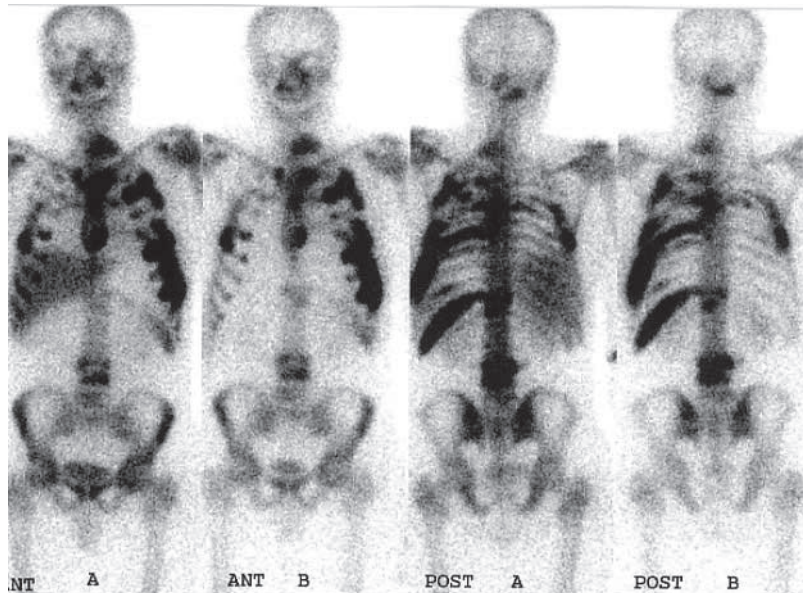
### CASE REPORT

A twenty-five year old male patient presented with back and chest pain which had worsened over the preceding two years. His physical examination was normal. Chest X-ray and computerized tomography revealed multiple expansile destructive cystic lesions in the ribs and lytic lesions in the fourth, fifth and sixth thoracic vertebrae. A Tc-99m-MDP bone scan showed increased activity accumulation on the left ribs from 1st to 11th; right 4th and 5th ribs, lumbar 3rd and 4th vertebrae and base of the

Received March 17, 2004, revision accepted June 23, 2004.

For reprint contact: Ersoy Kekilli, M.D., Department of Nuclear Medicine, Inonu University, Turgut Ozal Medical Center, Elazig Avenue, 7. km. Malatya, TURKEY.

E-mail: ekekilli@inonu.edu.tr



**Fig. 1** Multiple bone involvement and diffuse increased  $^{99m}\text{Tc}$ -MDP pathologic uptake in the liver (A) and abnormal hepatic Tc-99m-MDP uptake improvement with pamidronate treatment (B) were shown.

cranium, and irregular, mildly increased uptake in multiple thoracic vertebrae and sternum. In addition, images demonstrated intense and diffuse hepatic uptake (Fig. 1). Laboratory examinations revealed increased serum alkaline phosphatase activity of 449 U/l (normal 38–155), normal serum calcium concentration of 10.3 mg/dl (normal 8.1–10.4), and inorganic phosphate concentration of 3.1 mg/dl (normal 2.6–4.7). Urinary calcium concentration (250 mg/day) and serum parathyroid hormone level (69.3 pg/ml normal range: 7–72 pg/ml) ruled out either hyperparathyroidism no endocrinologic hyperfunction was revealed. There was no history of repeated iron dextran injection. Serum transaminase values were within the normal limits, and serological tests for viral hepatitis were negative.

An open incisional biopsy of the left fifth rib was performed and the histopathological features were consistent with fibrous dysplasia. To exclude the possibility of amyloidosis—which would explain the abnormal hepatic radiopharmaceutical accumulation—gingival biopsy was performed. However, no amyloid deposition was found.

Intravenous pamidronate (Aredia, Novartis) was administered for severe lytic bone lesions and bone pain. The patient received 90 mg of pamidronate in 500 ml 5% dextrose solution as a 2-h infusion. The infusion was repeated every 4 weeks over a period of 2 months. Neither hypocalcemia or hypophosphatemia nor fever or infusion site reaction was observed during the treatment. However no significant clinical improvement was achieved with in regard to pain or the radiographical findings.

On the 3rd week of the last pamidronate therapy, Tc-

99m-MDP bone scan was repeated. Despite a lack of any difference on the bone scans, the pathologic hepatic uptake had disappeared (Fig. 1).

## DISCUSSION

Fibrous dysplasia, in general, appears as an area of markedly increased uptake on bone scintigraphy. Approximately 15% of cases are polyostotic, leading to multifocal areas of increased uptake. However, diffuse hepatic uptake of Tc-99m-MDP is an unusual, serendipitous finding in nuclear medicine practice, occurring less frequently than focal hepatic abnormalities. Although several possible reasons are suggested, the exact mechanism of non-osseous uptake of Tc-99m-MDP remains speculative.

The extra-osseous uptake of Tc-99m-MDP can suggest the presence of amyloid deposits or the result of an altered serum calcium phosphate balance.<sup>6,7</sup> The elimination of amyloidosis may provide a possible explanation of the abnormal distribution of these ions in this case. In addition, to our knowledge an association between amyloidosis and fibrous dysplasia has not been reported yet.

Extra-osseous uptake has also been reported in patients with multiple myeloma (MM). It has been concluded that amyloid deposits are the probable reason for such uptake. However, not only is renal failure relatively common in MM, but is also usually associated with hypercalcemia.<sup>6,8,9</sup> Disturbances in calcium metabolism can lead to metastatic calcification, which is visualized with Tc-99m-MDP scintigraphy. Similar disturbances leading to radioisotope uptake in the soft tissue can be seen in hyperparathyroidism as well.<sup>10</sup>

The extra-osseous uptake on bone scanning is largely due to renal failure in which there is a failure to excrete the radiopharmaceuticals. Any disease causing extracellular fluid expansion causes enhanced regional vascularity, and permeability with elevated tissue calcium concentration, also results in increased radiopharmaceutical uptake.<sup>11</sup> De Francisco et al.<sup>12</sup> reported that the presence of non-visceral soft tissue calcification was not related to the age, sex, duration of end-stage renal failure treatment, total serum calcium, magnesium, phosphate, calcium phosphate balance, alkaline phosphatase, ionized calcium, serum aluminum, intact parathyroid hormone or parathyroid gland weight in 42 uremic patients.

Intense and diffuse liver uptake of Tc-99m-MDP has also been reported in cases of severe hepatic necrosis but it could not be determined as a finding consistent with the disease.<sup>13,14</sup>

Hepatic and other ectopic soft tissue calcifications can also be seen following orthotopic liver transplantation. Munoz et al.<sup>15</sup> reported that there was no difference in serum calcium, magnesium, or vitamin D or phosphate levels, between 20 patients with and without soft tissue calcification who underwent liver transplantation.

Palmer et al.<sup>16</sup> reported that Tc-99m-hydroxymethylene diphosphonate is a colloidal preparation and labeled colloid formed in the presence of calcium salts may aggregate *in vitro* and be rapidly removed by the reticuloendothelial system *in vivo*. This aggregated radiopharmaceutical uptake in liver, spleen and muscle was significantly higher and bone uptake was significantly lower in mice. In our case, hepatic Tc-99m-diphosphonate uptake was evident but spleen and muscle uptake was not seen. Bone uptake did not differ between the two bone scans.

Polyostotic fibrous dysplasia can be complicated by hypercalcemia and hypophosphatemia, which roughly correspond to the extent of the bone lesions. In addition; the same biochemical findings can be found in hyperparathyroidism which can also be a component of fibrous dysplasia. We excluded hyperparathyroidism on the basis of normal serum calcium, phosphorus and parathyroid hormone levels, accompanied with a normal daily calcium excretion.

Bisphosphonates inhibit bone resorption. They are now commonly used in the treatment of osteoporosis, tumor-induced hypercalcemia, Paget disease, bone metastases and some other bone diseases.<sup>17</sup> Azuma et al.<sup>18</sup> showed <sup>14</sup>C labeled alendronate (i.e., bisphosphonate) in rat tibia osteoclasts. Reszka et al.<sup>17</sup> reported the direct/indirect apoptotic effects of bisphosphonates on osteoclasts. Pamidronate disodium is another bisphosphonate. Pamidronate adsorbs to calcium phosphate (hydroxyapatite) crystals in bone and may directly block dissolution of this major mineral component of bone.

Urinary hydroxyproline excretion, a bone resorption marker, significantly decreases after pamidronate treat-

ment. It has been reported that despite a definitive decrease in bone turnover, bone histomorphometrical results were not changed with pamidronate treatment.<sup>3,19</sup> In our case, bone involvement was not changed on bone scintigraphy but we could not evaluate the bone turnover parameters biochemically.

In addition to its anti-resorptive effect, bisphosphonates also inhibit the formation and aggregation of the calcium oxalate and phosphate crystals, block the transformation of amorphous calcium phosphate into hydroxyapatite, and delay the aggregation of hydroxyapatite crystals. For this reason, bisphosphonates can be used in the inhibition and protection of soft tissue calcifications.<sup>20</sup> In our case, improvement in hepatic Tc-99m-MDP uptake may be related to this effect of pamidronate treatment.

The soft tissue uptake of Tc-99m-diphosphonates is often difficult to explain.

Palmer et al.<sup>16</sup> reported that the colloidal preparation of the Tc-99m-hydroxymethylene diphosphonate may aggregate *in vitro* in the presence of calcium salts. We thought that pathologic hepatic Tc-99m-MDP accumulation may be related to the formation and aggregation of the calcium oxalate and phosphate crystals in the liver and other extra-osseous tissues, which might be the *in vivo* aggregation mechanism of the Tc-99m-diphosphonates. Incidentally, abnormal hepatic Tc-99m-MDP uptake improved with pamidronate treatment in our patient.

## REFERENCES

1. Kitoh H, Yamada Y, Nogami H. Different genotype of periosteal and endosteal cells of a patient with polyostotic fibrous dysplasia. *J Med Genet* 1999; 36: 724–725.
2. Favus MJ, ed. *Primer on the metabolic bone diseases and disorders of mineral metabolism, 4th ed.* Philadelphia; Lippincott Williams & Wilkins, 1999.
3. Plotkin H, Rauch F, Zeitlin L, Munns C, Travers R, Glorieux FH. Effect of pamidronate treatment in children with polyostotic fibrous dysplasia of bone. *J Clin Endocrinol Metab* 2003; 88: 4569–4575.
4. Resnick D. *Diagnosis of bone and joint disorders, 3rd ed.* Philadelphia; WB Saunders, 1995.
5. Charpurlat RD, Meunier PJ. Fibrous dysplasia of bone. *Bailliere's Clin Rheumatol* 2000; 14: 385.
6. Eigel BA, Stier SA, Wakem C. Non-osseous bone scan abnormalities in multiple myeloma associated with hypercalcemia. *Clin Nucl Med* 1988; 13: 869–873.
7. Cronhjort M, Saaf M, Sjoberg HE, Schnell PO, Jacobsson H. Influence of the phosphate balance on the activity distribution of <sup>99m</sup>Tc-hydroxymethylene diphosphonate. Experimental studies in the mouse. *Acta Radiol* 1998; 39: 427–433.
8. Evans JC, Murphy M, Eyes B. Extensive soft tissue uptake of <sup>99m</sup>Tc methylene diphosphonate in a patient with multiple myeloma. *Br J Radiol* 2000; 73: 1018–1020.
9. Posch TJ, Olson SP. Marked soft tissue uptake of bone tracer in a patient with amyloidosis and multiple myeloma. *Clin Nucl Med* 1992; 17: 909.

10. Hwang GJ, Lee JD, Park CY, Lim SK. Reversible extra-skeletal uptake of bone scanning in primary hyperparathyroidism. *J Nucl Med* 1993; 37: 469–471.
11. Peller PJ, Ho VB, Kransdorf MJ. Extraosseous Tc-99m MDP uptake: a pathophysiologic approach. *Radiographics* 1993; 13: 715–734.
12. De Francisco AM, Cassidy MJ, Owen JP, Ellis HA, Farndon JR, Ward MK, et al. Ectopic calcification. The role of parathyroid hormone. *Proc Eur Dial Transplant Assoc Eur Ren Assoc* 1985; 21: 888–894.
13. Bykov S, Garty I, Bisharat N. Transient Tc-99m MDP hepatic uptake induced by acute hypoxic hepatitis. *Clin Nucl Med* 2001; 26: 550–551.
14. Cardaci GT, Van der Schaaf A. Hepatic uptake of Tc-99m MDP in ischemic hepatitis. *Clin Nucl Med* 1993; 18: 906–907.
15. Munoz SJ, Nagelberg SB, Green PJ, Angstadt JD, Yang SL, Jarrell BE, et al. Ectopic soft tissue calcium deposition following liver transplantation. *Hepatology* 1988; 8: 476–483.
16. Palmer AM, Watt I, Dieppe PA. Soft-tissue localization of <sup>99m</sup>Tc-hydroxymethylene diphosphonate due to interaction with calcium. *Clin Radiol* 1992; 45: 326–330.
17. Reszka AA, Halasy-Nagy JM, Masarachia PJ, Rodan GA. Bisphosphonates act directly on the osteoclast to induce caspase cleavage of mst1 kinase during apoptosis. A link between inhibition of the mevalonate pathway and regulation of an apoptosis-promoting kinase. *J Biol Chem* 1999; 274: 34967–34973.
18. Azuma Y, Sato H, Oue Y, Okabe K, Ohta T, Tsuchimoto M, et al. Alendronate distributed on bone surfaces inhibits osteoclastic bone resorption *in vitro* and in experimental hypercalcemia models. *Bone* 1995; 16: 235–245.
19. Bravenboer N, Papapoulos SE, Holzmann P, Hamdy NA, Netelenbos JC, Lips P. Bone histomorphometric evaluation of pamidronate treatment in clinically manifest osteoporosis. *Osteoporos Int* 1999; 9: 489–493.
20. Fleisch H. Bisphosphonates: mechanisms of action. *Endocr Rev* 1998; 19: 80–100.