

## Semiquantitative analysis of interictal glucose metabolism between generalized epilepsy and localization related epilepsy

Akio HIKIMA,\* Hiroyuki MOCHIZUKI,\* Noboru ORIUCHI,\*\* Keigo ENDO\*\* and Akihiro MORIKAWA\*

*\*Department of Pediatrics and Developmental Medicine, and*

*\*\*Department of Diagnostic Radiology and Nuclear Medicine, Gunma University Graduate School of Medicine*

Positron emission tomography (PET) with [ $^{18}\text{F}$ ]fluoro-D-deoxyglucose (FDG) has been used to detect seizure foci and evaluate surgical resection with localization related epilepsies. However, few investigations have focused on generalized epilepsy in children. To reveal the pathophysiology of generalized epilepsy, we studied 11 patients with generalized epilepsy except West syndrome, and 11 patients with localization related epilepsy without organic disease. The FDG PET was performed by simultaneous emission and transmission scanning. We placed regions of interest (ROI) on bilateral frontal lobe, parietal lobe, occipital lobe, temporal lobe, basal ganglia, thalamus and cerebellum. Standardized uptake value (SUV) was measured and normalized to SUV of ipsilateral cerebellum. Then, we compared the data of generalized epilepsy to those of localization related epilepsy.

FDG PET revealed significant interictal glucose hypometabolism in bilateral basal ganglia in generalized epilepsy compared to that in localization related epilepsy (right side:  $p = 0.0095$ , left side:  $p = 0.0256$ , Mann-Whitney test). No other region showed any significant difference ( $p > 0.05$ ) between the two groups. These findings indicate that the basal ganglia is involved in the outbreak of generalized seizures or is affected secondarily by the epileptogenicity itself.

**Key words:** children, epilepsy, positron emission tomography, SPECT

### INTRODUCTION

RECENT ADVANCES in neuroimaging techniques have made a great contribution to the diagnosis, management, and clarification of the pathophysiology in epilepsies. Positron emission tomography (PET) has been utilized for more than two decades to investigate seizure disorders, and is an accurate and noninvasive method to study brain activity using systemically administered tracers labeled with positron emitting isotopes.<sup>1</sup>

The role of PET in the other pediatric epileptic conditions has been reported. In the Lennox-Gastaut syndrome, PET with [ $^{18}\text{F}$ ]-fluorodeoxyglucose (FDG) has demonstrated different metabolic patterns, underscoring the

heterogeneity of this syndrome.<sup>2</sup> In some patients with hemimegalencephaly, PET has revealed bilateral metabolic abnormalities.<sup>3</sup> Also, in patients with Sturge-Weber syndrome, PET may provide a sensitive measure of the extent of cerebral involvement, especially during the first year of life.<sup>4</sup>

On the other hand, generalized epilepsy starts at all ages in the childhood period, and is a very common disorder in children.<sup>5</sup> Despite a focal epileptic pattern, the tonic and general spasms are quite symmetrical. Although FDG-PET has been used to detect seizure foci and to evaluate the area of surgical resection in localization related epilepsies,<sup>6</sup> the clinical value of PET studies in generalized epileptic children has not been analyzed in detail.

We considered that the evaluation of the interictal FDG-PET in patients with general and partial epilepsy would be useful, and undertook this study to determine the pathophysiology of generalized epilepsy in children using FDG-PET.

Received March 16, 2004, revision accepted June 25, 2004.

For reprint contact: Hiroyuki Mochizuki, M.D., Department of Pediatrics and Developmental Medicine, Gunma University Graduate School of Medicine, Showa-Machi 3-39-15, Maebashi 371-8511, JAPAN.

## PATIENTS AND METHODS

### STUDY PROTOCOL

All of the patients were asked about their past history of epilepsy in detail, and underwent detailed neurologic examinations, interictal and ictal EEGs, CT and/or MRI. After diagnosing epilepsy, the cerebral glucose metabolism was measured using the FDG-PET technique.<sup>7,8</sup>

### STUDY SUBJECTS

Eleven children with generalized epilepsy (8 boys and 3 girls, 3 to 19 years old; mean 10.5 years) participated in this study (Table 1). A clinical diagnosis of epilepsy was

based on previous reports; a characteristic history of epilepsy, and identification of neurologic examinations. In all of them, EEG showed a marked increase in abundance and amplitude of wake and sleep interictal abnormalities. CT and/or MRI showed no virtual abnormalities. West syndrome has been studied using FDG PET, and is now being discussed in connection with the relationship between brain hypometabolism and convulsions.<sup>9,10</sup> Thus, patients with West syndrome were excluded from this study. For comparison, eleven children with partial epilepsy (7 boys and 4 girls, 3 to 19 years old; mean 7.7 years) also participated in this study (Table 2). On MRI, one patient showed diffuse brain atrophy, and one showed

**Table 1** Clinical features and interictal EEG findings in patients with generalized epilepsy

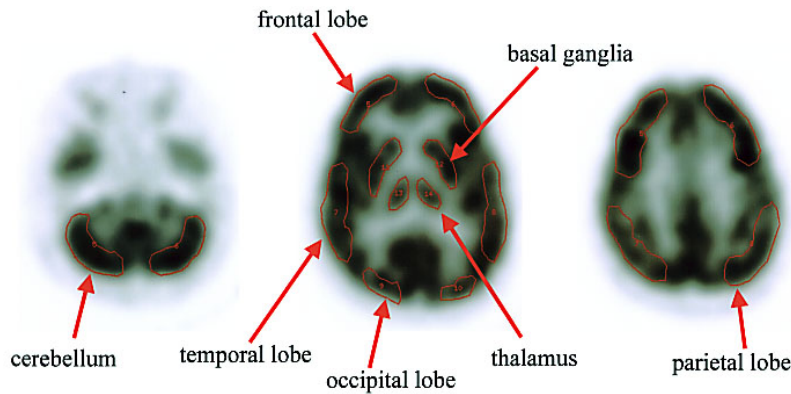
Patient	Age (year)	Onset (year)	Seizure type	Interictal EEG	Drugs at time of PET study
1	19	6	GTC, myoclonus	photoparoxysmal response	VPA, ZNS
2	19	6	GTC, myoclonus	photoparoxysmal response	VPA, ZNS
3	6	6	myoclonus	diffuse sp-w	VPA
4	10	3	GTC, myoclonus absence	diffuse sp-w	VPA, ESM
5	10	9	absence	3 Hz diffuse sp-w	VPA
6	3	1	GTC, myoclonus atonic seizure absence	diffuse sp-w	VPA, CZP ZNS
7	6	4	GTC, myoclonus	diffuse sp-w	VPA, CZP
8	3	2	myoclonus, absence	diffuse slow wave	VPA
9	13	11	GTC	diffuse sp-w	VPA
10	12	12	GTC	diffuse sp-w photoparoxysmal response	VPA
11	14	14	GTC	normal	VPA

GTC; generalized tonic epilepsy, sp-w; spike and wave, VPA; Valproic acid, ESM; Ethosuximide, CZP; Clonazepam, ZNS; Zonisamide

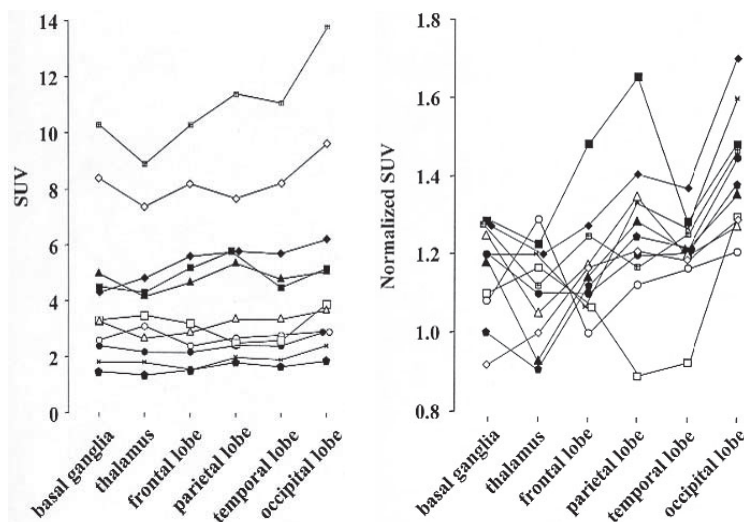
**Table 2** Control clinical and interictal EEG features

Patient	Age at scan	Age at onset	Seizure type	Interictal EEG	Drugs at time of scan
1	14	9	CPS	frontal ~ diffuse sp-w	CBZ
2	9	7	CPS	multifocal sp-w	VPA, CBZ
3	7	2	CPS	frontal slow	ZNS, CBZ
4	4	4	CPS, s-GTC	frontal slow ~ sp-w	CBZ, PB
5	1	0	CPS	normal	CBZ
6	1	0	CPS, s-GTC	normal	CBZ
7	1	1	s-GTC	normal	CBZ
8	11	9	CPS	left frontal sp	PHT, CBZ
9	9	7	simple partial seizure	normal	PHT, CBZ
10	13	4	CPS, SPS, s-GTC	right central sp	VPA, PB
11	15	14	CPS	frontal sp	CBZ

CPS; complex partial seizure, s-GTC; secondarily generalized tonic epilepsy, sp-w; spike and wave, sp; spike, PHT; Phenytoin, VPA; Valproic acid, ESM; Ethosuximide, CBZ; Carbamazepine, CZP; Clonazepam, PB; Phenobarbital, ZNS; Zonisamide



**Fig. 1** PET images and settings of ROI; The density of those images indicates the degree of determine standardized uptake value (SUV). ROIs were manually placed on bilateral cerebellum, basal ganglia, thalamus, frontal lobe, parietal lobe, temporal lobe and occipital lobe, to determine SUV of FDG in 3 different transaxial images. Each SUV was represented by the average of all ROIs.



**Fig. 2** Normalization of SUV, a; the SUV of right hemisphere of each patient. The level of SUV is variable between the individuals. b; SUV was normalized with ipsilateral cerebellum. After the normalization, interindividual comparison became visually and statistically understandable.

subcortical hemangioma in the right frontal lobe. The others had no abnormal findings.

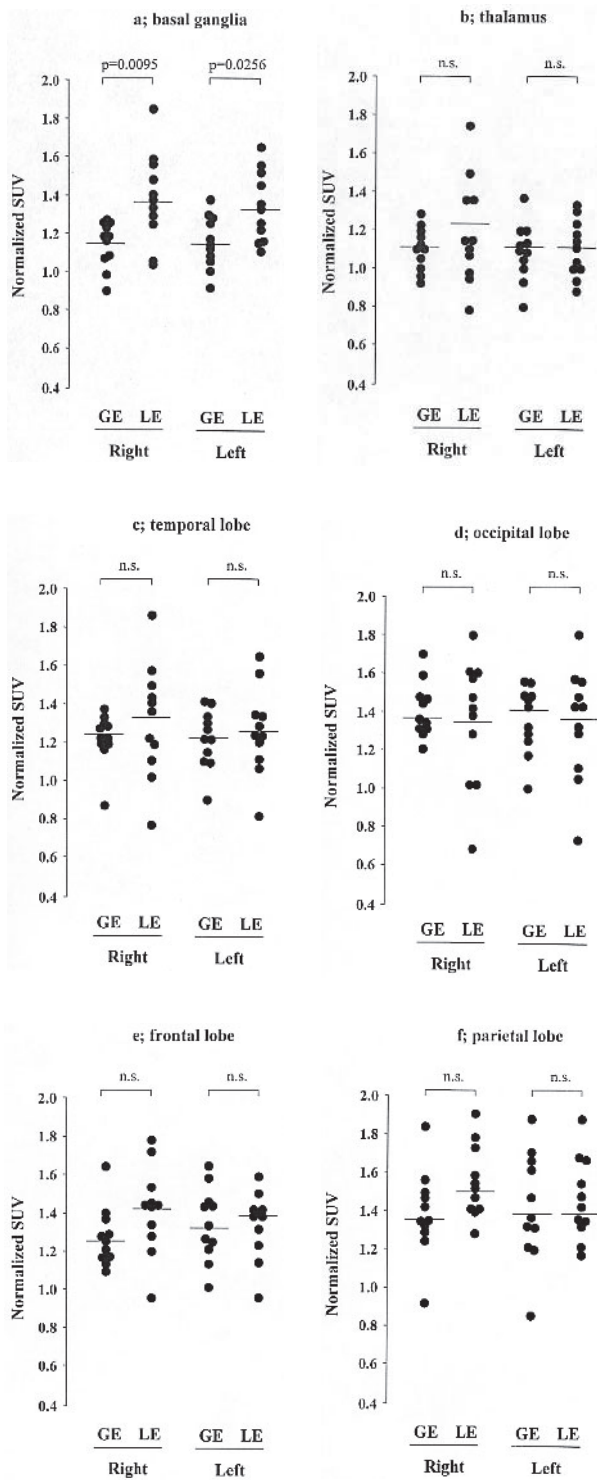
All subjects were free of upper respiratory tract infections for more than 2 weeks prior to the study, and none had received any medication for at least 12 hours prior to the study. Informed parental consent was obtained before each study.

#### FDG PET imaging technique

All PET studies were performed in accordance with the policies of the hospital's human subject protection committee, and informed consent was obtained. PET studies were performed using a SET 2400W (Shimadzu Corporation, Kyoto, Japan). An 8 min simultaneous emission/transmission scan was performed about 50 min after FDG injection (5 MBq/kg). Spatial resolution at the center of

the field was 4.2 mm (FWHM), and the slice thickness was 3.125 mm.

All studies were initially planned to be conducted in the wake state, with children's eyes open and ears unoccluded. Despite the presence of seizures, visual, auditory, and other sensory stimuli being kept to a minimum by dimming the lights and discouraging parent-child interaction just before and during at least the first 30 min after FDG administration. However, the studies in less than 5-years old children had to be performed during sleep in the supine position after trichlorethyl phosphate monosodium syrup (70 mg/kg) was administered because of problems with cooperation. Approximately 50 min after injection, a head-holder was used to minimize head movement, and tomographic scanning of the brain was initiated.



**Fig. 3** a–f; Statistical difference in normalized SUV of FDG in each ROI. A significant interictal glucose hypometabolism on both sides of the basal ganglia in generalized epilepsy compared to the localization related epilepsy is shown in Figure 3a. No other regions showed any significant difference between the two groups (b–f). GE; generalized epilepsy, LE; localization related epilepsy, n.s.; not significant.

By using attenuation corrected transverse images, injected doses of FDG, body weight, and cross-calibration factors between the PET scanner and the dose calibrator, functional images of the standardized uptake value (SUV) were also produced. SUV was defined as  $SUV = \text{conc} / \text{dose} / \text{weight}$ , where conc is the radioactive concentration in the tissue or lesion in MBq per gram, dose is the injected dose of FDG in MBq, and weight is the patient's body weight in grams.

We placed a region of interest (ROI) on both sides of cerebellum, basal ganglia, thalamus, frontal lobe, parietal lobe, temporal lobe and occipital lobe, and determined SUV in each ROI (Fig. 1). Furthermore, SUV was normalized with ipsilateral cerebellum for comparison.

#### DATA ANALYSIS

Non-parametric analysis of variance (Kruskal-Wallis method) was used to determine the significant difference between groups. If a significant overall difference was found, a Mann-Whitney U-test was performed to assess the significant difference between individual groups. For convenience, data are expressed as means  $\pm$  S.E.M. A p-value of less than 0.05 was considered to be significant.

### RESULTS

#### (1) Normalization of SUV

Figure 2a shows the SUV of ROIs in the right hemisphere of each patient with generalized epilepsy. The level of SUV varies in individual patients. Therefore, normalization of SUV is required to compare these values between them. Then, every SUV was normalized to ipsilateral cerebellar SUV, and the differences between individuals were resolved (Fig. 2b). Thus, normalization of SUV is useful for this study, and the normalized SUV in patients with generalized epilepsy and those in patients with partial epilepsy were used to compare the data.

#### (2) PET results

We demonstrated the presence of interictal glucose hypometabolism in the bilateral basal ganglia in generalized epilepsy compared to that in localization related epilepsy. The normalized SUV in the bilateral basal ganglia in generalized epilepsy were significantly lower than that in partial epilepsy (right side:  $p = 0.0095$ , left side:  $p = 0.0256$ , Mann-Whitney test, Fig. 3a). No other regions showed any significant difference ( $p > 0.05$ ) between the two groups (Fig. 3 b–f).

### DISCUSSION

Advances in neuroimaging continue to resolutionize the evaluation and management of patients with central nervous system disorders. The impact in the management of patients with seizures and epilepsy cannot be overemphasized, considering the high sensitivity and exquisite de-

gree of anatomic resolution now available with different imaging techniques. In neurology, one of the most widely accepted uses of FDG-PET is in the field of epilepsy.<sup>11</sup> Also, the interictal FDG-PET technique used in this study is a sensitive technique to identify the functional deficit zone in patients with focal epilepsy. It has been suggested that the changes are more extensive than the structural and EEG abnormalities. Nevertheless, when MRI is normal, PET is able to aid in the localization.

Previously, however, few neuroimaging studies have been performed in generalized epilepsy, and it is generally believed that patients with primary generalized epilepsy have normal findings.<sup>12</sup> Using FDG-PET, Theodore et al. reported no significant interictal changes in glucose metabolism in patients with absence seizures and tonic-clonic generalized seizures.<sup>13</sup> On the other hand, Swartz et al. showed some degree of regional decrease in relative glucose uptake in patients with juvenile myoclonic epilepsy.<sup>14</sup> Thus, localization and abnormality in glucose metabolism in generalized epilepsy are still unclear.

In this study, we examined the interictal FDG-PET for the evaluation of the original lesion in 11 children with generalized epilepsy and compared with partial epilepsy. Our study demonstrated the interictal glucose hypometabolism in the bilateral basal ganglia in generalized epilepsy compared to the basal ganglia in partial epilepsy. Our results implicate the basal ganglia are related to emergence of the generalized seizure. Because abnormalities of basal ganglia are bilateral and this abnormality was not found in the control group, we suppose that there is a basic mechanism of generalized epilepsy affecting the function of bilateral basal ganglia. There have been no reports of interictal glucose hypermetabolism of basal ganglia in generalized epilepsy.

During the last two decades, there has been increasing experimental evidence that the basal ganglia circuitry may be a part of the remote control system influencing the spread of epileptic seizures.<sup>15</sup> The basal ganglia constitute a major integrative system of the forebrain, critically involved in the adaptive control of behavior.<sup>16,17</sup> While the basal ganglia have been considered to be essentially involved in the control of movement, it is now accepted that they contribute to a wide range of functions including motor, cognitive, motivational and emotional aspects of behavior.<sup>18,19</sup> To achieve these functions, the basal ganglia process a considerable diversity of information originating from the entire cerebral cortex including the hippocampus, as well as the intralaminar and midline thalamic nuclei and the amygdala. In turn, via their efferent pathways, the basal ganglia control the excitability of brainstem premotor networks and thalamic nuclei connected to the motor, premotor, prefrontal and limbic areas of the cerebral cortex.

PET studies of various neurotransmission systems in epileptic patients have provided information about the involvement of the basal ganglia in epilepsy. Most of

these studies have evaluated the GABAergic and dopaminergic systems.<sup>15</sup> It seems reasonable to think that the basal ganglia are involved in seizure propagation and that dopamine may be important in this process, as well as in determining the seizure threshold.<sup>20</sup> Several authors have suggested that the basal ganglia are involved in the control of epileptic seizures.<sup>21</sup> Clinical and electrophysiological studies as well as experimental data have demonstrated abnormalities of basal ganglia in generalized and partial seizures.<sup>22</sup> The present study clearly demonstrated hypometabolism of glucose in basal ganglia in children with generalized epilepsy.

However, in patients with untreated generalized epilepsies such as childhood and juvenile absence epilepsy, no significant change in benzodiazepine/GABA Type A receptors was found in the thalamus, the basal ganglia, the cerebellum or the occipital and parietal cortex, by [<sup>11</sup>C]flumazenil-PET.<sup>23,24</sup> Savic et al. reported a moderate decrease of [<sup>11</sup>C]flumazenil binding in the thalamus of patients with generalized tonic-clonic seizures.<sup>25</sup> Thus, the precise role of the subcortical structures is still controversial, and further studies are needed to evaluate the significance of abnormalities in the basal ganglia in generalized epilepsy and other different epilepsies.

In this report, we were concerned that some anti-convulsive drugs might suppress brain metabolism and affect our research into brain glucose hypometabolism which is part of a FDG-PET study. Phenytoin (PTH) clearly decreases cerebellum metabolism,<sup>26</sup> and we compared the values of cerebellum SUV in two patients, Patient 8 and Patient 9, who used PTH, with other patients who did not use PTH in a control group. The values of SUV in the control group were  $2.56 \pm 1.4$  and  $2.56 \pm 1.4$  (mean  $\pm$  S.D.), in Patient 8, 2.50 and 2.60, and in Patient 9, 4.59 and 4.94 (the right and left cerebellum, respectively). We also examined the relationship between the significant decrease in SUV and other anti-convulsive drugs in the cerebellum and in other parts of the brain but found no significant correlation (data not shown). These data suggested that the anti-convulsive drugs administered to our patients did not significantly suppress brain metabolism which we evaluated using the FDG PET technique.

In conclusion, our functional imaging study with FDG-PET strongly suggests that the basal ganglia are involved in epileptic seizures. These findings support the current contention that the functional organization of the basal ganglia can dynamically control generalized seizures through their input-output relationships. Although many aspects of the anatomy and physiology of this system have now been clarified, allowing the emergence of basic principles of organization, the precise contribution of the basal ganglia to the propagation of epileptic activity is still unclear. Further studies to evaluate the precise mechanism of generalized epilepsy are needed.

## REFERENCES

1. Kuzniecky RI. Neuroimaging in pediatric epilepsy. *Epilepsia* 1996; 37 (Suppl 1): 10–21.
2. Henry TR, Mazziotta JC, Engel J Jr, Christenson PD, Zhang JX, Phelps ME, et al. Quantifying interictal metabolic activity in human temporal lobe epilepsy. *J Cereb Blood Flow Metab* 1990; 10: 748–757.
3. Hoffmann KT, Amthauer H, Liebig T, Hosten N, Etou A, Lehmann TN, et al. MRI and <sup>18</sup>F-fluorodeoxyglucose positron emission tomography in hemimegalencephaly. *Neuroradiology* 2000; 42: 749–752.
4. Lee JS, Asano E, Muzik O, Chugani DC, Juhasz C, Pfund Z, et al. Sturge-Weber syndrome: correlation between clinical course and FDG PET findings. *Neurology* 2001; 57: 189–195.
5. Camfield P, Camfield C. Epileptic syndromes in childhood: clinical features, outcomes, and treatment. *Epilepsia* 2002; 43 (Suppl 3): 27–32.
6. Dupont S, Semah F, Samson Y, Baulac M. The underlying pathophysiology of ictal dystonia in temporal lobe epilepsy: an FDG-positron emission tomography study. *Neurology* 1998; 51: 1289–1292.
7. Yanagawa T, Watanabe H, Inoue T, Ahmed AR, Tomiyoshi K, Shinozaki T, et al. Carbon-11 choline positron emission tomography in musculoskeletal tumors: comparison with fluorine-18 fluorodeoxyglucose positron emission tomography. *J Comput Assist Tomogr* 2003; 27: 175–182.
8. Sasaki M, Kuwabara Y, Yoshida T, Fukumura T, Morioka T, Nishio S, et al. Carbon-11-methionine PET in focal cortical dysplasia: a comparison with fluorine-18-FDG PET and technetium-99m-ECD SPECT. *J Nucl Med* 1998; 39: 974–977.
9. Metsahonkala L, Gaily E, Rantala H, Salmi E, Valanne L, Aarimaa T, et al. Focal and global cortical hypometabolism in patients with newly diagnosed infantile spasms. *Neurology* 2002; 58: 1646–1651.
10. Itomi K, Okumura A, Negoro T, Watanabe K, Natsume J, Takada H, et al. Prognostic value of positron emission tomography in cryptogenic West syndrome. *Dev Med Child Neurol* 2002; 44: 107–111.
11. Chugani HT, Rintahaka PJ, Shewmon DA. Ictal patterns of cerebral glucose utilization in children with epilepsy. *Epilepsia* 1994; 35: 813–822.
12. Semah F. PET imaging in epilepsy: basal ganglia and thalamic involvement. *Epileptic Disord* 2002; 4 (Suppl 3): 55–60.
13. Theodore WH, Brooks R, Margolin R, Patronas N, Sato S, Porter RJ, et al. Positron emission tomography in generalized seizures. *Neurology* 1985; 35: 684–690.
14. Swartz BE, Simpkins F, Halgren E, Mandelkern M, Brown C, Krisdakumtorn T, et al. Visual working memory in primary generalized epilepsy: an <sup>18</sup>FDG-PET study. *Neurology* 1996; 47: 1203–1212.
15. Slaughter SJ, Paz T, Mahon S, Maurice N, Charpier S, Deniau JM. Functional organization of the circuits connecting the cerebral cortex and the basal ganglia: implications for the role of the basal ganglia in epilepsy. *Epileptic Disord* 2002; 4 (Suppl 3): 9–22.
16. Graybiel AM. Building action repertoires: memory and learning functions of the basal ganglia. *Curr Opin Neurobiol* 1995; 5: 733–741.
17. Graybiel AM. The Basal Ganglia and Chunking of Action Repertoires. *Neurobiol Learn Mem* 1998; 70: 119–136.
18. Pennartz CM, Groenewegen HJ, Lopes da Silva FH. The nucleus accumbens as a complex of functionally distinct neuronal ensembles: an integration of behavioural, electrophysiological and anatomical data. *Prog Neurobiol* 1994; 42: 719–761.
19. Rogers RD, Baunez C, Everitt BJ, Robbins TW. Lesions of the medial and lateral striatum in the rat produce differential deficits in attentional performance. *Behav Neurosci* 2001; 115: 799–811.
20. Deransart C, Depaulis A. The control of seizures by the basal ganglia? A review of experimental data. *Epileptic Disord* 2002; 4 (Suppl 3): 61–72.
21. Deransart C, Vercueil L, Marescaux C, Depaulis A. The role of basal ganglia in the control of generalized absence seizures. *Epilepsy Res* 1998; 32: 213–223.
22. Rektor I, Kuba R, Brazdil M. Interictal and ictal EEG activity in the basal ganglia: an SEEG study in patients with temporal lobe epilepsy. *Epilepsia* 2002; 43: 253–262.
23. Prevett MC, Lammertsma AA, Brooks DJ, et al. Benzodiazepine-GABA<sub>A</sub> receptors in idiopathic generalized epilepsy measured with [<sup>11</sup>C]flumazenil and positron emission tomography. *Epilepsia* 1995; 36: 113–121.
24. Koepp MJ, Richardson MP, Brooks DJ, Cunningham VJ, Duncan JS. Central benzodiazepine/gamma-aminobutyric acid A receptors in idiopathic generalized epilepsy: an [<sup>11</sup>C]flumazenil positron emission tomography study. *Epilepsia* 1997; 38: 1089–1097.
25. Savic I, Pauli S, Thorell JO, Blomqvist G. *In vivo* demonstration of altered benzodiazepine receptor density in patients with generalised epilepsy. *J Neurol Neurosurg Psychiatry* 1994; 57: 797–804.
26. De Marcos FA, Ghizoni E, Kobayashi E, De Marcos FA, Ghizoni E, Kobayashi E, et al. Cerebellar volume and long-term use of phenytoin. *Seizure* 2003; 12: 312–315.