

Significance of ^{123}I -MIBG scintigraphy as a pathophysiological indicator in the assessment of Parkinson's disease and related disorders: It can be a specific marker for Lewy body disease

Junichi TAKI,* Mitsuhiro YOSHITA,** Masahito YAMADA** and Norihisa TONAMI*

*Departments of *Biotracer Medicine and **Neurology and Neurobiology of Aging,
Kanazawa University Graduate School of Medical Sciences*

Recently, reliable and clear evidence for the usefulness of ^{123}I -MIBG scintigraphy in the diagnosis of Parkinson's disease (PD) has been accumulated and it has become increasingly popular as one of the most accurate means of diagnosing the disease. PD, one of the most common neurodegenerative disorders, is characterized by resting tremor, rigidity, bradykinesia or akinesia, and postural instability. The disease is characterized pathologically by distinctive neuronal inclusions called Lewy bodies in many surviving cells of dopaminergic neurons of the substantia nigra pars compacta and other specific brain regions. Furthermore Lewy body type degeneration in the cardiac plexus has been observed in PD. In PD, cardiac MIBG uptake is reduced markedly even in the early disease stages; therefore, MIBG imaging can be used as an indicator of the presence of PD rather than disease severity. Other parkinsonian syndromes such as multiple system atrophy, progressive supranuclear palsy, and corticobasal degeneration demonstrate normal cardiac MIBG uptake or only mild reduction of MIBG uptake, indicating that MIBG imaging is a powerful method to differentiate PD from other parkinsonian syndromes. Dementia with Lewy bodies (DLB) also shows severe reduction of MIBG uptake, whereas Alzheimer's disease (AD) demonstrates normal MIBG uptake, permitting differentiation of DLB from AD using MIBG scintigraphy. In pure autonomic failure, which shares similar pathological findings with PD and is thought to be associated with diffuse loss of sympathetic terminal innervation, cardiac MIBG uptake also decreases markedly. Considering all the data together, marked reduction of cardiac MIBG uptake seems to be a specific marker of Lewy body disease and thus extremely useful in the differentiation from other diseases with similar symptoms without Lewy bodies.

Key words: ^{123}I -MIBG, Parkinson's disease, Lewy body disease, multiple system atrophy, dementia with Lewy bodies

INTRODUCTION

^{123}I -MIBG scintigraphy has been developed to evaluate cardiac sympathetic innervation and function and has been used in a variety of cardiac diseases and disorders, including atherosclerotic coronary artery disease, vasospastic angina pectoris, various cardiomyopathies, and

heart failure.^{1–16} Recently the tracer has been applied to patients with autonomic dysfunction including neurodegenerative diseases such as Parkinson's disease.

Parkinson's disease (PD) is one of the most common neurodegenerative disorders and is characterized by resting tremor, rigidity, bradykinesia or akinesia, and postural instability. Its onset is usually after the age of 50 years, and there is an increasing age-related prevalence to at least age 80. Patients with PD often have concomitant autonomic dysfunctions, including gastrointestinal, sudomotor, bladder abnormalities, and orthostatic hypotension.

One decade ago, in patients with autonomic failure associated with various neurological diseases of the

Received May 11, 2004, revision accepted May 11, 2004.

For reprint contact: Junichi Taki, M.D., Ph.D., Department of Biotracer Medicine, Kanazawa University Graduate School of Medical Sciences, 13–1 Takara-machi, Kanazawa 920–8640, JAPAN.

E-mail: taki@med.kanazawa-u.ac.jp

central and peripheral nervous system, iodine-123-labeled metaiodobenzylguanidine (^{123}I -MIBG) scintigraphy demonstrated depressed myocardial uptake of the tracer, suggesting cardiac sympathetic dysfunction or denervation.^{17,18} Subsequently, it was revealed that cardiac MIBG uptake is significantly depressed in PD in a disease-specific manner among the PD related disorders.

In this review, we describe the clinical role of ^{123}I -MIBG in the differential diagnosis of parkinsonian syndromes based on the pathophysiology of PD and its related diseases and clinical experience with MIBG scintigraphy.

NOREPINEPHRINE AND ^{123}I -MIBG KINETICS IN THE SYMPATHETIC NERVE SYSTEM

In the sympathetic nerve system, the neurotransmitter, norepinephrine (noradrenaline) is synthesized from tyrosine through several enzymatic steps and stored in the storage vesicles. Nerve stimulation induces norepinephrine release by exocytosis. Receptor stimulation also regulates norepinephrine release from the nerve terminal. Angiotensin II and β -receptors accelerate norepinephrine release; on the other hand, α_2 -adrenergic receptor stimulation is thought to suppress the exocytosis.¹⁹ Most of the norepinephrine released into the neuromuscular junction undergoes reuptake via uptake 1 mechanism (sodium and energy dependent intraneuronal accumulation) and is restored in the storage vesicle or metabolized by monoamine oxidase in the cytosol (Fig. 1).

MIBG, an analogue of the adrenergic blocking agent guanethidine, has mechanisms of uptake and storage similar to those of the endogenous neurotransmitter norepinephrine, thereby permitting non-invasive assessment of the cardiac sympathetic nerve endings.^{20–26} It is actively transported into cells by uptake 1 and stored in the vesicles without catabolism by monoamine oxidase. In globally denervated canine hearts, non-neuronal MIBG uptake is observed in early images followed by complete washout. However, patients receiving heart transplants show absence of MIBG uptake in early and delayed images, implying that the non-neuronal uptake mechanism (uptake 2) is not significant in man.^{23,24,27}

In rat hearts, yohimbine, an α_2 -adrenergic receptor antagonist, induced an almost identical increase in rates of loss of hydrogen-3 noradrenaline and ^{125}I -MIBG. On the other hand, clonidine, an α_2 -agonist, induced decreases in the rates of loss of both tracers. Similar findings were observed in dogs and humans, suggesting that the rate of loss of MIBG reflects sympathetic tone.^{25,28} MIBG washout from normal human heart is around 5–15% in 3 to 4 hours, and this rate is consistent with norepinephrine turnover measured in man invasively.²⁹

These findings suggested that early MIBG uptake reflects presynaptic sympathetic system integrity and distribution, and that MIBG washout reflects the presyn-

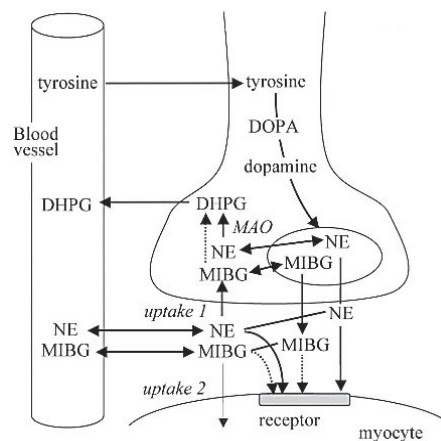


Fig. 1 Schematic presentation of norepinephrine and MIBG kinetics in sympathetic nerve ending. DHPG = dihydroxy-phenylglycol; MAO = monoamine oxidase; NE = norepinephrine

aptic functional status or tone of the sympathetic nervous system in man.

PATHOPHYSIOLOGY OF PARKINSON'S DISEASE

The etiology of Parkinson's disease is still unknown. While several mutations have been shown to be major risk factors for Parkinson's disease, the majority of patients appear to have environmental causes.³⁰

The disease is characterized pathologically by distinctive neuronal inclusions called Lewy bodies in many surviving cells of dopaminergic neurons of the substantia nigra pars compacta^{30,31} and other specific brain regions. Lewy bodies are rarely found in other degenerative diseases of the central nervous system. Lewy body formation has been considered to be a marker for neuronal degeneration because postmortem studies of patients with PD show loss of neurons in the sites of predilection for Lewy bodies. Aggregations of a misfolded protein, α -synuclein, contribute substantially to the formation of the Lewy bodies, and PD is established as one of the α -synucleinopathies from the molecular pathogenesis point of view.³²

It is generally believed that PD is primarily a motor disease resulting from loss of dopaminergic terminals in the central nervous system especially in the nigrostriatal system, with the abnormality sometimes extending outside the central nervous system and involving peripheral autonomic nerves, culminating in autonomic failure. Recently, meticulous pathological studies of the patients with PD and patients with incidental Lewy body disease revealed that the neurodegenerative process of the disease does not occur randomly but, rather, follows a predetermined sequence marked by characteristic changes in topographical extent.^{33–35} The process begins in the lower brain stem, in the dorsal motor nucleus of the vagus nerve

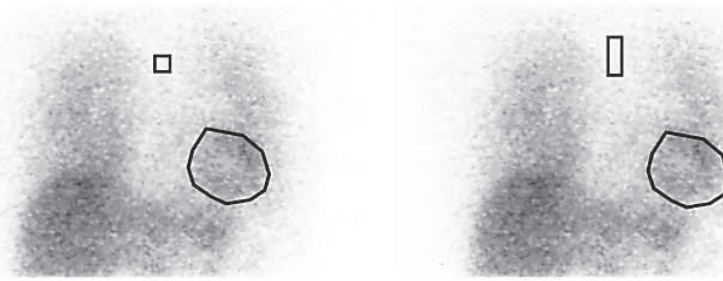

Fig. 2 Example of mediastinal and cardiac region of interest (ROI) on anterior chest MIBG images. Mediastinal ROI is recommended to be set as a narrow rectangle in the upper mediastinum to minimize the effect of bilateral lung activity.

(stage 1), and advances to the lower raphe nuclei, gigantocellular reticular nucleus, and locus ceruleus (stage 2). Then the focus of the pathological change shifts to the central nucleus of the amygdala, magnocellular nuclei of the basal forebrain, and substantia nigra (pars compacta) (stage 3). Until this pathological stage patients are usually free of symptoms. Further pathological changes involve the cerebral cortex beginning with the anteromedial temporal mesocortex (stage 4). Around this stage patients develop clinical symptoms and are diagnosed with PD clinically. Subsequently, the neocortex becomes affected in stage 5, with lesions appearing in the high-order sensory association and prefrontal area, followed by the final stage 6 with involvement of the first order sensory association areas and premotor areas, and occasionally mild changes in the primary sensory and motor fields.

In PD the entire autonomic nervous system is also affected, including the hypothalamus, parasympathetic system (Edinger-Westphal nucleus, salivary nuclei, dorsal vagal nucleus and parasympathetic ganglia) and the sympathetic system (intermediolateral nucleus of the thoracic cord and sympathetic ganglia). Furthermore, Lewy bodies are frequently found in the enteric nervous system of the alimentary tract, heart (ganglia located in the interatrial groove, nerve fibers around the coronary arteries and in the myocardium), the pelvic plexus and the adrenal medulla.³⁶

Interestingly, incidental cases of PD (considered as preclinical PD) may show involvement of both dorsal motor nucleus of the vagus nerve and enteric nervous system.^{36,37} The former is the portion where the first disease process begins in the central nervous system and the latter is innervated from the dorsal motor nucleus of the vagus nerve. This observation raises the question as to whether the disorder might originate from outside of the central nervous system, with one hypothesis being that an unknown neurotropic pathogen enters from the gastrointestinal tract into postganglionic enteric neurons and is transferred to the central nervous system along preganglionic fibers generated from the visceromotor projection cells of the vagus nerve. However we must await further research in this field in which etiology and pathophysiol-

ogy are wholly integrated and focused based on clinical and pathological pursuits.

The autonomic nerve system of the heart consists of dual sympathetic (noradrenergic) and parasympathetic (adrenergic) innervation. Postganglionic sympathetic nerves are derived from the stellate and middle cervical ganglia and innervate myocardial cells and coronary vessels. Preganglionic parasympathetic nerves derived from the dorsal vagal nucleus form synapses with postganglionic neurons close to and within the heart. Pathological studies revealed that the Lewy body-type degeneration in the cardiac plexus is observed in almost all patients with incidental Lewy body disease as well as in those with PD,³⁸ and sympathetic nerve fibers were markedly decreased in number in all the patients with PD regardless of the presence/absence of orthostatic hypotension.^{39,40} These findings suggest that cardiac sympathetic nerve might be involved already in the preclinical stage or in early disease stage, consistent with the reduction of cardiac MIBG uptake from the early stage of PD.

TECHNOLOGICAL ASPECTS OF ¹²³I-MIBG IMAGING

For the ideal imaging of ¹²³I-MIBG a medium energy collimator or specially designed low energy collimators that completely cover the 159 keV photons from ¹²³I should be used. However, changing the collimator is time consuming and limits the number of patients that can be processed in busy nuclear medicine departments, because most of the usual examinations are performed with ^{99m}Tc labeled radiopharmaceuticals. Accordingly, a considerable number of institutions perform ¹²³I-MIBG imaging using low energy collimators that are usually designed for ^{99m}Tc imaging not for ¹²³I. ¹²³I has a photopeak of 159 keV, which is higher than that of 141 keV of ^{99m}Tc, resulting in some degree of image degradation due to septal penetration of higher energy photons. For the evaluation of cardiac innervation, the heart to mediastinum ratio (H/M ratio) is used as the standard index in an anterior planar image. Since the count density of mediastinal region of interest (ROI) tends to be higher due to septal penetration

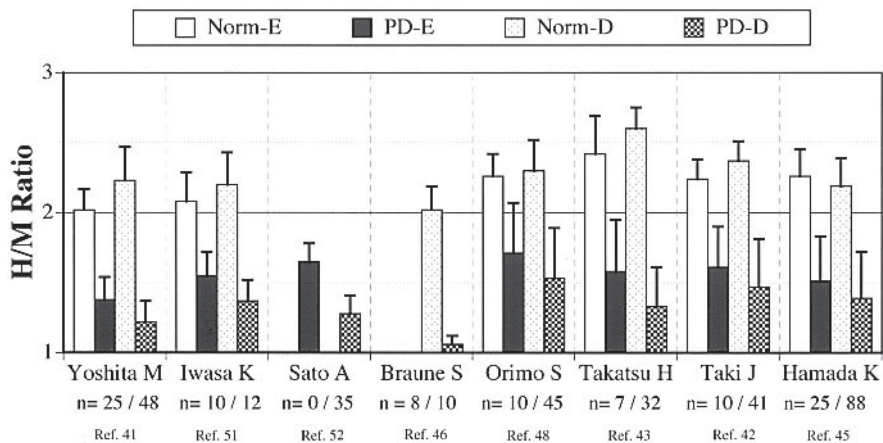


Fig. 3 H/M ratios in patients with Parkinson's disease (PD) and normal control subjects (Norm) in early (E) and delayed (D) images from various studies indicated by the first author's name. In the bottom line, numbers of patients studied were listed as n = number of normal subjects / number of PD patients. In all studies H/Ms in PD were significantly lower than those of normal subjects in both early and delayed images.

from bilateral lung activities of ^{123}I -MIBG, mediastinal ROI is recommended to be set as a narrower rectangle in the upper mediastinum to prevent underestimation of H/M ratio. ROI for the heart should be drawn manually to cover the whole left ventricle (Fig. 2). Rectangular ROI on the heart might cause erroneous H/M ratio because ROI contains lung activity when it is larger and the count density of the ROI might destabilize when ROI is smaller depending on its location on the heart. Since the degree of the underestimation of the H/M ratio depends mainly on the characteristics of the collimator (thickness of the lead septum), it is important that the normal value of the H/M ratio be determined for each gamma camera system. Approximately, with narrow rectangular upper mediastinal ROI and whole left ventricular ROI, normal H/M ratio is around 2.0–2.4 on the early image (15–20 min after MIBG injection) and 2.1–2.6 on the delayed image (3–4 hr after MIBG administration) when a low energy collimator is used, and over 2.6–3.4 when a medium energy collimator is used.

FINDINGS FROM CLINICAL STUDIES OF ^{123}I -MIBG IMAGING

Severe reduction of cardiac ^{123}I -MIBG uptake in patients with PD

Recently, an appreciable number of ^{123}I -MIBG studies focused on the evaluation of cardiac sympathetic innervation or function in patients with PD and related disorders have been performed. The severe reduction of cardiac MIBG uptake seems obviously to be specific for PD among related disorders.

In Figure 3, H/M ratios of ^{123}I -MIBG imagings were summarized in comparison with those of normal controls. All reports demonstrated apparently impaired cardiac

MIBG uptake in both early (15–20 min) and delayed images (3–4 hr). Although the MIBG uptake abnormality tends to decrease with disease progression, the abnormality is apparent in the early stage of the disease (Fig. 4), indicating that the H/M ratio cannot be used as an index of the disease severity, but rather is suitable for the diagnosis.^{41–45} The marked MIBG uptake abnormality in the early stage of the disease also implies that the cardiac denervation is an essential attribute rather than extrinsic abnormality since the cardiac sympathetic denervation has just started or is almost completed at the onset of the disease. The MIBG uptake abnormality does not seem to be related to the presence of autonomic failure either^{41–44,46,47} although two reports showed a more greatly impaired H/M ratio in PD with orthostatic hypotension.^{48,49} No relation between the duration of the disease and H/M ratio was observed in most studies,^{41–43,46,47,50,51} although a weak correlation was suggested in two studies.^{48,52} Rather, reduction of the H/M ratio seems to depend on the age at disease onset and age at the examination.⁴⁵ This observation is consistent with a PET study with 6-[^{18}F]fluorodopamine, in which diffuse cardiac loss of the tracer was found in older patients while localized loss of the tracer was observed in relatively younger ones.⁵³ Antiparkinsonian medication does not seem to affect the H/M ratio.^{41,46–48,50–52} In a study with whole body ^{123}I -MIBG imaging, the abnormality of MIBG uptake seemed to be heart selective.⁴² The high rate of oxidative deamination of norepinephrine in cardiac sympathetic nerves⁵⁴ might account for the cardioselectivity of sympathetic denervation in PD, as it has been suggested that the loss of nigrostriatal dopamine cells results in some way from oxidative or neurotoxic injury. However, this issue remains to be elucidated, because other organs' MIBG uptake in normal subjects is relatively low compared with

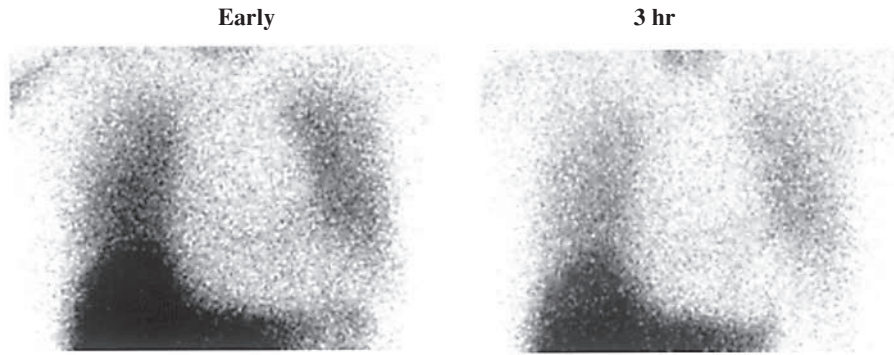


Fig. 4 MIBG images from a 70-year-old patient with Parkinson's disease in Hoehn and Yahr stage I. MIBG scintigraphy, performed at 3 months after onset of symptoms, showed marked reduction of cardiac MIBG uptake in both early and delayed images.

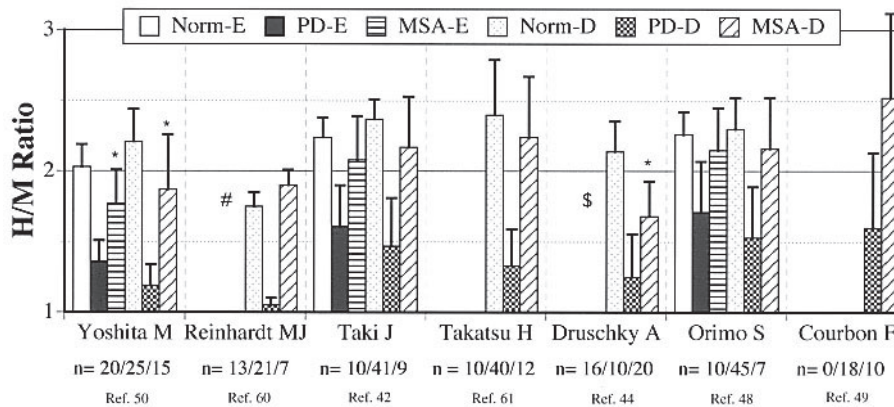


Fig. 5 H/M ratios in patients with Parkinson's disease (PD), multiple system atrophy (MSA) and normal control subjects (Norm) in early (E) and delayed (D) images from various studies indicated by the first author's name. In the bottom line, numbers of patients studied were listed as n = number of normal subjects / number of PD patients / number of MSA patients. In all studies H/Ms in PD were significantly lower than those of normal subjects in both early and delayed images and H/M ratios in MSA was significantly higher than those of PD. H/M ratios in MSA were similar to normal subjects except for 2 studies labeled with *. In the study labeled with #, the H/M ratio might have been underestimated due to large mediastinal ROI. In the study labeled with \$, rectangular cardiac ROI was used for the analysis on anterior projection image of dual isotope SPECT data with ^{99m}Tc-sestamibi.

heart, and might result in low detectability of mild sympathetic dysfunction.

Differentiation of PD from multiple system atrophy (MSA), progressive supranuclear palsy (PSP), and corticobasal degeneration (CBD)

Parkinsonism is characterized clinically as a syndrome dominated by a disorder of movement including tremor, rigidity, bradykinesia (slowness of movement), hypokinesia (reduced movement), akinesia (loss of movement) and postural abnormalities and is a feature of a number of neurodegenerative diseases, including PD, MSA, PSP, and CBD. Differential diagnosis of these diseases is important because of differences in prognosis and therapy. However, discrimination of these disorders on the basis of clinical criteria alone is sometimes difficult, especially

early in the clinical course.⁵⁵⁻⁵⁹ Pathological study revealed that the accuracy of antemortem diagnosis of PD is around 80%, with MSA, PSP and Alzheimer's disease misdiagnosed as PD most commonly.⁵⁷

MSA is clinically characterized by any combination of parkinsonism, autonomic, cerebellar, or pyramidal signs, including varying combination and degree of subtypes; striatonigral degeneration (SND), olivopontocerebellar atrophy (OPCA), and autonomic involvement (Shy-Drager syndrome). Pathologically it is characterized by marked neuronal cell loss, gliosis and glial cytoplasmic inclusions in several central nervous system sites, including the basal ganglia, pontine nuclei, inferior olives, cerebellar Purkinje cells, and intermediolateral gray columns of the spinal cord. In molecular pathogenesis, MSA has been established as an α -synucleinopathy along with PD and

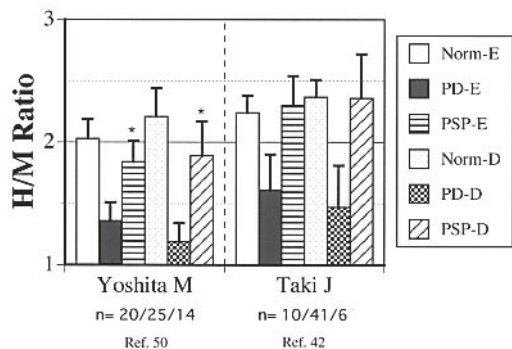


Fig. 6 H/M ratios in patients with Parkinson's disease (PD), progressive supranuclear palsy (PSP) and normal control subjects (Norm) in early (E) and delayed (D) images from 2 studies indicated by the first author's name. In the bottom line, numbers of patients studied were listed as n = number of normal subjects / number of PD patients / number of PSP patients. In both studies H/Ms in PD were significantly lower than those of normal subjects in both early and delayed images and H/M ratios in PSP were significantly higher than those of PD. H/M ratios in PSP were slightly but significantly reduced compared to normal subjects in one study labeled with *.

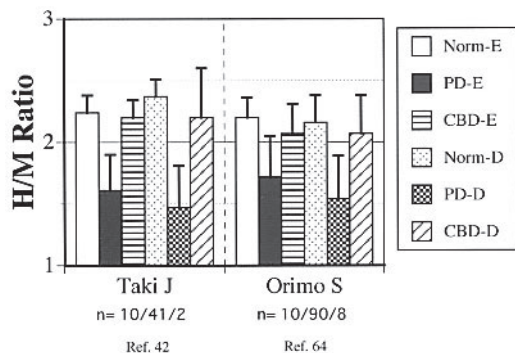


Fig. 7 H/M ratios in patients with Parkinson's disease (PD), corticobasal degeneration (CBD) and normal control subjects (Norm) in early (E) and delayed (D) images from 2 studies indicated by the first author's name. In the bottom line, numbers of patients studied were listed as n = number of normal subjects / number of PD patients / number of CBD patients. In both studies H/Ms in PD were significantly lower than those of normal subjects in both early and delayed images and H/M ratios in PSP were significantly higher than those of PD and similar to those of normal subjects.

dementia with Lewy bodies. In MSA, central and preganglionic neurons are predominantly affected, while postganglionic sympathetic neurons are usually spared. Therefore, MIBG uptake might not be impaired. PET study with ^{18}F -fluorodopamine demonstrated that a significant reduction of cardiac tracer uptake in patients with pure autonomic failure and PD with and without sympathetic neurocirculatory failure. However, the cardiac tracer uptake in MSA with and without sympathetic neurocirculatory failure was similar to that of normal controls, indicating that cardiac sympathetic denervation is not the

case in MSA.⁵³ MIBG uptake is also similar to that of normal controls or reduced but higher than in PD, revealing the significance of MIBG imaging as a discriminator between PD and MSA (Fig. 5).^{42,44,47-50,60,61} Mild reduction of MIBG in MSA in some reports might account for the mechanism of transsynaptic degeneration of postganglionic nerve.⁴⁴ Postmortem study demonstrated that postganglionic cardiac sympathetic nerve fibers (tyrosine hydroxylase immunoreactive nerve fibers) are markedly decreased in all PD (5/5) but not in all MSA (4/4), offering substantial evidence of discrepant MIBG uptake in PD and MSA.^{39,40}

PSP also should be listed as one of the most important differential diagnoses of PD. PSP is pathologically characterized by widespread neurofibrillary degeneration associated with system-bound neuronal loss and gliosis in subcortical areas, particularly affecting the subthalamic nucleus, substantia nigra, brainstem tegmentum and dentate nuclei, with no or little involvement of the cerebral cortex.⁶² Although MIBG uptake appeared normal or showed a mild reduction in PSP, the uptake was apparently higher than that of PD, demonstrating the good ability of MIBG imaging to differentiate between PD and PSP (Fig. 6).^{42,50}

CBD is one of the neurodegenerative parkinsonisms and should be carefully differentiated from PD especially in its early disease stage.⁶³ Since MIBG uptake in CBD was similar to that of normal controls, MIBG imaging could be considered a useful technique for the differentiation between PD and CBD (Fig. 7).^{42,64}

Vascular parkinsonism and essential tremor also demonstrated near normal MIBG uptake, indicating that MIBG imaging can be of great help in differentiating these conditions from PD.⁴⁸

Differentiation between dementia with Lewy bodies (DLB) and Alzheimer's disease (AD)

Dementia is an increasingly common disorder in the elderly population. AD is the most common cause of dementia. DLB is now thought to be the second most common type of degenerative dementia after AD. The main differential diagnoses of DLB are AD, vascular dementia, PD, atypical parkinsonian syndromes such as PSP, MSA, CBD and Creutzfeldt-Jacob disease.⁶⁵ The importance of accurate diagnosis of DLB lies in its pharmacological management, with good responsiveness to cholinesterase inhibitors but extreme sensitivity to the side effects of neuroleptic drugs. Clinical features and functional brain imaging with MRI have failed to clearly differentiate between AD and DLB.⁶⁶ Although DLB and PD are clinically defined syndromes, no formal clinical criteria have been established and the specificity of a clinical diagnosis of probable DLB, using consensus criteria, is generally high (>85%), whereas the sensitivity of case detection is lower and more variable.⁶⁵ Pathologically, both diseases have Lewy bodies, namely the char-

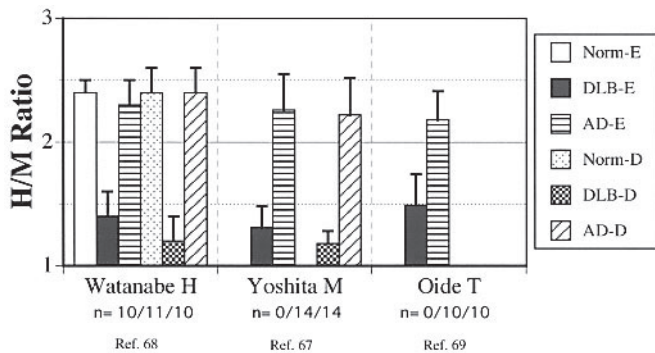


Fig. 8 H/M ratios in patients with dementia with Lewy bodies (DLB), Alzheimer's disease (AD) and normal control subjects (Norm) in early (E) and delayed (D) images from 3 studies indicated by the first author's name. In the bottom line, numbers of patients studied were listed as n = number of normal subjects / number of DLB patients / number of AD patients. In all studies H/Ms in DLB were markedly reduced in both early and delayed images, but H/M ratios in AD were significantly higher than those of PD and similar to those of normal subjects.

acteristic pathological feature of Lewy body disease, while no definite pathological criteria are available that differentiate the disorders either from each other or from PD with dementia. Predictably marked MIBG uptake reduction was also anticipated and observed in DLB.⁴² Therefore for the differentiation of AD and DLB, MIBG can be expected as a good predictor. Until now, 3 systematic studies investigating MIBG value to differentiate DLB from AD have been performed.⁶⁷⁻⁶⁹ All revealed marked cardiac MIBG uptake reduction in DLB in contrast to normal uptake in AD without substantial overlap between the two groups, indicating that MIBG scintigraphy is a powerful tool in terms of differential diagnosis of AD and DLB and might improve the sensitivity in the detection of DLB (Fig. 8). The MIBG uptake reduction does not correlate with disease duration.^{68,69}

Pure autonomic failure

Pure autonomic failure shares similar pathological findings with PD associated with Lewy bodies in the substantia nigra and locus ceruleus^{39,70} and is thought to be associated with diffuse loss of sympathetic terminal innervation.^{40,53,71,72} PET with 6-[¹⁸F]fluorodopamine as well as MIBG studies revealed the loss of cardiac tracer uptake, indicating cardiac denervation in pure autonomic failure.^{53,72}

CONCLUSIONS

Apparent reduction of cardiac ¹²³I-MIBG uptake is observed in patients with Parkinson's disease, dementia with Lewy bodies, and pure autonomic failure. These three disorders have some overlap in their clinical and neuropathological features and can be called Lewy body

disease.⁷⁰ Considering all the data together, marked cardiac MIBG uptake reduction seems to be a specific marker of Lewy body disease making it extremely useful in the differentiation from other diseases with similar symptoms without Lewy bodies. In the differential diagnosis of PD from other parkinsonian syndromes with or without autonomic failure, and in the differentiation of DLB from Alzheimer's disease in patients with dementia, ¹²³I-MIBG cardiac imaging can be used as a powerful diagnostic tool and should gain acceptance as an established examination technique in daily clinical practice.

REFERENCES

1. Taki J, Nakajima K, Bunko H, Simizu M, Muramori A, Hisada K. Whole-body distribution of iodine 123 metaiodobenzylguanidine in hypertrophic cardiomyopathy: significance of its washout from the heart. *Eur J Nucl Med* 1990; 17: 264-268.
2. Matsunari I, Bunko H, Taki J, Nakajima K, Muramori A, Kuji I, et al. Regional uptake of iodine-125-metaiodobenzylguanidine in the rat heart. *Eur J Nucl Med* 1993; 20: 1104-1107.
3. Nakajima K, Taki J, Tonami N, Hisada K. Decreased ¹²³I-MIBG uptake and increased clearance in various cardiac diseases. *Nucl Med Commun* 1994; 15: 317-323.
4. Kreiner G, Wolzt M, Fasching P, Leitha T, Edlmayer A, Korn A, et al. Myocardial m-[¹²³I]iodobenzylguanidine scintigraphy for the assessment of adrenergic cardiac innervation in patients with IDDM. Comparison with cardiovascular reflex tests and relationship to left ventricular function. *Diabetes* 1995; 44: 543-549.
5. Langer A, Freeman MR, Josse RG, Armstrong PW. Metaiodobenzylguanidine imaging in diabetes mellitus: assessment of cardiac sympathetic denervation and its relation to autonomic dysfunction and silent myocardial ischemia. *J Am Coll Cardiol* 1995; 25: 610-618.
6. Sakata K, Shirotani M, Yoshida H, Kurata C. Iodine-123 metaiodobenzylguanidine cardiac imaging to identify and localize vasospastic angina without significant coronary artery narrowing. *J Am Coll Cardiol* 1997; 30: 370-376.
7. Tamaki N, Tadamura E, Kudoh T, Hattori N, Inubushi M, Konishi J. Recent advances in nuclear cardiology in the study of coronary artery disease. *Ann Nucl Med* 1997; 11: 55-66.
8. Matsunari I, Schricke U, Bengel FM, Haase HU, Barthel P, Schmidt G, et al. Extent of cardiac sympathetic neuronal damage is determined by the area of ischemia in patients with acute coronary syndromes. *Circulation* 2000; 101: 2579-2585.
9. Momose M, Kobayashi H, Ikegami H, Matsuda N, Hachida M, Kasanuki H, et al. Regional cardiac sympathetic reinnervation in transplanted human hearts detected by ¹²³I-MIBG SPECT imaging. *Ann Nucl Med* 2000; 14: 333-337.
10. Naruse H, Arai T, Kondo T, Ohnishi M, Sakaki T, Takahashi K, et al. Relation between myocardial response to dobutamine stress and sympathetic nerve activation in patients with idiopathic dilated cardiomyopathy: a comparison of ¹²³I-MIBG scintigraphic and echocardiographic data. *Ann Nucl Med* 2000; 14: 427-432.

11. Sakata K, Yoshida H, Nawada R, Obayashi K, Tamekiyo H, Mochizuki M. Scintigraphic assessment of regional cardiac sympathetic nervous system in patients with single-vessel coronary artery disease. *Ann Nucl Med* 2000; 14: 151–158.
12. Koyama K, Inoue T, Hasegawa A, Oriuchi N, Okamoto E, Tomaru Y, et al. Alternating myocardial sympathetic neural function of athlete's heart in professional cycle racers examined with iodine-123-MIBG myocardial scintigraphy. *Ann Nucl Med* 2001; 15: 307–312.
13. Matsuo S, Nakamura Y, Matsui T, Matsumoto T, Kinoshita M. Detection of denervated but viable myocardium in cardiac sarcoidosis with I-123 MIBG and Tl-201 SPECT imaging. *Ann Nucl Med* 2001; 15: 373–375.
14. Nagamachi S, Jinnouchi S, Kurose T, Nishii R, Kawai K, Futami S, et al. Serial change in ¹²³I-MIBG myocardial scintigraphy in non-insulin-dependent diabetes mellitus. *Ann Nucl Med* 2002; 16: 33–38.
15. Narula J, Zaret BL. Epilogue: development of novel imaging techniques for ultimately superior management of congestive heart failure. *J Nucl Cardiol* 2002; 9: 81S–86S.
16. Shimizu M, Ino H, Yamaguchi M, Terai H, Hayashi K, Nakajima K, et al. Heterogeneity of cardiac sympathetic nerve activity and systolic dysfunction in patients with hypertrophic cardiomyopathy. *J Nucl Med* 2002; 43: 15–20.
17. Hakusui S, Yasuda T, Yanagi T, Tohyama J, Hasegawa Y, Koike Y, et al. A radiological analysis of heart sympathetic functions with meta-[¹²³I]iodobenzylguanidine in neurological patients with autonomic failure. *J Auton Nerv Syst* 1994; 49: 81–84.
18. Ando Y, Obayashi K, Tanaka Y, Tsuji T, Uchino M, Takahashi M, et al. Radiolabelled metaiodobenzylguanidine in assessment of autonomic dysfunction. *Lancet* 1994; 343: 984–985.
19. Francis GS. Modulation of peripheral sympathetic nerve transmission. *J Am Coll Cardiol* 1988; 12: 250–254.
20. Wieland DM, Brown LE, Rogers WL, Worthington KC, Wu JL, Clinthorne NH, et al. Myocardial imaging with a radioiodinated norepinephrine storage analog. *J Nucl Med* 1981; 22: 22–31.
21. Nakajo M, Shimabukuro K, Yoshimura H, Yonekura R, Nakabeppu Y, Tanoue P, et al. Iodine-131 metaiodobenzylguanidine intra- and extravascular accumulation in the rat heart. *J Nucl Med* 1986; 27: 84–89.
22. Tobes MC, Jaques S Jr, Wieland DM, Sisson JC. Effect of uptake-one inhibitors on the uptake of norepinephrine and metaiodobenzylguanidine. *J Nucl Med* 1985; 26: 897–907.
23. Dae MW, De Marco T, Botvinick EH, O'Connell JW, Hattner RS, Huberty JP, et al. Scintigraphic assessment of MIBG uptake in globally denervated human and canine hearts—implications for clinical studies. *J Nucl Med* 1992; 33: 1444–1450.
24. Fagret D, Wolf JE, Vanzetto G, Borrel E. Myocardial uptake of metaiodobenzylguanidine in patients with left ventricular hypertrophy secondary to valvular aortic stenosis. *J Nucl Med* 1993; 34: 57–60.
25. Sisson JC, Shapiro B, Meyers L, Mallette S, Mangner TJ, Wieland DM, et al. Metaiodobenzylguanidine to map scintigraphically the adrenergic nervous system in man. *J Nucl Med* 1987; 28: 1625–1636.
26. Manger WM, Hoffman BB. Heart imaging in the diagnosis of pheochromocytoma and assessment of catecholamine uptake. *J Nucl Med* 1983; 24: 1194–1196.
27. Glowniak JV, Turner FE, Gray LL, Palac RT, Lagunas-Solar MC, Woodward WR. Iodine-123 metaiodobenzylguanidine imaging of the heart in idiopathic congestive cardiomyopathy and cardiac transplants. *J Nucl Med* 1989; 30: 1182–1191.
28. Sisson JC, Bolgos G, Johnson J. Measuring acute changes in adrenergic nerve activity of the heart in the living animal. *Am Heart J* 1991; 121: 1119–1123.
29. Eisenhofer G, Friberg P, Rundqvist B, Quyyumi AA, Lambert G, Kaye DM, et al. Cardiac sympathetic nerve function in congestive heart failure. *Circulation* 1996; 93: 1667–1676.
30. Riess O, Kruger R, Schulz JB. Spectrum of phenotypes and genotypes in Parkinson's disease. *J Neurol* 2002; 249 Suppl 3: III/15–20.
31. Gibb WR, Lees AJ. The relevance of the Lewy body to the pathogenesis of idiopathic Parkinson's disease. *J Neurol Neurosurg Psychiatry* 1988; 51: 745–752.
32. Takahashi H, Wakabayashi K. The cellular pathology of Parkinson's disease. *Neuropathology* 2001; 21: 315–322.
33. Braak H, Del Tredici K, Bratzke H, Hamm-Clement J, Sandmann-Keil D, Rub U. Staging of the intracerebral inclusion body pathology associated with idiopathic Parkinson's disease (preclinical and clinical stages). *J Neurol* 2002; 249 Suppl 3: III/1–5.
34. Braak H, Del Tredici K, Rub U, de Vos RA, Jansen Steur EN, Braak E. Staging of brain pathology related to sporadic Parkinson's disease. *Neurobiol Aging* 2003; 24: 197–211.
35. Braak H, Rub U, Gai WP, Del Tredici K. Idiopathic Parkinson's disease: possible routes by which vulnerable neuronal types may be subject to neuroinvasion by an unknown pathogen. *J Neural Transm* 2003; 110: 517–536.
36. Wakabayashi K, Takahashi H. Neuropathology of autonomic nervous system in Parkinson's disease. *Eur Neurol* 1997; 38 Suppl 2: 2–7.
37. Wakabayashi K, Takahashi H, Ohama E, Takeda S, Ikuta F. Lewy bodies in the visceral autonomic nervous system in Parkinson's disease. *Adv Neurol* 1993; 60: 609–612.
38. Iwanaga K, Wakabayashi K, Yoshimoto M, Tomita I, Satoh H, Takashima H, et al. Lewy body-type degeneration in cardiac plexus in Parkinson's and incidental Lewy body diseases. *Neurology* 1999; 52: 1269–1271.
39. Orimo S, Ozawa E, Oka T, Nakade S, Tsuchiya K, Yoshimoto M, et al. Different histopathology accounting for a decrease in myocardial MIBG uptake in PD and MSA. *Neurology* 2001; 57: 1140–1141.
40. Orimo S, Oka T, Miura H, Tsuchiya K, Mori F, Wakabayashi K, et al. Sympathetic cardiac denervation in Parkinson's disease and pure autonomic failure but not in multiple system atrophy. *J Neurol Neurosurg Psychiatry* 2002; 73: 776–777.
41. Yoshita M, Hayashi M, Hirai S. Decreased myocardial accumulation of ¹²³I-meta-iodobenzyl guanidine in Parkinson's disease. *Nucl Med Commun* 1998; 19: 137–142.
42. Taki J, Nakajima K, Hwang EH, Matsunari I, Komai K, Yoshita M, et al. Peripheral sympathetic dysfunction in patients with Parkinson's disease without autonomic failure is heart selective and disease specific. *Eur J Nucl Med* 2000; 27: 566–573.
43. Takatsu H, Nishida H, Matsuo H, Watanabe S, Nagashima

- K, Wada H, et al. Cardiac sympathetic denervation from the early stage of Parkinson's disease: clinical and experimental studies with radiolabeled MIBG. *J Nucl Med* 2000; 41: 71–77.
44. Druschky A, Hilz MJ, Platsch G, Radespiel-Troger M, Druschky K, Kuwert T, et al. Differentiation of Parkinson's disease and multiple system atrophy in early disease stages by means of I-123-MIBG-SPECT. *J Neurol Sci* 2000; 175: 3–12.
 45. Hamada K, Hirayama M, Watanabe H, Kobayashi R, Ito H, Ieda T, et al. Onset age and severity of motor impairment are associated with reduction of myocardial ¹²³I-MIBG uptake in Parkinson's disease. *J Neurol Neurosurg Psychiatry* 2003; 74: 423–426.
 46. Braune S, Reinhardt M, Bathmann J, Krause T, Lehmann M, Lucking CH. Impaired cardiac uptake of meta-[¹²³I]iodobenzylguanidine in Parkinson's disease with autonomic failure. *Acta Neurol Scand* 1998; 97: 307–314.
 47. Braune S, Reinhardt M, Schnitzer R, Riedel A, Lucking CH. Cardiac uptake of [¹²³I]MIBG separates Parkinson's disease from multiple system atrophy. *Neurology* 1999; 53: 1020–1025.
 48. Orimo S, Ozawa E, Nakade S, Sugimoto T, Mizusawa H. (¹²³I)-metaiodobenzylguanidine myocardial scintigraphy in Parkinson's disease. *J Neurol Neurosurg Psychiatry* 1999; 67: 189–194.
 49. Courbon F, Brefel-Courbon C, Thalamas C, Alibelli MJ, Berry I, Montastruc JL, et al. Cardiac MIBG scintigraphy is a sensitive tool for detecting cardiac sympathetic denervation in Parkinson's disease. *Mov Disord* 2003; 18: 890–897.
 50. Yoshita M. Differentiation of idiopathic Parkinson's disease from striatonigral degeneration and progressive supranuclear palsy using iodine-123 meta-iodobenzylguanidine myocardial scintigraphy. *J Neurol Sci* 1998; 155: 60–67.
 51. Iwasa K, Nakajima K, Yoshikawa H, Tada A, Taki J, Takamori M. Decreased myocardial ¹²³I-MIBG uptake in Parkinson's disease. *Acta Neurol Scand* 1998; 97: 303–306.
 52. Satoh A, Serita T, Seto M, Tomita I, Satoh H, Iwanaga K, et al. Loss of ¹²³I-MIBG uptake by the heart in Parkinson's disease: assessment of cardiac sympathetic denervation and diagnostic value. *J Nucl Med* 1999; 40: 371–375.
 53. Goldstein DS, Holmes C, Li ST, Bruce S, Metman LV, Cannon RO, 3rd. Cardiac sympathetic denervation in Parkinson disease. *Ann Intern Med* 2000; 133: 338–347.
 54. Eisenhofer G, Esler MD, Meredith IT, Dart A, Cannon RO 3rd, Quyyumi AA, et al. Sympathetic nervous function in human heart as assessed by cardiac spillovers of dihydroxyphenylglycol and norepinephrine. *Circulation* 1992; 85: 1775–1785.
 55. Marsden CD. Parkinson's disease. *J Neurol Neurosurg Psychiatry* 1994; 57: 672–681.
 56. Hughes AJ, Ben-Shlomo Y, Daniel SE, Lees AJ. What features improve the accuracy of clinical diagnosis in Parkinson's disease: a clinicopathologic study. *Neurology* 1992; 42: 1142–1146.
 57. Hughes AJ, Daniel SE, Kilford L, Lees AJ. Accuracy of clinical diagnosis of idiopathic Parkinson's disease: a clinicopathological study of 100 cases. *J Neurol Neurosurg Psychiatry* 1992; 55: 181–184.
 58. Hughes AJ, Daniel SE, Blankson S, Lees AJ. A clinicopathologic study of 100 cases of Parkinson's disease. *Arch Neurol* 1993; 50: 140–148.
 59. Wenning GK, Litvan I, Jankovic J, Granata R, Mangone CA, McKee A, et al. Natural history and survival of 14 patients with corticobasal degeneration confirmed at post-mortem examination. *J Neurol Neurosurg Psychiatry* 1998; 64: 184–189.
 60. Reinhardt MJ, Jungling FD, Krause TM, Braune S. Scintigraphic differentiation between two forms of primary dysautonomia early after onset of autonomic dysfunction: value of cardiac and pulmonary iodine-123 MIBG uptake. *Eur J Nucl Med* 2000; 27: 595–600.
 61. Takatsu H, Nagashima K, Murase M, Fujiwara H, Nishida H, Matsuo H, et al. Differentiating Parkinson disease from multiple-system atrophy by measuring cardiac iodine-123 metaiodobenzylguanidine accumulation. *JAMA* 2000; 284: 44–45.
 62. Jellinger K, Riederer P, Tomonaga M. Progressive supranuclear palsy: clinico-pathological and biochemical studies. *J Neural Transm Suppl* 1980: 111–128.
 63. Wenning GK, Ebersbach G, Verny M, Chaudhuri KR, Jellinger K, McKee A, et al. Progression of falls in postmortem-confirmed parkinsonian disorders. *Mov Disord* 1999; 14: 947–950.
 64. Orimo S, Ozawa E, Nakade S, Hattori H, Tsuchiya K, Taki K, et al. [¹²³I] meta-iodobenzylguanidine myocardial scintigraphy differentiates corticobasal degeneration from Parkinson's disease. *Intern Med* 2003; 42: 127–128.
 65. McKeith I, Mintzer J, Aarsland D, Burn D, Chiu H, Cohen-Mansfield J, et al. Dementia with Lewy bodies. *Lancet Neurol* 2004; 3: 19–28.
 66. McKeith IG, Perry EK, Perry RH. Report of the second dementia with Lewy body international workshop: diagnosis and treatment. Consortium on Dementia with Lewy Bodies. *Neurology* 1999; 53: 902–905.
 67. Yoshita M, Taki J, Yamada M. A clinical role for [¹²³I]MIBG myocardial scintigraphy in the distinction between dementia of the Alzheimer's-type and dementia with Lewy bodies. *J Neurol Neurosurg Psychiatry* 2001; 71: 583–588.
 68. Watanabe H, Ieda T, Katayama T, Takeda A, Aiba I, Doyu M, et al. Cardiac (¹²³I)-meta-iodobenzylguanidine (MIBG) uptake in dementia with Lewy bodies: comparison with Alzheimer's disease. *J Neurol Neurosurg Psychiatry* 2001; 70: 781–783.
 69. Oide T, Tokuda T, Momose M, Oguchi K, Nakamura A, Ohara S, et al. Usefulness of [¹²³I]metaiodobenzylguanidine ([¹²³I]MIBG) myocardial scintigraphy in differentiating between Alzheimer's disease and dementia with Lewy bodies. *Intern Med* 2003; 42: 686–690.
 70. Hishikawa N, Hashizume Y, Yoshida M, Sobue G. Clinical and neuropathological correlates of Lewy body disease. *Acta Neuropathol (Berl)* 2003; 105: 341–350.
 71. Hirayama M, Hokusui S, Koike Y, Ito K, Kato T, Ikeda M, et al. A scintigraphical qualitative analysis of peripheral vascular sympathetic function with meta-[¹²³I]iodobenzylguanidine in neurological patients with autonomic failure. *J Auton Nerv Syst* 1995; 53: 230–234.
 72. Yoshida M, Fukumoto Y, Kuroda Y, Ohkoshi N. Sympathetic denervation of myocardium demonstrated by ¹²³I-MIBG scintigraphy in pure progressive autonomic failure. *Eur Neurol* 1997; 38: 291–296.