

Comparison of FDG-PET and IMP-SPECT in patients with dementia with Lewy bodies

Kazunari ISHII,* Kayo HOSAKA,**** Tetsuya MORI* and Etsuro MORI**

*Department of Radiology and Nuclear Medicine, Hyogo Brain and Heart Center

**Institute for Aging Brain and Cognitive Disorders, Hyogo Brain and Heart Center

***Department of Radiology, Kobe University Graduate School of Medicine

Objectives: To investigate regional differences in cerebral glucose metabolism and blood flow of dementia with Lewy bodies (DLB), we studied 7 subjects with DLB and 20 normal controls using F-18 fluorodeoxyglucose (FDG) and positron emission tomography (PET) and then examined the same 7 subjects and 20 other normal controls with I-123 iodoamphetamine (IMP) and single photon emission computed tomography (SPECT). **Methods:** The anatomically standardized images were produced with NEUROSTAT and the regional relative metabolic and perfusional values were calculated. **Results:** The mean reduction ratios of FDG uptake in the DLB group relative to the mean normal controls in the parietal lobe and occipital lobe were 0.72 and 0.83, respectively, while the corresponding mean reduction ratios of IMP uptake were 0.81 and 0.88, respectively. In the DLB group, parietal FDG uptake was significantly lower than parietal IMP uptake ($p < 0.05$), occipital FDG uptake was significantly lower than occipital IMP uptake ($p < 0.05$), and parietal IMP uptake was significantly lower than occipital IMP uptake ($p < 0.01$), but there was no difference between parietal and occipital FDG uptake. **Conclusions:** Our findings suggest that parietal metabolism and perfusion are severely affected in DLB patients, though the occipital metabolic and perfusional reduction is thought to be a feature of DLB. FDG-PET is thought to be superior to IMP-SPECT in detecting functional changes in the DLB brain.

Key words: dementia with Lewy bodies, fluorodeoxyglucose (FDG), positron emission tomography (PET), iodoamphetamine (IMP), single photon emission computed tomography (SPECT)

INTRODUCTION

DEMENTIA WITH LEWY BODIES (DLB) has been recognized as a clinical entity of primary degenerative dementia that is pathologically characterized by the presence of Lewy bodies in cortical, subcortical, and brainstem structures. An international workshop proposed criteria for clinical and pathological diagnoses of DLB (CDLBIW) in 1996.¹ FDG-PET has found reduced regional glucose metabolism in the occipital association cortex and primary visual area in patients with DLB.^{2–4} The relative hypoperfusion

in the occipital cortices has also been reported in patients with DLB.^{5,6} Involvement of the medial and lateral occipital lobes is unique to patients with DLB, and occipital hypometabolism and hypoperfusion are the features of DLB that discriminate it from Alzheimer's disease (AD). Although these findings are used for clinical diagnosis of DLB, the correspondence between FDG-PET and IMP-SPECT is not known in detail, and it is unclear whether FDG-PET is superior to IMP-SPECT. We compared FDG PET and IMP-SPECT images in the same individuals with DLB.

SUBJECTS AND METHODS

Subject

All procedures followed the clinical study guidelines of our institute, and were approved by the Institutional

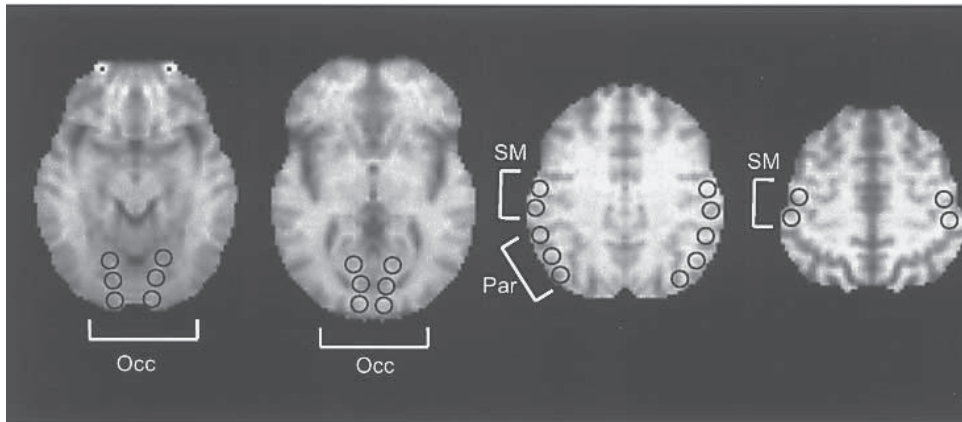
Received February 10, 2004, revision accepted April 8, 2004.

For reprint contact: Kazunari Ishii, M.D., Department of Radiology and Nuclear Medicine, Hyogo Brain and Heart Center, 520 Saisho-Ko, Himeji, Hyogo 670-0981, JAPAN.

E-mail: ishii@hiabcd.go.jp

Table 1 Clinical features of patients with dementia with Lewy bodies

cases	sex	age	MMSE	cognitive fluctuation	visual hallucinations	spontaneous parkinsonism
Case 1	F	68	19	yes	yes	no
Case 2	F	68	18	yes	yes	yes
Case 3	M	76	24	yes	no	yes
Case 4	F	77	23	yes	yes	yes
Case 5	F	78	24	yes	yes	no
Case 6	M	79	18	yes	yes	yes
Case 7	M	79	13	yes	yes	yes

**Fig. 1** ROI settings for the sensorimotor, occipital, and parietal association region on the MR template image of NEUROSTAT. Occ: occipital lobe, SM: primary sensorimotor cortices, Par: parietal lobe.**Table 2** Parietal and occipital FDG and IMP uptake ratio normalized to sensorimotor uptake in the DLB group and normal control group (NC)

	parietal	occipital
DLB-FDG	0.74 ± 0.11	0.81 ± 0.09
DLB-IMP	0.80 ± 0.11	0.96 ± 0.14
NC-FDG	1.02 ± 0.07	0.98 ± 0.06
NC-IMP	0.99 ± 0.07	1.09 ± 0.07

Review Board. Written consent was obtained after a complete description of the study from all the subjects and patients' relatives. Seven patients with DLB who agreed to undergo both FDG-PET and IMP-SPECT examinations were selected. The patients were examined comprehensively by both neurologists and psychiatrists during a short-term admission in the infirmary of our institute. The diagnosis was based on standard neuropsychological examinations, routine laboratory tests, electroencephalography, and cranial magnetic resonance (MR) imaging. Diagnosis of probable DLB was based on the CDLBIW criteria.¹ These criteria include three core features (fluctuating cognitive functions, recurrent visual hallucinations and spontaneous Parkinsonism), any two of which are necessary for a diagnosis of probable DLB. The mean (\pm standard deviation) age was 75.0 \pm 4.9 years, and the

mean MMSE score was 19.9 \pm 4.1 (Table 1). Two groups of normal control (NC) subjects were selected. Their mean ages \pm SD were 65.6 \pm 9.9 (13 women and 7 men) for the FDG-PET images and 65.6 \pm 10.4 (14 women and 6 men) for the IMP-SPECT images. Both FDG and IMP NC subjects were age-matched; however they could not be age-matched with the DLB group due to the limitation of the number of IMP-SPECT NC subjects. The control subjects showed no clinical evidence of cognitive deficits or neurological disease and were taking no short or long-term medications at the time of the scan. They had no abnormal findings on MR images. None of the subjects in this study had diabetes mellitus.

PET and SPECT procedure

The detailed PET procedure is described elsewhere.⁷ In brief, FDG-PET images were obtained using a Headtome IV scanner (Shimadzu Corp., Kyoto, Japan). All subjects had fasted for at least 4 hours before PET scanning. Subjects were studied under resting conditions with eyes closed and ears unplugged. After a transmission scan, a 12-minute emission scan was started 60 min after intravenous injection of 185–370 MBq of FDG. Data were collected in 128 \times 128 matrices. The slice thickness was 11 mm and the slice interval was 6.5 mm when the z-motion mode was used. The subject's head was placed

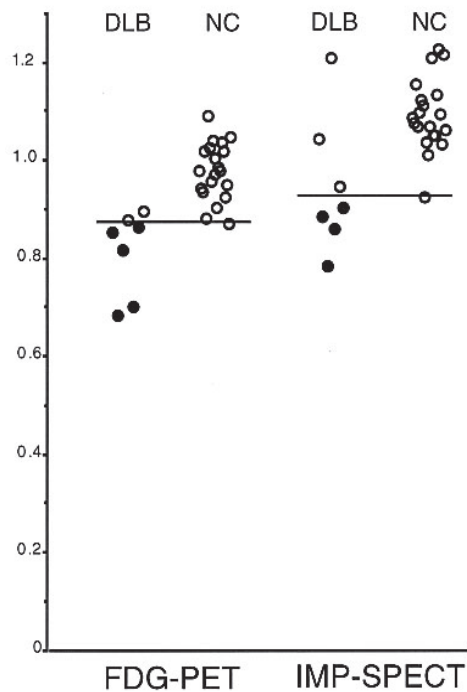


Fig. 2 Relative occipital glucose metabolism and blood flow in the DLB and normal control (NC) groups. The line indicates the minimal relative metabolic and perfusional occipital values of the NC group as the cut-off point for diagnosis of DLB. Closed circles represent subjects diagnosed as DLB by this cut-off point.

horizontally on the table of the PET scanner, and the gantry and the table of the PET scanner were adjusted according to the coordinates determined with MR imaging, so that the scans were taken parallel to the AC-PC plane.

The detailed SPECT procedure is described elsewhere.⁸ In brief, IMP-SPECT images were obtained with a rotating dual-headed gamma camera (GAMMA VIEW SPECT 2000H 20, Hitachi, Tokyo, Japan). Twenty minutes after the injection of 111 MBq of ¹²³I-IMP, the SPECT scan was started. The SPECT acquisition was done in 60 steps, with each step lasting 30 seconds. Data were collected in 64 × 64 matrices, and were reconstructed in transaxial sections parallel to the frontal pole-occipital pole plane with 8 mm thickness.

All the subjects were studied under resting conditions with eyes closed and ears unplugged with PET and/or SPECT.

Data analysis

We used NEUROSTAT (University of Michigan, Ann Arbor, MI, USA) for anatomical standardization of PET and SPECT images, because we found that NEUROSTAT was suitable for anatomical standardization of atrophied brains,^{9,10} and because brain atrophy is often seen in the DLB group. The image sets were transformed on a Power

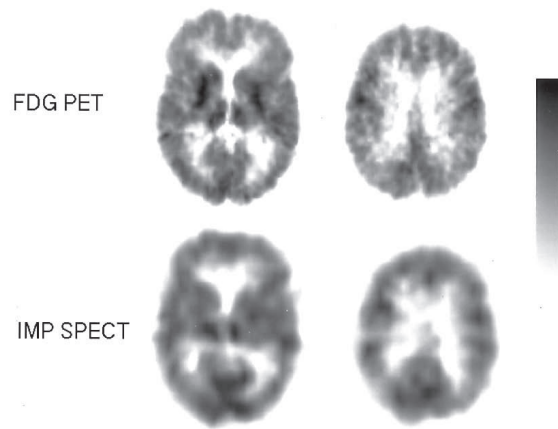


Fig. 3 FDG-PET and IMP-SPECT images of a 68-year-old female patient with DLB. Her MMSE score was 18. In the FDG-PET image, diffuse glucose hypometabolism is demonstrated except in the basal gangli and thalami, while in the IMP-SPECT image, occipital blood flow is preserved.

Mac G4 computer (Apple, CA, USA) to a standard stereotactic space using the part of the program NEUROSTAT that generates standardized three dimensional stereotactic surface projections (3D-SSP) data sets for individual subjects.

Six to twelve circular regions of interest (ROIs) (10 mm diameter) were placed on the cortical ribbon of the sensorimotor, occipital, and parietal association region on the MR template image of NEUROSTAT which is coordinated to Talairach space (Fig. 1). Then the same ROIs were transferred to the standardized FDG-PET and IMP-SPECT images, and regional relative metabolic value (FDG uptake) and regional relative perfusional value (IMP uptake) were calculated using the regional-to-sensorimotor cortical ratio. Two-way analysis of variance (ANOVA), or one-way ANOVA when an interaction existed, and post-hoc Tukey test were performed to detect group differences and regional differences between the relative metabolic and perfusional values. The criterion for statistical significance was a probability value less than 0.05. To find out the diagnostic value of occipital reduction in DLB, the minimal relative metabolic and perfusional occipital values of the NC group were used as the cut-off points.

RESULTS

The mean regional relative metabolic and perfusional values in each group are summarized in Table 2. The relative metabolism and perfusion in parietal and occipital lobe in DLB groups were significantly lower than those in the NC group. The mean reduction ratios of metabolism in the DLB group relative to the mean NC group in the parietal lobe and occipital lobe were 0.72 and 0.83,

respectively. The mean reduction ratios of perfusion in DLB group relative to the mean NC group in the parietal lobe and occipital lobe were 0.81 and 0.88, respectively. Two-way ANOVA showed a significant group difference ($F = 59.5$; $p < 0.001$) and significant group \times region interaction ($F = 5.0$; $p < 0.005$). One-way ANOVA revealed a significant difference among regional FDG uptake and IMP uptake ($F = 18.7$; $p < 0.001$). In the DLB group, parietal metabolism was significantly lower than parietal perfusion ($p < 0.05$), occipital metabolism was significantly lower than occipital perfusion ($p < 0.05$), and parietal perfusion was significantly lower than occipital perfusion ($p < 0.01$), but there was no difference between parietal and occipital metabolism. Individual relative occipital glucose metabolism in the DLB and NC groups is shown in Figure 2. By using the occipital metabolic value five (71%) of the seven cases were diagnosed as probable DLB, and four (57%) as probable DLB by using the occipital perfusional value.

Figure 3 shows representative FDG-PET and IMP-SPECT images of a 68-year-old female patient with DLB, whose MMSE score was 18. In the FDG-PET image, diffuse glucose metabolism is demonstrated except in the basal gangli and thalami, while in the IMP-SPECT image, occipital blood flow is not reduced.

DISCUSSION

We showed that FDG-PET is superior to IMP-SPECT in demonstrating the severe parietal and occipital involvement in patients with DLB. The results showed that in DLB patients, occipital reduction of metabolism is greater than that of perfusion, which indicates that FDG-PET is superior to IMP-SPECT in the diagnosis of DLB. The spatial resolution and attenuation correction of images obtained with PET are clearly much superior to those with SPECT. Moreover, in patients with AD, glucose metabolic reduction is greater than perfusional reduction in the parietotemporal area.¹¹ A similar pathophysiological state may occur in patients with DLB. That is, glucose metabolic reduction may be greater than perfusional reduction in the affected regions in DLB. Other possible reasons are that the occipital IMP uptake may be affected by spillover of the cerebellar IMP uptake and small reduction of occipital IMP uptake was not demonstrated in DLB patients.

A limitation of our study was that the subjects in the FDG-NC and IMP-NC groups were not the same. The mean ages were matched for the FDG-NC and IMP-NC groups, but not for the NC groups and DLB groups. In normal healthy people, metabolism and blood flow do not decrease with age in the parietal and occipital lobe¹²⁻¹⁴ or sensorimotor cortices.¹⁵ However, frontal metabolism^{12,14} and blood flow^{13,16} significantly decrease with increasing age. In this study there was no problem in evaluating parietal, occipital and sensorimotor glucose metabolism

and blood flow, though the NC groups and DLB groups were not age-matched.

It is noteworthy that the degree of decreased parietal FDG and IMP uptake was large in DLB brain, which has not been emphasized before. Previous reports have indicated that the metabolic and perfusional occipital reductions are the characteristics of DLB that distinguish it from AD.^{4,6,17} Although these criteria have been used in clinical practice, the metabolic and perfusional reductions are more severe in the parietal lobe than in the occipital lobe. Greater reduction in the parietal lobe was also found in this study. This may be due to the clinical diagnosis of DLB.¹ The criteria of probable DLB include both pure form and common form of diffuse Lewy body disease (DLBD).¹⁸ The subjects in this study were relatively old (mean age: 75 y.o.), most of them might have the common form of DLBD, which involves Alzheimer pathology. Another reason may be due to DLB's specific pathophysiology. In the cerebrum, Lewy bodies are found in the amygdala, temporal, frontal lobe, insula and anterior cingulate gyrus.¹⁹⁻²¹ Pathologically Lewy bodies rarely involve the occipital lobes in patients with DLB. Dopaminergic and cholinergic impairments are speculated to be the cause of the reduced metabolism and perfusion in the occipital lobe.²⁻⁴ A similar pathophysiological state may occur in the parietal lobe in the DLB brain.

In DLB, the brain stem is the most affected region, and it is interesting that brain stem metabolism is not affected in DLB brain,⁵ though the brain stem is one of the most pathologically affected regions. This phenomenon is related to parietal and occipital pathophysiology. FDG-PET and IMP-SPECT reflect functional changes rather than histological changes in the DLB brain. This discrepancy between the distribution of Lewy bodies and metabolic/perfusional reduction areas may be due to dysfunction of dopaminergic and cholinergic systems.^{2,5}

CONCLUSION

Metabolic reduction is greater than perfusional reduction in the DLB brain. Though occipital functional reduction is the hallmark of DLB, parietal function is more severely affected than occipital function in the DLB brain. FDG-PET is superior to IMP-SPECT in the diagnosis of DLB. If FDG-PET is available, it is better to perform FDG-PET study in DLB patients rather than IMP-SPECT study.

REFERENCES

1. McKeith IG, Galasko D, Kosaka K, Perry EK, Dickson DW, Hansen LA, et al. Consensus guidelines for the clinical and pathologic diagnosis of dementia with Lewy bodies (DLB): Report of the consortium on DLB international workshop. *Neurology* 1996; 47: 1113-1124.
2. Albin RL, Minoshima S, D'Amato CJ, Frey KA, Kuhl DA, Sima AAF. Fluorodeoxyglucose positron emission tomography in diffuse Lewy body disease. *Neurology* 1996; 47:

- 462–466.
3. Imamura T, Ishii K, Sasaki M, Kitagaki H, Yamaji S, Hirono N, et al. Regional cerebral glucose metabolism in dementia with Lewy bodies and Alzheimer's disease: a comparative study using positron emission tomography. *Neurosci Lett* 1997; 235: 49–52.
 4. Ishii K, Imamura T, Sasaki M, Yamaji S, Sakamoto S, Kitagaki H, et al. Regional cerebral glucose metabolism in dementia with Lewy bodies and Alzheimer's disease. *Neurology* 1998; 51: 125–130.
 5. Ishii K, Yamaji S, Kitagaki H, Imamura T, Hirono N, Mori E. Regional cerebral blood flow difference between dementia with Lewy bodies and AD. *Neurology* 1999; 53: 413–416.
 6. Colloby SJ, Fenwick JD, Williams ED, Paling SM, Lobotesis K, Ballard C, et al. A comparison of ^{99m}Tc-HMPAO SPET changes in dementia with Lewy bodies and Alzheimer's disease using statistical parametric mapping. *Eur J Nucl Med Mol Imaging* 2002; 29: 615–622.
 7. Ishii K, Sasaki M, Kitagaki H, Yamaji S, Sakamoto S, Matsuda K, et al. Reduction of cerebellar glucose metabolism in advanced Alzheimer's disease. *J Nucl Med* 1997; 38: 925–928.
 8. Ishii K, Mori E, Kitagaki H, Sakamoto S, Yamaji S, Imamura T, et al. The clinical utility of visual evaluation of scintigraphic perfusion for Alzheimer's disease using ¹²³I-IMP SPECT. *Clin Nucl Med* 1996; 21: 106–110.
 9. Ishii K, Willoch F, Minoshima S, Drzezga A, Ficarò EP, Cross DJ, et al. Statistical brain mapping of ¹⁸F-FDG PET in Alzheimer's disease: Validation of anatomic standardization for atrophied brains. *J Nucl Med* 2001; 42: 548–557.
 10. Ishii K. Clinical application of positron emission tomography for diagnosis of dementia. *Ann Nucl Med* 2002; 16: 515–525.
 11. Fukuyama H, Ogawa M, Yamauchi H, Yamaguchi S, Kimura J, Yonekura Y, et al. Altered cerebral energy metabolism in Alzheimer's disease: A PET study. *J Nucl Med* 1994; 35: 1–6.
 12. Loessner A, Alavi A, Lewandrowski K-U, Mozley D, Souder E, Gur RE. Regional cerebral function determined by FDG-PET in healthy volunteers: Normal patterns and changes with age. *J Nucl Med* 1995; 36: 1141–1149.
 13. Bentourkia M, Bol A, Ivanoiu A, Labar D, Sibomana M, Coppens A, et al. Comparison of regional cerebral blood flow and glucose metabolism in the normal brain: effect of aging. *J Neurol Sci* 2000; 181: 19–28.
 14. Moeller JR, Ishikawa T, Dhawan V, Spetsieris P, Mandel F, Alexander GE, et al. The metabolic topography of normal aging. *J Cereb Blood Flow Metab* 1996; 16: 385–398.
 15. Kawachi T, Ishii K, Sakamoto S, Matsui M, Mori T, Sasaki M. Gender differences in cerebral glucose metabolism: a PET study. *J Neurol Sci* 2002; 199: 79–83.
 16. Marchal G, Rioux P, Petit-Taboue MC, Sette G, Traverre JM, Le Poec C, et al. Regional cerebral oxygen consumption, blood flow, and blood volume in healthy human aging. *Arch Neurol* 1992; 49: 1013–1020.
 17. Lobotesis K, Fenwick JD, Phipps A, Ryman A, Swann A, Ballard C, et al. Occipital hypoperfusion on SPECT in dementia with Lewy bodies but not AD. *Neurology* 2001; 56: 643–649.
 18. Kosaka K. Diffuse Lewy body disease. *Neuropathology* 2000; 20 Suppl: S73–S78.
 19. Kosaka K, Yoshimura M, Ikeda K, Budka H. Diffuse type of Lewy body disease: progressive dementia with abundant cortical Lewy bodies and senile changes of varying degree—a new disease? *Clin Neuropathol* 1984; 3: 185–192.
 20. Dickson DW, Crystal H, Mattiace LA, Kress Y, Schwagerl A, Ksiezak-Reding H, et al. Diffuse Lewy body disease: light and electron microscopic immunocytochemistry of senile plaques. *Acta Neuropathol* 1989; 78: 572–584.
 21. Gibb WR, Luthert PJ, Janota I, Lantos PL. Cortical Lewy body dementia: clinical features and classification. *J Neurol Neurosurg Psychiatry* 1989; 52: 185–192.