Annals of Nuclear Medicine Vol. 17, No. 7, 613–617, 2003

The role of thallium-201 whole body scan with pelvic SPECT in patients with uterine cervical cancer treated by radiation therapy: a preliminary report

Ji-An LIANG,* Chia-Hung KAO,** Shang-Wen CHEN,*
Shih-Neng YANG* and Shung-Shung SUN**

*Department of Radiation Therapy and Oncology and **Department of Nuclear Medicine, China Medical University Hospital, Taichung, Taiwan

Evaluation of tumor extent before treatment and its response to therapy is important. The aim of this report is to assess the usefulness with thallium-201 (Tl-201) imaging study including whole body scan and pelvic single photon emission computed tomography (SPECT) in patients with uterine cervical cancers treated by radiation therapy. Before irradiation, eleven patients received detailed physical examination and Tl-201 imaging studies. A 4-score grading system was set for evaluation. The interval between Tl-201 imaging follow-up and completion of radiotherapy is one to four months, and its findings were compared with those from CT scan and clinical evidence. Before radiation, left supraclavicular and paraaortic lymphadenopathy was identified in one patient from whole body scan. Accumulation of Tl-201 uptake is observed from pelvic SPECT in all patients. It seems that patients with more tumor bulk had more intense uptake, except for one case with history of suspected pelvic inflammatory disease (PID). After radiotherapy, complete or partial regression is observed. For 6 patients with complete regression (score = 0), no evidence of recurrence is confirmed by follow-up examinations. For three patients with little residual uptake (score = 1), one is suspected with residual density and she is under close follow-up, the other two patients seem due to uterine myoma or short latency. These three patients received another Tl-201 scan 6 months after irradiation completion and the score became zero. One patient with residual intense uptake (score = 2) suffered from relapse in the pelvis and abdomen. This preliminary report indicates that Tl-201 whole body scan and pelvic SPECT has potential in the assessment of response to radiotherapy in patients with uterine cervical cancers. However, further studies including more cases and longer follow-up are needed.

Key words: cervical cancer, thallium-201, single photon emission tomography, radiation therapy

INTRODUCTION

RADIOTHERAPY remains the important role in the treatment of uterine cervical cancer. Factors that affect prognosis include tumor stage, volume of the primary mass, histologic grade and status of anemia.[1,2] Currently the staging system of the International Federation of Gynecology and Obstetrics (FIGO) is well accepted for its convenience. Though FIGO has prohibited the use of CT scan and MRI, etc. However, the anatomic information gained with CT scan and MRI can aid in the treatment and follow-up.[3,4]

On the other hand, whole body functional imaging can use metabolic data to show the location, size and aggressiveness of the tumor. In addition, distant metastatic lesions beyond the pelvis can be discovered. Single photon emission computed tomography (SPECT) imaging with thallium-201 (Tl-201) is valid in the evaluation of several malignancies.[5,6]

In this preliminary article, we report the results of application of Tl-201 whole body scan with pelvic SPECT

Received February 28, 2003, revision accepted July 7, 2003.
For reprint contact: Ji-An Liang, M.D., Department of Radiation Therapy and Oncology, China Medical University Hospital, No. 2, Yuh-Der Road, Taichung 404, TAIWAN.
E-mail: hope.jal@msa.hinet.net.

in a group of the patients with uterine cervical cancers who had received radiotherapy. Clinical information and findings of CT scans are applied for comparison.

MATERIALS AND METHODS

Patients

From December 2001 to April 2002, eleven patients with uterine cervical cancer (age: 42–83 years; median: 58 years) were enrolled in this study. Histology of biopsy specimens confirmed all of squamous cell carcinoma. Patients were initially evaluated with physical and pelvic examinations by gynecologist and radiation oncologist for staging (FIGO IB: 2, IIA: 3, IIB: 3, IIIB: 2, IVB: 1). The routine work-up consisted of blood counts, chemistry profile, serum squamous cell carcinoma (SCC) antigen level, chest X-ray, abdominal-pelvic CT scan and Tl-201 whole body scan with pelvic SPECT. The maximal dimension of the enhanced tumor volume was measured from the CT scans.

External beam irradiation (EBRT)

The radiation strategy consisted of external beam irradiation (EBRT), followed by high dose rate intracavitary brachytherapy (HDRICB). Initially, the whole pelvis was treated via AP/PA two portals or box fields for 45 Gy/25 Fr/5 weeks. For patients with FIGO staging IIB to IIIB, additional radiation boost to parametrium with central shielding is prescribed. After the completion of whole pelvis EBRT, HDRICB was performed using Ir-192 remote afterloading technique for 3 to 4 times with dose of 5–6 Gy to point A/each fraction at 1-week intervals. Total cumulative point A dose ranged from 60 Gy to 70 Gy. Concurrent chemotherapy with weekly Cisplatin, 50 mg/m^2, was prescribed in 8 patients.

CT scan

After radiation, all patients received regular follow-up including physical and pelvic examinations. The latency between second Tl-201 imaging and the completion of radiotherapy is one to four months. Ten patients also received CT scan again for comparison.

Tl-201 whole body scan and pelvic SPECT

Tl-201 whole body scan and pelvic SPECT were performed with a vertex dual-head gamma camera (ADAC, Milphas, CA) equipped with low-energy, high-resolution collimators on 2–3-hour after 2–3 mCi (74–111 MBq) Tl-201 was injected intravenously. Acquisition of SPECT images was based on 360° noncircular rotation with 7° step angles, 60 sec per frame, 64 × 64 × 64 matrix and zoom factor of 1.85. Reconstruction was performed with Butterworth filter, order 5, cutoff 0.35, one-pixel images, obtained in the sagittal, coronal and transverse planes. Accumulation of Tl-201 in the suspicious lesions was interpreted to give a score of 0 to 3 (Fig. 1). Significant higher Tl-201 uptake than in the surrounding normal soft tissue was given a score of 3. A score of 2 was given to areas with higher Tl-201 uptake, and Tl-201 uptake equal to the surrounding normal soft tissues was given a score of 1. Total absence of Tl-201 uptake was given a score of 0. Scores 3 and 2 were considered as positive findings and scores 1 and 0 were considered as negative findings. The SPECT image was introduced in all patients to avoid false-positive effect by physiological uptake in the uterus, bladder or alimentary tract. Interpretation was performed by the agreement of at least 2 or 3 experienced nuclear medicine physicians who were blinded to the other clinical data.

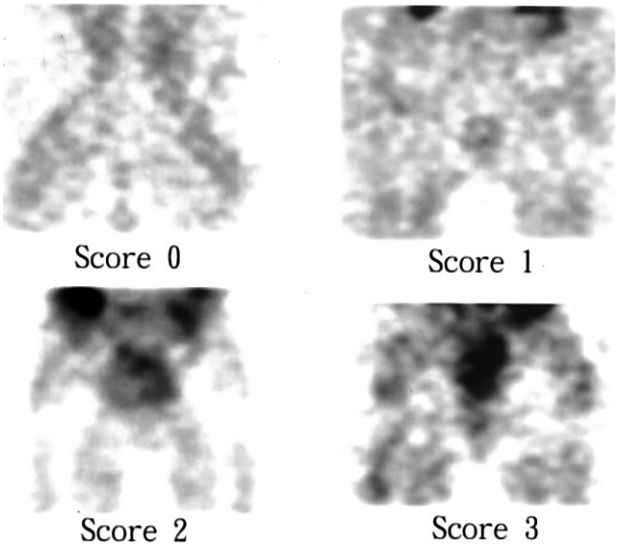

Fig. 1 The 4-score grading system of Tl-201 uptake.

RESULTS

Results of individual patient are summarized in Table 1. The median length of follow-up is 15 months. Before radiation, the size of primary tumor estimated by CT scan ranged from 2 to 6 cm, which is not so coordinated with FIGO staging. The patient with stage IVB was found to have multiple pelvic and paraaortic lymphadenopathy. SCC marker increased in 8 cases.

Ten patients were found to have positive finding by Tl-201 pelvic SPECT with scores ranged from 2 to 3 except for one case (No. 3, score = 1) whose tumor size is 3 cm as measured by CT scan. It seems that patients with small tumor burden (diameter not larger than 3 cm) had lower score, ranged from 1 to 2. However, one patient (No. 2) with small tumor has a high score of 3. Beyond the pelvis, left supraclavicular and paraaortic lesions were clearly identified in one case (No. 11, Fig. 2).

Complete or partial regression of Tl-201 uptake after radiation is observed. For 6 patients with score of 0, no evidence of recurrence is confirmed by follow-up examinations. For three patients with score of 1, one of them is

Table 1 Patient characteristics and follow-up

Case No.	Age (years)	FIGO stage	Pre-RT			RT Dose (Gy)	Latency (month)	Post-RT			
			Tl-201 SPECT score	Tumor size by CT scan	SCC			Tl-201 SPECT score	SCC	CT scan finding	Follow-up (months/status)
1	70	IB	2	3.5 cm	2.33*	68	2	0	1.58*	Well response	17m/NER
2	77	IB	3	2 cm	5.11*	65	2	2	0.53	Patient refuse	17m/NER
3	66	IIA	1	3 cm	1.19	69	2	0	0.45	Well response	17m/NER
4	47	IIA	3	6 cm	1.25	65	4	0	0.58	Well response	16m/NER
5	54	IIA	2	3 cm	0.47	69	2	1#	1.17	Well response	15m/NER
6	53	IIB	2	3 cm	3.47*	69	1	0	0.18	Well response	15m/NER
7	58	IIB	2	3 cm	2.07*	66	1	1#	1.22	Well response	14m/NER
8	51	IIB	2	3 cm	10.07*	69	2	1#	2.54*	Residual density	14m/NER
9	42	IIIB	3	6 cm	11.55*	70	1	0	0.86	Well response	17m/NER
10	58	IIIB	2	5 cm	45.59*	69	2	0	0.37	Well response	15m/NER
11	83	IVB	3	4 cm	16.64*	60	4	2	10.66*	Multiple lesions	8m/DWD

*Cut-off level of SCC: 1.50

#Case 5, 7, 8 received third Tl-201 scan 6 months after radiotherapy completion and the score became 0.

NER: no evidence of recurrence, DWD: died with disease

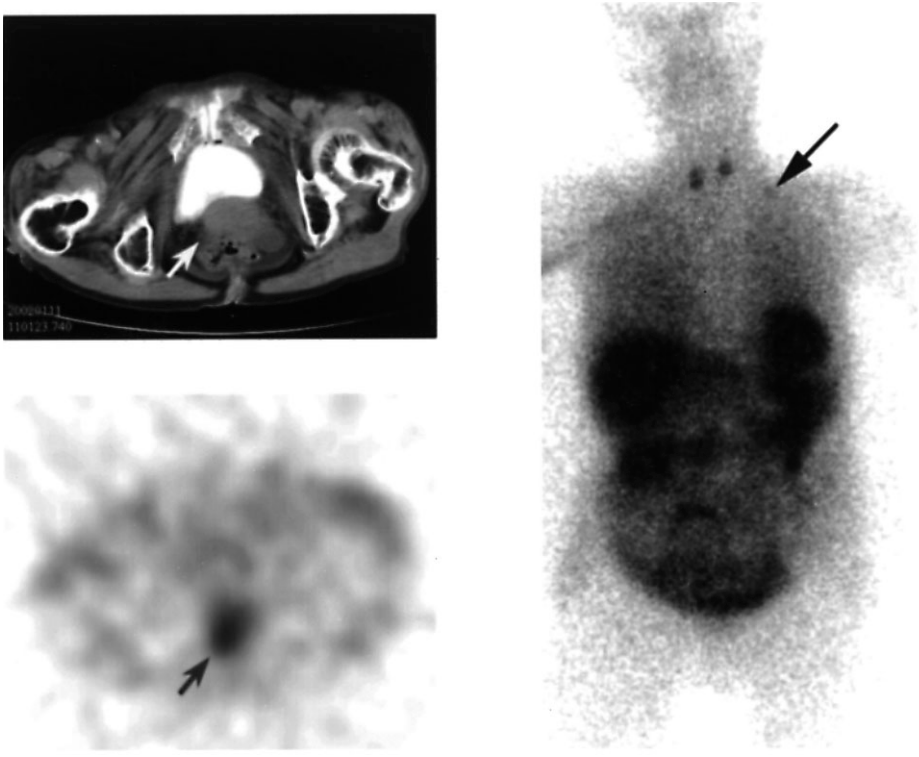

Fig. 2 A case of cervical carcinoma defined by CT scan and high uptake from Tl-201 pelvic SPECT presenting with a left supraclavicular metastatic lymph node (*arrows*).

suspected with residual density by CT scan and is under close follow-up. The other two patients seem due to uterine myoma (No. 5) or short latency (No. 7). These three patients received another Tl-201 scan 6 months after the completion of irradiation and the score became zero. The patient (No. 11) with multiple distant metastatic lesions, despite the early well response to palliative radiotherapy, suffered from relapse in the pelvis and abdomen (4 month latency, score = 2) and expired 6 months after treatment. One (No. 2) with the small mass and high accumulation of Tl-201 still remains with high uptake after RT. She refused further CT scan, but physical examination didn't show abnormality. Tracking her history, she didn't remove her insertion of intrauterine device and was suffered from low abdominal pain for long time.

DISCUSSION

Clinical stage and size of tumor are critical factors in therapy efficacy for patients with uterine cervical cancers. Early diagnosis and accurate identification of recurrent tumor after radiotherapy are essential for proper management. Death of cells after radiation is linked with the mechanism of reproductive death or apoptosis.[7] Unlike surgical excision, malignant tumor received radiotherapy doesn't disappear abruptly, but just in a much slower manner which is influenced by the four R's: repair, regeneration, redistribution and reoxygenation.[8] Anatomical imaging such as CT scan and MRI are nowadays considered as the modality of choice for surveillance in the treatment of cervical cancer. However, tumor necrosis, tissue fibrosis and inflammatory reaction may be within the tumor and interfere with the interpretation.[9] Besides, distant metastases may clearly affect prognosis, which cannot be identified by localized image modalities.

Tl-201 scan is a functional imaging method that depends on metabolic alternation. The primary mechanism of Tl-201 uptake is thought to link to the Na-K-ATPase pump in the cell membrane.[10] Because of the physical and biological similarity of thallium and potassium,[11] tumor cells with high Na-K-ATPase activity can collect Tl-201 and potassium ions into high concentration. Radiotherapy or chemotherapy will affect the activity of Na-K-ATPase on tumor cells, thus decrease the uptake of Tl-201.[12] In a same manner, areas of necrosis do not accumulate Tl-201 due to nonfunctioning of the ATPase cell membrane pump.[13] This prevents active transport of Tl-201 into areas of necrosis. Thus, Tl-201 uptake appears to reflect the viability of the metabolic activity of the tumor. Therefore, Tl-201 SPECT is considered to have the advantage of differentiation between viable and nonviable parts.

Recently, positron emission tomography (PET) with 18-fluoro-2-deoxyglucose (FDG) proved its role in the treatment of uterine cervical cancer.[14,15] However, there are many economic and practical problems associated with its widely application. Tl-201 whole body scan with SPECT, as a potential tumor-imaging agent, is more available than FDG-PET in some situations considering the cost-benefit effect. Both of them will show the whole body image instead of local image modalities. Pelvic abnormalities may be more easily imaged by Tl-201 SPECT without interference by excreted FDG in the urine that may be problematic in some cases.[16] However, evaluation of Tl-201 uptake may be limited by smaller lesion in relation to the resolution of the camera and partial-volume effects. Significant scatter effects from physiologic but normal Tl-201 uptake of the GI tract may disturb the evaluation. Inflammed tissue with much blood flow will also decrease the specificity of Tl-201 SPECT. In addition, determining the precise location and the relationship between the primary tumor or metastatic lesions and the surrounding structures was difficult using Tl-201 imaging alone. Therefore, it is advised to use a combination of conventional anatomic imaging and Tl-201 whole body scan with pelvic SPECT. The use of serum SCC marker was shown to be valid for assessing radiation response,[17] especially when it combined with image findings to localize the site of the disease.

It is undefined for the optimal timing of post-irradiation Tl-201 scintigraphy. The time interval more than two months might be suggested to avoid false-positive effect lead by slow regression or inflammation process of cervical tumor according to our data.

In this preliminary report, we have first applied Tl-201 whole body scan with SPECT in radiotherapy of uterine cervical cancer. It appears to be promising in evaluating tumor viability and distant metastatic lesions. However, further studies including more cases and longer follow-up are needed

REFERENCES

1. Perez CA, Grigsby PW, Chao KS, et al. Tumor size, irradiation dose, and long-term outcome of carcinoma of uterine cervix. *Int J Radiat Oncol Biol Phys* 1998; 41: 307–317.
2. Kapp DS, Fischer D, Gutierrez E, et al. Pretreatment prognostic factors in carcinoma of the uterine cervix: A multivariable analysis of the effect of age, stage, histology and blood counts on survival. *Int J Radiat Oncol Biol Phys* 1983; 9: 445–455.
3. Pannu HK, Corl FM, Fishman EK. CT evaluation of cervical cancer: spectrum of disease. *Radiographics* 2001; 21: 1155–1168.
4. Wagenaar HC, Trimbos JB, Postema S, et al. Tumor diameter and volume assessed by magnetic resonance imaging in the prediction of outcome for invasive cervical cancer. *Gynecol Oncol* 2001; 82: 474–482.
5. Togawa T, Yui N, Kinoshita F, et al. Thallium-201 single-photon emission tomography in the treatment follow-up of nasopharyngeal carcinoma. *Eur J Nucl Med* 1997; 24: 305–311.
6. Sun SS, Shih CS, Hsu NY, et al. Detection of esophageal carcinoma using single-photon emission computed tomography of thallium-201: a preliminary report. *Anticancer Res* 2001; 21 (6A): 4109–4112.
7. Dewey WC, Ling CC, Meyn RE. Radiation induced apoptosis: Relevance to radiotherapy. *Int J Radiat Oncol Biol Phys* 1995; 33: 781–796.
8. Withers HR. The 4R's of radiotherapy. In: *Advances in Radiation Biology, vol. 5*, Lett JT, Alder H (eds), New York; Academic, 1975: 241.
9. Ebner F, Kressel HY, Mintz MC, et al. Tumor recurrence versus fibrosis in the female pelvis: differentiation with MR imaging at 1.5T. *Radiology* 1988; 166: 333–340.
10. Britten JS, Blank M. Thallium activation of the (Na^+, K^+) activated ATPase of rabbit kidney. *Biochem Biophys Acta* 1968; 15: 160–166.
11. Waxman AD. Thallium-201 in nuclear oncology. In: *Nuclear Medicine Annual 1991*, Freeman LM (ed), New York; Raven Press, 1991: 193–207.

12. Lin J, Leung WT, Ho SKW, et al. Quantitative evaluation of thallium-201 uptake in predicting chemotherapeutic response of osteosarcoma. *Eur J Nucl Med* 1995; 22: 553–555.
13. Elgazzar AH, Fernandes-Ulloa M, Silberstein EB. Tl-201 as a tumour-localizing agent: current status and future considerations. *Nucl Med Commun* 1993; 14: 96–103.
14. Grigsby PW, Siegel BA, Dehdashti F. Lymph node staging by positron emission tomography in patients with carcinoma of the cervix. *J Clin Oncol* 2001; 19: 3745–3749.
15. Sun SS, Chen TC, Yen RF, et al. Value of whole body ^{18}F-fluoro-2-deoxyglucose positron emission tomography in the evaluation of recurrent cervical cancer. *Anticancer Res* 2001; 21: 2957–2961.
16. Sugawara Y, Eisbruch A, Kosuda S, et al. Evaluation of FDG PET in patients with cervical cancer. *J Nucl Med* 1999; 40: 1125–1131.
17. Pras E, Willemse PH, Caneinus AA, et al. Serum squamous cell carcinoma antigen and CYFRA 21-1 in cervical cancer treatment. *Int J Radiat Oncol Biol Phys* 2002; 52: 23–32.