

## Accumulation of $^{67}\text{Ga}$ citrate in early pregnancy

Hiromasa KUROSAKI, Yoshihiro SAITO, Miho KAWASHIMA, Takeshi EBARA,  
Michitaka YAMAKAWA and Norio MITSUHASHI

*Department of Radiology and Radiation Oncology, Gunma University School of Medicine*

A 26-year-old pregnant woman complained of chest pain and dyspnea and was diagnosed with malignant lymphoma of the mediastinum. To determine the stage of malignant lymphoma, tumor scintigraphy with  $^{67}\text{Ga}$  citrate was performed.  $^{67}\text{Ga}$  scintigraphy revealed an abnormal accumulation in the center of the pelvic cavity. An artificial abortion was performed, and the early pregnancy obtained from the abortion showed a prominent uptake of  $^{67}\text{Ga}$  citrate *ex vivo*.  $^{67}\text{Ga}$  citrate re-examination, which was performed immediately after the abortion, showed no abnormal accumulation in the pelvic cavity. To our knowledge, this is the first medical report on an aborted tissue investigated *ex vivo* to determine whether it demonstrated increased uptake of  $^{67}\text{Ga}$  citrate.

**Key words:** gallium scintigraphy, pregnancy, placenta, fetal membrane, early pregnancy

### INTRODUCTION

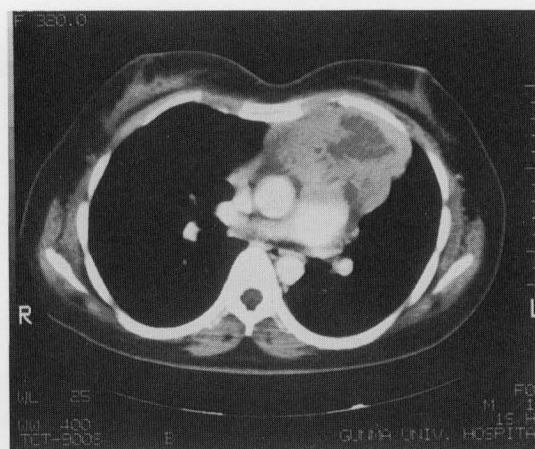
$^{67}\text{Ga}$  citrate scintigraphy is one of the radionuclide type of examinations.  $^{67}\text{Ga}$  citrate accumulates in the foci of inflammations and tumors, but only a few reports have shown an increased uptake of  $^{67}\text{Ga}$  citrate in the placenta. We report here on a case of a pregnant patient with malignant lymphoma, whose aborted fetal tissue showed an increased uptake of  $^{67}\text{Ga}$  citrate.

### CASE REPORT

A 26-year-old woman visited her family doctor complaining of chest pain and dyspnea. There was an abnormal shadow on the mediastinum in a chest X-ray. Computed tomography of the chest revealed a tumor-like shadow, which seemed to infiltrate into the chest wall (Fig. 1).

An operation was performed, but the tumor was unresectable because it had infiltrated into its immediate surroundings. Pathological examination of the open biopsy specimen indicated malignant lymphoma (diffuse

large B cell type). The patient was admitted to our department for radiotherapy and was found to be 6 weeks pregnant. Informed consent for artificial abortion and further radiological examinations was obtained.  $^{67}\text{Ga}$  citrate (74 MBq) was administered after she had received radiation therapy with a total dose of 14 Gy to the mediastinum mass. At the point when she received  $^{67}\text{Ga}$  citrate, she was seven weeks pregnant.  $^{67}\text{Ga}$  citrate scintigraphy revealed an abnormal accumulation in the center of the pelvic cavity, but not in the mediastinal mass (Fig.

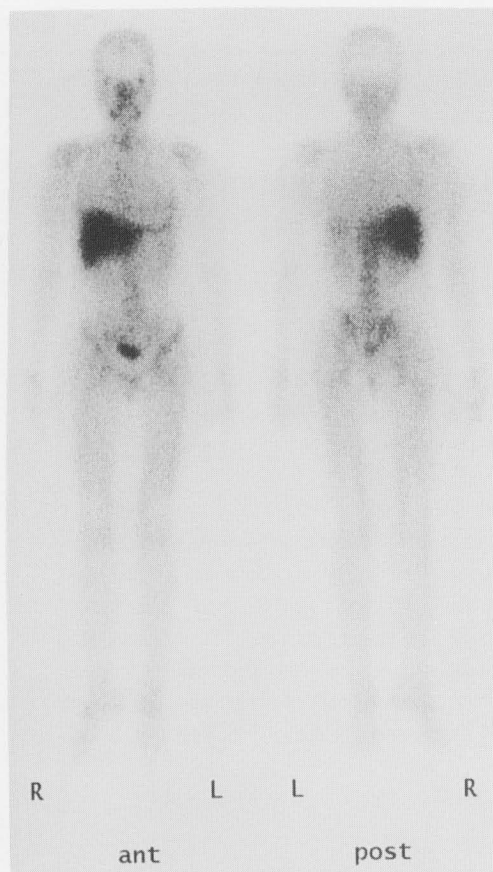


**Fig. 1** Findings of chest enhanced CT: It demonstrates a huge anterior mediastinal mass which is enhanced heterogeneously.

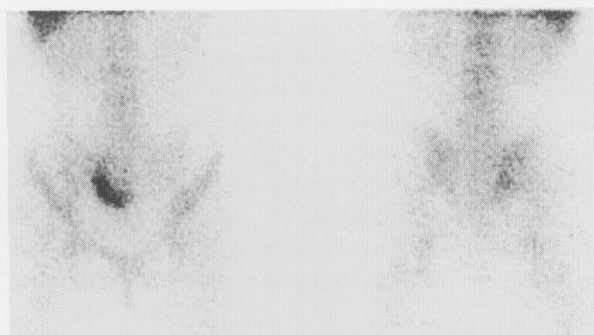
Received January 11, 2001, revision accepted April 2, 2001.

For reprint contact: Hiromasa Kurosaki, M.D., Department of Radiology and Radiation Oncology, Gunma University School of Medicine, 3-39-22 Showa-machi, Maebashi, Gunma 371-8511, JAPAN.

E-mail: kuro@coo.net



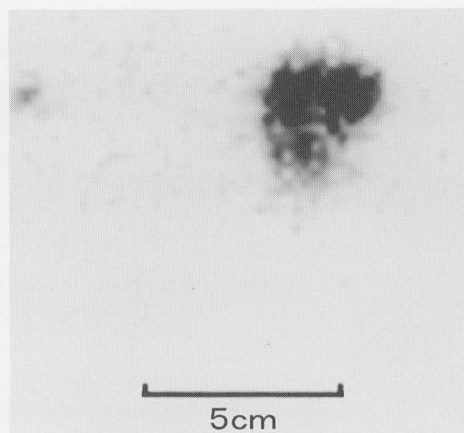
A



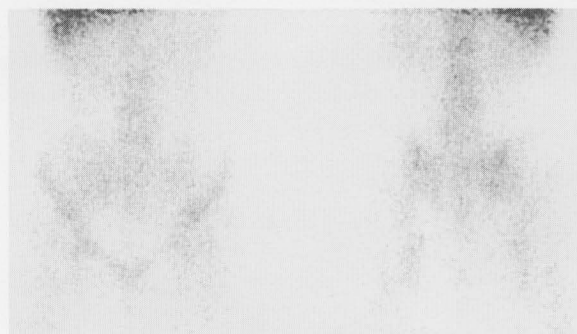
B

**Fig. 2** A & B: Findings of  $^{67}\text{Ga}$ -citrate scintigraphy:  $^{67}\text{Ga}$  citrate scintigraphy was evaluated 4 days after injection. It reveals an abnormal accumulation in the center of the pelvic cavity although an abnormal uptake in the mediastinum has already been disappeared by radiation therapy with a total dose of 14 Gy.

2). Artificial abortion was performed 5 days after  $^{67}\text{Ga}$  citrate injection. The aborted tissue showed a prominent uptake of  $^{67}\text{Ga}$  citrate in *ex vivo* imaging (Fig. 3). In histological research there were no records on infiltration of tumor cells into fetal tissue. The scanning, which was performed immediately after the abortion, did not show the abnormal accumulation in the pelvic cavity (Fig. 4). The mediastinal tumor disappeared completely after ra-



**Fig. 3** Scintigraphy of the aborted placenta *ex vivo*: Strong radioactivity is demonstrated in the aborted placenta.



**Fig. 4**  $^{67}\text{Ga}$ -citrate scintigraphy immediately after artificial abortion: There is no abnormal accumulation in the pelvic cavity.

diation therapy with a total dose of 30 Gy, and the patient is now receiving chemotherapy and is in remission.

## DISCUSSION

It has often been reported that there is an increased uptake of  $^{67}\text{Ga}$  citrate in the mammary glands during the lactation period.<sup>1</sup> There was, however, no report regarding an accumulation of  $^{67}\text{Ga}$  citrate in the placenta, except for 2 reports in English medical literature.<sup>2,3</sup> To our knowledge, this is the first report where the aborted tissue was investigated *ex vivo*.

Mahon et al. reported that the placenta showed a higher uptake rate than other organs in rabbits.<sup>4</sup> According to their report,  $^{113\text{m}}\text{In}$  is only one radioligand which indicates a higher uptake rate than  $^{67}\text{Ga}$ , and the uptake of radioligand in the placenta is more evident than that in the fetus.

It is uncertain at which stage of early pregnancy  $^{67}\text{Ga}$  citrate accumulates. Strong uptake was found in the early pregnancy at the 7th week in our case, and in the placenta at the 19 week stage in Newman's report.<sup>3</sup> Tyndall et al. reported a marked concentration of  $^{67}\text{Ga}$  in uterus in 5-day

pregnant rabbits.<sup>5</sup> In 7- to 8-day pregnant rabbits, <sup>67</sup>Ga concentrated in blastocysts and sites of implantation. As gestation progressed, <sup>67</sup>Ga increasingly concentrated in placental and mammary tissue. To our knowledge, it is uncertain where <sup>67</sup>Ga citrate will concentrate in early pregnancy; the villi, chorion, deciduas, fetal membrane, or fetus.

We always consider the possibility of accumulation in the placenta when we perform <sup>67</sup>Ga citrate scintigraphy in women of childbearing age. It is important to take anamnesis when <sup>67</sup>Ga citrate examination is planned, because the procedure may affect the normal development of the fetus, but in this case artificial abortion was planned before the <sup>67</sup>Ga citrate examination was performed.

#### ACKNOWLEDGMENT

We gratefully acknowledge the help of Mr. Hidenori Ohtake, Division of Radiology, Gunma University School of Medicine,

and thank Dr. Kazuko Abe, Department of Obstetrics and Gynecology, Tatebayashi Kousei Hospital.

#### REFERENCES

1. Larson SM, Schall GL. Gallium-67 concentration in human breast. *JAMA* 1971; 218: 257.
2. Palestro CJ, Malat J, Collica CJ, Richman AH. Incidental diagnosis of pregnancy on bone and gallium scintigraphy, *J Nucl Med* 1986; 27: 370-372.
3. Newman RA, Gallagher JG, Clements JP, Krakoff IH. Demonstration of Ga-67 localization in human placenta. *J Nucl Med* 1978; 19: 504-506.
4. Mahon DF, Subramanian G, McAfee JG. Experimental comparison of radioactive agents for studies of the placenta. *J Nucl Med* 1973; 14: 651-659.
5. Tyndall RL, Chaskes SJ, Carlton JE, Nelson B, Daniel JC. Gallium-67 distribution in pregnant mammals. *J Exp Zoo* 1976; 195: 417-424.