

Relationship between thallium-201 myocardial SPECT and findings of endomyocardial biopsy specimens in dilated cardiomyopathy

Motohiro WATANABE, Kohshi GOTOH, Kenshi NAGASHIMA, Yoshihiro UNO, Toshiyuki NODA, Kazuhiko NISHIGAKI, Genzou TAKEMURA, Motoo KANOH, Norio YASUDA, Yasushi OHNO, Shinya MINATOUGHCHI and Hisayoshi FUJIWARA

Second Department of Internal Medicine, Gifu University School of Medicine

The purpose of this study was to clarify which myocardial histological findings associated with dilated cardiomyopathy (DCM) are reflected in quantitative ^{201}Tl myocardial SPECT. We obtained studied SPECT images from 21 patients with DCM 10 minutes and 2 hours after they received an injection of 111 MBq ^{201}Tl at rest. We calculated the percent coefficient of variation of myocardial ^{201}Tl counts [%CV(Tl)], the washout rate (WR), standard deviation of WR [SD(WR)], extent score (ES) and severity score (SS). We used image analysis to measure % fibrosis, % myocytes, the ratio of fibrous tissue to myocyte tissue (F/My), myocyte size and standard deviation of myocyte size [SD(My)] in left ventricular endomyocardial biopsy specimens. The %CV(Tl) was correlated with % fibrosis and F/My. The ES and SS also correlated with F/My. The correlation between SD(WR) and SD(My) was significant. The present findings suggest that %CV(Tl), ES and SS of rest ^{201}Tl SPECT reflect myocardial fibrosis and that the standard deviation of washout reflects the distribution of myocyte size.

Key words: thallium, endomyocardial biopsy, dilated cardiomyopathy

INTRODUCTION

THE SEVERITY of dilated cardiomyopathy (DCM) is often assessed by means of thallium-201 (^{201}Tl) myocardial single photon emission computed tomography (SPECT).^{1–3} The ^{201}Tl myocardial SPECT findings of DCM are quite varied. Uptake is not homogeneous, and defects can appear as patchy, small or large.^{4–6} Because of recent developments in computer analysis systems, ^{201}Tl myocardial SPECT can be easily quantified.

Myocardial pathological findings in endomyocardial biopsy specimens are also varied; fibrosis can appear as diffuse, focal or mixed. Few studies have demonstrated the relationship between the quantitative findings of myocardial SPECT and the visual assessment of myocardial fibrosis,⁷ and the relationship between quantitative myo-

cardial SPECT and quantitative histological findings remains unknown. We compared visual assessments with quantitative histological findings of myocardial fibrosis.

The purpose of the present study was to clarify whether quantitative results of ^{201}Tl myocardial SPECT have relevance to pathological findings. We therefore compared the quantitative findings of ^{201}Tl myocardial SPECT with those of endomyocardial biopsy tissue (% fibrosis, % myocyte and myocyte size) at the left ventricle (LV) and of contrast left ventriculography.

MATERIALS AND METHODS

Subjects

Twenty-one patients (mean age 55 ± 13 years; 15 male, 6 female) who fulfilled the following diagnostic criteria were examined at Gifu University hospital from January, 1997 through March, 1999. Written informed consent was obtained from all patients.

Diagnostic criteria^{8,9}

(1) Ejection fraction (EF) $< 50\%$ and end-diastolic volume index (EDVI) $> 100 \text{ ml/m}^2$ assessed by contrast

Received July 18, 2000, revision accepted November 10, 2000.

For reprint contact: Hisayoshi Fujiwara, M.D., Second Department of Internal Medicine, Gifu University School of Medicine, 40 Tsukasa-machi, Gifu 500-8705, JAPAN.

left ventriculography.

(2) Idiopathic, familial/genetic, viral and/or immune, alcoholic/toxic, or associated with recognized cardiovascular disease in which the degree of myocardial dysfunction could not be explained by either abnormal loading conditions or the extent of ischemic damage.

²⁰¹Tl myocardial SPECT

Early and delayed images were obtained by means of a gamma camera equipped with a low-energy high-resolution parallel-hole collimator (PICKER. PRISM-3000XP, image size 64 × 64, angular Step 5° number of steps 24 × 3, value 30 sec/step, pixel size 3.7 mm) 10 minutes and 2 hours, respectively, after an intravenous injection of 111 MBq (3 mCi). The ²⁰¹Tl data were stored in a computer (PICKER. ODYSSEY) for subsequent analysis. Circumferential profiles of each short-axis tomographic image were constructed of maximal count values per pixel in each of 60 radii that were spaced at 6-degree intervals. Count values at each point in the profile were then normalized to the maximal counts in the profile of each image. The resulting profiles were arranged as a series of concentric circles that formed a single two-dimensional Bull's eye map with the apex at the center and the base at the periphery. The mean of the counts per pixel and standard deviation of the counts per pixel were calculated.

The % coefficient of variation of ²⁰¹Tl counts [%CV(Tl)] was calculated as [(standard deviation of the counts per pixel)/(mean of the counts per pixel)] × 100. The %CV(Tl) was considered an index of the heterogeneity of myocardial ²⁰¹Tl uptake.

Washout rates per pixel were calculated with the formula [(counts per pixel on early images – counts per pixel on delayed images)/(counts per pixel on early images)] × 100. The mean value of the washout rates per pixel is named WR and their standard deviation is referred to as SD (WR). Standard Bull's eye maps were drawn with the same apparatus from 96 normal individuals consisting of 47 males and 49 females.

A myocardial pixel region was considered abnormal if the ²⁰¹Tl uptake on the image was greater than 2 standard deviations below the mean observed in the same pixel for the standard Bull's eye map. The Extent Score (ES) refers to abnormal pixel points per total pixel points × 100. The Severity Score (SS) refers to the sum of counts in abnormal points which were the difference between the counts in the same pixel in patients and counts in the standard Bull's eye per total pixel points^{10,11} (Fig. 1). The ES and SS were considered to be an index of myocardial damage.

Cardiac catheterization

All patients underwent left side cardiac catheterization within a month of undergoing ²⁰¹Tl myocardial SPECT. By the standard area-length method, the end-diastolic volume and ejection fraction were measured with an Angiogram Analyzer System from traced silhouettes of

the left ventriculogram in the right anterior oblique projection. We simultaneously obtained a left ventricular endomyocardial biopsy specimen.

Histological assessment

Three to five biopsy specimens were obtained from left ventricles. The largest specimens were diagnostically evaluated by light microscopy. These specimens were immediately fixed in 10% buffered formalin, dehydrated, embedded in paraffin wax, sliced into 4 μm sections and stained with Masson's trichrome. Histological parameters such as the degree of fibrosis (from 0 to 3), % fibrosis, % myocyte and myocyte size were evaluated.

The extent of fibrosis was graded by visual assessment as 0 (no fibrosis), 1 (mild, when an isolated scar or mild interstitial fibrous tissue formation or both were identified), 2 (moderate, intermediate between mild and severe), or 3 (severe, characterized by extreme replacement scarring occupying substantial portions of the section)¹² (Fig. 2).

We defined fibrous tissue as blue stained areas, myocytes as red stained areas and interstitial tissue as neither blue nor red. Each area was measured with an Image Analyzer (NIRECO, LUZEX-F, Fig. 3). The ratio of each area to total tissue area was % fibrosis, % myocytes and % interstitial tissue, respectively. Some crevices on biopsy and fatty tissue were included in the interstitial tissue. The ratio of fibrous to myocyte tissue (F/My) was calculated. This was considered to be an index of fibrosis without the influence of crevices and fatty tissue. Subendocardial fibrosis and perivascular fibrosis were included in fibrous tissue, but these conditions were infrequent in the total tissue.

Myocyte size, namely the mean diameter of 30 to 50 myocytes per specimen was measured with the same Image Analyzer at a point directly across the center of the nucleus in the longitudinal sections.¹³ Standard deviations of myocyte size [SD(My)] were also taken as the inhomogeneity index. At the same time, [SD(My)/myocyte size] × 100 was taken as the coefficient of variation of myocyte size [%CV(My)].

Statistical analysis

Values are expressed as means ± 1 standard deviation (SD). Significant correlation was assessed by linear regression analysis where appropriate. But % fibrosis and fibrosis score were compared by means of a logarithmic curve fit. A p value < 0.05 was considered significant.

RESULTS

Quantitative ²⁰¹Tl SPECT findings

The %CV(Tl) on early images was 13.4 ± 3.3% (mean ± SD). The ES on early images was 17.8 ± 14.5. The SS on early images was 9.1 ± 10.0. The %CV(Tl) on delayed images was 13.4 ± 3.3%. The ES on delayed images was 18.9 ± 18.0. The SS on delayed images was 10.7 ± 15.0.

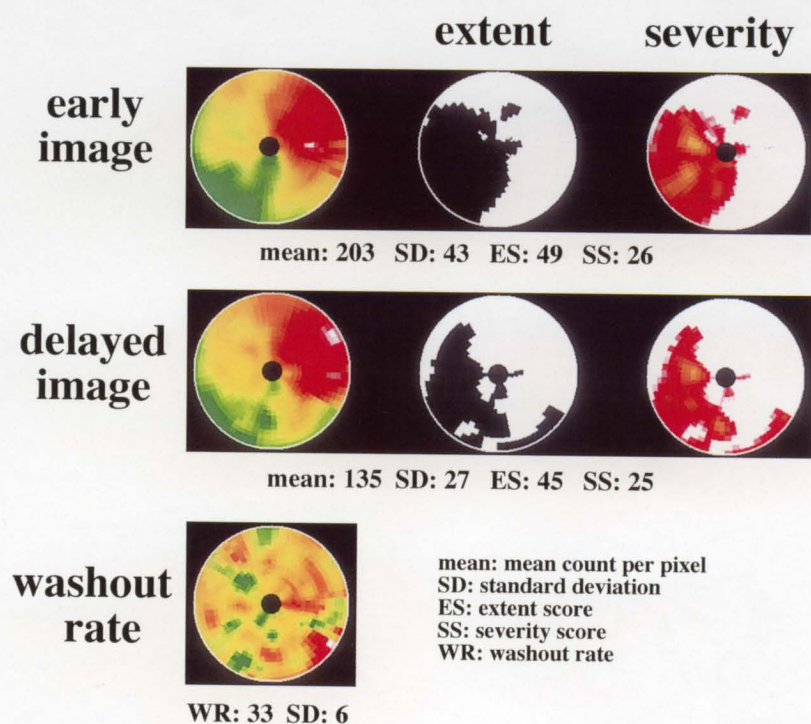


Fig. 1 Bull's eye, extent and severity maps. Quantitative findings of ^{201}Tl SPECT in a patient with DCM were calculated using a computer system.

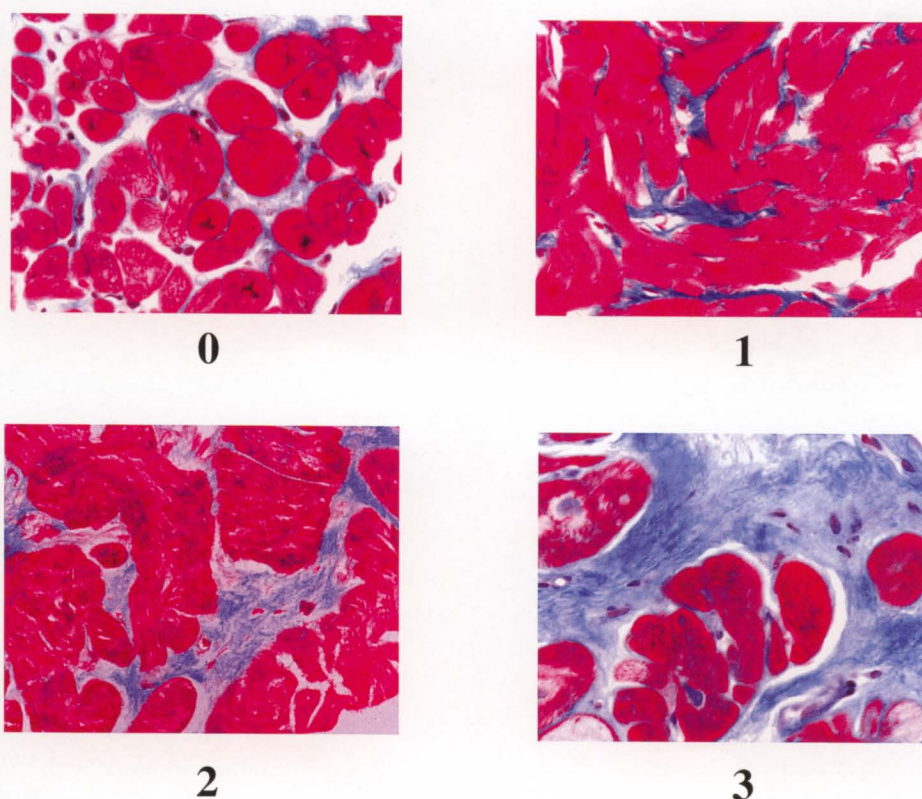


Fig. 2 Degree of fibrosis (from 0 to 3) evaluated from light microscopic observations of the section stained with Masson's trichrome.

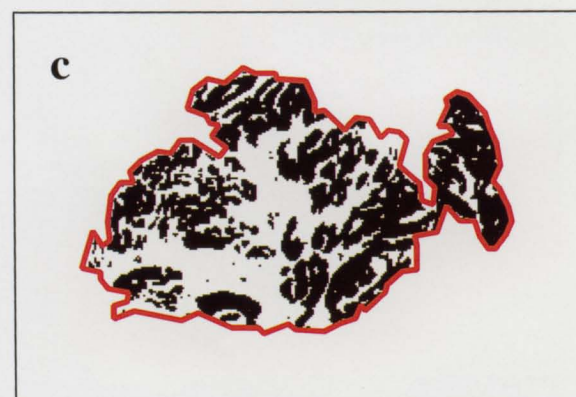
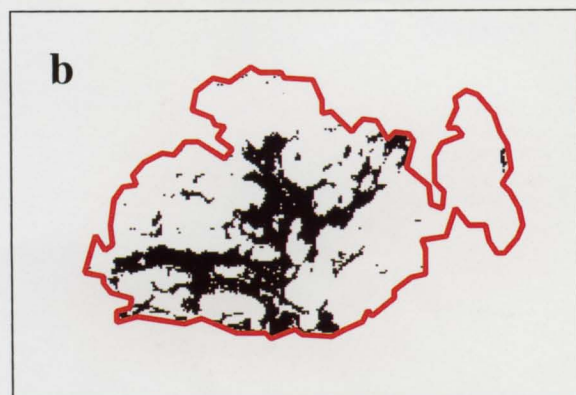
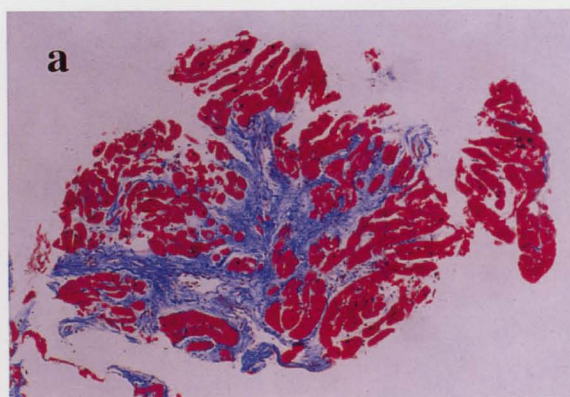


Fig. 3 a: Biopsy tissue stained with Masson's trichrome examined by image analysis. b: Blue area of biopsy tissue indicates fibrosis. c: Red area of biopsy tissue represents myocytes. Interstitial tissue was (b) and (c) subtracted from total tissue area.

The WR was 12.2 ± 10.9 . The SD(WR) was 6.4 ± 2.1 (Table 1).

Pathological findings of LV endomyocardial biopsy specimens

The % fibrosis was $12.7 \pm 7.8\%$. The F/My was 0.37 ± 0.42 . The fibrosis score was 2.0 ± 0.8 . The myocyte size was $21.2 \pm 4.5 \mu\text{m}$. The SD(My) was $5.2 \pm 2.1 \mu\text{m}$. The

Table 1 Quantitative findings of ^{201}Tl SPECT

| | |
|--|-----------------|
| early image | |
| %CV of myocardial ^{201}Tl counts | 13.4 ± 3.3 |
| extent score | 17.8 ± 14.5 |
| severity score | 9.1 ± 10.0 |
| delayed image | |
| %CV of myocardial ^{201}Tl counts | 13.4 ± 3.3 |
| extent score | 18.9 ± 18.0 |
| severity score | 10.7 ± 15.0 |
| washout | |
| washout rate | 12.2 ± 10.9 |
| SD of washout rate | 6.4 ± 2.1 |

%CV: % coefficient of variation, SD: standard deviation

Table 2 Quantitative pathological findings of left ventricular biopsies

| | |
|--------------------------------|-----------------|
| % fibrosis | 12.7 ± 7.8 |
| fibrosis/myocyte | 0.37 ± 0.42 |
| fibrosis score | 2.0 ± 0.8 |
| myocyte size (μm) | 21.2 ± 4.5 |
| SD of myocyte size | 5.2 ± 2.1 |
| %CV of myocyte size | 24.1 ± 7.6 |
| % myocyte | 44.6 ± 14.1 |
| % interstitium | 43.3 ± 11.7 |

SD: standard deviation, %CV: % coefficient of variation

%CV(My) was $24.1 \pm 7.6\%$, the % coefficient of variation of myocardial cell size, which was greater than in non-cardiac patients, was due to myocyte loss and vicarious myocyte hypertrophy.¹⁴ The % myocytes was $44.6 \pm 14.1\%$. The % interstitial tissue was $43.3 \pm 11.7\%$ (Table 2). The correlation that was roughly between % fibrosis and the fibrosis score was significant ($r = 0.64$, $p < 0.01$, Fig. 4).

Left ventriculogram findings

The EDVI was $126 \pm 27.6 \text{ ml/m}^2$. The EF was $30.9 \pm 10.8\%$.

Correlation between quantitative ^{201}Tl SPECT findings, pathological findings in endomyocardial biopsy specimens and left ventriculography

The %CV(Tl) on early images significantly correlated with % fibrosis ($r = 0.603$, $p < 0.01$, Fig. 5), F/My ($r = 0.604$, $p < 0.01$), EDVI ($r = 0.744$, $p < 0.0001$, Fig. 6) and EF ($r = -0.490$, $p < 0.05$), but %CV(Tl) on early images and fibrosis score were not correlated. The ES on early images significantly correlated with F/My ($r = 0.541$, $p < 0.05$) and EDVI ($r = 0.552$, $p < 0.01$). The SS on early images significantly correlated with F/My ($r = 0.496$, $p < 0.05$) and EDVI ($r = 0.545$, $p < 0.01$) (Table 3). The %CV(Tl) of delayed images significantly correlated with % fibrosis ($r = 0.530$, $p < 0.05$), F/My ($r = 0.530$, $p < 0.05$), EDVI ($r = 0.673$, $p < 0.001$) and EF ($r = -0.580$, $p < 0.01$). The ES on delayed images significantly correlated with

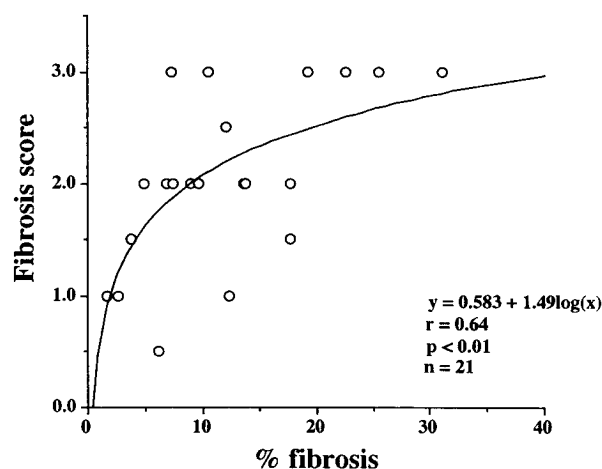


Fig. 4 Relationship between fibrosis score and % fibrosis in 21 patients with DCM. Correlation coefficient is only 0.64 ($p < 0.01$), although these were assessed in the same specimen. This shows that fibrosis score was sometimes judged to be more severe than % fibrosis.

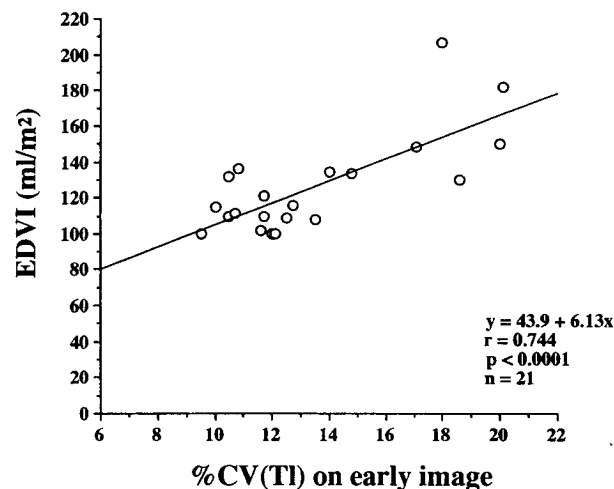


Fig. 6 Relationship between %CV(Tl) on early image and EDVI. Correlation coefficient is $r = 0.774$ ($p < 0.0001$).

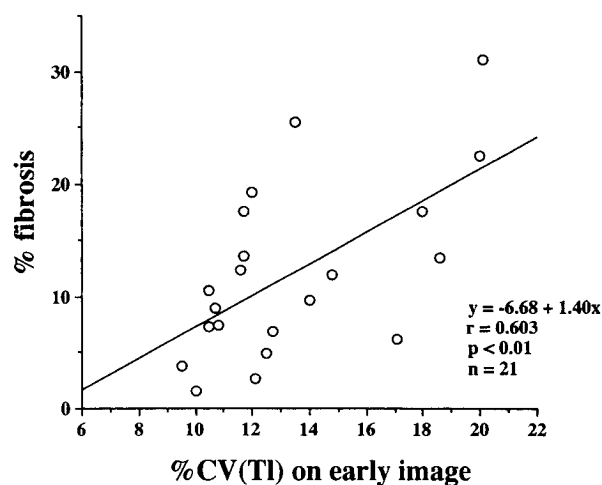


Fig. 5 Data plot showing relationship between %CV(Tl) on early image and % fibrosis. Regression analysis reveals significant correlation ($r = 0.603$ $p < 0.01$).

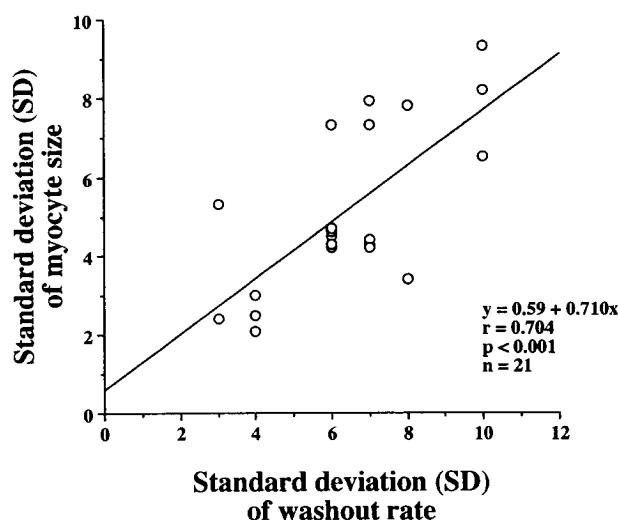


Fig. 7 Relationship between standard deviation (SD) of the washout rate and of myocyte size. The correlation between the two was significant ($p < 0.001$).

Table 3 Correlation between quantitative findings of ^{201}Tl SPECT on early images, and quantitative pathological findings of endomyocardial biopsies and LVG findings

| early image | % fibrosis | fibrosis/ myocyte | fibrosis score | myocyte size | % myocyte | EDVI | EF |
|--------------------------------|------------------|----------------------|-------------------|-----------------|-----------|-------------------|----------------|
| %CV of myocardial Tl counts | $r = 0.603^{**}$ | $r = 0.604^{**}$ | NS | NS | NS | $r = 0.744^{***}$ | $r = -0.490^*$ |
| extent score | NS | $r = 0.541^*$ | NS | NS | NS | $r = 0.552^{**}$ | NS |
| severity score | NS | $r = 0.496^*$ | NS | NS | NS | $r = 0.545^{**}$ | NS |

LVG: left ventriculogram, EDVI: end-diastolic volume index, EF: ejection fraction, %CV: % coefficient variation

*: $p < 0.05$, **: $p < 0.01$, ***: $p < 0.0001$

EDVI ($r = 0.688$, $p < 0.001$). The SS on delayed images significantly correlated with F/My ($r = 0.493$, $p < 0.05$) and EDVI ($r = 0.722$, $p < 0.0001$).

Correlation between quantitative washout of ^{201}Tl SPECT and pathological findings in endomyocardial biopsy specimens

The correlation was significant ($r = 0.704$, $p < 0.001$) between SD(WR) and SD(My) (Fig. 7) and between SD(WR) and %CV(My) ($r = 0.456$, $p < 0.05$), but neither the WR nor SD(WR) significantly correlated with other pathological findings.

DISCUSSION

Assessment of pathological findings of LV endomyocardial biopsy specimens in DCM

Onodera et al.¹⁵ reported that the percent areas of fibrosis in the septum, anterior, lateral and posterior walls of the left ventricle in autopsy tissue of DCM do not significantly differ among regions. These observations suggest that biopsy findings represent a similar extent of total left ventricular fibrosis, indicating that comparison of biopsy specimens with the ^{201}Tl image is acceptable.

On the other hand, our quantitative pathological assessment of LV endomyocardial biopsy tissues with an Image Analyzer revealed % fibrosis of $12.7 \pm 7.8\%$ and myocyte size of $21.2 \pm 4.5 \mu\text{m}$. These values were similar to those reported by Fujiwara¹⁶ using a similar method in autopsy tissue % fibrosis in the LV free wall was $11 \pm 4\%$ and myocyte size was $21 \pm 3 \mu\text{m}$.

The coefficient of correlation of between % fibrosis as a quantitative assessment and fibrosis score as a visual assessment was only 0.64, in the same specimen. Figure 4 suggests that the fibrosis score in visual assessment was more severe when regional fibrosis was severe, even if the total % fibrosis was low. This finding showed that regional replacement fibrosis greatly influenced the fibrosis score in the visual assessment. Therefore, quantifying % fibrosis is not the same as fibrosis score by visual assessment. The fibrosis in DCM was mainly interstitial, although some replacement fibrosis was evident.^{17–19} This suggests that quantitative evaluation is necessary to assess interstitial fibrosis in biopsy tissues.

Relationship between quantitative ^{201}Tl SPECT and pathological findings in endomyocardial biopsy specimens

Myocardial damage in DCM is often assessed by ^{201}Tl SPECT, DCM images of which often show various findings such as inhomogeneous uptake, patchy defects and small or large defects. Therefore %CV(Tl) should be a useful parameter with which to assess diffuse and patchy damage observed in DCM.

The %CV(Tl) correlated with % fibrosis and F/My of endomyocardial tissue, suggesting that inhomogeneous

myocardial ^{201}Tl uptake reflects the degree of fibrosis. The ES and SS significantly correlated with F/My as an index of fibrosis because the influence of some crevices and fatty tissue was excluded. Therefore, F/My was a better index than % fibrosis. The %CV(Tl) correlated well with EDVI and EF. Therefore, %CV(Tl) also reflects left ventricular dysfunction.

This paper is the first known comparison of quantitative ^{201}Tl and binarized quantitative methods of defining fibrosis in endomyocardial biopsy specimens. Although the visual assessment of myocardial fibrosis and quantitative findings of ^{201}Tl SPECT under our conditions did not significantly correlate, quantitative % fibrosis and F/My significantly correlated with quantitative findings of ^{201}Tl SPECT. As a result, the % fibrosis and F/My, which are objective indices, seemed to be reflected in the quantitative ^{201}Tl findings.

Relationship between quantification of ^{201}Tl washout rate and pathological finding of endomyocardial biopsy specimens

The standard deviation of the washout rate per pixel and of myocyte size (Fig. 7) significantly correlated. The amount of ^{201}Tl uptaken by the myocardium is determined primarily by myocardial perfusion and depends on aspects of cell function such as the Na^+ , K^+ pump and the electropotential gradient at the myocyte cell membrane. The ^{201}Tl washout rate reflects the net ^{201}Tl clearance, which is the sum of the ^{201}Tl uptake and backflow (dependent on the electropotential gradient), but in hypertrophied myocytes, Na^+ , K^+ -ATPase is impaired.^{20,21} Therefore the SD of the washout rate reflected Na^+ , K^+ -ATPase variability, which may in turn reflect myocyte size distribution together with microcirculatory derangement and luminal narrowing of capillaries.²² The inhomogeneous washout rate was possibly caused by a mosaic state produced by the framework, fibrosis and a combination of cells with disparate functions, that is, groups of myocytes with normal cell functions, one with impaired functions and others.

Nishikawa et al.¹⁴ described %CV(My) as a parameter of the distribution of myocyte cell sizes. They found that patients with DCM had the histological feature of a larger distribution of myocyte cell sizes. With regard to the published relationship between ^{201}Tl and pathological findings, no comparisons have been described. The %CV(My) together with SD(My) was used in the present study as an index of the dispersion of myocyte cell size. Because of the higher correlation coefficients, SD(My) rather than %CV(My) seemed to be more appropriate as a parameter of myocyte cell size dispersion, which is reflected in the ^{201}Tl SPECT findings.

In conclusion, (1) quantitative evaluation is necessary to assess myocardial fibrosis in the endomyocardial biopsy specimens, (2) %CV(Tl), ES and SS, of rest ^{201}Tl SPECT reflect myocardial fibrosis and LV function, and

(3) the standard deviation of the washout rate reflects the distribution of myocyte size.

REFERENCES

1. Shiotani H, Yamabe H, Fukuzaki H. The clinical and prognostic significance of dipyridamole Tl-201 emission computed tomography in patients with dilated cardiomyopathy. *Jpn Circ J* 1987; 51: 1016–1021.
2. Tamai J, Nagata S, Nishimura T, Yutani C, Miyatake K, Sakakibara H, et al. Hemodynamic and prognostic value of thallium-201 myocardial imaging in patients with dilated cardiomyopathy. *Int J Cardiol* 1989; 24: 219–224.
3. Doi Y, Chikamori T, Takata J, Yonezawa Y, Poloniecki JD, Ozawa T, et al. Prognostic value of thallium-201 perfusion defects in idiopathic dilated cardiomyopathy. *Am J Cardiol* 1991; 67: 188–193.
4. Bulkley BH, Hutchins GM, Bailey I, Strauss HW, Pitt B. Thallium 201 imaging and gated cardiac blood pool scan in patients with ischemic and idiopathic congestive cardiomyopathy: A clinical and pathologic study. *Circulation* 1977; 55: 753–760.
5. Saltissie S, Hockings B, Croft DN, Webb-Peploe MM. Thallium-201 myocardial imaging in patients with dilated and ischemic cardiomyopathy. *Br Heart J* 1981; 46: 290–295.
6. Dunn RF, Uren RF, Sadick N, Bautovich G, McLaughlin A, Hiroe M, et al. Comparison of thallium-201 scanning in idiopathic dilated cardiomyopathy and severe coronary artery disease. *Circulation* 1982; 66: 804–810.
7. Li L, Nohara R, Okuda K, Hosokawa R, Hata T, Tanaka M, et al. Comparative study of ²⁰¹Tl-scintigraphic image and myocardial pathologic findings in patients with dilated cardiomyopathy. *Ann Nucl Med* 1996; 10: 307–314.
8. Brandenburg RO, Chazov E, Cherian G, Falase AO, Grosgeat Y, Kawai C, et al. Report of the WHO/ISFC task force on the definition and classification of cardiomyopathies. *Br Heart J* 1980; 44: 672–673.
9. Richardson P, McKenna W, Bristow M, Maisch B, Mautner B, O'Connell, et al. Report of the 1995 World Health Organization/International Society and Federation of Cardiology Task Force on the definition and classification of cardiomyopathies. *Circulation* 1996; 93: 841–842.
10. Burow RD, Pond M, Schafer AW, Becker L. "Circumferential Profiles:" A new method for computer analysis of Thallium-201 myocardial perfusion images. *J Nucl Med* 1979; 20: 771–777.
11. Garcia EV, Train KV, Maddahi J, Prigent F, Freidman J, Areeda J, et al. Quantification of rotational thallium-201 myocardial tomography. *J Nucl Med* 1985; 26: 17–26.
12. Edwards WD. Myocarditis and endomyocardial biopsy. *Cardiol Clin* 1984; 2: 647–656.
13. Nunoda S, Genda A, Sekiguchi M, Takeda R. Left ventricular endomyocardial biopsy findings in patients with essential hypertension and hypertrophic cardiomyopathy with special reference to the incidence of bizarre myocardial hypertrophy with disorganization and biopsy score. *Heart and Vessels* 1985; 1: 170–175.
14. Nishikawa T, Sekiguchi M, Hasumi M, Kasajima T, Nakazawa M, Ando M, et al. Histopathologic findings of endomyocardial biopsies in pediatric patients with arrhythmias or conduction disturbances. *Heart Vessels Suppl* 1990; 5: 24–27.
15. Onodera T, Fujiwara H, Tanaka M, Wu DJ, Hamashima Y, Kawai C. Quantitative analysis of cardiac fibrosis in normal hearts, hearts with secondary eccentric hypertrophy and hearts with dilated cardiomyopathy. *Card-Ang Bull (Cardiologisch-Angiologisches Bulletin)* 1986; 3: 53–59.
16. Fujiwara H, Onodera T, Tanaka T, Fujiwara T, Kawai C, Hamashima Y. Number and size of myocytes, amount of interstitial space, fibrosis and disarray in dilated cardiomyopathy. [in Japanese] *J Cardiography* 1986; 16: 27–33.
17. Olsen EJG. Pathology of primary cardiomyopathies. *Postgrad Med J* 1972; 48: 732–737.
18. Roberts WC, Ferrans VJ, Buja LM. Pathologic aspects of the idiopathic cardiomyopathies. *Adv Cardiol* 1974; 13: 349–367.
19. Roberts WC, Siegel RJ, McMarrus BM. Idiopathic dilated cardiomyopathy: analysis of 152 necropsy patients. *Am J Cardiol* 1987; 60: 1340–1355.
20. Godfraind T, Noel F. Sodium activation of heart (Na⁺+K⁺)-ATPase from normotensive and spontaneously hypertensive rats. *Arch Int Pharmacodyn* 1980; 245: 139–144.
21. David-Duflho M. Quantitative changes in cardiac Na,K-ATPase of spontaneously hypertensive rats. *J Cardiovasc Pharmacol* 1984; 6: 273–280.
22. Takemura G, Takatsu Y, Fujiwara H. Luminal narrowing of coronary capillaries in human hypertrophic hearts: an ultrastructural morphometrical study using endomyocardial biopsy specimens. *Heart* 1998; 79: 78–85.