

## Detecting meningeal carcinomatosis from breast cancer with thallium-201 SPECT

Naoto WATANABE,\* Masashi SHIMIZU,\* Kyo NOGUCHI,\* Hideto KAWABE,\*  
Norihisa TONAMI\*\* and Hikaru SETO\*

*\*Department of Radiology, Toyama Medical and Pharmaceutical University*

*\*\*Department of Nuclear Medicine, Kanazawa University*

Thallium-201 ( $^{201}\text{Tl}$ ) scintigraphy is one of the imaging methods used in the detection of various tumors including brain metastasis. We evaluated a patient with meningeal carcinomatosis from breast cancer by using  $^{201}\text{Tl}$  single-photon emission computed tomography (SPECT). Meningeal spread of a tumor was noted on enhanced CT. SPECT revealed tumor localization in meningeal carcinomatosis. These results suggest that SPECT with  $^{201}\text{Tl}$  may be useful in detecting meningeal carcinomatosis from breast cancer.

**Key words:** meningeal carcinomatosis, breast cancer,  $^{201}\text{Tl}$  SPECT, Tumor imaging

### INTRODUCTION

MENINGEAL CARCINOMATOSIS is recognized as a rare form of diffuse or multifocal leptomeningeal metastasis of solid tumors. Breast cancer and lung cancer are the most common primary tumors associated with meningeal carcinomatosis.<sup>1,2</sup> The incidence of meningeal carcinomatosis has been reported to be 5% in patients with breast cancer<sup>3</sup> and from 9 to 28% in patients with small cell carcinoma of the lung.<sup>4,5</sup>

$^{201}\text{Tl}$  chloride, first used for myocardial imaging, has also been shown to have affinity for a variety of malignant tumors.<sup>6–11</sup> Tumor uptake of  $^{201}\text{Tl}$  in brain metastasis was also described.<sup>12</sup> It is suggested that  $^{201}\text{Tl}$  imaging may be useful in investigating patients with meningeal carcinomatosis.

The purpose of this paper is to report the scintigraphic SPECT findings in a patient with meningeal carcinomatosis from breast cancer by using  $^{201}\text{Tl}$ .

### CASE REPORT

A 58-year-old woman was admitted with nausea and vomiting. Solid tubular carcinoma of recurrent breast tumor had already been confirmed by the surgery. Enhanced CT (Toshiba, TCT 900S, Tokyo, Japan) was performed to evaluate the neurological symptoms including ataxia. CT scan revealed prominent enhancement adjacent to the right cerebellar hemisphere, fourth ventricle and cerebellar vermis with low density edema in the right cerebellar hemisphere and brain stem. Hydrocephalus was also detected (Fig. 1). Examination of the cerebrospinal fluid (CSF) could not be done, but meningeal carcinomatosis from breast cancer was highly suspected with these clinical findings. Transverse reconstruction of SPECT images was done with high-resolution SPECT with three-head rotating cameras (Toshiba, GCA 9300A, Tokyo, Japan) at 15 min postinjection of 3 mCi (111 MBq) of  $^{201}\text{Tl}$  chloride. Axial SPECT images (Fig. 2) showed abnormally high uptake of  $^{201}\text{Tl}$  in the mass lesion. SPECT findings were correlated with those of subsequent CT. Delayed SPECT imaging was not done. The patient died 2 months after admission. An autopsy could not be done.

### DISCUSSION

The incidence of meningeal carcinomatosis in breast

Received February 24, 2000, revision accepted July 5, 2000.

For reprint contact: Naoto Watanabe, M.D., Department of Radiology, Toyama Medical and Pharmaceutical University, Sugitani 2630, Toyama 930-0194, JAPAN.

E-mail: nw31456@ms.toyama-mpu.ac.jp

cancer patients accounts for 1% to 5% in most clinical studies. Tsukada et al. reported an incidence of meningeal carcinomatosis in breast cancer patients about 5.6%.<sup>13</sup> The clinical diagnosis of meningeal carcinomatosis rests upon the findings of neurologic signs and symptoms of cerebral, cranial nerve, and spinal cord involvement, such as headache, change of mental status, ataxia and diplopia. The most important diagnostic test is examination of CSF. Wasserstrom et al. reported that the initial lumbar puncture was abnormal in 87 of 90 patients (97%).<sup>14</sup> In our case, examination of CSF could not be done, but meningeal carcinomatosis from breast cancer was highly suspected with these clinical findings.

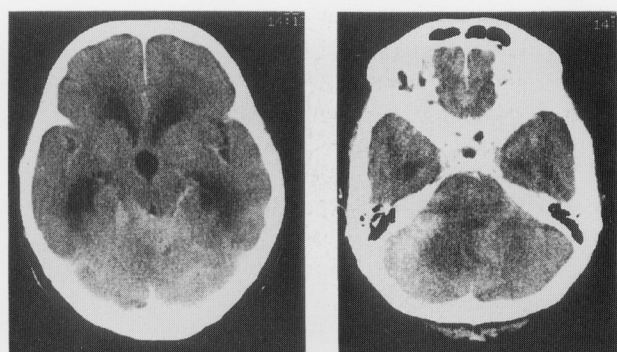CT is helpful in the diagnosis of meningeal carcinomatosis. Contrast-enhanced CT may detect communicating hydrocephalus and abnormal enhancement of the tentorium, sylvian fissures and basal cisterns, cortical sub-

arachnoid space, and ventricular walls.<sup>15,16</sup> In our patient, CT findings were compatible with meningeal carcinomatosis from breast cancer, but our CT findings were not specific for meningeal carcinomatosis. The causes of abnormal meningeal enhancement on CT are subarachnoid hemorrhage, infection and neoplasm.

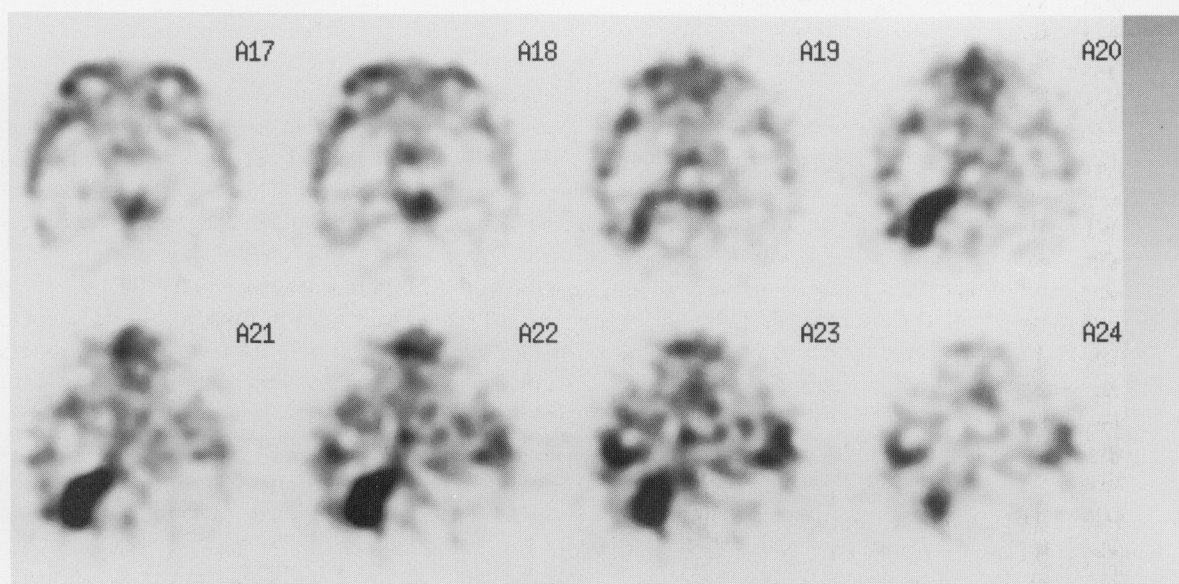
The prognosis of meningeal carcinomatosis from breast cancer has been considered poor, with or without treatment. The survival of patients remains short and median survival was 5.8 months after diagnosis, with a range of 1–29 months.<sup>14</sup> A variety of treatments have been used including craniospinal radiotherapy and intrathecal chemotherapy. This patient refused to have chemotherapy, and prognosis was also very poor.

<sup>201</sup>Tl scintigraphy can be generally used to detect various malignant tumors including breast cancer.<sup>6–11</sup> Tumor uptake of <sup>201</sup>Tl in various brain tumors including brain metastasis has also been described, but tumor uptake of <sup>201</sup>Tl in meningeal carcinomatosis has not been extensively reported. High uptake of <sup>201</sup>Tl on early images in our case suggested that <sup>201</sup>Tl may accumulate in meningeal carcinomatosis from breast cancer. Staffen et al. found that <sup>201</sup>Tl brain SPECT early imaging helps to differentiate between malignant tumors, poorly vascularized benign lesions and necrosis.<sup>17</sup> Liu et al. reported that <sup>201</sup>Tl brain SPECT early and delayed imaging is very useful in brain tumor localization, in distinguishing low-grade from high-grade brain tumors and in predicting histologic grades of brain tumors,<sup>18</sup> but <sup>201</sup>Tl may accumulate in inflammation of the brain.<sup>19</sup> Unfortunately we could not clarify the tumor uptake of <sup>201</sup>Tl in the primary breast cancer in our patient because <sup>201</sup>Tl scintigraphy had not been performed before.

We succeeded in demonstrating the tumor uptake of



**Fig. 1** CT scan revealed prominent enhancement adjacent to right cerebellar hemisphere, fourth ventricle and cerebellar vermis with low density edema in right cerebellar hemisphere and brain stem. Hydrocephalus was also detected.



**Fig. 2** Transverse SPECT image showed tumor uptake in meningeal carcinomatosis.

meningeal carcinomatosis from breast cancer with  $^{201}\text{Tl}$  SPECT imaging. These results suggested that  $^{201}\text{Tl}$  scintigraphy may be a useful radiopharmaceutical agent for detecting of lesions with meningeal carcinomatosis from breast cancer.

## REFERENCES

1. Sorensen SC, Eagan RT, Scott M. Meningeal carcinomatosis in patients with primary breast or lung cancer. *Mayo Clin Proc* 59: 91-94, 1984.
2. Boogerd W, Hart AAM, van der Sande JJ, Engelsman E. Meningeal carcinomatosis in breast cancer. *Cancer* 67: 1685-1695, 1991.
3. Yap HY, Yap BS, Tashima CK, DiStefano A, Blumenschein GR. Meningeal carcinomatosis in breast cancer. *Cancer* 42: 283-286, 1978.
4. Aroney RS, Dalley DN, Chan WK, Bell DR, Levi JA. Meningeal carcinomatosis in small cell carcinoma of the lung. *Am J Med* 71: 26-32, 1981.
5. Rosen ST, Aisner J, Makuch RW, Matthews MJ, Ihde DC, Whitacre M, et al. Carcinomatous leptomeningitis in small cell lung cancer: a clinicopathologic review of the National Cancer Institute experience. *Medicine* (Baltimore) 61: 45-53, 1982.
6. Waxman AD. Thallium-201 in nuclear oncology. In: Freeman LM. *Nuclear Medicine Annual*. New York: Raven Press; pp. 193-209, 1991.
7. Tonami N, Hisada K. Clinical experience of tumor imaging with thallium-201-chloride. *Clin Nucl Med* 2: 75-81, 1977.
8. Hisada K, Tonami N, Miyamae T, Hiraki Y, Yamazaki T, Maeda T, Nakajo M. Clinical evaluation of tumor imaging with thallium-201-chloride. *Radiology* 129: 497-500, 1978.
9. Tonami N, Hisada K. Thallium-201 scintigraphy in postoperative detection of thyroid cancer; a comparative study with I-131. *Radiology* 136: 461-464, 1980.
10. Kaplan WD, Takvorian T, Morris JH, Rumbaugh CL, Connolly BT, Atkins HL. Thallium-201 brain tumor imaging: a comparative study with pathological correlation. *J Nucl Med* 28: 47-52, 1987.
11. Tonami N, Shuke N, Yokoyama K, Seki H, Takayama T, Kinuya S, et al. Use of thallium-201 single-photon emission computed tomography in the evaluation of suspected lung cancer. *J Nucl Med* 30: 997-1004, 1989.
12. Dierckx RA, Martin JJ, Dobbeleir A, Crols R, Neetens I, De Deyn PP. Sensitivity and specificity of thallium-201 single-photon emission tomography in the functional detection and differential diagnosis of brain tumours. *Eur J Nucl Med* 21: 621-633, 1994.
13. Tsukada Y, Fouad A, Pickren JW, Lane WW. Central nervous system metastasis from breast carcinoma autopsy study. *Cancer* 52: 2349-2354, 1983.
14. Wasserstorm WR, Glass JP, Posner JB. Diagnosis and treatment of leptomeningeal metastases from solid tumors: experience with 90 patients. *Cancer* 49: 759-772, 1982.
15. Lee YY, Glass JP, Geoffray A, Wallace S. Computed tomographic abnormalities in leptomeningeal metastasis. *AJNR* 139: 361-365, 1982.
16. Krol G, Sze G, Malkin M, Walker R. MR of cranial and spinal meningeal carcinomatosis: comparison with CT and myelography. *AJR* 151: 583-588, 1988.
17. Staffen W, Hondl N, Trinka E, Iglseder B, Unterrainer J, Ladurner G. Clinical relevance of  $^{201}\text{Tl}$ -chloride SPET in the differential diagnosis of brain tumours. *Nucl Med Commun* 19: 335-340, 1998.
18. Liu Q, Liu W, Hu W. Clinical application of  $^{201}\text{Tl}$  SPECT imaging of brain tumors. *J Nucl Med* 41: 5-10, 2000.
19. Gianotti N, Marenzi R, Messa C, Terreni MR, Rocca A, Castagna A, et al. Thallium-201 single photon emission computed tomography in the management of contrast-enhancing brain lesions in a patient with AIDS. *Clin Infect Dis* 23: 185-186, 1996.