

## A case of cavernous hemangioma of the small intestine diagnosed by scintigraphy with Tc-99m-labeled red blood cells

Yoshinori IWATA,\* Susumu SHIOMI,\* Ryuji OISO,\* Nobumitsu SASAKI,\* Junji HARA,\*  
Shiro NAKAMURA, Shuhei NISHIGUCHI\* and Hironobu OCHI\*\*

*\*Third Department of Internal Medicine, and \*\*Division of Nuclear Medicine,  
Osaka City University Medical School*

Hemangioma of the small intestine is rare, and the preoperative diagnosis of it is difficult. We report a patient with gastrointestinal bleeding for whom Tc-99m-labeled red blood cell scintigraphy was useful in diagnosing cavernous hemangioma of the small intestine. A 25-year-old man was referred to our hospital for recurrent iron deficiency anemia. Because of the patient's severe anemia, imaging was performed to locate the bleeding lesion in the gastrointestinal tract. Scintigraphy with Tc-99m-labeled red blood cells revealed pooling indicating a tumor and extravasation of blood from the tumor. Scintigraphy with Tc-99m pertechnetate revealed no abnormal accumulation. Partial resection of the small intestine was done, and cavernous hemangioma of the small intestine was diagnosed by using the specimen of resected tissue.

**Key words:** Tc-99m-labeled red blood cells, hemangioma of small intestine, gastrointestinal bleeding

### INTRODUCTION

HEMANGIOMA of the small intestine is an uncommon lesion of the digestive tract that causes gastrointestinal bleeding.<sup>1</sup> The preoperative diagnosis of this lesion has been difficult.<sup>2</sup> There are several techniques for identifying sites of gastrointestinal bleeding, including endoscopy, barium study, angiography, and scintigraphy. Tc-99m-labeled red blood cell scintigraphy is the most sensitive of them and a noninvasive method for detecting sites of obscure gastrointestinal bleeding.<sup>3–5</sup> Moreover, gastrointestinal bleeding tends to be intermittent,<sup>6</sup> and therefore studies to detect it should be performed repeatedly over a period of 24 hr. Tc-99m-labeled red blood cells, which remain in the intravascular blood pool for a long time, are an ideal radiopharmaceutical for detecting sites of intermittent gastrointestinal bleeding.<sup>3</sup>

We report here a patient with gastrointestinal bleeding

for whom Tc-99m-labeled red blood cells scintigraphy was useful in diagnosing cavernous hemangioma of the small intestine.

### CASE REPORT

A 25-year-old man consulted a neighborhood physician complaining of general fatigue and exertional dyspnea four years ago. He had been under the care of that physician with a diagnosis of iron deficiency anemia. He was referred to our hospital because of tarry stool, and hospitalized.

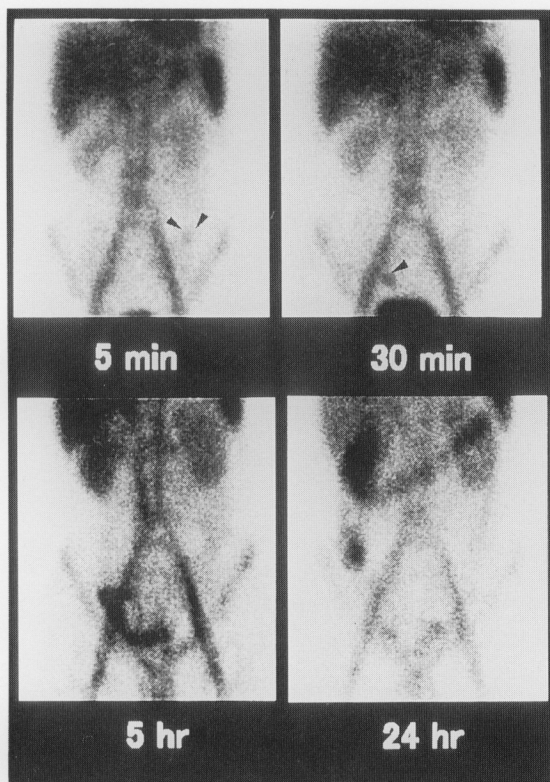
On admission, physical examination was normal except for severe anemia in the palpebral conjunctivae. There was no palpable abdominal mass, and there was no audible bruit. The red blood cell count was  $295 \times 10^4/\text{mm}^3$ , hemoglobin 7.8 g/dl, hematocrit 24.1%, serum iron 14  $\mu\text{g}/\text{dl}$ , total iron binding capacity 429  $\mu\text{g}/\text{dl}$ , and the serum ferritin level 8 ng/dl.

Because of the patient's severe anemia, imaging was performed to locate the bleeding lesion in the gastrointestinal tract. Tc-99m-labeled red blood cells (dose: 370 MBq) were injected intravenously. Image acquisition was started immediately after injection at 2 seconds per

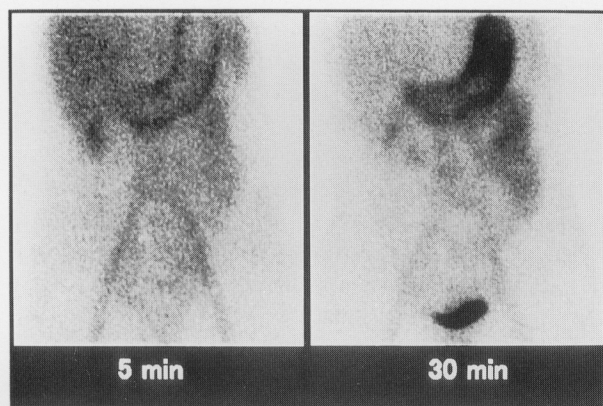
Received March 22, 2000, revision accepted June 5, 2000.

For reprint contact: Susumu Shiomi, M.D., Third Department of Internal Medicine, Osaka City University Medical School, 1–4–3 Asahimachi, Abeno-ku, Osaka 545–8585, JAPAN.

E-mail: shiomis@med.osaka-cu.ac.jp

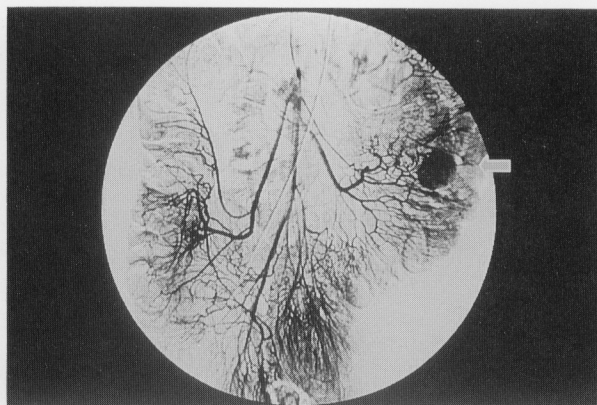


**Fig. 1** Scintigraphy with Tc-99m-labeled red blood cells. Imaging performed 5 minutes after injection revealed an abnormal accumulation suggesting a bleeding site. Imaging of 30 minutes after injection revealed an abnormal accumulation in the ileocecal region, and the radioactivity moved gradually along the ascending colon to the transverse colon.

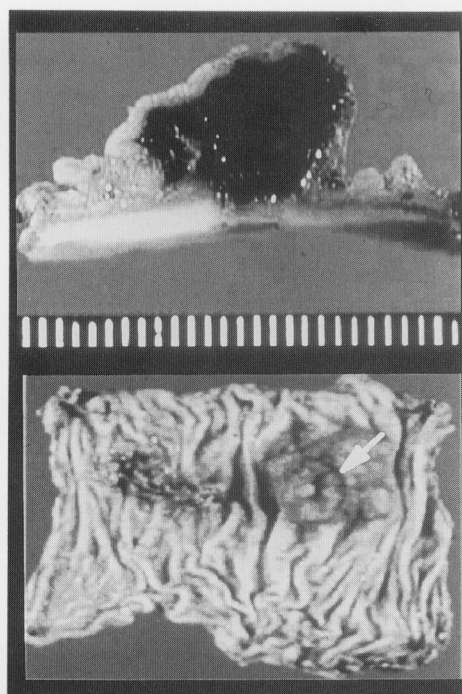


**Fig. 2** Scintigraphy with Tc-99m pertechnetate revealed no abnormal accumulation in the abdomen.

frame for 2 minutes. Static anterior images were obtained 5, 10, 20, 30, 60 min, 5 hr and 24 hr after injection. Imaging performed 5 minutes after injection revealed an abnormal accumulation, suggesting a bleeding site. Imaging 30 minutes after injection revealed an abnormal accumulation in the ileocecal region, and the radioactivity

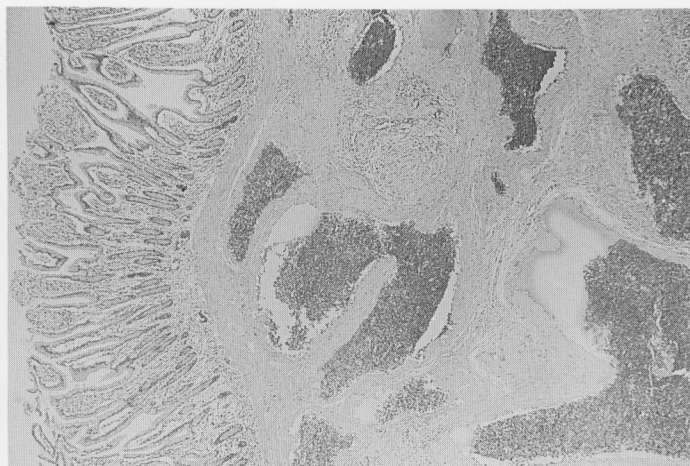


**Fig. 3** Venous-phase of superior mesenteric angiography. Pooling region of contrast medium is continuously observed (arrow).



**Fig. 4** Macroscopic view of resected specimen. Submucosal tumor with an erosion is observed (arrow). The diameter of the tumor is 15 mm.

moved gradually along the ascending colon to the transverse colon (Fig. 1). Scintigraphy with Tc-99m pertechnetate performed one week after the scintigraphy with Tc-99m-labeled red blood cells revealed no abnormal accumulation in the abdomen (Fig. 2). The venous-phase of superior mesenteric angiography revealed a pooling lesion of contrast medium (Fig. 3), but no extravasation was seen in the arterial phase. Partial resection of the small intestine was performed. On the mucosal surface of the central portion of the resected segment of the jejunum, there was a polypoid lesion with an erosion



**Fig. 5** Microscopic findings for resected specimen. Abnormal capillary vessels grew locally and modularly in the submucosal and muscle layers (hematoxylin-eosin stain;  $\times 100$ ).

measuring 15 mm in diameter (Fig. 4). A specimen of the resected tissue exhibited abnormal capillary vessels growing locally and nodularly in the submucosal and muscle layers (Fig. 5). The tumor was diagnosed as a cavernous hemangioma. The patient was discharged after an uneventful postoperative course, and no recurrence of anemia has been detected postoperatively.

### DISCUSSION

Hemangioma of the small intestine is a rare disease. Enteric hemangiomas account for 7–10% of all benign tumors of the small intestine,<sup>2,7</sup> with the jejunum being the most common location of such lesions.<sup>2</sup> Hemangiomas can be histologically classified as capillary, cavernous or mixed type. Microscopically, cavernous hemangioma is the most common, followed by roughly equal proportions of capillary and mixed types.<sup>2</sup> In our case, cavernous hemangioma was diagnosed by examining of resected tissue. Preoperative diagnosis of small bowel hemangioma can be very difficult. In a review of the Japanese literature by Akamatsu et al.,<sup>8</sup> preoperative detection was possible in 24.1% of patients by barium small bowel series, angiography, or scintigraphy.

Although diagnosis of hemangioma is established when pooling is detected by angiography or Tc-99m-labeled red blood cell scintigraphy, it was not always determined by means of these techniques whether there is bleeding from the site of the hemangioma. In our case, a pooling lesion was observed on the venous-phase of angiography corresponding to the bleeding lesion, but extravasation was not detected on the arterial phase. The reason for this appeared to be either discontinuation of bleeding when angiography was performed or an insufficient amount of bleeding for detection by angiography. The rate of bleeding detected by scintigraphy is less than that by angiography. Thorne et al.<sup>9</sup> reported that the minimal detectable

rate of bleeding is only 0.04 ml/min with scintigraphy, whereas Nusbaum et al.<sup>10</sup> reported that it is at most 0.5 ml/min with angiography.

Furthermore, Tc-99m-labeled red blood cell scintigraphy permits noninvasive as well as emergent examination so that Tc-99m-labeled red blood cells scintigraphy is the examination method of choice when gastrointestinal bleeding is found. Bleeding from the small intestine accounts for only 3–5% of bleeding from the whole gastrointestinal tract,<sup>11</sup> and bleeding from a hemangioma accounts for no more than 10% of bleeding from the small intestine.<sup>12</sup> In hemangioma, Tc-99m-labeled red blood cells accumulate in the early phase, and the accumulation increases gradually thereafter. In our case, such a finding was absent because bleeding originated in the hemangioma. Meckel's diverticulum is one of the common causes of bleeding from the small intestine.<sup>13</sup> In our case, since radioisotopic accumulation was observed in the region of the left abdomen at 5 minutes after intravenous injection of Tc-99m-labeled red blood cells, discrimination from Meckel's diverticulum was necessary.

Meckel's diverticulum is usually found on the anti-mesenteric border within the region 100 cm proximal to the ileocecal valve.<sup>14</sup> It usually contains ileal mucosa, but heterotopic tissue, such as gastric, duodenal or colonic mucosa or pancreatic tissue may be present.<sup>15</sup> Tc-99m pertechnetate is selectively accumulated and subsequently excreted into the bowel lumen by the mucoid surface cells of the gastric mucosa.<sup>16,17</sup> In our case, scintigraphy with Tc-99m pertechnetate revealed no abnormal accumulation in the abdomen. In conclusion, Tc-99m-labeled red blood cell scintigraphy was found to be useful for diagnosing of gastrointestinal bleeding, especially bleeding from the small intestine.



## REFERENCES

1. Taylor TV, Torrance HB. Hemangiomas of gastrointestinal tract. *Br J Surg* 61: 236–238, 1974.
2. Byle L, Lack EE. Solitary cavernous hemangioma of small intestine. Case report and literature review. *Arch Pathol Lab Med* 117: 939–941, 1993.
3. Winzelberg GG, Mckusick KA, Strauss HW, Waltman AC, Greenfield AJ. Evaluation of gastrointestinal bleeding by red blood cells labeled *in-vivo* with technetium-99m. *J Nucl Med* 20: 1080–1086, 1979.
4. Seto H, Kageyama M, Wu Y-W, Shimizu M, Nagayoshi T, Watanabe N, et al. Sequential subtraction scintigraphy with <sup>99m</sup>Tc-RBC for early detection of gastrointestinal bleeding. *Ann Nucl Med* 9: 203–208, 1995.
5. Yoshikai T, Yokomizo Y, Iwashita I, Okada Y, Koga H, Kudo S. Inferior mesenteric varix demonstrated by <sup>99m</sup>Tc-red blood cell gastrointestinal bleeding study. *Ann Nucl Med* 11: 163–166, 1997.
6. Sos TA, Lee JG, Wixson D, Sniderman KW. Intermittent bleeding from minute to minute in acute massive gastrointestinal hemorrhage—Arteriographic demonstration. *Am J Roentgenol* 131: 1015–1017, 1978.
7. Barkin JS, Schonfeld W, Thomsen S, Manten HD, Rogers AI. Enteroscopy and small bowel biopsy—An improved technique for the diagnosis of small bowel disease. *Gastrointest Endosco* 31: 215–217, 1985.
8. Akamatsu T, Matsuda Y, Tsugane E, Matsuzawa K, Hasebe O, Furuta S, et al. A case of multiple cavernous hemangioma of the small intestine and clinical review of Japanese literature. *J Gastroenterol* 25: 494–498, 1990.
9. Thorne DA, Datz FL, Remley K, Christian PE. Bleeding rates necessary for detecting acute gastrointestinal bleeding with Tc-99m labeled red blood cells in an experimental model. *J Nucl Med* 28: 514–520, 1987.
10. Nusbaum M, Baum S. Radiographic demonstration for unknown sites of gastrointestinal bleeding. *Surg Forum* 14: 374–375, 1963.
11. Briley CA, Jackson DC, Johnsrude IS, Mills SR. Acute gastrointestinal hemorrhage of small bowel origin. *Radiology* 136: 317–319, 1980.
12. Wilson JM, Melvin DB, Gray G, Thorbjarnarson B. Benign small bowel tumor. *Ann Surg* 181: 247–250, 1975.
13. Yanaguchi M, Takeuchi S, Awazu S. Meckel's diverticulum—Investigation of 600 patients in Japanese literature. *Am J Surg* 136: 247–249, 1978.
14. Kiesewetter WB. Meckel's diverticulum in children. *Arch Surg* 75: 914–919, 1957.
15. Leijonmarck CE, Bonman-Sandelin K, Frisell J, Raf L. Meckel's diverticulum in the adult. *Br J Surg* 73: 146–149, 1986.
16. Sfakianakis GN, Conway JJ. Detection of ectopic mucosa in Meckel's diverticulum and in other aberrations by scintigraphy: II. Indications and methods—A 10-year experience. *J Nucl Med* 22: 732–738, 1981.
17. Imaeda T, Kanematsu M, Sone Y, Iinuma G, Hirose Y, Miya K, Shimokawa K. A case of intermittent bleeding Meckel's diverticulum. *Ann Nucl Med* 4: 107–110, 1990.