

^{18}F -FDG for the staging of patients with differentiated thyroid cancer: Comparison of a dual-head coincidence gamma camera with dedicated PET

Claudia TIEPOLT,* Bettina BEUTHIEN-BAUMANN,*^{***} Reiner HLISCS,* Jan BREDOW,*^{***} Anneliese KÜHNE,*
Joachim KROPP,* Wolfgang BURCHERT*^{***} and Wolf-Gunter FRANKE*

**Department of Nuclear Medicine, Carl Gustav Carus Medical School, University of Dresden, Germany*

***Institute of Bioanorganic and Radiopharmaceutical Chemistry, Research Centre Rossendorf, Rossendorf, Germany*

Coincidence imaging with a dual-head gamma camera may offer a cost-effective alternative to dedicated PET. The aim of this study was to compare the diagnostic accuracy of coincidence imaging and PET in patients with differentiated thyroid cancer.

Thirty-one patients were studied after thyroidectomy and radioiodine ablation. They were injected with a single dose of 300 MBq ^{18}F -FDG. Scanning was performed on a dedicated PET system after 1 hr, and on a coincidence gamma camera after 4 hrs.

Based on a lesion-by-lesion comparison, coincidence imaging and PET concurred in 69% of 118 lesions. Based on lesion size, concurrence was 96% in lesions larger than 1.5 cm, and 62% in those between 1 and 1.5 cm. Lesions smaller than 1 cm could not be identified with coincidence imaging.

Identical staging was obtained with coincidence imaging and PET in 26/31 patients (84%). In four patients FDG accumulating lesions were shown by both the coincidence camera and the dedicated scanner, but not detectable with any other imaging means and were confirmed histologically on surgery.

Although a coincidence camera is technically inferior to a dedicated PET scanner, it may provide clinically useful results in situations where a lesion of sufficient size and FDG uptake is to be expected, e.g. when evaluating a known lesion for malignancy.

Key words: positron emission tomography, coincidence imaging, differentiated thyroid cancer, ^{18}F -fluorodeoxyglucose

INTRODUCTION

IN PATIENTS with differentiated thyroid cancer, positron emission tomography (PET) with ^{18}F -fluorodeoxyglucose (FDG) has been proven to provide additional diagnostic information compared to ^{131}I whole body scanning. It has been found to be particularly useful in cases of suspected local recurrence, regional lymph node metastases or distant metastatic spread. A multicentre study with 222 patients suffering from differentiated thyroid cancer dem-

onstrated a diagnostic sensitivity of 75% for FDG-PET, 50% for ^{131}I whole body scan, and 93% when both methods were combined.¹ Two studies with FDG-PET and ^{131}I whole body scan found a combined sensitivity of 95 and 86%, respectively.^{2,3} In patients with increased serum thyroglobulin levels and negative ^{131}I whole body scan, the sensitivity of FDG-PET has been shown to be 85%.⁴

A number of studies have consistently shown that sestamibi and thallium can be used to image thyroid cancer with a sensitivity and specificity that is nearly identical to FDG. But FDG-PET provides better image contrast and higher spatial resolution.^{5,6}

The availability of PET for routine clinical use is

Received April 10, 2000, revision accepted July 17, 2000.

For reprint contact: Claudia Tiepolt, M.D., Department of Nuclear Medicine, Carl Gustav Carus Medical School, Fetscherstrasse 74, 01307 Dresden, GERMANY.

E-mail: tiepolt@rcs.urz.tu-dresden.de

limited by the high price of a full-ring tomograph. The coincidence gamma camera has therefore been proposed as a cost-effective alternative to perform FDG imaging. In spite of technical limitations of gamma camera coincidence imaging, first results indicate a usefulness in clinical settings.^{7,8} But before coincidence imaging can be introduced into clinical practice, the equivalence of both imaging methods has to be demonstrated by intraindividual comparison in various diseases.

The aim of this study was to investigate the diagnostic accuracy of PET imaging with a dual-head gamma camera compared to a dedicated PET scanner with regard to the staging of patients with differentiated thyroid cancer.

MATERIALS AND METHODS

Patients

Thirty-one patients (16 women and 15 men; mean age \pm SD, 64 ± 9.3 yrs) with differentiated thyroid cancer presenting with a positive ^{131}I whole body scan ($n = 22$) and/or high thyroglobulin levels ($n = 27$) were included in this study. Nine of the patients investigated had negative radioiodine whole body scans. All patients had undergone thyroidectomy and at least two radioiodine treatments for ablation of thyroid remnants or distant metastases. ^{131}I whole body scanning, ultrasonography, chest X-ray, thyroid function tests (thyrotropin, triiodothyronine, free thyroxine), and measurement of serum thyroglobulin (immunoradiometric assay, SELco[®]Tg, Medipan Diagnostica, Selchow, Germany) were performed in all patients. According to clinical need, some patients had a CT lung scan, MRI of the neck, and X-ray imaging of various parts of their skeleton. All investigations were performed within 2 months. Informed consent was obtained from all patients. The study was performed according to the guidelines of the local ethics committee.

The histological diagnosis was papillary carcinoma in 11 patients, and follicular carcinoma in 20 patients. At the time of initial diagnosis, 20 patients had lymph node or distant metastases suspected on chest X-ray, computerized tomography, or by ultra sound. The primary staging was pT1 in 4, pT2 in 12, pT3 in 5, pT4 in 9, and pTx in 1 patient.

Study design

All patients were investigated with both dedicated PET and a coincidence camera on the same day. Prior to the injection the patients were fasted for at least 4 hours. Blood glucose levels were normal in all patients (range 3.4–7.0 mmol/l). The reference scan with a dedicated ring-tomograph was performed 60 minutes after intravenous injection of 300–370 MBq of ^{18}F -FDG. Subsequently, coincidence imaging with the dual-head gamma camera was carried out 210–240 minutes after tracer application. The feasibility of doing coincidence imaging at this stage was shown by a pilot study in a small number

of patients. Because the tumour/background ratio in this study increased from 1 to 4 hours after injection, the activity remaining at 4 hours can be used for coincidence imaging without a negative influence on lesion detectability.¹⁸ Due to a radioiodine whole body scan being performed 4 days after PET imaging, 14 patients were off levothyroxine. The remaining patients had radioiodine treatments two months before the PET imaging. It can, therefore, be assumed that there was no significant breakthrough of the 364 keV gamma ray from ^{131}I into the Compton window at the time of FDG scanning.

PET imaging

We used an ECAT Exact HR+ (Siemens/CTI, Knoxville, Tenn., USA) with BGO detectors and an axial field of view of 15.2 cm. Six bed positions overlapping 1 cm were acquired in 2D mode for 10 minutes each. The energy window was set to 350–650 keV. The image sets were reconstructed by filtered back-projection (Hann filter, cut-off 0.4).

Coincidence gamma camera imaging

A Solus EPIC MCD gamma camera (ADAC Laboratories, Milpitas, Calif., USA) with a 5/8 inch NaI crystal and an axial field of view of 38 cm was used. The acquisition matrix was 128×128 . With the coincidence camera we could not correct for attenuation, scatter or random coincidences. Imaging started when the singles count rate was below $1.5 \times 10^6/\text{s}$. Two to three bed positions covering the head, neck and chest, and overlapping 35% were acquired in three-dimensional (3D) mode with 32 angles of 40 s each. The energy windows were set at $511 \text{ keV} \pm 15\%$ for the photopeak and $310 \text{ keV} \pm 15\%$ for Compton events, respectively. Photopeak-photopeak and photopeak-Compton scatter coincidences were accepted. Reconstruction was performed with an iterative method (4 iterations, 8 ordered subsets, Wiener prefilter, noise factor of 0.7, ADAC Laboratories).

^{131}I whole body scanning

This was performed 72 hours after oral administration of a therapeutic dose of ^{131}I -NaI (3,700 MBq) for treatment of metastases with a dual-head gamma camera equipped with high-energy collimators (Genesis, ADAC Laboratories). An acquisition matrix of 512×512 and a scanning speed of 15 cm/min were used. All patients were off levothyroxine for 8 weeks, had discontinued triiodothyronine medication 2 weeks before, and had reached hypothyroidism.

Data analysis

Because the coincidence camera was not equipped with attenuation correction, uncorrected images were used for comparison of the results obtained with dedicated PET and the coincidence camera. Images obtained with both methods were read separately by two experienced inves-

tigators (CT, BB-B) who were blinded to the PET results when evaluating coincidence gamma camera scans. Data sets were interpreted on a computer screen with a linear grey scale which investigators were free to manipulate. Foci of increased FDG uptake were counted. A consensus decision was made in cases of discrepancy between the two observers. The size of each lesion was derived from the PET images by applying a 50% intensity isocontour as the outline of the tumour. The detectability and contrast of the lesions in the coincidence images compared to PET was scored on a three point scale (1 = similar to PET; 2 = visible, but inferior to PET; 3 = invisible).

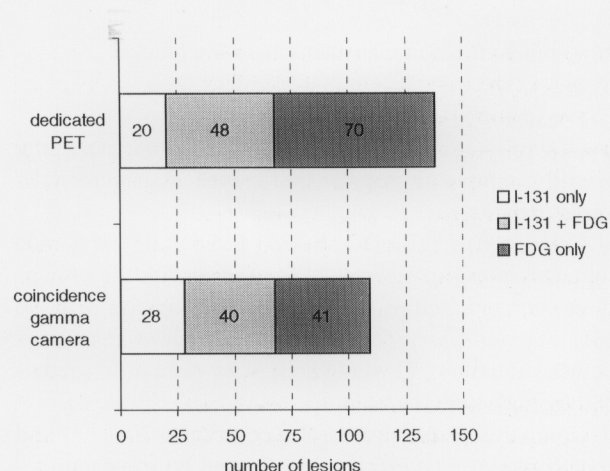


Fig. 1 Comparison of the diagnostic accuracy of coincidence camera and dedicated PET. The number of lesions accumulating ^{131}I , FDG, or both tracers, are shown.

Statistical analysis

The differences between groups (patients who were on or off levothyroxine) were tested with Fisher's exact test (95% confidence interval).

RESULTS

Combined use of FDG and ^{131}I -NaI detected 138 lesions (100%) in 31 patients. With ^{131}I whole body scan 68/138 lesions (49%) could be seen. Coincidence imaging showed 81/138 (59%), and dedicated PET 118/138 (85%) lesions. Combining coincidence imaging and ^{131}I whole body scan increased the relative sensitivity from 59 to 73%.

Twenty lesions of all 138 detected (14%) did accumulate ^{131}I -NaI only, and 70 lesions (51%) showed uptake of FDG only. Of these, 41 lesions (59%) could be detected with the coincidence gamma camera. The remaining 48 lesions (35%) accumulated both tracers (Fig. 1).

Lesion-by-lesion comparison of images obtained with dedicated PET and coincidence camera showed concordance in 69%. Analysis of different anatomical areas showed agreement in the head and neck of 60%, and 79%

Table 1 Anatomical localization of lesions imaged with the different modalities

anatomical localization	coincidence camera [n]	dedicated PET scanner [n]	^{131}I whole body scan [n]
head & neck	21	35	11
chest	54	68	34
bone	6	15	23
total	81	118	68

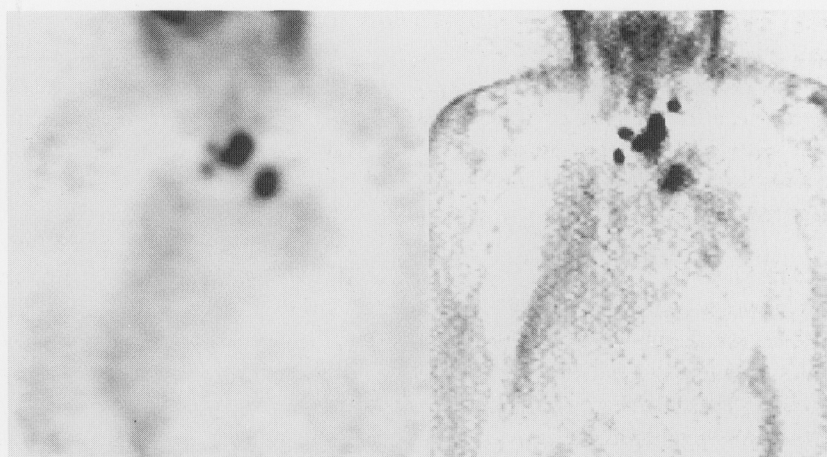

Fig. 2 A 67-year-old man with metastatic differentiated thyroid cancer. Coronal images of coincidence camera (left) and PET (right) showed increased uptake in mediastinal lymph node metastases. Whereas the contrast in the PET image was equal in all lesions, in the coincidence image it is lower in the smaller lesions. One lesion (in the left jugular region) could not be recognized in the coincidence image without knowledge of the PET results.

in the chest. Of 23 bone metastases detected by ^{131}I whole body scan, 15 lesions were revealed by dedicated PET, but only 6 by coincidence imaging (Table 1).

Analysis according to size showed that the best agreement between the two imaging methods was for lesions larger than 1.5 cm. The coincidence camera detected 96% of lesions (50/52) larger than 1.5 cm, and 62% of lesions (31/50) between 1 and 1.5 cm that were seen with the PET scanner. In contrast, 16 lesions that were smaller than 1 cm could only be imaged with the dedicated PET scanner.

Lesion contrast in images obtained with the coincidence camera was judged to be equal to the PET scanner in 40% of lesions (score 1), and inferior in 29% (score 2). Thirty-one percent of lesions were invisible in the coincidence images and scored 3. Images of a patient with several mediastinal lesions that could be detected with both techniques are shown in Figure 2, but the contrast of the smaller lesions in the coincidence image was inferior to PET. The lesion in the left jugular region could not be identified by coincidence imaging.

In patients who were on levothyroxine, 31 of 51 lesions (61%) found with the dedicated PET scanner could also be seen with the coincidence camera. In patients off

levothyroxine, the detection rate was 49 out of 66 lesions (74%). This difference was not statistically significant ($p > 0.05$).

Table 2 shows to what extent TNM staging was influenced by the result of the FDG imaging with both devices in comparison to ^{131}I whole body scan and to a combination of ^{131}I and other imaging methods. According to the TNM system the same stage as with the PET scanner could be obtained with the coincidence camera in 26/31 patients. Those metastases that were missed by coincidence imaging but were relevant to TNM staging were

- small (< 1.5 cm) mediastinal lymph nodes in two cases (in one of which the PET scan was the only diagnostic procedure showing evidence of disease activity)
- small (< 1.5 cm) metastases in the lung
- a 1 cm cervical lymph node metastasis
- a lesion in the thoracic spine,

but the misstaging of 5 patients by coincidence imaging would not have altered the therapeutic management of these patients.

Compared to ^{131}I , FDG showed additional lymph node metastases in 9 patients when imaged with the coincidence camera, and in 11 patients when imaged with the PET scanner. Three patients who had known metastases demonstrated by ^{131}I whole body scan were misstaged as M0 by both imaging methods using FDG (Table 2).

Compared to the results of a combination of ^{131}I and other imaging FDG showed additional lymph node metastases in 6 patients when imaged with the coincidence camera, and in 9 patients when imaged with the PET scanner.

The therapeutic strategy was changed as a result of the additional diagnostic information provided by the FDG

Table 2 TNM staging according to imaging modality

	coincidence camera	dedicated PET scanner	^{131}I whole body scan	^{131}I scan and conventional imaging
	[n]	[n]	[n]	[n]
N0	15	14	24	14
N1a	5	3	3	10
N1b	11	14	4	7
M0	16	13	13	10
M1	15	18	18	21

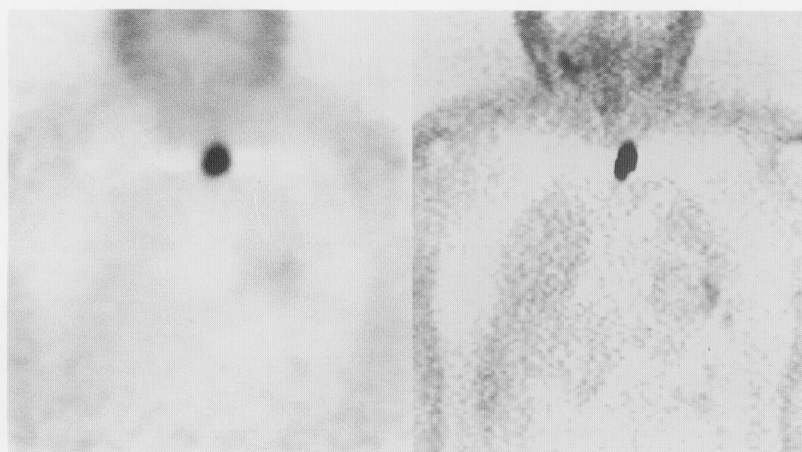

Fig. 3 A 60-year-old man was investigated with FDG because of raised thyroglobulin and (false) negative ^{131}I whole body scan. The FDG images obtained with the coincidence camera (left) and the PET scanner (right) showed increased uptake in the paratracheal region. Surgery and histology confirmed this finding.

scan in 4/31 patients. In three of these cases both the dedicated PET scanner and the coincidence camera showed radioiodine negative lymph node metastases which could subsequently be removed by surgery and were confirmed histologically (Fig. 3). In another patient coincidence imaging revealed a singular region of focally increased FDG uptake paratracheally, whereas PET imaging showed an additional right cervical focus. Both of these were histologically proven to be metastases of a papillary thyroid carcinoma at surgery.

DISCUSSION

Coincidence imaging with a modified gamma camera may offer a cost-effective alternative to a dedicated PET scanner for the imaging of oncological patients with FDG. This new technology has, however, not been fully evaluated in clinical settings, although the number of publications addressing this problem is growing steadily. Many of these studies include patients with a range of different malignancies,^{7,9-12} which will only give an impression of the overall performance of the new method. In our opinion, it is of paramount importance to have a study population with a single, well-defined disease entity. It may well be found that coincidence imaging is suitable for imaging a small group of malignancies with a particularly high FDG uptake whilst being unable to completely replace dedicated PET scanners in oncological FDG imaging. Some studies evaluating coincidence imaging in pure populations of patients with lung cancer,^{8,13} laryngeal cancer¹⁴ and breast cancer¹⁵ have been published. There is also a preliminary study in 11 patients with recurrent papillary thyroid cancer comparing FDG imaging by means of a coincidence gamma camera with ¹³¹I whole body scanning, without the use of a dedicated PET scanner as a reference method for FDG scanning.¹⁶

Technical limitations

Due to technical limitations of dual-head gamma cameras modified for coincidence imaging the probability of detecting small lesions is lower than with dedicated PET.^{11,13} In agreement with others,^{7,9,11,13,15} we found that only lesions larger than 1.5 cm could be reliably detected and that lesions smaller than 1 cm are usually undetectable (there is only one group which claims to be able to detect lesions smaller than 1 cm, and as small as 4 mm).¹⁶⁻¹⁸ The main reasons for this are limitations in usable spatial resolution and contrast as well as partial volume effects. The limited usable spatial resolution is mainly due to the restricted count rate capacity (typical values are $<1.2 \times 10^6/s$ for single events and $<1.5 \times 10^4/s$ for coincident events)¹¹ and lesser probability of detecting coincident events (which is typically around ten times higher in a dedicated system).⁹ Regarding the image contrast of the coincidence camera in a phantom study, at target/background ratios of 8 : 1 and 3 : 1 the 16 and 25 mm

sphere were the smallest that could be detected, respectively. The resolution of the dedicated PET scanner was 13 mm at both of these target/background ratios.^{19,20} Therefore, the underestimation of FDG uptake of small lesions due to partial volume effects becomes more severe in coincidence camera imaging.²¹

Another reason for the lower image quality of the coincidence gamma camera compared to PET is the different acquisition mode used in this study. Whereas coincidence gamma camera acquisition is restricted to the 3D mode, the dedicated PET device was operated in the 2D mode to improve image quality. In a 3D acquisition random and scattered coincidences will rise disproportionately with the increasing count rate. If not corrected for, contrast and spatial resolution will be decreased. In addition, the large detectors of the coincidence gamma camera have a high detection rate for photons from outside the field of view. Concurrently, this causes a high fraction of random coincidences which increases dead-time.²²

Clinical results

This study showed a relative sensitivity of 69% for coincidence imaging compared to dedicated PET. This is slightly higher than in the results published by Shreve et al. who found a relative sensitivity of 55% in 31 patients. For lesions located in the chest a nearly identical relative sensitivity of 73% was reported. The lower overall sensitivity may have been caused by the low detection rate for abdominal lesions (23%) in this heterogeneous patient population.¹¹

Regarding contrast, our results with subjective assessment on a three-point scale are in accordance with those of Weber et al.¹³ who measured tumour/background ratios for pulmonary nodules and found that the image contrast was 32% lower in coincidence gamma camera than in PET images and decreased with decreasing lesion size. For lesions smaller than 1 cm it was about 60% lower in the coincidence than in the PET images.

A German multicentre study¹ reported a higher sensitivity of FDG-PET if the patient was on suppressive thyroid hormone therapy (91% vs. 67%). In contrast, Sisson et al. found a higher FDG uptake in hypothyroidism.²³ In our study lesion detectability with coincidence camera imaging compared to PET was similar in patients on and off levothyroxine. Whether FDG imaging in patients with differentiated thyroid cancer should, in general, be performed with patients on levothyroxine remains to be clarified in further studies.

Without attenuation correction it proved difficult to assign lesions located at the border between the lung and mediastinum to one or the other anatomical structure. Due to the lower usable spatial resolution, this effect was more pronounced with the coincidence gamma camera than with the dedicated PET system. A study by Shreve et al. reported similar results.¹¹ Furthermore, the generally

poorer image quality of the coincidence camera makes distinguishing between pathological and physiological FDG uptake more difficult.¹¹ Because attenuation correction improves geometric distortion as well as edge definition of lesions it will lead to a better visualization and localization.²⁴ One study has shown that the detection of smaller lesions benefits most from attenuation correction; an increase in sensitivity from 60% to 80% was reported for lesions smaller than 2 cm.¹²

Taking into account the severe technical limitations of the coincidence imaging outlined above, it seems encouraging that 26/31 patients in our selective cohort could be staged correctly according to the TNM system with dedicated PET as a reference. In these 4 cases where only PET imaging led to a change in therapeutic strategy, the dedicated PET scanner and the coincidence gamma camera gave nearly identical results.

CONCLUSION

Although a coincidence camera is technically inferior to a dedicated PET scanner, it may provide clinically useful results in a limited number of patients, especially if a lesion of sufficient size and FDG uptake is to be expected, e.g. when evaluating a known lesion for malignancy. Nevertheless, our results clearly show that a coincidence gamma camera cannot yet fully replace a dedicated PET scanner for patients with thyroid cancer.

REFERENCES

1. Grünwald F, Källicke T, Feine U, Lietzenmayer R, Scheidhauer K, Dietlein M, et al. Fluorine-18 fluorodeoxyglucose positron emission tomography in thyroid cancer: results of a multicentre study. *Eur J Nucl Med* 26 (12): 1547–1552, 1999.
2. Dietlein M, Scheidhauer K, Voth E, Theissen P, Schicha H. Fluorine-18 fluorodeoxyglucose positron emission tomography and iodine-131 whole-body scintigraphy in the follow-up of differentiated thyroid cancer. *Eur J Nucl Med* 24 (11): 1342–1348, 1997.
3. Feine U, Lietzenmayer R, Hanke JP, Held J, Wohrle H, Müller-Schauenburg W. Fluorine-18-FDG and iodine-131-iodide uptake in thyroid cancer. *J Nucl Med* 37 (9): 1468–1472, 1996.
4. Grünwald F, Schomburg A, Bender H, Klemm E, Menzel C, Bultmann T, et al. Fluorine-18 fluorodeoxyglucose positron emission tomography in the follow-up of differentiated thyroid cancer. *Eur J Nucl Med* 23: 312–319, 1996.
5. Grünwald F, Menzel C, Bender H, Palmedo H, Willkomm P, Ruhlmann J, et al. Comparison of ¹⁸F-FDG-PET with ¹³¹I-iodine and ^{99m}Tc-sestamibi scintigraphy in differentiated thyroid cancer. *Thyroid* 7 (3): 327–335, 1997.
6. Grünwald F, Briele B, Biersack HJ. Non-¹³¹I-scintigraphy in the treatment and follow-up of thyroid cancer. Single-photon-emitters or FDG-PET? *Q J Nucl Med* 43 (3): 195–206, 1999.
7. Delbeke D, Patton JA, Martin WH, Sandler MP. FDG PET and dual-head gamma camera positron coincidence detection imaging of suspected malignancies and brain disorders. *J Nucl Med* 40 (1): 110–117, 1999.
8. Weber W, Young C, Abdel-Dayem HM, Sfakianakis G, Weir GJ, Swaney CM, et al. Assessment of pulmonary lesions with ¹⁸F-fluorodeoxyglucose positron imaging using coincidence mode gamma cameras. *J Nucl Med* 40 (4): 574–578, 1999.
9. Boren ELJ, Delbeke D, Patton JA, Sandler MP. Comparison of FDG PET and positron coincidence detection imaging using a dual-head gamma camera with 5/8-inch NaI(Tl) crystals in patients with suspected body malignancies. *Eur J Nucl Med* 26 (4): 379–387, 1999.
10. Moonsun P, Park CH, Suh JH, Koh JH. Fluorine-18 fluorodeoxyglucose imaging using dual-head coincidence positron emission tomography without attenuation correction in patients with head and neck cancer. *Clin Nucl Med* 24 (7): 495–500, 1999.
11. Shreve PD, Steventon RS, Deters EC, Kison PV, Gross MD, Wahl RL. Oncologic diagnosis with 2-[fluorine-18]fluoro-2-deoxy-D-glucose imaging: dual-head coincidence gamma camera versus positron emission tomographic scanner. *Radiology* 207 (2): 431–437, 1998.
12. Zimny M, Kaiser HJ, Cremerius U, Reinartz P, Schreckenberger M, Sabri O, et al. Dual-head gamma camera 2-[fluorine-18]-fluoro-2-deoxy-D-glucose positron emission tomography in oncological patients: effects of non-uniform attenuation correction on lesion detection. *Eur J Nucl Med* 26 (8): 818–823, 1999.
13. Weber WA, Neverve J, Sklarek J, Ziegler SI, Bartenstein P, King B, et al. Imaging of lung cancer with fluorine-18 fluorodeoxyglucose: comparison of a dual-head gamma camera in coincidence mode with a full-ring positron emission tomography system. *Eur J Nucl Med* 26 (4): 388–395, 1999.
14. Stokkel MP, Terhaard CH, Hordijk GJ, van Rijk PP. The detection of local recurrent head and neck cancer with fluorine-18 fluorodeoxyglucose dual-head positron emission tomography. *Eur J Nucl Med* 26 (7): 767–773, 1999.
15. Yutani K, Tatsumi M, Shiba E, Kusuoka H, Nishimura T. Comparison of dual-head coincidence gamma camera FDG imaging with FDG PET in detection of breast cancer and axillary lymph node metastasis. *J Nucl Med* 40 (6): 1003–1008, 1999.
16. Stokkel MP, de Klerk JHM, Zelissen PMJ, Koppeschaar HPF, van Rijk PP. Fluorine-18 fluorodeoxyglucose dual-head positron emission tomography in the detection of recurrent differentiated thyroid cancer: preliminary results. *Eur J Nucl Med* 26 (12): 1606–1609, 1999.
17. Stokkel MP, Terhaard CH, Mertens IJ, Hordijk GJ, van Rijk PP. Fluorine-18-FDG detection of laryngeal cancer postradiotherapy using dual-head coincidence imaging. *J Nucl Med* 39 (8): 1385–1387, 1998.
18. Stokkel MP, ten Broek FW, van Rijk PP. Preoperative assessment of cervical lymph nodes in head and neck cancer with fluorine-18 fluorodeoxyglucose using a dual-head coincidence camera: a pilot study. *Eur J Nucl Med* 26 (5): 499–503, 1999.
19. Andreeff M, Hliscs R, Kropp J, Beuthien-Baumann B, Tiepolt C, Oehme L, Franke WG, Linemann H, Johannsen B. Doppelkopf-Koinzidenz-Kamera im Vergleich zu einem

PET-Ringtomographen—erste physikalische Untersuchungen und klinische Erfahrungen. *Medizinische Physik* 1998, Deutsche Gesellschaft für Medizinische Physik, Dresden, 1998.

20. Kropp J, Tiepolt C, Beuthien-Baumann B, et al. F-18-FDG Positron Coincidence Tomography with a Dual Head Gamma Camera in Comparison with a Dedicated PET-Scanner. *In*: Limouris GS, Shukla SK, Bender HF, Biersack HJ, eds. *Radionuclides for Oncology. Current status and future aspects*. Athen: Mediterra, pp. 151–157, 1998.
21. Links JM. Advances in nuclear medicine instrumentation: considerations in the design and selection of an imaging system. *Eur J Nucl Med* 25 (10): 1453–1466, 1998.
22. Bailey DL, Miller MP, Spinks TJ, Bloomfield PM, Livieratos L, Young HE, et al. Experience with fully 3D PET and implications for future high-resolution 3D tomographs. *Phys Med Biol* 43 (4): 777–786, 1998.
23. Sisson JC, Ackermann RJ, Meyer MA, Wahl RL. Uptake of 18-fluoro-2-deoxy-D-glucose by thyroid cancer: implications for diagnosis and therapy. *J Clin Endocrinol Metab* 77: 1090–1094, 1993.
24. Bengel FM, Ziegler S, Avril N, Weber W, Laubenbacher C, Schwaiger M. Whole-body positron emission tomography in clinical oncology: comparison between attenuation-corrected and uncorrected images. *Eur J Nucl Med* 24 (9): 1091–1098, 1997.