

FDG PET in the clinical evaluation of sarcoidosis with bone lesions

Atsushi KOBAYASHI,* Tetsuya SHINOZAKI,* Yasuaki SHINJO,* Katsuya KATO,**
Noboru ORIUCHI,** Hideomi WATANABE* and Kenji TAKAGISHI*

*Department of Orthopedic Surgery, Gunma University Faculty of Medicine

**Department of Nuclear Medicine, Gunma University Faculty of Medicine

We report a case of sarcoidosis with osseous involvement. Whole-body fluorine-18-fluorodeoxyglucose (FDG) PET scanning demonstrated multiple sites of FDG uptake in the hilar lymph nodes, right ulna, bilateral feet, and subcutaneous tissue of the extremities. FDG PET scanning provides useful information for the detection of sarcoidosis with systemic distribution, even when osseous lesions are included.

Key words: fluorine-18-fluorodeoxyglucose, PET, sarcoidosis, bone lesions

INTRODUCTION

SARCOIDOSIS is a chronic, multisystem disease of unknown etiology most frequently affecting middle-aged persons.^{1,2} Osseous involvement is seen without symptoms.^{1,3} Until now, scintigraphy has been the most popular strategy for determination of its systemic distribution^{4,5} but, fluorine-18-fluorodeoxyglucose (FDG), which has been used in clinical PET for the diagnosis of various types of tumors and metastases,^{6,7} may also provide useful information for the detection of this disease.⁸ We report a patient suffering from sarcoidosis with osseous involvement for whom whole-body FDG PET scanning was very useful in determining the distribution of lesions.

CASE REPORT

A twenty-five-year-old woman was referred to our hospital in February 1998, complaining of pain and swelling in her left index finger in the absence of any history of trauma. She had initially noted this symptom one month previously. She had received dropping lotion for the treatment of uveitis due to sarcoidosis from December 1994 at another hospital. On physical examination, swell-

ing and tenderness were observed around the metacarpopharyngeal (MP) joint of the left index finger. The range of motion of her left MP joint was slightly limited due to the local pain and swelling. She had noticed multiple subcutaneous nodules in the bilateral upper extremities and the back. Laboratory data showed slight anemia and increase in angiotensin converting enzyme (ACE, 23.7 IU/l; normal range 8.3–21.4 IU/l) but, inflammatory reactions such as CRP and ESR were essentially within normal limits. Tests for tuberculin reaction were negative. Plain roentgenography showed osteolytic lesions within the left second metacarpus and right distal ulna (Fig. 1), although the latter was asymptomatic. Chest plain roentgenography showed bilateral hilar lymphadenopathy. Whole-body FDG PET was performed after intravenous injection of 242 MBq FDG by the simultaneous transmission emission method with a PET scanner (SET-2000W, Shimadzu, Kyoto, Japan). FDG PET demonstrated multiple sites of FDG uptake in the hilar lymph nodes, right ulna, left hand, bilateral feet, pubic bone, and subcutaneous tissue of the extremities (Fig. 2). Plain roentgenography also showed osteolytic lesions within the phalanx of bilateral toes (Fig. 3). ^{99m}Tc-MDP and ⁶⁷Ga-citrate scintigraphy were also performed. The former demonstrated uptake in the right ulna, left hand, bilateral feet, and pubic bone; the latter in the hilar lymph node, right ulna, left hand, and bilateral feet. Exploratory surgery of the metacarpal lesion of the left index finger and right ulna lesion, and subcutaneous lesion of the right upper extremity was performed in April 1998, since these lesions were clinically the most suspicious. The histology derived from

Received March 30, 2000, revision accepted June 5, 2000.

For reprint contact: Tetsuya Shinozaki, M.D., D.M.Sc., Department of Orthopedic Surgery, Gunma University Faculty of Medicine, 3-39-22 Showa Maebashi, Gunma 371-8511, JAPAN.

E-mail: tshinoza@showa.gunma-u.ac.jp

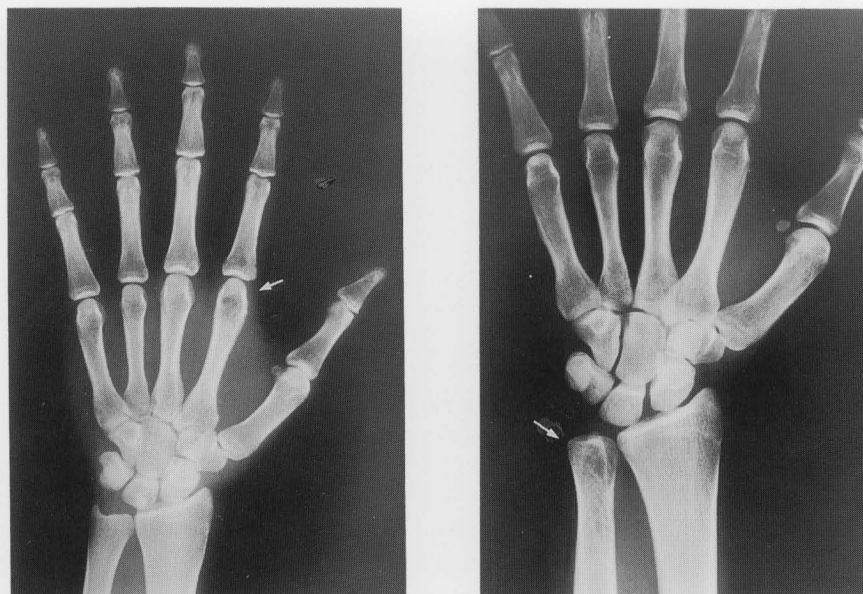


Fig. 1 Plain roentgenograph showing osteolytic lesions within the left second metacarpus and right distal ulna.

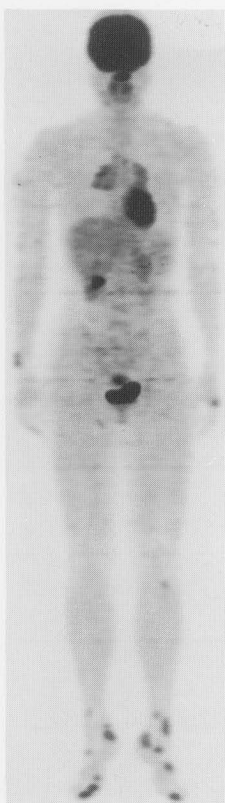


Fig. 2 Whole-body FDG PET (maximum intensity projection image) demonstrated multiple sites of FDG uptake in the hilar lymph node, right ulna, left hand, bilateral feet, pubic bone, and the subcutaneous tissue of the extremities.

bone and subcutaneous tissue was sarcoidosis showing noncaseating epithelioid-cell granulomas with giant cells. Since the operation, she is being followed as an out-patient with dropping lotion treatment for eye lesions. No steroid therapy has been prescribed due to the lack of heart and central nervous system lesions and only minor lung lesions.

DISCUSSION

Sarcoidosis is a generalized systemic disease of unknown etiology,³ and the frequency of the osseous involvement is unclear. A number of papers have indicated this to be limited^{1,3,9} with most frequent bone involvement in the small bones of the hands and feet.^{3,5,10} Involvement of large bones, spine and skull is relatively rare.³ The co-existence of skin and bone lesions is controversial, osseous sarcoidosis being more frequent in patients with chronic skin involvement in one report,³ and prevalent when there were no skin lesions in another.⁹ Our case featured multiple skin lesions mixed with small bone lesions of the hands and feet. As in our case, the most common radiographic manifestation is a reticular trabecular pattern⁹ but, this is nonspecific. Computed tomography (CT) and magnetic resonance imaging (MRI) are also useful for the detection of sarcoidosis,^{9,11,12} but only for local and not systemic lesions. Until now, for the detection of the systemic lesions, Tc-99m methylene diphosphonate (MDP) or Ga-67 citrate scintigraphy have been applied,^{4,5} but the former mainly detects bone lesions,¹³ whereas the latter is better for soft tissue lesions.¹⁴ Whole body PET scanning with fluorine-18-fluorodeoxyglucose (FDG) opened a new phase in the investigation of meta-

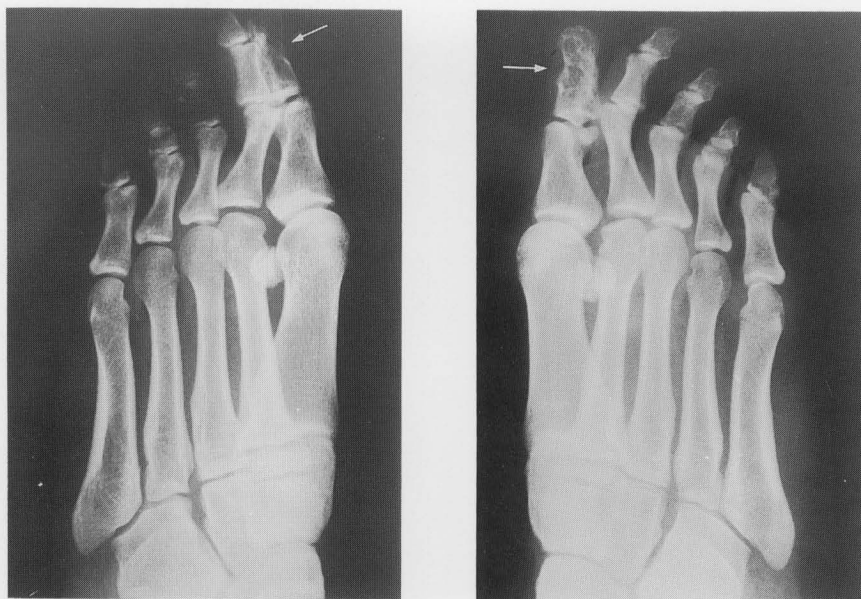


Fig. 3 Plain roentgenograph showing osteolytic lesions within the phalanx of bilateral toes.

bolic activities of systemic various organs and many disorders.⁴ It has previously been used on a patient with sarcoidosis showing FDG uptake in soft lesions.⁸ In our case, FDG uptake could be demonstrated with hilar lymphadenopathy, subcutaneous and bone lesions. This suggests that FDG PET scanning, although the uptake is nonspecific, may be a useful strategy for investigating the systemic distribution of sarcoidosis, even when bone lesions exist.

ACKNOWLEDGMENT

We thank Mr. Kiichi Osawa for his technical assistance in making the figures.

REFERENCES

1. Neville E, Walker AN, James DG. Prognostic factors predicting the outcome of sarcoidosis: an analysis of 818 patients. *Q J Med* 52 (208): 525-533, 1983.
2. Pietinalho A, Hiraga Y, Hosoda Y, Löfroos A-B, Yamaguchi M, Selroos O. The frequency of sarcoidosis in Finland and Hokkaido, Japan. A comparative epidemiological study. *Sarcoidosis* 12: 61-67, 1995.
3. Gunter B. Sarcoidosis. *Orthopedics* 18: 214-218, 1995.
4. Alavi A, Buchpiguel CA, Loessner A. Is there a role for FDG PET imaging in the management of patients with sarcoidosis? *J Nucl Med* 35: 1650-1652, 1994.
5. Pino JGD, Ulloa AD, Lovic A, Relea MF. Sarcoidosis of the hand and wrist: a report of two cases. *J Hand Surg* 22A: 942-945, 1997.
6. Aoki J, Watanabe H, Shinozaki T, Tokunaga M, Inoue T, Endo K. FDG-PET in differential diagnosis and grading of chondrosarcomas. *J Comput Assist Tomogr* 23: 603-608, 1999.
7. Watanabe H, Shinozaki T, Yanagawa T, Aoki J, Tokunaga M, Inoue T, et al. Glucose metabolic analysis of musculoskeletal tumors using fluorine-18-FDG PET as an aid to preoperative planning. *J Bone Joint Surg* 82-B: 760-767, 2000.
8. Lewis PJ, Salama A. Uptake of fluorine-18-fluorodeoxyglucose in sarcoidosis. *J Nucl Med* 35: 1647-1649, 1994.
9. Edeiken J. *Roentgen Diagnosis of Disease of Bone*. 3rd ed., Baltimore, Williams & Wilkins, pp. 808-816, 1891.
10. Landi A, Brooks D, Santis GD. Sarcoidosis of the hand-report of two cases. *J Hand Surg* 8: 197-200, 1983.
11. Bushara KO, Petermann G, Waclawik AJ, Brown WD, Schutta HS. Sarcoidosis of the spinal cord with extensive vertebral involvement: a case report. *Comput Med Imaging Graph* 19: 443-446, 1995.
12. Shinozaki T, Watanabe H, Aoki J, Fukuda T, Shirakura K, Takagishi K. Imaging features of subcutaneous sarcoidosis. *Skeletal Radiol* 27: 359-364, 1998.
13. Hoefnagel CA, Bruning PF, Cohen P, Marcuse HR, vander-Schoot JB. Detection of lung metastases from osteosarcoma by scintigraphy using ^{99m}Tc-methylene diphosphonate. *Diagn Imaging* 50: 277-284, 1981.
14. Lin WY, Kao CH, Hsu CY, Liao SQ, Wang SJ, Yeh SH. The role of Tc-99m MDP and Ga-67 imaging in the clinical evaluation of malignant fibrous histiocytoma. *Clin Nucl Med* 19: 996-1000, 1994.