

## Uncommon and dynamic changes detected by $^{123}\text{I}$ -15-(p-iodophenyl)-3-R,S-methylpentadecanoic acid myocardial single photon emission computed tomography in a stunned myocardium induced by coronary microvascular spasm

Kan ZEN,\* Kazuki ITO,\* Takato HIKOSAKA,\* Yoshihiko ADACHI,\* Satoshi YONEYAMA,\* Shuji KATO,\*  
Akihiro AZUMA,\*\* Hiroki SUGIHARA\*\*\* and Masao NAKAGAWA\*\*

*\*Department of Internal Medicine, Murakami Memorial Hospital, Asahi University*

*\*\*Second Department of Medicine and \*\*\*Department of Radiology, Kyoto Prefectural University of Medicine*

A 55-yr-old man underwent surgery. Soon after the procedure was finished, the patient complained of chest pain, and the electrocardiogram showed increase in the ST-segment in some leads. Emergency angiography showed normal coronary arteries, but there was asynergy in the left ventricle, and delayed filling of contrast medium was observed in the LCA. An intracoronary infusion of isosorbide dinitrate did not improve the delayed filling of contrast medium or ST segment increase in the electrocardiogram. Soon after nicorandil was injected into the LCA, the patient's symptoms, electrocardiogram, and delayed filling of contrast medium dramatically improved. On the second day, initial imaging by  $^{123}\text{I}$ -BMIPP myocardial SPECT showed a moderate increase in tracer uptake in the apico-antero-septal region and a moderate decrease in tracer uptake in the lateral region, in which the first left ventriculography showed akinesis, and delayed imaging revealed a moderate increase in tracer uptake in the apical region and a high washout of  $^{123}\text{I}$ -BMIPP in the antero-septal and lateral regions. On the sixth day, initial imaging by  $^{123}\text{I}$ -BMIPP myocardial SPECT showed a moderate decrease in tracer uptake in the apical and lateral regions and a mild decrease in tracer uptake in the antero-septal region, and delayed imaging revealed a moderate increase in tracer uptake in the apical region and a high washout of  $^{123}\text{I}$ -BMIPP in the antero-septal and lateral regions. By the 30th day,  $^{123}\text{I}$ -BMIPP myocardial SPECT had normalized. We consider that these dynamic changes in  $^{123}\text{I}$ -BMIPP myocardial SPECT imaging may reflect metabolic changes in fatty acids in the ischemic state, the size of the triacylglycerol pool, and the degree of turnover in the triacylglycerol pool.

**Key words:**  $^{123}\text{I}$ -BMIPP, fatty acid metabolism, myocardial ischemia, coronary microvascular spasm, nicorandil

### INTRODUCTION

RADIOIODINATED 15-(p-iodophenyl)-3-R,S-methylpentadecanoic acid ( $^{123}\text{I}$ -BMIPP) is a  $\beta$ -methyl-branched fatty acid which was developed recently.  $^{123}\text{I}$ -BMIPP is thought to be suitable for myocardial SPECT imaging

because it shows rapid blood clearance, higher uptake and longer retention in the canine heart than the straight-chain fatty acid analog iodophenyl pentadecanoic acid (IPPA). Furthermore, the quality of the myocardial images obtained with  $^{123}\text{I}$ -BMIPP is excellent, since  $^{123}\text{I}$ -BMIPP activity in the lung and liver is lower than that in the heart.<sup>1–3</sup>  $^{123}\text{I}$ -BMIPP myocardial imaging is useful for the diagnosis and evaluation of ischemic myocardial disease for the reasons stated above.<sup>3,4</sup> But the kinetics and metabolism of  $^{123}\text{I}$ -BMIPP in the myocardium have not been clarified in detail. We discuss those aspects of  $^{123}\text{I}$ -BMIPP in the post-myocardial ischemic state that was

Received January 26, 2000, revision accepted May 1, 2000.

For reprint contact: Kan Zen, M.D., Department of Internal Medicine, Murakami Memorial Hospital, Asahi University, 3–23 Hashimoto-cho, Gifu 500–8523, JAPAN.

E-mail: k-zen@dent.asahi-u.ac.jp

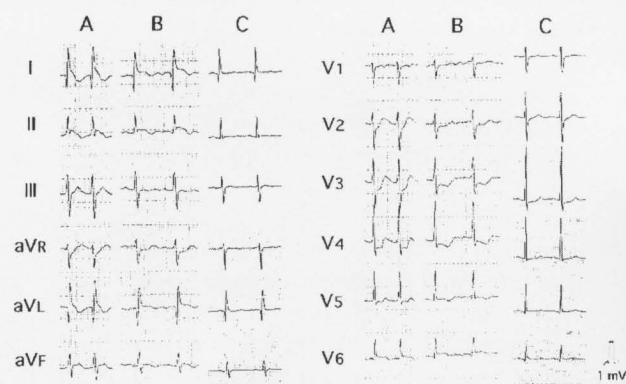
thought to be induced by coronary microvascular spasm in the case presented here.

## CASE REPORT

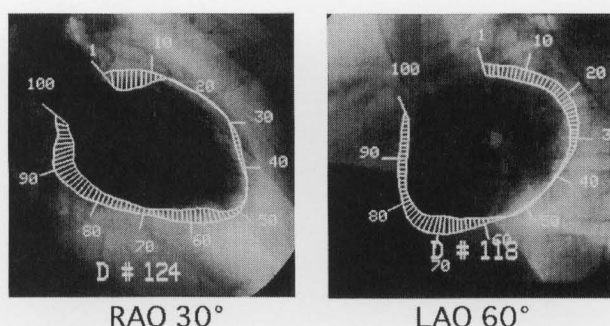
A 55-yr-old man with a 5 yr. history of liver cirrhosis was hospitalized for treatment of gastric varices. Soon after the balloon occluded-retrograde transvenous obliteration (B-RTO) procedure was finished, the patient complained of anterior chest pain. At that time, the electrocardiogram showed sustained ventricular tachycardia. Although the

cardiac rhythm had recovered to sinus rhythm after a bolus injection of lidocaine (50 mg) intravenously, the electrocardiogram showed increase in the ST-segment in leads I, II, aVL and V<sub>6</sub>, and depression of the ST-segment in leads V<sub>2</sub>–V<sub>5</sub> (Fig. 1A).

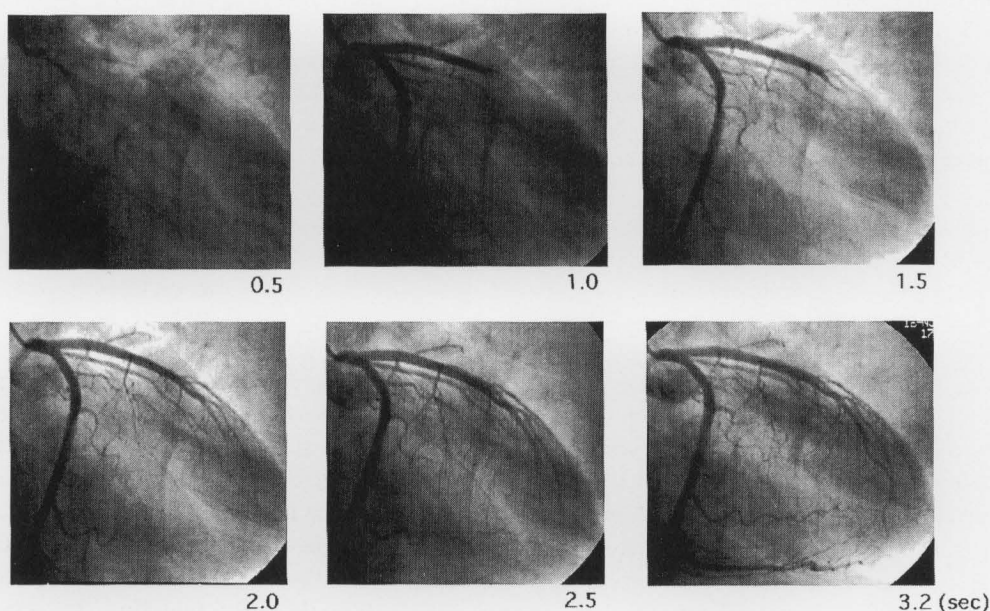
On physical examination, the patient's blood pressure was 80 over 39 mmHg, and the pulse was 134 per minute with a regular rhythm. The patient was almost in a state of shock. Laboratory examinations indicated thrombocytopenia ( $2.9 \times 10^4 /\mu\text{l}$ ), increase in transaminase (AST 87 IU/l, ALT 89 IU/l), and increase in lactate dehydrogenase. These data are compatible with the patient's liver cirrhosis. Cyclophosphokinase (CPK), CPK of the MB-fraction (CPK-MB), myosin light chain kinase and troponin T were almost within the normal range (CPK 182 IU/l, CPK-MB 28 IU/l, myosin light chain kinase 2.2 ng/ml,



**Fig. 1** Serial electrocardiograms. (A) Electrocardiogram at the onset of anterior chest pain showing increase in the ST-segment in leads I, II, aVL and V<sub>6</sub>, and depression of the ST-segment in leads V<sub>2</sub>–V<sub>5</sub>. (B) Electrocardiogram at the first angiography after intra-coronary injection of nicorandil showing improvement of ST-increase or decrease. (C) Electrocardiogram in the intensive care unit after angiography was almost normal.



**Fig. 2** Left ventriculography performed 15 minutes after the onset of anterior chest pain showing signs of akinesis in the apico-anteroseptal and lateral regions and signs of severe hypokinesis in the inferior-posterior region of the left ventricle.



**Fig. 3** Although angiography performed 15 minutes after the onset of anterior chest pain did not show any stenosis in the coronary arteries, severely delayed filling of the LCA with contrast medium was observed.

troponin T 0.20 ng/ml). The chest radiograph revealed mild cardiomegaly and lung congestion.

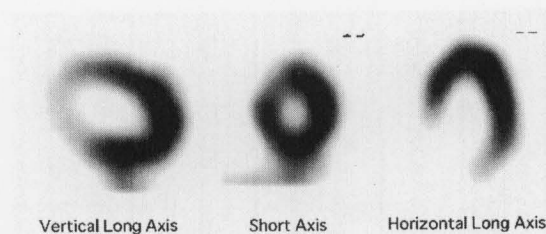
Angiography, which was performed 15 minutes after the onset of anterior chest pain, revealed no organic stenosis in the coronary arteries, akinesis in the apico-antero-septal and lateral regions or severe hypokinesis in the inferior-posterior region of the left ventricle (Fig. 2). Although the coronary artery was intact, severely delayed filling with contrast medium was observed in the left coronary artery (LCA). It took almost 3.2 seconds to visualize the peripheral epicardial arteries (Fig. 3). Although isosorbide dinitrate was injected into the LCA, the patient's symptoms, electrocardiogram, and delayed filling of the LCA with contrast medium did not improve. Soon after *N*-2-hydroxyethyl-nicotinamide nitrate (nicorandil), which has the effect of causing coronary microvascular vasodilatation, was injected into the LCA, the patient's symptoms, electrocardiogram, and delayed filling of the LCA with contrast medium dramatically improved (Fig. 1B). The electrocardiogram was almost normalized when the patient was returned to the intensive care unit after angiography (Fig. 1C).

Angiography and left ventriculography were performed again on the 14th day after the onset of anterior chest pain. Delayed filling with contrast medium was not observed in the coronary artery, and it took 1.1 seconds to visualize the peripheral epicardial arteries. No coronary artery vasospasm was evoked by intracoronary ergonovine provocation. Left ventriculography did not show any asynergy, and left ventricular wall motion was almost normal.

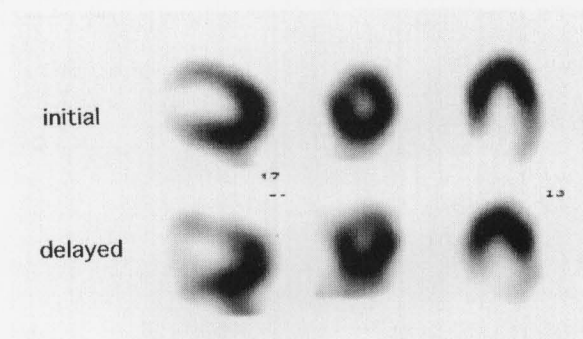
## MYOCARDIAL IMAGING

To further study the patient,  $^{99m}\text{Tc}$ -tetrofosmin and  $^{123}\text{I}$ -BMIPP myocardial SPECT imaging studies were performed after informed consent was obtained from him. While the patient was at rest, 740 MBq of  $^{99m}\text{Tc}$ -tetrofosmin was injected intravenously, and 30 minutes later images were taken. Similarly 111 MBq of  $^{123}\text{I}$ -BMIPP was injected intravenously, and 15 minutes and 3 hours later initial and delayed images were taken under fasting and resting conditions.  $^{99m}\text{Tc}$ -PYP and  $^{201}\text{Tl}$  myocardial SPECT imaging studies were also performed simultaneously on the fourth day after the onset of anterior chest pain. While the patient was at rest, 740 MBq of  $^{99m}\text{Tc}$ -PYP was injected intravenously, and 100 minutes later, 111 MBq of  $^{201}\text{Tl}$  was injected intravenously, and then dual imagings of  $^{99m}\text{Tc}$ -PYP and  $^{201}\text{Tl}$  were taken simultaneously 20 minutes later. All SPECTs were performed without intravenous infusion of catecholamine. In addition, the washout rate was taken as the percent change in cardiac  $^{123}\text{I}$ -BMIPP activity from initial to delayed imaging. The half-life of  $^{123}\text{I}$  was not corrected.

$^{99m}\text{Tc}$ -tetrofosmin myocardial SPECT performed 2 hours after the onset of anterior chest pain did not indicate any decrease in tracer uptake (Fig. 4).



**Fig. 4**  $^{99m}\text{Tc}$ -tetrofosmin myocardial SPECT performed 2 hours after the onset of anterior chest pain did not show any decrease in tracer uptake.

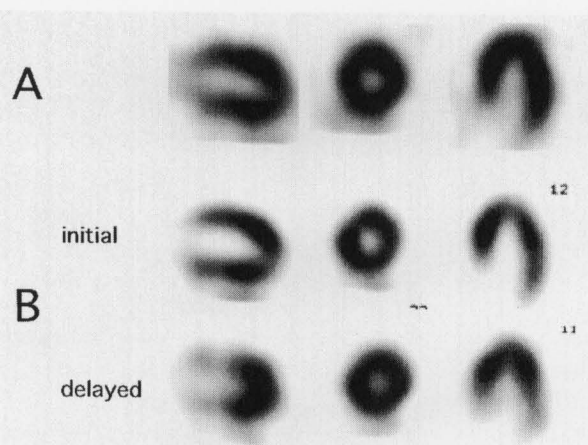


**Fig. 5**  $^{123}\text{I}$ -BMIPP myocardial SPECT performed 20 hours after the onset of anterior chest pain: the initial imaging indicated a moderate increase in tracer uptake in the apico-antero-septal region and a moderate decrease in tracer uptake in the lateral region. The delayed imaging revealed a moderate increase in tracer uptake in the apical region and a high washout of  $^{123}\text{I}$ -BMIPP in the antero-septal and lateral regions.

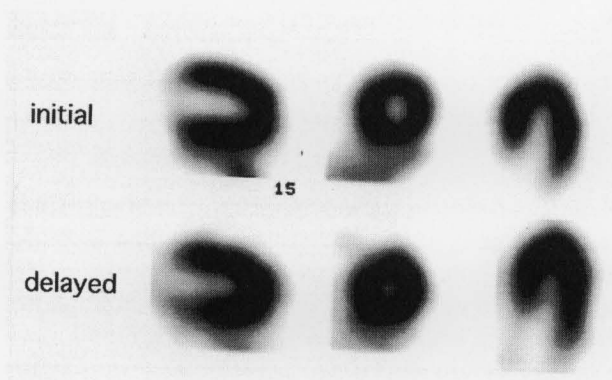
In  $^{123}\text{I}$ -BMIPP myocardial SPECT performed 20 hours after the onset of anterior chest pain, initial imaging indicated a moderate increase in tracer uptake in the apico-antero-septal region and a moderate decrease in tracer uptake in the lateral region, in which the first left ventriculography showed akinesis, and delayed imaging revealed a moderate increase in tracer uptake in the apical region and a high washout of  $^{123}\text{I}$ -BMIPP in the antero-septal and lateral regions (Fig. 5). The washout rate was about 12% for the whole left ventricle, which was lower than the normal average ( $22 \pm 3\%$ ) for this hospital, and the rate was 11% in the apical region.

On the fourth day after the onset of anterior chest pain,  $^{99m}\text{Tc}$ -PYP and  $^{201}\text{Tl}$  myocardial dual SPECT was performed, and the imagings did not show any uptake of  $^{99m}\text{Tc}$ -PYP or any decrease in  $^{201}\text{Tl}$  (Fig. 6A). Because there was no typical enzymatic evidence of acute myocardial infarction, as indicated above, these imagings were not compatible with acute myocardial infarction.

$^{123}\text{I}$ -BMIPP myocardial SPECT was performed on the sixth day after the onset of anterior chest pain. In contrast to the initial  $^{123}\text{I}$ -BMIPP myocardial SPECT imagings taken 20 hours after the onset of anterior chest pain, initial



**Fig. 6** (A)  $^{99m}\text{Tc}$ -PYP and  $^{201}\text{Tl}$  myocardial dual SPECT performed on the fourth day after the onset of anterior chest pain did not show any uptake of  $^{99m}\text{Tc}$ -PYP or any decrease of  $^{201}\text{Tl}$ . The  $^{99m}\text{Tc}$ -PYP SPECT is not shown. (B)  $^{123}\text{I}$ -BMIPP myocardial SPECT performed on the sixth day after the onset of anterior chest pain: the initial imaging showed a moderate decrease in tracer uptake in the apical and lateral regions and a mild decrease in tracer uptake in the antero-septal region. The delayed imaging revealed a moderate increase in tracer uptake in the apical region and a high washout of  $^{123}\text{I}$ -BMIPP in the antero-septal and lateral regions.



**Fig. 7**  $^{123}\text{I}$ -BMIPP myocardial SPECT performed on the 30th day after the onset of anterior chest pain showed no decrease in tracer uptake on either initial or delayed images.

imaging on the sixth day showed a moderate decrease in tracer uptake in the apical and lateral regions and a mild decrease in tracer uptake in the antero-septal region, in which the first left ventriculography showed signs of akinesis. Nevertheless, delayed imaging continued to reveal a moderate increase in tracer uptake in the apical region and showed a high washout of  $^{123}\text{I}$ -BMIPP in the antero-septal and lateral regions (Fig. 6B). The washout rate was about 14% for the whole left ventricle, which remained lower than the normal average ( $22 \pm 3\%$ ) for this hospital, and the rate was 12% in the apical region.

$^{123}\text{I}$ -BMIPP myocardial SPECT performed on the 30th day after the onset of anterior chest pain showed no decrease in tracer uptake on either initial or delayed images (Fig. 7). The washout rate in the whole left ventricle was 26%, which was within the normal limits at this hospital.

## DISCUSSION

In the present case, a dynamic and unpredictable change in  $^{123}\text{I}$ -BMIPP myocardial SPECT imaging was observed, which has not been reported before in humans to the best of our knowledge. To understand this dynamic change in  $^{123}\text{I}$ -BMIPP myocardial SPECT imaging, we must consider the kinetics and metabolism of  $^{123}\text{I}$ -BMIPP in the myocardium. Accumulating evidence about the regulation of fatty acids in the heart suggests that the concentration of  $^{123}\text{I}$ -BMIPP in the myocardium is regulated by the following 5 main factors<sup>5-7</sup>: (i) the CD36 molecule which is expressed on the myocardium and acts as a transporter of long-chain fatty acids; (ii) back diffusion from the myocardial cytosol to the blood in the early stage; (iii) accumulation in the endogenous triacylglycerol (TG) pool; (iv) conversion to  $^{123}\text{I}$ -p-iodophenylacetic acid (PIPA) as the end product through successive cycles of  $\alpha$ - and  $\beta$ -oxidations; (v) back diffusion from the TG pool to the blood in the late stage. After steadying of the early back diffusion from the myocardium to the blood, a portion of the  $^{123}\text{I}$ -BMIPP accumulates in the TG pool, and the rest is converted to PIPA through  $\alpha$ - and  $\beta$ -oxidations in the mitochondria. The pathway of the back diffusion in the late stage, however, is not well understood. Although the fatty acid metabolism is considered to be impaired in accordance with the degree of ischemia, in the ischemic state there are discrepancies in the response between the metabolism in the mitochondria and that in the TG pool.<sup>5</sup> The function of the mitochondria and TG pool are lost and will never be restored in a state of myocardial cell necrosis, but it has been reported that in reperfused rat hearts the TG pool responsively expands in the acute stage in spite of severe suppression of mitochondrial function.<sup>5</sup> The expanded TG pool will take in the excessive free fatty acids in the blood, which have been shown both clinically and experimentally to promote and accelerate life-threatening arrhythmias,<sup>8,9</sup> impair membrane integrity and suborganelle performance,<sup>10,11</sup> and depress myocardial contractility.<sup>12,13</sup> This responsive expansion of the TG pool disappears a few days after reperfusion,<sup>5</sup> but it is unclear whether the size of the TG pool becomes smaller than the original size or not. In the subacute stage of the stunned myocardium, it has been reported that  $^{123}\text{I}$ -BMIPP myocardial imaging and positron emission tomography (PET) with  $^{11}\text{C}$ -palmitic acid, which is considered to be a reliable agent for the quantification of regional fatty acid utilization, causes decreased tracer uptake, and  $^{18}\text{F}$ -fluorodeoxyglucose (FDG) PET imaging



showed increased tracer uptake.<sup>14,15</sup> This indicates that it is not fatty acid metabolism but rather aerobic glucose metabolism, that mainly produces the energy in the myocardium during the subacute stage of myocardial ischemia. But examination during the chronic stage has disclosed that there is improvement in the decreased tracer uptake in the <sup>123</sup>I-BMIPP myocardial imaging and <sup>11</sup>C-palmitic acid PET imaging, and that <sup>18</sup>F-FDG PET imaging showed decreased tracer uptake.<sup>14,15</sup> These findings show that it is not aerobic glucose metabolism, but rather fatty acid metabolism, that mainly produces the energy during the chronic stage.

In this patient, the increase in the ST-segment in leads I, II, aV<sub>L</sub> and V<sub>6</sub> and depression of the ST-segment in leads V<sub>2</sub>–V<sub>5</sub> shown on the electrocardiogram, the akinesis in the apico-anteroseptal and lateral regions and the severe hypokinesis in the inferior-posterior region of the left ventricle shown on the first left ventriculography suggested that a broad area of the left ventricular myocardium was in a state of severe ischemia, especially in the region supplied by the LCA. The severely delayed filling of the LCA with contrast medium was further evidence of myocardial ischemia in those regions.<sup>16</sup> Nevertheless, no enzymatic evidence of acute myocardial infarction was detected, <sup>99m</sup>Tc-PYP SPECT did not indicate any uptake of <sup>99m</sup>Tc-PYP in the myocardium, and the left ventricular wall motion normalized early. Although these characteristics are typical of stunned myocardium, the cause of the myocardial ischemia remains unknown. No organic stenosis was observed in the coronary artery, and no coronary artery vasospasm was evoked by intracoronary ergonovine provocation, but anterior chest pain, ST-increase or decrease shown on the electrocardiogram, and delayed filling of the LCA with contrast medium shown on the first angiography were dramatically improved by intracoronary infusion of nicorandil. These facts make us strongly suspect that the myocardial ischemia was caused by coronary microvascular spasm, because nicorandil causes coronary microvascular vasodilatation. It also has been reported that nicorandil might have a direct vasodilatory effect on the coronary microvasculature in patients with microvascular angina.<sup>17</sup> Since it is also thought that abnormal cardiac autonomic activity might play a role in the occurrence of microvascular angina or coronary microvascular spasm,<sup>17,18</sup> the fact that the patient had just undergone the B-RTO procedure and was therefore in a stressed condition also suggested that coronary microvascular spasm caused by endogenous catecholamines induced myocardial ischemia. Although it has been reported that excessive secretion of endogenous catecholamines by pheochromocytomas or excessive invasion during surgical operations could cause a decline in left ventricular wall motion or bring about ST depression, increase or other effects on the electrocardiogram,<sup>19,20</sup> it is not possible to explain why in the present case the severely delayed filling with contrast medium was ob-

served in the LCA or why the intracoronary injection of nicorandil improved the symptoms, the electrocardiogram abnormality, and the delayed filling with contrast medium. Moreover, although this was the third B-RTO procedure for this patient, no complications had been seen previously. If we had examined the amount of lactic acid in venous blood from the coronary sinus, or measured coronary flow reserve with a Doppler guidewire with intracoronary acetylcholine provocation, we could have obtained more evidence of myocardial ischemia, which we suspect was induced by coronary microvascular spasm. We also think that it would have been informative to evaluate whether exercise-induced myocardial ischemia was positive or not in this patient. Because this patient was in a state of severe thrombocytopenia, there was little possibility of intracoronary thrombosis of various origins. Because <sup>99m</sup>Tc-tetrofosmin myocardial SPECT performed 2 hours after the onset of anterior chest pain and <sup>201</sup>Tl myocardial SPECT performed on the fourth day after the onset of anterior chest pain did not show any reduced tracer uptake, it was considered that the blood supply to the myocardium had become normal by then.

Although the left ventricular wall motion showed signs of severe hypokinesis or akinesis 15 minutes after the onset of anterior chest pain, initial imaging by <sup>123</sup>I-BMIPP myocardial SPECT performed 20 hours after the onset of anterior chest pain showed a moderate increase in tracer uptake in the apico-anteroseptal region. These findings suggest that the TG pool in the myocardium had increased responsively, probably due to a neurohumoral factor (catecholamines or something similar) produced during the acute myocardial ischemic period. Nishimura et al. reported a canine occlusion and reperfusion model in which <sup>123</sup>I-BMIPP showed greater uptake than thallium, and they concluded that the initial image of <sup>123</sup>I-BMIPP myocardial SPECT reflected the change in the TG pool size in the ischemic state.<sup>21</sup> But initial imaging by <sup>123</sup>I-BMIPP myocardial SPECT performed 20 hours after the onset of anterior chest pain showed a moderate decrease in tracer uptake in the lateral region, in which the first left ventriculography showed an akinesis-like apico-anteroseptal region. The difference between the apico-anteroseptal region and the lateral region in tracer uptake suggests that there was a difference between the apico-anteroseptal region and the lateral region in the degree of myocardial ischemia. Straeter-Knowlen et al. reported that the degree of TG accumulation in the myocardium might change according to the degree of myocardial ischemia.<sup>22</sup> And, if coronary microvascular spasm occurred randomly as to time and space, there would be a difference in tracer uptake at that time. In addition, delayed imaging revealed a moderate increase in tracer uptake in the apical region, which might indicate fill-in in the endocardial region. The washout rate was 12% in the whole left ventricle, which was lower than the average for patients in Murakami Memorial Hospital. These findings

suggest that not only the fatty acid metabolism in the mitochondria but also the late back diffusion from the TG pool to the blood was suppressed in the acute period of myocardial ischemia. That might serve to protect the myocardium against life-threatening arrhythmias,<sup>8,9</sup> impaired membrane integrity and suborganelle performance,<sup>10,11</sup> and depressed myocardial contractibility promoted or accelerated by excessive free fatty acids in the blood.<sup>12,13</sup> Also, contrary to our expectations, the washout rate declined uniformly throughout the whole left ventricle area in spite of the segmental difference in left ventricular wall motion. This is probably because neuro-humoral factors influenced the whole left ventricle area, but delayed imaging showed high washout of <sup>123</sup>I-BMIPP in the antero-septal and lateral regions at that time. This is probably because the degree of TG accumulation in the myocardium in the early stages and the random occurrences of microvascular spasm as to time and space influenced the delayed imaging. Although the use of <sup>123</sup>I-BMIPP has increased in clinics, to the best of our knowledge no similar case in humans has yet been reported, which is probably because <sup>123</sup>I-BMIPP is usually performed in the subacute period of myocardial ischemia.

On the sixth day after the onset of anterior chest pain, the initial image of <sup>123</sup>I-BMIPP myocardial SPECT showed a moderate decrease in tracer uptake in the apical and lateral regions and a mild decrease in tracer uptake in the antero-septal region. Contrary to our expectations, although the delayed image showed a high washout of <sup>123</sup>I-BMIPP in the antero-septal and lateral regions, the tracer uptake in the apical region came to increase moderately or strongly. It is generally thought that the initial image in the subacute period of myocardial ischemia shows reduced uptake of <sup>123</sup>I-BMIPP, and the delayed image shows a high washout of <sup>123</sup>I-BMIPP, mainly in the ischemic myocardial region. The initial image results might indicate a reduction in the expanded TG pool and a severely suppressed state of mitochondrial function. And, the difference between apical, lateral and antero-septal regions in tracer uptake might be caused by the difference in the degree of myocardial ischemia in the early stages or the difference in the time of recovery from myocardial ischemia. The delayed image of the apical region might indicate that the late back diffusion of <sup>123</sup>I-BMIPP from the TG pool to the blood remained suppressed. To the best of our knowledge, no similar case in humans has yet been reported, which is probably because the degree and duration of myocardial ischemia, and the degree of reperfusion of the myocardium will influence the metabolism of <sup>123</sup>I-BMIPP inside and outside the myocardium.

Left ventriculography performed on the 14th day after the onset of anterior chest pain showed no asynergy and the left ventricular wall motion was normalized. If we examined the <sup>123</sup>I-BMIPP myocardial SPECT, the initial image would show severely reduced tracer uptake mainly in the apico-antero-septal region and the lateral region, and

the delayed image would disclose high washout in the same region. This is referred to by us as "memories of myocardial ischemic damage."<sup>23</sup> Improvement in the wall motion probably indicated a recovery of energy production in the mitochondria of the myocardium. Because the <sup>123</sup>I-BMIPP myocardial SPECT showed a gradual decrease in tracer uptake, we supposed that the energy was produced not by fatty acid metabolism but by aerobic glucose metabolism. As shown above, experiments with FDG PET proved this speculation to be correct. The deterioration in the <sup>123</sup>I-BMIPP myocardial SPECT results might indicate the disappearance of the expanded TG pool, or a reduction in the size of the TG pool compared with the normal state. The high washout in the delayed imaging also was probably caused not by an increase in fatty acid metabolism but by an increase in late back diffusion of the <sup>123</sup>I-BMIPP from the TG pool to the blood, a process that was suppressed during the acute stage to protect against life-threatening arrhythmias,<sup>8,9</sup> impaired membrane integrity and suborganelle performance,<sup>10,11</sup> and depressed myocardial contractibility.<sup>12,13</sup> A similar high washout on delayed <sup>123</sup>I-BMIPP myocardial SPECT imaging was reported in stunned myocardium caused by vasospastic angina.<sup>24</sup>

A case of stunned myocardium without infarction in which the tracer uptake in the <sup>123</sup>I-BMIPP myocardial SPECT was reduced, reportedly improved after 1 month.<sup>24</sup> Similarly, in the present case, both initial and delayed <sup>123</sup>I-BMIPP myocardial SPECT imagings normalized by the 30th day after admission. These findings may be explained by the fact that energy was produced not by aerobic glucose metabolism but by fatty acid metabolism in the mitochondria, and that the function and size of the TG pool had recovered.

## CONCLUSION

The present case showed remarkably uncommon and dynamic changes in <sup>123</sup>I-BMIPP myocardial SPECT imagings and is considered as noteworthy in understanding the kinetics and metabolism of <sup>123</sup>I-BMIPP in the myocardium. Moreover, although myocardial ischemia induced by coronary microvascular spasm has rarely been reported and is very difficult to prove, it was strongly suspected that coronary microvascular spasm induced the myocardial ischemia in this case. We suggest that initial <sup>123</sup>I-BMIPP myocardial SPECT imaging reflects the size of the TG pool, and delayed imaging reflects the degree of turnover in the TG pool, which could be regulated by the fatty acid metabolism in the mitochondria. As in this case, the period in which <sup>123</sup>I-BMIPP myocardial SPECT is performed must be considered in estimating the degree of ischemic damage. In addition, although the first left ventricular wall motion showed signs of akinesis in the apico-antero-septal and lateral regions of the left ventricle, some segmental differences in tracer uptake were observed in

this case. These findings suggest that there was a difference in the degree of myocardial ischemia or a difference in time in the process of recovery from myocardial ischemia that we could not detect by left ventriculography or the electrocardiogram. Delayed  $^{123}\text{I}$ -BMIPP myocardial SPECT imaging could be useful for circumstantial evaluation of fatty acid metabolism.

## REFERENCES

1. Reske SN, Sauer W, Machulla HJ, Knust J, Winkler C. Metabolism of 15 (p- $^{123}\text{I}$ -iodophenyl-) pentadecanoic acid in heart muscle and non cardiac tissue. *Eur J Nucl Med* 10: 228–234, 1985.
2. Goodmann MM, Kirsch G, Knapp FF Jr. Synthesis and evaluation of radioiodinated terminal p-iodophenyl-substituted alpha- and beta-methyl branched fatty acids. *J Med Chem* 27: 390–397, 1984.
3. Knapp FF Jr, Ambrose KR, Goodmann MM. New radioiodinated methyl-branched fatty acids for cardiac studies. *Eur J Nucl Med* 12: S39–S44, 1986.
4. Tamaki N, Kawamoto M, Yonekura Y, Fujibayashi Y, Takahashi N, Konishi T, et al. Regional metabolic abnormality in relation to perfusion and wall motion in patients with myocardial infarction: Assessment with emission tomography using an iodinated branched fatty acid analog. *J Nucl Med* 33: 659–667, 1992.
5. Lopaschuk GD, Belke DD, Gamble J, Itoi T, Schonekess BO. Regulation of fatty acid oxidation in the mammalian heart in health and disease. *Biochem Biophys Acta* 1213: 263–276, 1994.
6. Yamamichi Y, Kusuoka H, Morishita K, Shirakami Y, Kurami M, Okano K, et al. Metabolism of iodine-123-BMIPP in perfused rat hearts. *J Nucl Med* 36: 1043–1054, 1995.
7. Tanaka T, Okamoto F, Sohmiya K, Keishiro K. Lack of myocardial iodine-123 15-(p-iodophenyl)-3-R,S-methyl-pentadecanoic acid (BMIPP) uptake and CD36 abnormality. *Jpn Circ J* 61: 724–725, 1997.
8. Oliver MF, Kurien VA, Greenwood TW. Relation between serum-free-fatty-acids and arrhythmias and death after acute myocardial infarction. *Lancet* 1: 710–714, 1968.
9. Corr PB, Gross RW, Sobel BE. Amphipathic metabolites and membrane dysfunction in ischemic myocardium. *Circ Res* 55: 135–154, 1984.
10. Katz AM, Messineo FC. Lipid-membrane interactions and the pathogenesis of ischemic damage in the myocardium. *Circ Res* 48: 1–16, 1984.
11. Liedtke AJ. Alteration of carbohydrates and lipid metabolism in the acutely ischemic heart. *Prog Cardiovasc Dis* 23: 321–336, 1981.
12. Mjos OD. Effect of free fatty acids on myocardial function and oxygen consumption in intact dogs. *J Clin Invest* 50: 1386–1389, 1978.
13. Liedtke AJ, Nellis SH, Neely JR. Effects of excess free fatty acids on ischemic myocardium in swine. *Circ Res* 43: 652–661, 1978.
14. Hendrickx GR, Wijns W, Vogelaers D, Dogrieck Y, Bol A, Vandeplasse G, et al. Recovery of regional contractile function and oxidative metabolism in stunned myocardium induced by 1-hour circumflex coronary artery stenosis in chronically instrumented dogs. *Circ Res* 72: 901–913, 1993.
15. Tsubokawa A, Lee JD, Shimizu H, Nakano A, Usui H, Takeuchi M, et al. Recovery of perfusion, glucose utilization and fatty acid utilization in stunned myocardium. *J Nucl Med* 38: 1835–1837, 1997.
16. Ito K, Shudo T, Kohno Y, Asayama J, Katume H, Nakagawa M, et al. A case of myocardial ischemia associated with delayed opacification of the left anterior descending artery. *Kokyu to Junkan* 42: 1211–1215, 1994.
17. Chen JW, Lee WL, Lin SJ, Ting CT, Wang SP, Chang MS. Effects of short-term treatment of nicorandil on exercise-induced myocardial ischemia and abnormal cardiac autonomic activity in microvascular angina. *Am J Cardiol* 80: 32–38, 1997.
18. Maeda N, Hiraoka H, Kobayashi H, Yamashita S, Takemura K, Matsuzawa Y. Acetylcholine-induced coronary microvascular vasospasm in a patient with angina pectoris and normal coronary angiogram. *Angiology* 48: 995–999, 1997.
19. Elian D, Harpaz D, Sucher E, Kaplinsky E, Motro M, Vered Z. Reversible catecholamine-induced cardiomyopathy presenting as acute pulmonary edema in a patient with pheochromocytoma. *Cardiology* 83: 118–120, 1993.
20. Sugano S, Asahara T, Enoki M, Takeda J, Sugi K, Masuyama Y. Two cases of suspected catecholamine-induced cardiomyopathy associated with surgical operations. *Kokyu to Junkan* 46: 409–414, 1998.
21. Nishimura T, Sago M, Kihara K, Oka H, Shimonagata T, Katabuchi T, et al. Fatty acid myocardial imaging using  $^{123}\text{I}$ - $\beta$ -methyl-iodophenyl pentadecanoic acid (BMIPP): comparison of myocardial perfusion and fatty acid utilization in canine myocardial infarction (occlusion and reperfusion model). *Eur J Nucl Med* 15: 341–345, 1989.
22. Straeter-Knowlen IM, Evanochko WT, Balschi JA, Caulfield JB, Ku DD, Pohost GM, et al.  $^1\text{H}$  NMR spectroscopic imaging of myocardial triglycerides in excised dog hearts subjected to 24 hours of coronary occlusion. *Circulation* 93: 1464–1470, 1996.
23. Ito K, Sugihara H, Terada K, Matumoto K, Taniguchi Y, Ohtsuki K, et al. Assessment of myocardial fatty acid metabolism in patients with vasospastic angina using  $^{123}\text{I}$ -BMIPP myocardial SPECT. *KAKU IGAKU (Jpn J Nucl Med)* 32: 1099–1106, 1995.
24. Tanaka K, Ito K, Kinoshita N, Nakagawa M, Terada K, Kajita Y, et al. Importance of the delayed  $^{123}\text{I}$ -BMIPP image for detecting myocardial metabolic abnormality induced by transient myocardial ischemia: a case of vasospastic angina. *KAKU IGAKU (Jpn J Nucl Med)* 34: 229–235, 1997.