

## Accumulation of technetium-99m pertechnetate in a patient with metastases of thyroid carcinoma

Yuka YAMAMOTO,\* Yoshihiro NISHIYAMA,\* Yuko ONO,\* Katashi SATOH,\*  
Motoomi OHKAWA,\* Yukiko KAWASAKI\*\* and Masatada TANABE\*

*Departments of Radiology of \*Kagawa Medical University  
and \*\*Asada General Hospital*

Accumulation of both Tc-99m pertechnetate and radioiodine upon scintigraphy in thyroid carcinoma and/or in its metastases is a rare occurrence. In this paper we describe a patient who was taken to surgery for left lobectomy of the thyroid with follicular adenocarcinoma and who had accumulation of both I-131 and Tc-99m pertechnetate in lung metastases. The accumulation of I-131 was less than that of Tc-99m pertechnetate. The use of Tc-99m pertechnetate for imaging for diagnosis of functioning thyroid metastases is discussed.

**Key words:** thyroid carcinoma, Tc-99m pertechnetate, I-131

### INTRODUCTION

THYROID CARCINOMA and its metastases are usually delineated as a cold defect on scintigraphic images with radioiodine and Tc-99m pertechnetate but several cases showing an accumulation of radioiodine and/or Tc-99m pertechnetate in thyroid carcinoma<sup>1-3</sup> and/or in its metastases<sup>4-10</sup> have been described. In the present report, a case of follicular thyroid adenocarcinoma is presented. The patient had undergone left lobectomy and had accumulation of both Tc-99m pertechnetate and I-131 in metastatic lesions.

### CASE REPORT

A 58-year-old woman was admitted to our hospital, because of a several month history of coughing. The patient had undergone a left hemithyroidectomy for a follicular adenocarcinoma of the left thyroid 4 years previously, and had subsequently received 64 Gy radiation therapy to the neck. Since then thyroid hormone replacement was not done.

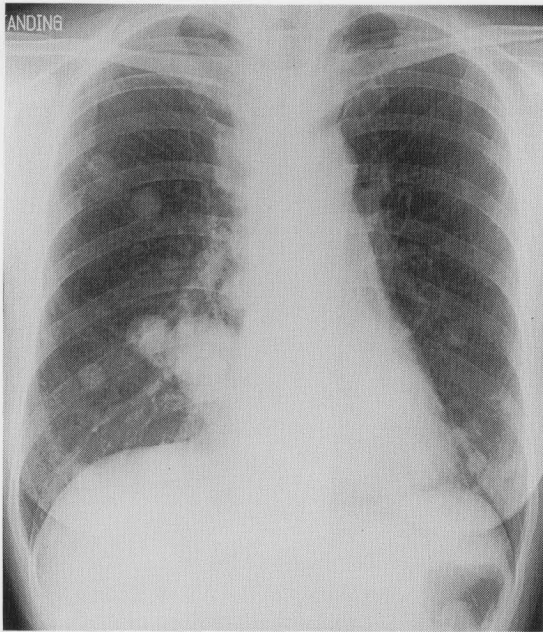
Upon admission, serum free T3 was normal, but serum free T4 was decreased to 0.45 ng/dl (normal: 0.9-1.80) and TSH was increased to 21.9  $\mu$ IU/ml (normal: 0.34-3.50), suggesting hypothyroidism. A serum thyroglobulin level of 23,900 ng/ml was indicative of metastasis of thyroid carcinoma. On physical examination, a right thyroid lobe was palpated in the right neck. No other palpable masses or adenopathies were present. Chest X-ray showed multiple nodules in the lung (Fig. 1). The largest mass was 4 cm in diameter. A biopsy of the lung nodule was performed which demonstrated metastatic carcinoma of the thyroid.

A whole-body scan with Tc-99m pertechnetate, 15 minutes after the injection of 185 MBq (5 mCi), revealed accumulation not only in the right thyroid lobe but also in the multiple lung metastases (Fig. 2). These findings suggested functioning thyroid metastases. The right thyroid lobe seemed to have a normal configuration. Another whole-body scan with I-131, 24 hours after the oral administration of 185 MBq (5 mCi), showed extensive functioning thyroid tissue in the right lobe and lung metastases (Fig. 3). A comparison of the two scans showed Tc-99m pertechnetate to be the better imaging agent. The patient was subsequently given 5.5 GBq (150 mCi) of I-131 for ablation of the residual right thyroid lobe and metastases. She is being followed up with periodic radioiodine therapy.

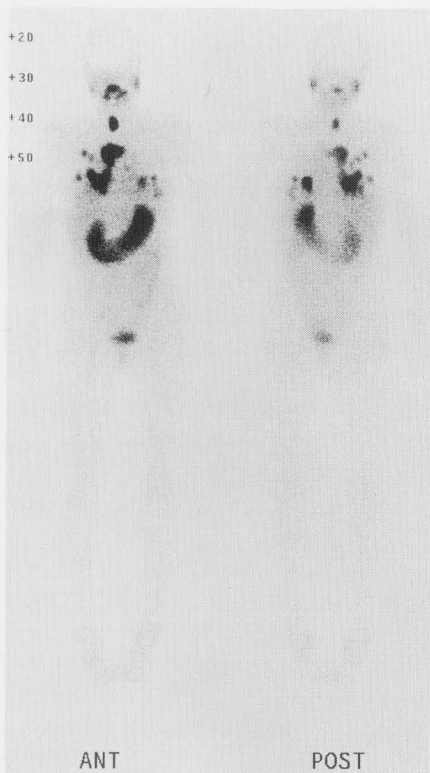Received June 3, 1999, revision accepted July 29, 1999.

For reprint contact: Yuka Yamamoto, M.D., Department of Radiology, Kagawa Medical University, 1750-1 Ikenobe, Miki-cho, Kita-gun, Kagawa 761-0793, JAPAN.

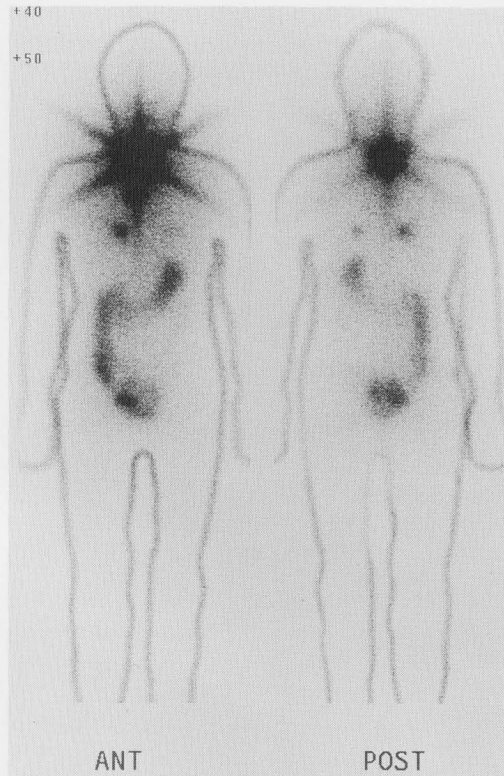E-mail: yuka@kms.ac.jp



**Fig. 1** Chest X-ray shows multiple nodular shadows in the lung of the case with thyroid carcinoma.



**Fig. 2** Whole-body image with Tc-99m pertechnetate shows accumulation in the right thyroid lobe and in the multiple lung nodules.



**Fig. 3** Whole-body image with I-131 shows intense radioactivity in the thyroid and in the multiple lung nodules. However, the number of metastases revealed on this image is less than those show on Tc-99m pertechnetate image (Fig. 2).

### DISCUSSION

I-131 and Tc-99m pertechnetate commonly do not show signs of accumulation in thyroid carcinoma and/or its metastases but a number of cases of thyroid carcinoma that showed accumulation of radioiodine and/or Tc-99m pertechnetate in the primary and/or metastatic lesions.<sup>1-10</sup> Cases in which tumors without removal of normal thyroid tissue showed signs of accumulation of both Tc-99m pertechnetate and radioiodine have rarely been reported.<sup>2,3,7</sup> Usually, in the presence of normal thyroid tissue, the uptake of radioiodine in the cancerous tissue is extremely poor.<sup>11</sup> Katagiri et al.<sup>3</sup> reported a case of follicular adenocarcinoma of the thyroid with neck lymph node metastasis, in which the thyroid tumor and the metastatic lymph node were delineated on images with both I-131 and Tc-99m pertechnetate.

Although the patient described in the present report had undergone radiotherapy in the neck region, the uptake of both I-131 and Tc-99m pertechnetate was seen in the right thyroid lobe. The remainder of the thyroid was therefore considered to contain functioning thyroid tissue. The tumor tissue in the lung was considered to have the ability to trap both Tc-99m pertechnetate and I-131 but the Tc-99m pertechnetate image was superior to the I-131 image.

Some reports suggest that Tc-99m pertechnetate is superior to radioiodine for the preoperative detection of extrathyroidal metastases.<sup>4,5</sup> The pertechnetate ion becomes trapped only in the follicular cells and, unlike iodine, does not become organified or incorporated into thyroid hormone. This may account for discordant Tc-99m pertechnetate and I-131 imaging.<sup>4</sup>

The present case is extremely unusual in that extensive lung metastases were identified with both Tc-99m pertechnetate and I-131 whereas the right thyroid gland had functioning tissue, but comparison between the two images showed Tc-99m pertechnetate to be the better imaging agent. Nevertheless, if the patient had undergone total thyroidectomy, the images with I-131 might have shown more extensive accumulation in the multiple lung metastases.

These observations stimulate speculation about the potential role of Tc-99m pertechnetate scintigraphy in the evaluation of metastases of the thyroid carcinoma, in the search for the ability to trap iodine ion.

### REFERENCES

1. Turner JW, Spencer RP. Thyroid carcinoma presenting as a pertechnetate "hot" nodule, but without <sup>131</sup>I uptake: case report. *J Nucl Med* 17: 22-23, 1976.
2. Tech KE, Davis L, Dworkin H. Papillary thyroid carcinoma concentrating both Tc-99m sodium pertechnetate and I-131 iodine case report and review of the literature. *Clin Nucl Med* 16: 497-500, 1991.
3. Katagiri M, Suzuki S, Sadahiro S, Kubouchi K, Ohmura T, Tsumura O, et al. Accumulation of iodine-131 and technetium-99m pertechnetate in thyroid carcinoma. *Clin Nucl Med* 13: 276-279, 1988.
4. Donoghue GD, Steinbach JJ, Winterberger AR. Unusual Tc-99m and I-123 images in metastatic thyroid adenocarcinoma. *Clin Nucl Med* 4: 468-470, 1979.
5. Bouvier J-F, You E, Peau J-Y, Chassard J-L, Lahneche B-E. Diffuse uptake of technetium-99m pertechnetate in a patient with metastases from thyroid carcinoma. *Clin Nucl Med* 11: 728-729, 1986.
6. Campbell CM, Khafagi FA. Insensitivity of Tc-99m pertechnetate for detecting metastases of differentiated thyroid carcinoma. *Clin Nucl Med* 15: 1-4, 1990.
7. Ryo UY, Stachura ME, Schneider AB, Nichols R, Cogan SR, Pinsky S. Significance of extrathyroidal uptake of Tc-99m and I-123 in the thyroid scan: concise communication. *J Nucl Med* 22: 1039-1042, 1981.
8. Kumaresan K, Sastry RA. Localization of Tc-99m pertechnetate in lymph node metastasis from occult thyroid carcinoma. *Clin Nucl Med* 19: 1112, 1994.
9. Krausz Y, Horne T. Detection of metastatic thyroid carcinoma by <sup>99m</sup>Tc-pertechnetate in the presence of hyperfunctioning thyroid tissue. *J Surg Oncol* 44: 132-134, 1990.
10. Vieras F. Preoperative scintigraphic detection of cervical metastases from thyroid carcinoma with technetium-99m pertechnetate. *Clin Nucl Med* 10: 567-569, 1985.
11. Lamberigts G, Roo MD, Devos P, Burie D. Tc-99m-pertechnetate scanning in metastatic thyroid carcinoma: a case report. *Clin Nucl Med* 6: 172-174, 1981.
12. Beierwaltes WH. The treatment of thyroid carcinoma with radioactive iodine. *Semin Nucl Med* 8: 79-94, 1978.