

## Testicular lymphoma with bone/bone marrow metastases illustrated by scrotal sonography, spinal MRI, and total body Tc-99m HMDP and Tc-99m MIBI imagines

Wei-Jen SHIH,\* Deborah S. KWOLEK\*\* and Barbara LAHR\*\*\*

*\*Nuclear Medicine Service, \*\*Medical Service and \*\*\*Radiology Service,  
Lexington VA Medical Center,  
and Nuclear Medicine Section, Department of Diagnostic Radiology  
and Department of Medicine, University of Kentucky  
Medical Centers, Kentucky, USA*

An 83-year-old man with testicular lymphoma demonstrated progressive scrotal enlargement with non-homogeneity sonographically and abnormally increased uptake in the scrotum of Tc-99m HMDP and Tc-99m MIBI scintigraphically. Extensive bone/bone marrow metastases were exhibited by Tc-99m MIBI and Tc-99m HMDP scintigraphies and MRI of the spine. In addition, focal/tubular activity of the femoral bone marrow on Tc-99m MIBI imaging was consistent with skeletal scintigraphic findings. It is emphasized that Tc-99m MIBI total body imaging enabled the demonstration of testicular lymphoma as increased uptake and the illustration of skeletal/bone marrow metastases as diffuse and/or focal increased uptake, especially focal/tubular MIBI activity of the femoral marrow.

**Key words:** testicular mass, non-Hodgkin's lymphoma B-cell type, bone marrow metastases, Tc-99m HMDP bone imaging, Tc-99m MIBI imaging, MRI, sonography

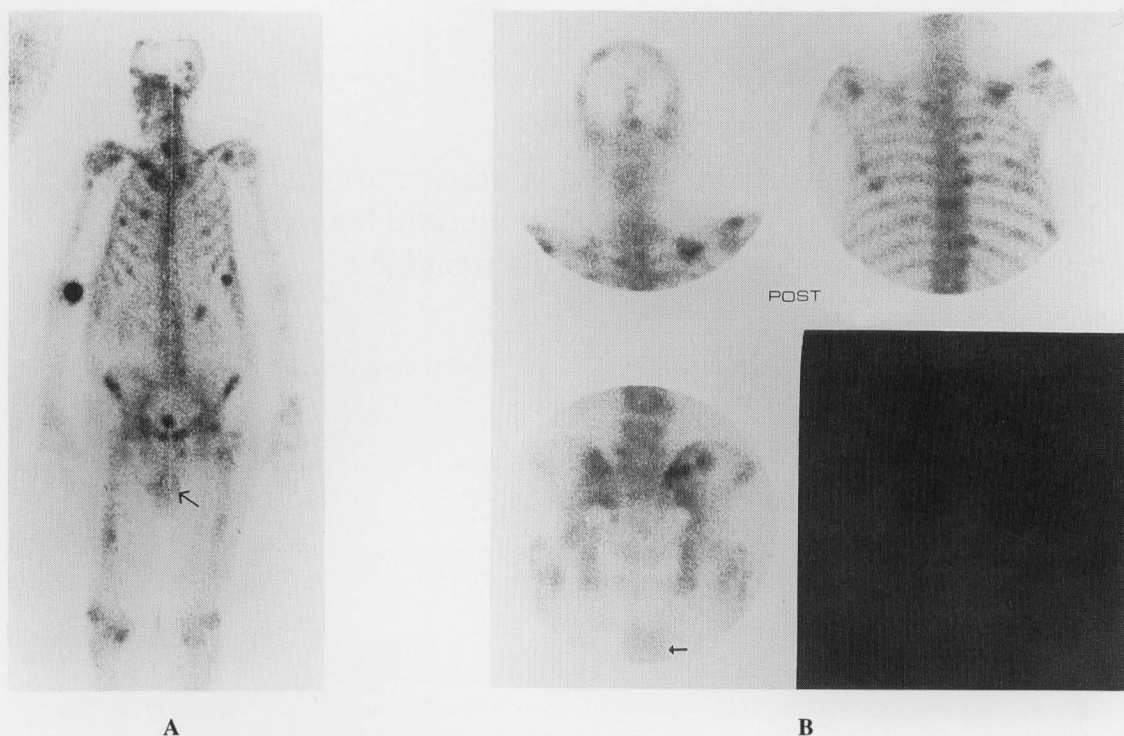
### CASE REPORT

AN 83-year-old man was admitted with the chief complaint of fatigue, malaise and enlargement of the scrotum. The patient was also found to have hypercalcemia (calcium 14.3 mg/dl,  $n = 9-10.6$ ; ionized calcium 6.67 mg/dl,  $n = 4.5-5.3$ ). An extensive laboratory work-up included HCG, alpha-fetoprotein, PSA, and liver function tests; all of which were all normal. Bone images using Tc-99m HMDP (performed on the 9th hospital day) showed multiple areas of increased uptake in the skull, spine, scapulae, ribs, pelvic bones and femurs; incidentally, increased radioactivity in the scrotum in anterior and posterior images is noted (Figs. 1A and 1B). Radiographs of the lumbar spine showed extensive lumbar spondylosis. Then the patient was referred to Nuclear Medicine Service for total body Tc-99m MIBI imaging and multiple spot im-

ages (performed on the 13th hospital day); the images showed diffuse and multiple focal areas of increased uptake in the skull, ribs, spine and femur; and intense diffuse increased uptake in the scrotum (Figs. 2A and 2B&C). Prostate biopsy was negative for malignancy. Sonographic examination of the scrotum (done on the 14th hospital day) revealed a large left testicle measuring  $5 \times 5$  cm, with mild heterogeneity of the parenchyma and a focal predominantly low echogenic area; a moderate size of hydrocele is present (Fig. 3A). Retrospectively, the patient had undergone a sonography of the scrotum two months previously, which showed diffuse homogeneous testicular enlargement on the left measuring  $3.2 \times 3.8$  cm (Fig. 3B). The patient underwent bone marrow biopsy from the right posterior iliac crest. Microscopic examination of the marrow showed bone marrow with involvement by non-Hodgkin's lymphoma, large cell type, B-cell phenotype, consistent with a large cell lymphoma, non-Hodgkin's, B-cell phenotype. The patient's mental status deteriorated with bilateral lower extremity edema, which was worse on the left one, and very little

Received April 26, 1999, revision accepted June 2, 1999.

For reprint contact: Wei-Jen Shih, M.D., Nuclear Medicine Service, VA Medical Center, Lexington, KY 40511, USA.



**Fig. 1** A: Tc-99m HMDP total body bone image shows multiple areas of increased uptake in the skull, proximal humeri, ribs, and pelvic bones; in addition, areas of increased uptake are seen in the femora. Mild but diffuse uptake of the scrotum is indicated by an arrow. B: Tc-99m HMDP posterior spot images of the skull, posterior thorax, posterior lumbar spine, and pelvis show multiple irregular areas of increased uptake in the skull, spine, ribs, and iliac bones. Mild and diffuse increased activity in the scrotum as indicated by an arrow is noted.

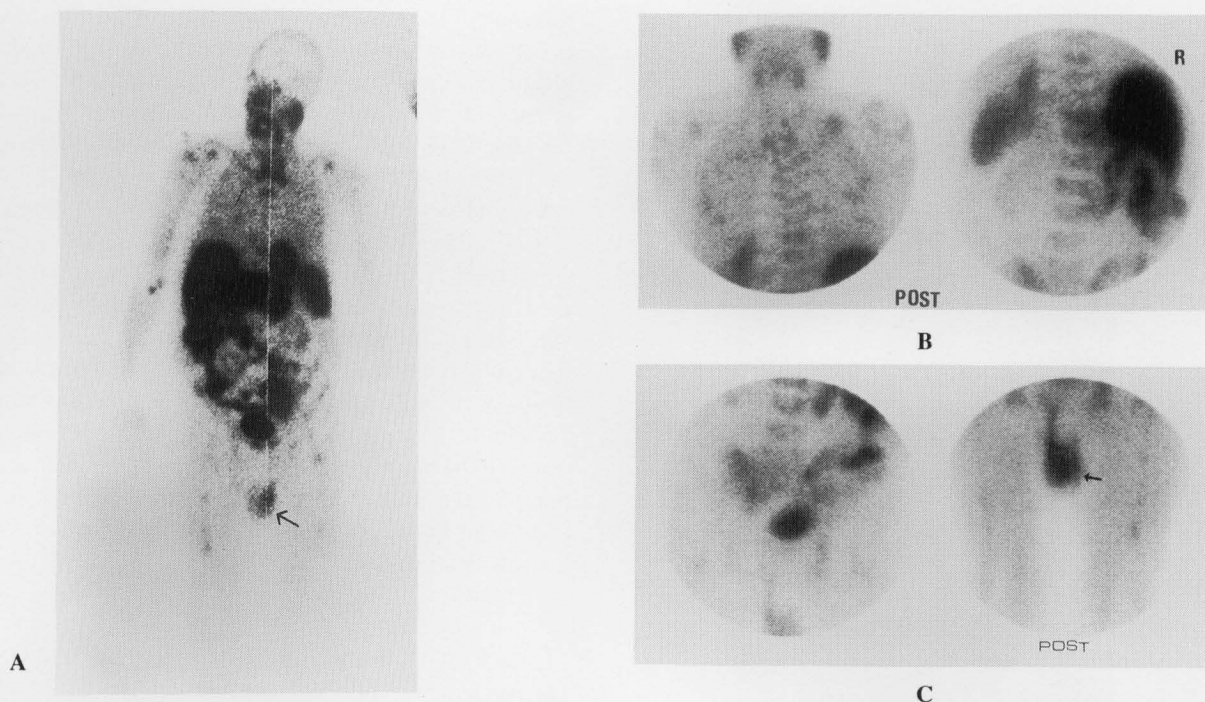
voluntary movement. Because of the possibility of isolated spinal meningeal deposits or cord compression, MRI of the spine was performed on the 31st hospital day. A T1-weighted sagittal MRI of the spine showed multiple areas of relative hypointensity replacing the relatively hyperintense fatty marrow in the cervical, thoracic, and lumbar segments of the spine; there were no meningeal deposits and no cord compression was demonstrated (Fig. 4). The patient was referred for evaluation of palliative radiation therapy to the left testicle. The patient completed 800 cGy divided into two fractions (performed on the 34th and 35th hospital day) but died one week after the radiation.

## DISCUSSION

Tc-99m MIBI, an alternative radiopharmaceutical for myocardial perfusion study, has been proposed for use as a tumor-imaging agent. The localization of Tc-99m MIBI has been described in malignant or benign tumors such as in the breast,<sup>1-3</sup> parathyroid,<sup>4,5</sup> thyroid,<sup>6</sup> lung,<sup>7,8</sup> brain,<sup>9,10</sup> and primary cardiac lymphoma.<sup>11</sup> Our patient's testicular lymphoma, as demonstrated by progressive enlargement on consecutive scrotal sonographies showed intensive uptake with Tc-99m MIBI.

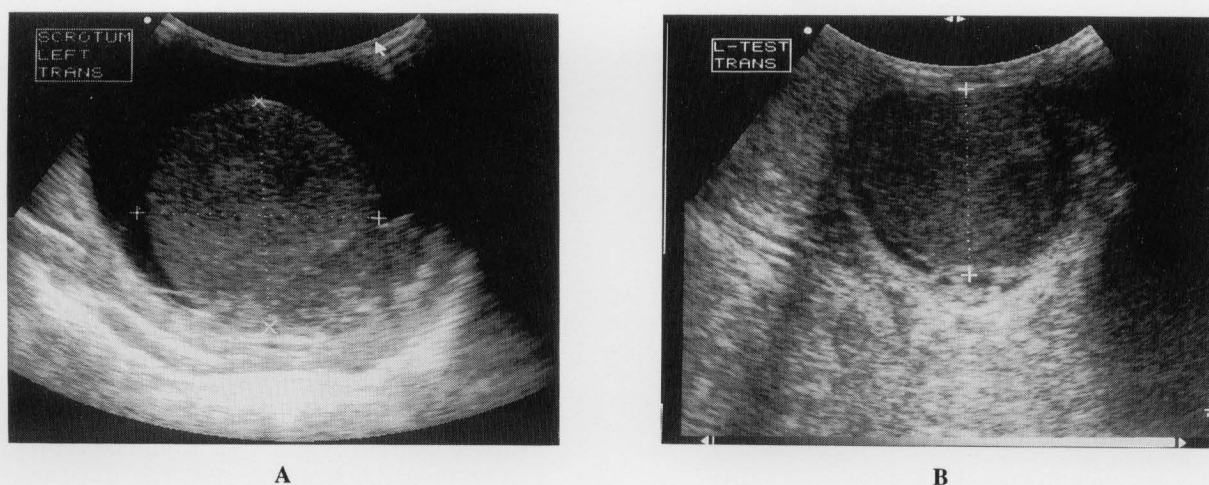
In addition, bone/bone marrow metastases exhibited by Tc-99m MIBI scintigraphy, especially in both femurs were manifested by tubular/focal activity. It has been reported that tubular/focal femoral activity with Tc-99m MIBI scintigraphy has been considered as a marker of bone marrow malignancy.<sup>12</sup> Our patient's Tc-99m MIBI tubular/focal femoral activity was consistent with bone imaging.

In comparison between anterior total body bone image (Fig. 1A) and anterior total body Tc-99m MIBI images (Fig. 2A), the lesions of both femora and upper humeri were agreeable. The detectable abnormalities of the ribs of the thorax, lower sternum, and pelvis was less favorable: Tc-99m MIBI imaging did not delineate well as compared with the bone imaging. This is due to that activity of the liver, heart, spleen, and bowel masked these abnormalities. The lesions of the ribs and sternum in the upper thorax on both imaging modalities were compatible but the lesions were easily detectable on bone scan. This is again probably due to relatively higher soft tissue background. The lesions in the skull were more distinct and delineated on the bone scan. Tc-99m MIBI for the malignant neoplasm of the left testicle was apparent than that of the bone scan. As compared with Tc-99m MIBI spot images (Figs. 2B&C), spot bone images (Fig. 1B)



**Fig. 2** A: Tc-99m MIBI total body anterior image shows areas of increased uptake in the skull, proximal humeri, and focal/tubular activity (an arrow) in the femora. Femoral tubular/focal activity is concordant to the bone imaging shown in Figure 1A.

B&C: Tc-99m MIBI posterior spot images show areas of abnormal uptake in the upper thoracic vertebrae, increased uptake in the lower thoracic vertebrae, iliac bones, and intense uptake in the scrotum (an arrow). Again focal/tubular activity in femoral bone marrow is seen.



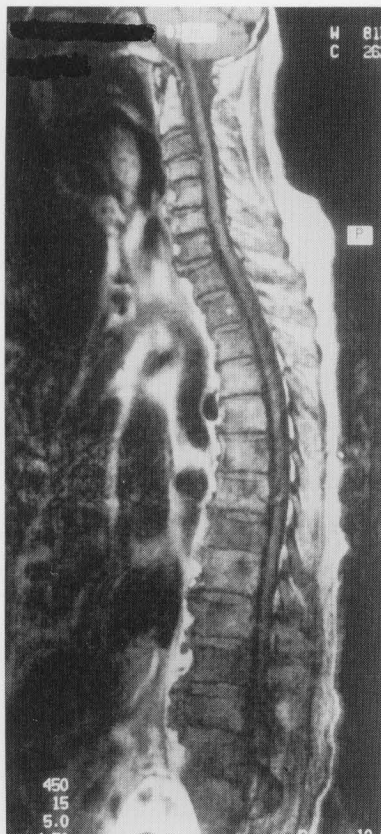**Fig. 3** A: A transverse sonography of the scrotum shows a large left testicle measuring 5 × 5 cm, with mild heterogeneity of the parenchyma and a focal predominantly low echogenic area; a moderate size of hydrocele is present. B: Scrotal transverse sonography performed two months prior to one in the Figure 3A shows diffuse homogeneous enlargement of the left testicle; the scrotal mass measures 3.2 × 3.8 cm.

showed more apparent and distinct lesions in the ribs, scapulae, and pelvis. Vertebral bodies involvement in the thoracic and lumbar spine of Tc-99m MIBI images manifested by diffusely increased uptake while in bone image there was diffuse uptake in the one of thoracic vertebrae: this finding might be due compression fracture and was

not necessary representing metastatic disease.

These similarity and dissimilarity might result in different localization mechanisms of the two radiopharmaceuticals. It is understandable that the mechanism of bone imaging localization on a bone scan is dependent on osteoblastic activity upon etiology involving the bone





**Fig. 4** T1-weighted sagittal MRI of the spine shows multiple areas of relative hypointensity replacing the relatively hyperintense fatty marrow in the cervical, thoracic, and lumbar segments of the spine.

tissue, while MIBI localization depends on the agent being taken up by mitochondria of malignant tumor cells. Accordingly, positive uptake on Tc-99m MIBI scintigraphy is presumably more specific and earlier for tumor depiction as compared with bone imaging study.

In adults femoral marrow consists mainly of fatty tissue, and the detection of abnormal MIBI activity is easier in the femoral marrow as compared with the vertebrae, sternum, pelvis, and ribs, which retain much cellular or red-marrow,<sup>12,13</sup> and MIBI shows mild and diffuse marrow activity. Besides, normal MIBI localizes in an oral cavity and thyroid gland, myocardium, liver and bowel that might obscure the marrow activity of the sternum, ribs, the cervical, thoracic, and lumbar vertebrae, and pelvic bones. Bone marrow activity of the femurs can be easily detected by anterior and posterior projections, such in our patient's tubular and focal activity in the femora (Fig. 2) is well delineated.

In Caner et al.<sup>14</sup> comparative Tc-99m MDP and Tc-99m MIBI study of malignant bone lesions, five patients with metastatic bone disease were included in 42 cases of malignant bone pathologies; 4 of the 5 patients with metastatic bone lesions were visualized by Tc-99m MIBI

images.<sup>14</sup> Homogeneous localization of Tc-99m MIBI in the bone marrow in two patients with diffuse myelodysplastic processes has been reported.<sup>15</sup> Therefore, interpretation of the diffuse pattern of Tc-99m MIBI uptake for bone/bone marrow metastases should be differentiated from myelodysplastic disease.

In summary, the patient's scrotal lymphoma progressively enlarged as documented by his consecutive sonographies, and its widespread bone/bone marrow metastases were evidenced by a bone marrow biopsy. Tc-99m MIBI total body imaging exhibited intense uptake in the scrotal lymphoma, diffuse uptake in the thoracic and lumbar vertebrae, and focal/tubular activity of both femora. Tc-99m MIBI localization in the scrotal lymphoma appeared to be more apparent as compared with bone scintigraphy. Femoral tubular/focal activity as concordant to bone scan findings may be used as a marker of bone marrow malignancy.

## REFERENCES

1. Lu G, Shih W-J, Huang H-Y, et al. Tc-99m MIBI mammoscintigraphy of breast masses: early and delayed imaging. *Nucl Med Commun* 16: 150-156, 1995.
2. Khalkhali I, Mena I, Jouanne E, et al. Prone scintimammography in patients with suspicion of carcinoma of the breast. *J Am Coll Surg* 178: 491-497, 1994.
3. Burak Z, Argon M, Memis A, et al. Evaluation of palpable breast masses with Tc-99m MIBI: A comparative study with mammography and ultrasonography. *Nucl Med Commun* 15: 604-612, 1994.
4. O'Doherty MJ, Kettle AG, Wells P, et al. Parathyroid imaging with technetium-99m sestamibi: preoperative localization and tissue uptake studies. *J Nucl Med* 33: 313-318, 1992.
5. Lu G, Shih W-J, Xiu J-Y. Tc-99m MIBI uptake in recurrent parathyroid carcinoma and brown tumors. *J Nucl Med* 36: 811-813, 1995.
6. O'Driscoll CM, Baker F, Casey MJ, et al. Localization of recurrent medullary thyroid carcinoma with technetium-99m-methoxybutylisonitrile scintigraphy: a case report. *J Nucl Med* 32: 2281-2283, 1991.
7. Hassan IM, Sahweil A, Constantinides C, et al. Uptake and kinetics of Tc-99m hexakis 2-methoxyisobutyl isonitrile in benign and malignant lesions in the lungs. *Clin Nucl Med* 14: 333-340, 1989.
8. Aktolun C, Bayhan H, Kir M. Clinical experience with Tc-99m MIBI imaging in patients with malignant tumors: Preliminary results and comparison with Tl-201. *Clin Nucl Med* 17: 171-176, 1992.
9. O'Tuama LA, Packard AB, Treves ST. SPECT imaging of pediatric brain tumor with hexakis (methoxyisobutyl-isonitrile) technetium (I). *J Nucl Med* 31: 2040-2041, 1990.
10. Shih WJ, Kadzielawak K, Lee C, Moody EB, Ryo UK. Tc-99m sestamibi uptake by cerebellar metastasis from bronchogenic carcinoma. *Clin Nucl Med* 18: 887-890, 1993.
11. Medolago G, Virotta G, Piti A, et al. Abnormal uptake of technetium-99m hexakis-2-methoxyisobutyl isonitrile in a primary cardiac lymphoma. *Eur J Nucl Med* 199: 222-225, 1992.

12. Wakasugi S, Teshima H, Nakamura H, Hashizume T, Maeda T, Hiraoka A, et al. Tc-99m MIBI localization in bone marrow: A marker of bone marrow malignancy. *Clin Nucl Med* 23: 664–671, 1998.
13. Kricum ME. Red-yellow marrow conversion: Its effect on the location of some solitary bone lesions. *Skeletal Radiol* 14: 10, 1985.
14. Caner B, Kitapci M, Aras T, Erben G, Ugur O, Bekdik C. Increased accumulation of hexakis (2-methoxyisobutylisocyanide) technetium (I) in osteosarcoma in its metastatic lymph nodes. *J Nucl Med* 32: 1977–1978, 1991.
15. Reiman RE, Fettes JK. Localization of Tc-99m MIBI in diffuse myelodysplastic processes. *J Nucl Med* 37: 471–473, 1996.