

rCBF in neurodegenerative diseases as estimated by the autoradiographic (ARG) method and delayed I-123-IMP studies

Leo Garcia FLORES II, Seishi JINNOUCHI, Shigeki NAGAMACHI, Hiroshi NAKAHARA,
Ryuichi NISHII, Shigemi FUTAMI and SHOZO TAMURA

Department of Radiology, Miyazaki Medical College

A total of 24 patients with a mean age of 45.8 ± 20.8 were included in the study. The patients were grouped as Control (C), Degenerative Syndromes (DS), Degeneration Associated with External Factors (DEF), Degeneration Associated with Focal Neurologic Lesion (DFN) and Demyelinating Disease (DM). Imaging started 15 minutes for early and 4 hours for delayed scans after IV infusion of I-123 IMP. The rCBF was calculated by the IMP autoradiographic (ARG) method. The wash-out ratio (WR) was calculated as the ratio of the Delay/Early count. In the rCBF of the various areas of the brain, significant differences were noted between various disease groups. No correlation was noted between rCBF and WR ($r = -0.50$). The WR of patients grouped according to various disease processes did not show a significant difference between various areas of the brain. In conclusion, the rCBF was effective in separating both various areas of the brain and disease entities. WR from a delayed study is less useful in neurodegenerative diseases.

Key words: iodine-123-IMP ARG method, regional cerebral blood flow, neurodegenerative disease

INTRODUCTION

THERE is a rapidly increasing incidence of neurodegenerative disease (ND) manifesting as dementia especially at ages above 65 years. In Japan alone there are about 1.5 million demented persons.¹ Brain single photon emission computed tomography (SPECT) is useful in the differential diagnosis and evaluation of the severity of ND.²

With iodine-123-N-isopropyl-p-amphetamine (I-123-IMP), it is possible to calculate the regional cerebral blood flow (rCBF) with a one point blood arterial blood sample and a single scan by means of the autoradiographic method (ARG).³ The distribution volume of I-123-IMP represents the extent of retention in the brain tissue which can play an important role in evaluating the functional activity of the brain and in differential diagnosis of ND.^{4,5}

In this study, we investigated the usefulness of rCBF as estimated by the I-123-IMP ARG method in ND. We also validated the necessity of acquiring a delayed scan as a

routine study in all patients with ND.

MATERIALS AND METHODS

Patients

A total of 24 patients with a mean age of 45.8 ± 20.8 and a 1 : 1.1 Male : Female ratio were included in the study. The patients were grouped as Control (C), those with an impertinent medical history and negative physical examination, MRI/CT and SPECT findings; Degenerative Syndromes (DS) those with Alzheimer's Disease and manifesting dementia except the vascular type; Degeneration Associated with External Factors (DEF) such as metabolic encephalopathy, gliomatosis cerebri and multiple neuritis; Degeneration Associated with Focal Neurologic Lesion (DFN) such as Parkinson's Disease, spinocerebellar degeneration and Demyelinating Disease (DM) such as Leukodystrophy. Patients with cerebrovascular and related diseases were excluded from the study with both MRI and MRA.

Imaging

A total of 222 MBq of I-123-IMP was injected into the antecubital vein continuously over 1 minute and imaging

Received October 29, 1998, revision accepted May 24, 1999.

For reprint contact: Leo G. Flores II, M.D., Department of Radiology, Miyazaki Medical College, 5200 Kihara, Kiyotake, Miyazaki 889-1692, JAPAN.

Table 1 The regional cerebral blood flow in various areas of the brain with various pathologies

Diagnosis	No. of cases	High frontal lobe	Frontal lobe	Parietal lobe	Temporal lobe	Occipital lobe	Basal ganglia	Thalamus	Cerebellum
Control (C)	7	47.9 ± 15.05	46.7 ± 15.45	45.3 ± 13.06	49.6 ± 13.59	43.6 ± 11.45	52.5 ± 16.20	48.0 ± 13.28	47.0 ± 11.34
Degenerative Syndromes (DS)	4	29.9* ± 6.29	29.5* ± 5.81	28.8* ± 3.17	32.0† ± 5.22	32.2 ± 5.45	34.0* ± 8.19	35.2 ± 12.62	39.4 ± 9.0
Degeneration Assoc. with External Factors (DEF)	4	27.2* ± 11.34	27.1* ± 10.65	26.2† ± 9.23	27.4† ± 10.19	26.5† ± 7.19	35.1† ± 15.19	28.9* ± 8.85	31.7* ± 10.18
Degeneration Assoc. with Focal Neurologic Lesion (DFN)	5	32.8 ± 4.23	35.4 ± 4.09	33.9 ± 3.71	36.2 ± 5.61	34.0 ± 6.47	42.6 ± 4.73	43.6 ± 7.82	39.2 ± 12.17
Demyelinating Disease	4	43.1 ± 19.64	42.2 ± 20.05	44.2 ± 17.43	46.1 ± 16.18	38.4 ± 14.26	52.9 ± 19.59	44.5 ± 17.86	47.3 ± 9.40

Classification: C (Negative MRI/CT and SPECT findings); DS (Alzheimer's disease, Dementia); DEF (Metabolic encephalopathy, Gliomatosis cerebri and Multiple neuritis); DFN (Parkinson's disease and Spinocerebellar degeneration) and DM (Leukodystrophy). *: $p < 0.05$, †: $p < 0.01$

Table 2 The wash-out ratio (D/E) in various areas of the brain with various pathologies

Diagnosis	No. of cases	High frontal lobe	Frontal lobe	Parietal lobe	Temporal lobe	Occipital lobe	Basal ganglia	Thalamus	Cerebellum
Control (C)	7	0.77 ± 0.19	0.78 ± 0.18	0.79 ± 0.16	0.75 ± 0.14	0.77 ± 0.16	0.79 ± 0.16	0.77 ± 0.15	0.72 ± 0.17
Degenerative Syndromes (DS)	4	0.81 ± 0.05	0.77 ± 0.02	0.80 ± 0.05	0.80 ± 0.03	0.77 ± 0.03	0.79 ± 0.03	0.81 ± 0.06	0.73 ± 0.07
Degeneration Assoc. with External Factors (DEF)	4	0.88 ± 0.21	0.89 ± 0.21	0.93 ± 0.24	0.93 ± 0.22	0.89 ± 0.16	0.85 ± 0.20	0.92 ± 0.18	0.80 ± 0.19
Degeneration Assoc. with Focal Neurologic Lesion (DFN)	5	0.91 ± 0.15	0.85 ± 0.14	0.91 ± 0.17	0.86 ± 0.15	0.87 ± 0.16	0.88 ± 0.17	0.86 ± 0.14	0.79 ± 0.15
Demyelinating Disease (DM)	4	0.79 ± 0.11	0.84 ± 0.17	0.77 ± 0.11	0.76 ± 0.11	0.80 ± 0.12	0.81 ± 0.16	0.87 ± 0.16	0.73 ± 0.07

Classification: C (Negative MRI/CT and SPECT findings); DS (Alzheimer's disease, Dementia); DEF (Metabolic encephalopathy, Gliomatosis cerebri and Multiple neuritis); DFN (Parkinson's disease and Spinocerebellar degeneration) and DM (Leukodystrophy)

started 15 minutes later for early and 4 hours later for delayed scans. A three-headed gamma camera (PRISM 3000, Picker, Ohio) equipped with a low energy high resolution fan beam collimator was used. Angular step 3° and 40 steps at 40 sec/step and a 64×64 matrix size were used. Transverse reconstruction with a Ramp filter and Butterworth-Low-Pass filter, and attenuation correction with the first order of Chang were applied. A cylindrical phantom (16-cm in inner diameter and 15 cm long) was used to calibrate the sensitivity of the SPECT scanner against a well counter system. Ten minutes after the intravenous injection, a one point intraarterial blood sample was taken from the opposite site.

Data Analysis

The rCBF values were calculated by the I-123-IMP ARG

method as described by Iida et al.³ A 53 pixel size region of interest was placed in high frontal, frontal, parietal, temporal and occipital lobes, basal ganglia, thalamus and cerebellum of the brain to estimate the mean counts on early (E) and delayed (D) images. The wash-out ratio (WR) was calculated as D/E. ANOVA Fischer's PLSD of the rCBF and WR in the various areas of the brain with the patients grouped in various disease processes were done. The correlation of the WR and the rCBF was also noted.

RESULTS

In the rCBF of the various areas of the brain, significant differences were noted in various disease groups as shown in Table 1. In the high frontal, frontal, parietal, temporal and occipital lobes, basal ganglia thalamus and cerebel-

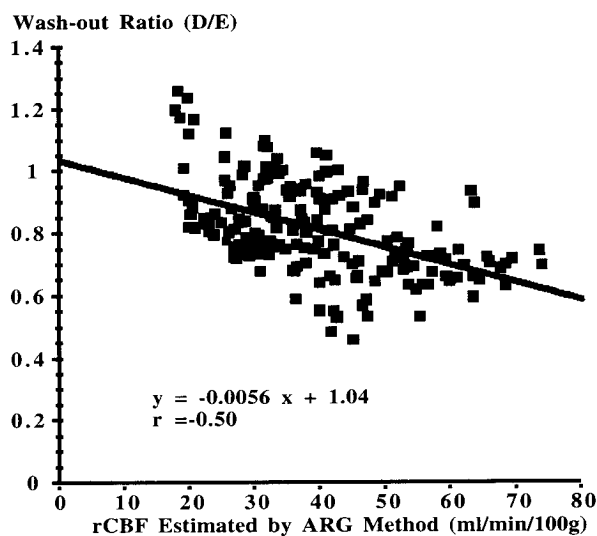


Fig. 1 Correlation of wash-out ratio and rCBF.

lum significant differences were noted between C and DEF ($p = 0.02$, $p = 0.02$, $p = 0.01$, $p = 0.01$, $p = 0.005$, $p = 0.01$, $p = 0.02$ and $p = 0.03$, respectively). In the high frontal, frontal, parietal and temporal lobes and basal ganglia significant difference were noted between C and DS ($p = 0.04$, $p = 0.04$, $p = 0.03$, $p = 0.002$ and $p = 0.05$, respectively). In parietal and temporal lobes, significant difference were also noted between DEF and DM ($p = 0.03$ and $p = 0.03$, respectively).

In Table 2, the WR of patients grouped according to various disease processes did not show a significant difference between various areas of the brain.

Figure 1 showed no correlation between rCBF and WR ($r = -0.50$).

DISCUSSION

Neurodegenerative diseases are characterized by progressive neuronal loss in the gray matter with secondary changes in the white matter tract. Their patterns of neuronal loss are selective, affecting certain groups of neurons while leaving others intact. The neuropathologic finding could be a specific intracellular abnormality or only neuronal loss in the affected area.⁶ I-123-IMP depicts these specific focal perfusion changes in the various areas of the brain such as typical bilateral involvement of the frontal, parietal and temporal lobes in Alzheimer's disease while sparing the bilateral pre-motor areas and the primary visual cortex, making it vital in the differential diagnosis of the various ND.^{2,7}

IMP SPECT delineates normal patients from those with ND. The IMP SPECT findings corresponded to the severity of symptoms and the various neuropsychological examination results.^{8,9} Compared to CT and MRI, IMP SPECT detect ND patients earlier.¹⁰ Although PET detected mildly affected areas better, IMP SPECT can be

more easily applied in clinical practice.¹¹ The use of quantitative methods has improved the sensitivity of IMP SPECT.¹²

In this study we used the two compartment model and the I-123-IMP ARG method which uses one SPECT scan and one point blood sampling in measuring rCBF. The retention of the I-123-IMP in the brain is assumed to be the fixed regional distribution volume (V_d). The whole-blood radioactivity was derived from a single blood sample by employing a standardized input function derived from an independent study population. To minimize errors caused by individual differences, the timing of the SPECT imaging and blood sampling were optimized and a cross calibration scan was performed at intervals of at least 3 weeks to calibrate the sensitivity of the SPECT scanner against a well counter system.^{13,14} Common problems encountered in the ARG method are inaccuracy and the underestimation of rCBF. The accuracy of the rCBF calculation is affected by individual differences in the input function which is the most dominant factor, individual differences in the V_d value and errors in the original SPECT image. Systematic underestimation of rCBF compared to the (^{15}O)H₂O PET method is due to limited first pass extraction of I-123-IMP and to poor spatial resolution of the SPECT scanner.³

Clinical validation of the I-123-IMP ARG method has shown that it is reproducible, and accurately and reliably estimate rCBF in a variety of clinical settings.^{14,15} The I-123-IMP ARG method was also useful in the assessment of treatment effects and the clinical course.¹⁶ In ND as in our study, significant differences in rCBF were noted both in various areas of the brain and various disease groups, which was useful in the differential diagnosis and assessment of clinical severity.^{17,18}

When comparing the delayed with the early scan there could be either no change from the previous study, filling in of the tracer in previously decreased accumulation areas in the early scan (redistribution), wash-out of areas with previous accumulation (reverse redistribution) and the widening of previously decreased accumulation areas.^{19,20} The distribution volume of the delayed scan represents the extent of retention of I-123-IMP in the brain tissue which plays a role in the evaluation of the functional activity of the brain and in diagnosing cerebral diseases.⁴ In epileptic patients with partial seizures, delayed scan was used to isolate epileptic lesions, and uptake patterns also correlated with epileptic activity.²¹ In patients with cerebrovascular disease, delayed scan was used to detect ischemic areas, understand the evolution of cerebral infarction, and to evaluate treatment and prognosticate.^{20,22,23} It is also useful in the diagnosis of intracranial malignant lymphoma.²⁴

The estimated activity in the early scan corresponds to K_1 which is equivalent to CBF, whereas in the delayed scan the estimated activity corresponds to V_d which is independent of CBF. The calculated WR also corre-

sponds to $1/k_2$ which is influenced by CBF. In our study WR was not able to delineate the various disease groups and the specific changes in various areas of the brain. WR is a physical parameter that is also affected by pathophysiological changes in brain cell or tissue viability.¹⁹⁻²⁴ In ND, the pathologic change is mainly atrophy or neuronal loss.⁶ This non-viable cell or tissue could not undergo a significant change that could be reflected in the delayed study. In WR of ND, the effect of CBF in the early study is diminished by an insignificant change in the delayed study. This raises the question whether WR or the delayed scan itself could be useful in ND.

Defer et al., hypothesized that the change in the delayed scan is a balance between the cellular uptake from the blood (blood flow) and the exit of I-123-IMP after the metabolism (cell viability).²⁵ In our study, there was no correlation between WR and rCBF. Other studies have shown an uncoupling or asymmetric cerebral perfusion and metabolism sometimes according to the clinical stage of the neurodegenerative disease.^{26,27}

The small number of subjects could be a limiting factor in this study. We are recommending that our findings be validated in larger study group classified according to the different clinical stages.

In conclusion, rCBF estimated by the I-123-IMP ARG method is useful in the differential diagnosis of ND. WR from a delayed scan has no clinical significance in the assessment of ND.

REFERENCES

1. Fukatsu R, Tsuzuki K, Takamaru Y, Hayashi Y, Sasaki N, Yoshida T, et al. Aging brains and the dementias. *Hokkaido Igaku Zasshi* 71: 297-301, 1996.
2. Ohnishi T, Hoshi H, Nagamachi S, Jinnouchi S, Futami S, Watanabe K, et al. Regional cerebral blood flow study with ¹²³I-IMP in patients with degenerative dementia. *Am J Neuroradiol* 12: 513-520, 1991.
3. Iida H, Nakazawa M, Hatazawa H, Ohnishi Y, Uemura K. Quantitative mapping of regional cerebral blood flow using iodine-123-IMP and SPECT. *J Nucl Med* 35: 2019-2030, 1994.
4. Odano I, Ohkubo M, Takahashi M, Noguchi E, Ohtaki H, Kasahara T, et al. A functional diagnostic method measuring of distribution volume of ¹²³I-IMP SPECT. *KAKU IGAKU (Jpn J Nucl Med)* 33: 579-586, 1996.
5. Odano I, Ohkubo M, Takahashi N, Ohtaki H, Noguchi E, Hatano M, et al. A new graphic method for evaluation of distribution volume on N-isopropyl-p-[¹²³I]iodoamphetamine (IMP) SPECT. *KAKU IGAKU (Jpn J Nucl Med)* 30: 1211-1219, 1993.
6. De Girolami U, Frosch DC, Anthony MP. The central nervous system. Coltran RS, Robbins SL, Kumar V, eds. *Pathologic Basis of Disease*, 5th edition. Philadelphia: W.B. Saunders Company, pp. 1295-1356, 1994.
7. Momose T, Nishikawa J, Kosaka N, Ohtake T, Watanabe T, Yoshikawa K, et al. N-isopropyl I-123 p-iodoamphetamine (IMP) brain SPECT in Alzheimer's disease. *KAKU IGAKU (Jpn J Nucl Med)* 26: 1177-1192, 1989.
8. Johnson KA, Holman BL, Rosen TJ, Nagel JS, English RJ, et al. Iofetamine I 123 single photon emission computed tomography is accurate in the diagnosis of Alzheimer's disease. *Arch Intern Med* 150: 752-756, 1990.
9. Ichimiya A. Multifunctional dementia rating scale: reliability and clinical validity. *Seishin Shinkeigaku Zasshi* 96: 1-25, 1994.
10. Killen AR, Oster G, Colditz GA. An assessment of the role of ¹²³I-N-isopropyl-p-iodoamphetamine with single-photon emission computed tomography in the diagnosis of stroke and Alzheimer's disease. *Nucl Med Commun* 10: 271-284, 1989.
11. Kuwabara Y, Ichiya Y, Otsuka M, Tahara T, Fukumura T, Gunasekera R, et al. Comparison of I-123 IMP and Tc-99m HMPAO SPECT studies and PET in dementia. *Ann Nucl Med* 4: 75-82, 1990.
12. Hellman RS, Tikofsky RS, Collier BD, Hoffman RG, Palmer DW, Glatt SL, et al. Alzheimer disease: Quantitative analysis of I-123-iodoamphetamine SPECT brain imaging. *Radiology* 172: 183-188, 1989.
13. Ito H, Ishii K, Kinoshita T, Koyama M, Kawashima R, Ono S, et al. Normal CBF values by the ARG method using IMP SPECT: comparison with a conventional microsphere model method. *KAKU IGAKU (Jpn J Nucl Med)* 33: 175-178, 1996.
14. Iida H, Akutsu T, Endo K, Fukuda H, Inoue T, Ito H, et al. A multicenter validation of regional cerebral blood flow quantitation using [¹²³I]iodoamphetamine and single photon emission computed tomography. *J Cereb Blood Flow Metab* 16: 781-793, 1996.
15. Hatazawa J, Iida H, Shimosegawa E, Sato T, Murakami M, Miura Y. Regional cerebral blood flow measurement with iodine-123-IMP autoradiography: normal values, reproducibility and sensitivity to hypoperfusion. *J Nucl Med* 38: 1102-1108, 1997.
16. Saito K, Murata H, Maruno H, Mori K, Tsuchida S. Reproducibility of regional cerebral blood flow measurement at rest with autoradiography method using ¹²³I-IMP and SPECT. *KAKU IGAKU (Jpn J Nucl Med)* 34: 343-348, 1997.
17. Koshi Y, Kitamura S, Komiyama T, Sakayori O, Komaba Y, Ohyama M, et al. A quantitative study of regional cerebral blood flow in patients with dementia of Alzheimer type using single photon emission computed tomography—clinical application of the IMP autoradiographic method (IMP ARG method). *KAKU IGAKU (Jpn J Nucl Med)* 33: 991-998, 1996.
18. Kageyama H, Kikuchi S, Tashiro K. Analysis of Parkinson's disease and related syndromes using ¹²³I-IMP-SPECT with the ARG method. *Nippon Rinsho* 55: 238-242, 1997.
19. Takahashi K, Odano I, Takahashi N. Redistribution on I-123-IMP SPECT in children and adolescent with partial seizures. *Clin Nucl Med* 21: 227-235, 1996.
20. Hoshi H, Yuki Y, Kawano S, Jinnouchi S, Nagamachi S, Ohnishi T, et al. Early and delayed imaging with ¹²³I-IMP SPECT in patients with ischemic cerebrovascular disease. *Ann Nucl Med* 4: 83-88, 1990.
21. Kawamura M, Murase K, Kataoka M, Itoh H, Ishine M, Kawamura S, et al. Early and delayed I-123 IMP SPECT in epileptic patients with partial seizures and normal CT. *Clin*

- Nucl Med* 16: 839–846, 1991.
22. Honda N, Machida K, Takishima T, Kaizu H, Sugimoto E. Iodine-123 IMP SPECT before and after bypass surgery in a patient with occlusion of left anterior and middle cerebral arteries with basal abnormal telangiectasis (unilateral Moyamoya disease). *Ann Nucl Med* 1: 43–46, 1987.
 23. Hayashida K, Nishimura T, Imakita S, Uehara T, Nakamura M, Tsuchiya T, et al. Change of accumulation and filling pattern in evolution of cerebral infarction with I-123 IMP brain SPECT. *Neuroradiology* 33: 9–14, 1991.
 24. Fukahori T, Tahara T, Mihara F, Kato A, Masumoto H, Kudo S, et al. Diagnostic value of high N-isopropyl-p-[¹²³I] iodoamphetamine (IMP) uptake in brain tumors. *Nippon Igaku Hoshasen Gakkai Zasshi* 56: 53–59, 1996.
 25. Defer G, Moretti J, Cesaro P, Sergent A, Raynaud C, Degos J. Early and Delayed SPECT using N-isopropyl-p-iodoamphetamine iodine 123 in cerebral ischemia: A prognostic index for clinical recovery. *Arch Neurol* 44: 715–718, 1987.
 26. Tanaka S, Tanaka M, Wada N, Okamoto K, Hirai S, Tanaka K. Uncoupling of cerebellar blood flow and metabolism in paraneoplastic cerebellar degeneration: report of a case. *Rinsho Shinkeigaku* 37: 514–519, 1997.
 27. Sato M, Nagata K, Yokoyama E, Hirata Y. Corticobasal degeneration: a combined clinical, PET and pathological study. *Rinsho Shinkeigaku* 36: 293–299, 1996.