

## Mechanism for abnormal thallium-201 myocardial scintigraphy in patients with left bundle branch block in the absence of angiographic coronary artery disease

Shinji HASEGAWA,\* Yasushi SAKATA,\*\* Fuminobu ISHIKURA,\*\* Atsushi HIRAYAMA,\*\*\*  
Hideo KUSUOKA,\*\*\*\* Tsunehiko NISHIMURA\* and Kazuhisa KODAMA\*\*\*

*\*Division of Tracer Kinetics, Biomedical Research Center, and \*\*First Department of Medicine,  
Osaka University Graduate School of Medicine*

*\*\*\*Cardiovascular Division, Osaka Police Hospital*

*\*\*\*\*HK is currently at Osaka National Hospital*

Patients with left bundle branch block (LBBB) often show abnormal images on exercise thallium (Tl)-201 scintigraphy without evidence of significant coronary stenosis. We investigated the mechanism for this phenomenon. Six patients with LBBB and without significant coronary stenosis underwent Tl-201 SPECT, ECG-gated SPECT imaging with Tc-99m-methoxyisobutyl-isonitrile (MIBI), and atrial pacing stress test. The % count amplitude in Tc-99m-MIBI images was calculated as  $\{(\text{maximal counts}) - (\text{minimal counts})\} / (\text{minimal counts}) \times 100$ . Though all patients had a low count in the septal and inferior wall in Tl-201 SPECT images, there was no ischemic production of lactate during an atrial pacing stress test. Nevertheless, gated SPECT images showed attenuated septal activity during systole. In patients with LBBB, the ratios of % count amplitude at the septum to that at the lateral wall at rest ( $0.47 \pm 0.05$ , mean  $\pm$  SE) were significantly less than the controls ( $n = 5$ ,  $0.83 \pm 0.12$ ,  $p = 0.014$ ). In conclusion, these results suggest that abnormal Tl-201 SPECT images of the septum in patients with LBBB are partially caused by impaired septal wall thickening during systole. Such an abnormal wall motion may reduce blood flow demands to the septum, resulting in reduction of coronary blood flow with little ischemia.

**Key words:** left bundle branch block, thallium, MIBI, gated SPECT

### INTRODUCTION

IN PATIENTS with left bundle branch block (LBBB), thallium (Tl)-201 myocardial scintigraphy frequently reveals decreased uptake in the septum despite the absence of coronary artery disease. Several mechanisms have been proposed to explain this phenomenon, but it is still controversial. We postulate two hypotheses as the mechanism for this phenomenon. One is that the partial volume effect due to decreased wall thickening in the septum may be

associated with abnormality in Tl-201 scintigraphy. The other is that septal asynchrony induces low perfusion but not ischemia in the septum. To prove the hypotheses, we performed Tc-99m-methoxyisobutyl-isonitrile (MIBI) electrocardiogram (ECG)-gated SPECT imaging and atrial pacing stress test in patients with LBBB.

### MATERIALS AND METHODS

#### *Subjects*

Exercise Tl-201 myocardial scintigraphy was performed in 21 patients with LBBB. These patients were referred to our clinics because of an abnormal electrocardiogram revealed during routine health checks (6 patients) or because of symptoms such as chest pain or palpitations (15 patients). Nineteen patients had perfusion abnormality noted on Tl imaging; all of them showed a defect in the

Received March 3, 1999, revision accepted May 12, 1999.

For reprint contact: Shinji Hasegawa, M.D., Ph.D., Division of Tracer Kinetics, Biomedical Research Center, Osaka University Graduate School of Medicine (D9), 2-2 Yamada-oka, Suita, Osaka 565-0871, JAPAN.

E-mail: hasegawa@tracer.med.osaka-u.ac.jp

septum, and showed re-distribution except one who was diagnosed as dilated cardiomyopathy. The other 2 patients had normal images on Tl scintigraphy. Coronary angiography was performed on 18 of these 19 patients with abnormal images on Tl scintigraphy, and 7 of them (39%) had significant coronary stenosis. Three of these 19 patients were diagnosed as having dilated cardiomyopathy based on global left ventricular hypokinesis (ejection fraction < 45% by left ventriculography or echocardiography). Six of the patients who had no significant coronary stenosis and were not diagnosed as dilated cardiomyopathy, gave informed consent for further studies; 2 of them had no significant abnormality, 1 had mild myocyte hypertrophy and 1 had interstitial fibrosis found only around the microvasculature in a biopsied specimen, but biopsy was not performed in the 2 remaining patients. Of the 6 patients recruited into our study, 5 were male and 1 was female, and the mean patient age was  $68 \pm 4$  years (mean  $\pm$  SE). Four of 6 patients had systemic hypertension and none had diabetes mellitus.

#### *Exercise Thallium-201 Myocardial Scintigraphy*

A 25-watt per 3-minute incremental protocol was used for symptom-limited exercise testing on a bicycle ergometer in the semisupine position. Thallium-201 (111 MBq) was injected intravenously when the maximal point was achieved, and exercise was continued for 1 additional minute. Single photon emission computed tomography (SPECT) was performed approximately 10 minutes after the injection for the initial images and 4 hours later for the delayed images. Re-injection was not performed. Images were obtained with rotating cameras (Optima 4000i, General Electronics, Milwaukee, USA), equipped with a low-energy general-purpose parallel-hole collimator. Each frame of image data was acquired over a 180-degree rotation from the right anterior oblique view to the left posterior oblique view with an interval of 5.6 degrees (32 projections). Polar map images were made, and regions with a % Tl uptake of less than the normal limit (mean – 2SD of normal file) were defined as abnormal regions.

#### *Tc-99m MIBI ECG-gated SPECT*

At rest, Tc-99m ECG-gated SPECT imaging was performed in all patients and 5 control subjects (2 men and 3 women, age;  $64 \pm 2$ , mean  $\pm$  SE) with normal electrocardiograms, no significant stenosis of coronary arteries on coronary angiography, and normal echocardiogram images. Tc-99m MIBI (740 MBq; Daiichi Radioisotope Laboratory, Tokyo, Japan) was injected intravenously at rest and images were obtained after 30 minutes of injection. Data acquisition was gated into 12 frames per cardiac cycle with an R-wave trigger, and data for 50 heart beats were obtained per projection.

Myocardial wall thickening was estimated from the fourth slice from the apical end of the left ventricular cavity in short axis images. Square regions of interest (3

$\times 3$  pixels,  $16.8 \times 16.8$  mm) were placed at the septum and the posterior wall in end-diastolic and systolic images. The % count increase, an index of myocardial wall thickening, was calculated as follows:<sup>1</sup>

$$\begin{aligned} &\% \text{ count increase} \\ &= \frac{(\text{end-systolic counts}) - (\text{end-diastolic counts})}{(\text{end-diastolic counts})} \times 100 \end{aligned}$$

We defined “end-systolic phase” and “end-diastolic phase” as the phases showing maximal counts and minimal counts in the lateral wall, respectively. Because the end-systolic phase and the end-diastolic phase in the lateral wall often differed from the phase of maximal counts and the phase of minimal counts in the septum due to asynchronous wall motion, we also calculated the counts of regions of interest on each frame (12 frame) in the septum and lateral wall and selected frames with maximal and minimal counts. Then we calculated the % count amplitude as follows:

$$\begin{aligned} &\% \text{ count amplitude} \\ &= \frac{(\text{maximal counts}) - (\text{minimal counts})}{(\text{minimal counts})} \times 100 \end{aligned}$$

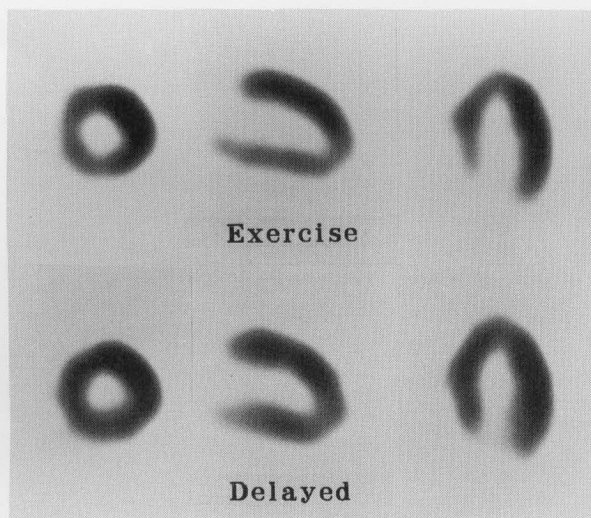
We defined “the maximal relaxed phase” as the phase of minimal counts. We also calculated the ratio of uptake in the septum to that in the lateral wall at the maximal relaxed phase to assess myocardial blood flow at rest, with the same regions of interest as in the analysis of wall thickening.

#### *Atrial Pacing Stress Test*

Atrial pacing stress tests were performed in all patients.<sup>2</sup> A 6 F pigtail catheter was positioned in the descending aorta for blood sampling. In addition, a 5 F NIH catheter (USCI, Billerica, Massachusetts, USA) was inserted into the coronary sinus, and positioned in the great cardiac vein close to its junction with the anterior interventricular vein for blood sampling. A 7 F pacing catheter was placed in the right atrium for atrial pacing. After blood sampling from the descending aorta and the great cardiac vein, atrial pacing was performed at a rate of 150 beats/min for 3 minutes, and blood sampling was repeated during pacing. Heparinized blood samples obtained by means of the catheters were rapidly centrifuged, and the plasma was analyzed for lactate. Lactate was measured with a commercially available assay kit (Determina LA, Kyowa Medics, Tokyo, Japan) and an automatic analyzer (model 705, Hitachi, Tokyo, Japan). To assess stress-induced ischemia in the antero-septal region, the lactate extraction ratio was calculated as follows:

$$\begin{aligned} &\text{lactate extraction ratio (\%)} \\ &= \frac{(\text{lactate in the aorta}) - (\text{lactate in the great cardiac vein})}{(\text{lactate in the aorta})} \times 100 \end{aligned}$$

Negative values for the lactate extraction ratio were regarded as proof of myocardial ischemia.



**Fig. 1** Early (upper panel) and delayed (lower panel) exercise thallium-201 SPECT images from a patient with LBBB and normal coronary arteries. Images displayed include the short axis (left), vertical long axis (middle) and horizontal long axis (right) views. Low count area exists in the septal and infero-septal wall in early image, and incomplete re-distribution occurred in delayed image.

Coronary angiography was also performed, and more than 75% stenosis of the coronary artery according to the visual assessment of the American Heart Association was defined as significant.

#### Echocardiography

With an M-mode echocardiograph (SSH-160A, Toshiba, Tokyo, Japan), the % wall thickening of the interventricular septum and left ventricular lateral wall was measured as follows:

$$\% \text{ wall thickening} = \frac{(\text{maximal wall thickness}) - (\text{minimal wall thickness})}{(\text{minimal wall thickness})} \times 100$$

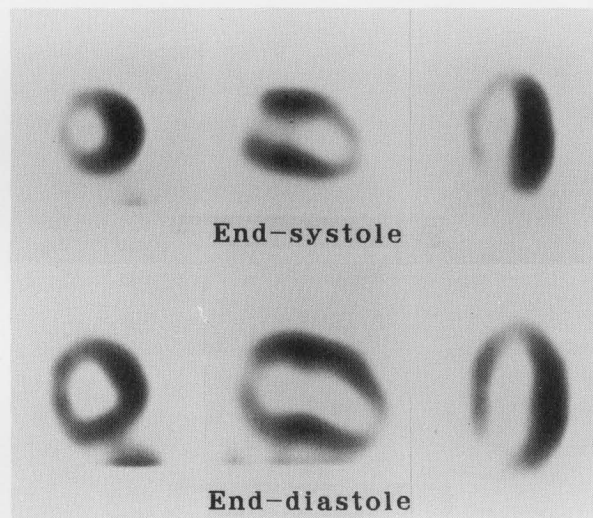
#### Statistical Analysis

Data are presented as the mean  $\pm$  SE. Differences between two means were assessed by the paired t-test or unpaired t-test where appropriate. A probability less than 0.05 was considered to be statistically significant.

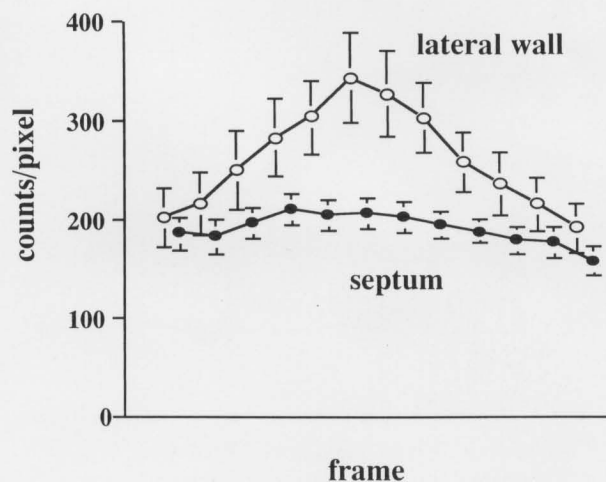
## RESULTS

#### Exercise Tl-201 Myocardial Scintigraphy

All of 6 patients had a low count in Tl-201 images after exercise and re-distribution in the septum. Four of them showed signs of incomplete re-distribution and the other 2 had complete re-distribution. Four of 6 patients also had a low count in the inferior wall after exercise, but all except one had no re-distribution. Figure 1 shows one of the typical exercise stress Tl-201 scintigraphy images



**Fig. 2** Tc-99m MIBI ECG-gated SPECT images of the patient same as in Figure 1. Images displayed are end-systolic (upper panel) and end-diastolic (lower panel) images. A severe septal defect present in the end-systolic image but not severe in the end-diastolic image. Images displayed include views of short axis (left), vertical long axis (middle) and horizontal long axis (right).



**Fig. 3** The count-curve in the septum (closed circle) and the lateral wall (open circle) of the six patients with LBBB.

obtained in these patients, depicting a reversible low count in the septum.

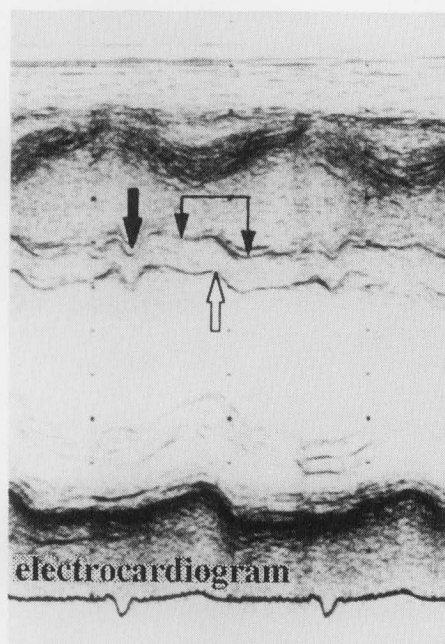
#### Tc-99m MIBI ECG-gated SPECT

Figure 2 shows images of the Tc-99m MIBI gated SPECT of the same patient as in Figure 1. This patient had a severe defect in the septum in the end-systolic images, but only mild hypoperfusion was noted in the end-diastolic images. Five of 6 patients had a lower count in the septum than in the lateral wall in the end-systolic Tc-99m MIBI image, and this difference was smaller in the end-diastolic image. One patient had equivalent counts in the septum

**Table 1** The count analysis of the patients with LBBB and controls

	LBBB (n = 6)	control (n = 5)	p value
% count increase			
septum	30.6 ± 4.4	59.1 ± 7.0	0.006*
lateral wall	89.9 ± 11.2	75.2 ± 12.5	0.40
% count amplitude			
septum	42.7 ± 7.0	59.1 ± 7.0	0.14
lateral wall	90.4 ± 11.6	75.2 ± 12.5	0.40
septum/lateral wall	0.47 ± 0.05	0.83 ± 0.12	0.014*
count at the maximal relaxed phase			
septum/lateral wall	0.89 ± 0.12	0.96 ± 0.05	0.65

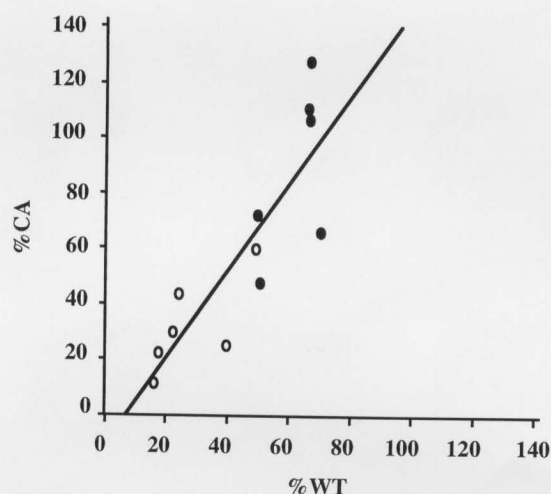
mean ± SE, \*:  $p < 0.05$ , LBBB vs. control



**Fig. 4** M-mode echocardiogram of a patient with LBBB.

and in the lateral wall in the end-systolic image, but the end-diastolic image showed a lower count in the lateral wall.

The count-curve during one cardiac cycle obtained from the patients with LBBB (Fig. 3) indicates that the count in the septum did not increase during systole compared with that in the lateral wall. Table 1 summarizes the count analysis for the septum and the lateral wall. The % count increase in the lateral wall of these 6 patients did not differ from that of the control without LBBB ( $p = 0.40$ ), whereas the % count increase in the septum was significantly lower in patients with LBBB than in the control ( $p = 0.006$ ). In the patients with LBBB, the maximal count and the minimal count in the septum was not achieved at end-systole or end-diastole. The % count amplitude in the septum was lower in patients with LBBB than in those in



**Fig. 5** The correlation between % count amplitude by MIBI gated SPECT and % wall thickening by echocardiography. There is significant correlation between % count amplitude and % wall thickening ( $r = 0.85$ ,  $p = 0.0001$ ). Closed circle: the septum, open circle: the lateral wall.

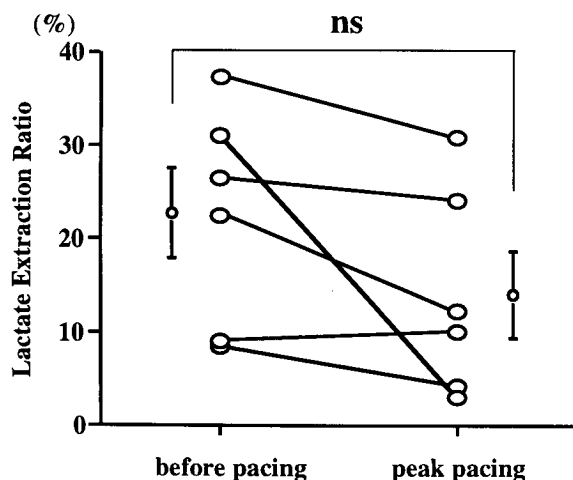
the control without LBBB ( $p = 0.14$ ), but it is not significant. Furthermore, the ratio of % count amplitude in the septum to that in the lateral wall was significantly lower in patients with LBBB ( $p = 0.014$ ). These results indicate that the septal wall thickening is decreased compared with that in the lateral wall in patients with LBBB. In contrast, the ratio of the uptake in the septum to that in the lateral wall in the maximal relaxed phase in the patients with LBBB and those without LBBB were similar ( $p = 0.65$ ). These results indicate that septal perfusion in patients with LBBB is not significantly reduced at rest, but the septum does not contract as strongly as the lateral wall.

#### Echocardiography

Abnormal systolic contraction of the septum (Fig. 4) was detected by M-mode echocardiography in all patients with LBBB. The septum moved concentrically twice during the cardiac cycle in patients with LBBB. The first movement during diastole may be due to an early rise in right ventricular filling pressure caused by an atrial kick (thick black arrow), while the second movement may be the true contraction of the septum (thin black arrow).<sup>3</sup> Such an abnormal septal wall motion may impair effective wall thickening of the septum. The count amplitude in gated SPECT was compared with the wall thickening on echocardiography in the patients with LBBB. These parameters closely correlated ( $r = 0.85$ ,  $p = 0.0001$ ; Fig. 5).

#### Atrial Pacing Stress Test

During atrial pacing stress test, none of the patients had any symptoms such as chest pain. All patients had a positive lactate extraction ratio of the great cardiac vein not only during the control phase ( $22.5 \pm 4.8\%$ ; mean  $\pm$



**Fig. 6** The myocardial lactate extraction ratio before pacing (left) and at the peak of pacing (right) in 6 patients with LBBB

SE) but also at the peak pacing rate of 150 beats/min ( $13.9 \pm 4.5\%$ ). The lactate extraction ratio at the peak and during the control phase did not change greatly ( $p = 0.097$ ; Fig. 6). But in 1 patient the lactate extraction ratio fell from 31% to 3% and his lactate extraction ratio calculated from the coronary sinus data was negative ( $-11\%$ ). In addition, he also had signs of re-distribution in the inferior wall on TI-201 images. These results suggest that there is no ischemia even during high frequent atrial pacing in most patients with LBBB, but some patients may have ischemia due to microvascular disease in the area showing signs of re-distribution.

## DISCUSSION

In this study we investigated the mechanisms for abnormal findings in TI-201 images in patients with LBBB and without coronary stenosis. Tc-99m MIBI ECG-gated SPECT indicates that impaired wall thickening in the septum causes the low count in the septum in TI-201 images due to a partial volume effect.<sup>4</sup> Data on the MIBI count ratio in the maximal relaxed phase suggest that the blood flow in the septum of patients with LBBB is not significantly reduced at rest. In addition, the data on the atrial pacing stress test implied that there might be no ischemia in the septum. But it cannot be denied that the hypoperfusion in the septum at a high heart rate may cause low uptake and re-distribution in the septum of TI, but our results imply that the decreased perfusion, if any, is still matched to the reduced demand due to impaired wall motion.

### *Mechanisms of Abnormal TI Image*

The present study demonstrates that a septal low count on thallium imaging in patients with LBBB may be partially due to reduced wall thickening during systole at rest. Wall thickening is thought to increase the scintigraphic count

because of a partial volume effect and it has been shown that changes in myocardial wall thickness are linearly related to changes in the count of the same myocardial region.<sup>5</sup> Cooke et al., with wall thickness data obtained from ultrasonic crystals implanted in normal canine myocardium, found that multigated MIBI SPECT studies could accurately measure systolic wall thickening by a count-based technique.<sup>6</sup> We also confirmed that the count amplitude in gated SPECT was well correlated with the wall thickening on echocardiography. These results indicate that impaired wall motion directly causes abnormality in SPECT images despite the preservation of regional myocardial blood flow, but this mechanism can explain only fixed defects, but not reversible defects.

Reversible defects signify relative hypoperfusion in the septum during exercise. It has been suggested that increases in wall stress combined with shortening of the diastolic coronary filling period during exercise decrease septal perfusion, even in patients with normal coronary arteries.<sup>7</sup> Ono et al. have shown that LBBB induced by right ventricular pacing causes increased intraseptal pressure during diastole and reduced septal myocardial blood flow when compared to the free wall.<sup>8</sup> They also showed that F-18-fluoro-deoxy-glucose uptake is reduced in the septum while the lactate extraction rate did not change. Althoefer et al. have found that F-18-fluoro-deoxy-glucose uptake in the septum is reduced in patients with coronary artery disease and LBBB.<sup>9</sup> Based on these findings, it was concluded that LBBB may reduce myocardial perfusion, but may not necessarily induce septal ischemia. Previous studies have shown that dipyridamole or adenosine TI-201 scintigraphy is superior to exercise TI-201 scintigraphy in detecting coronary artery disease in patients with LBBB.<sup>10-12</sup> Vasodilators such as dipyridamole and adenosine, act uniformly throughout the coronary vasculature without an increase in myocardial flow demand, and allow accurate measurement of coronary flow reserve by TI-201 imaging. In contrast, dobutamine induces reversible defects on thallium imaging through a similar mechanism to exercise in patients with LBBB.<sup>13</sup> In patients with LBBB, exercise or catecholamines may induce only a little increase in oxygen demand in the septum because of impaired wall motion caused by asynchrony, and therefore flow to the septum may not increase. In the present study, myocardial lactate was still extracted during atrial pacing. The results are consistent with previous observations. Even if there is hypoperfusion in the septum, it is still equivalent to reduced demand due to impaired wall motion; and ischemia is not severe enough to cause an increase in lactate production during rapid atrial pacing.

Knapp et al. have hypothesized that the imaging defect in the septum is caused by diffuse septal scarring.<sup>14</sup> According to their data stress and rest MIBI images and stress and re-injection TI-201 images show constant septal deficits in most patients with LBBB and without

significant coronary stenosis. They therefore concluded that MIBI or the TI re-injection method can differentiate ischemia from scar in patients with LBBB, but they did not clarify the mechanism of re-distribution of TI-201 in the septum. Tawarahara et al. have suggested that exercise induced defects are due to small-vessel disease and associated fibrodegenerative changes, which can cause intraventricular conduction disturbances.<sup>15</sup> Burns et al. have hypothesized that long-standing LBBB could lead to septal thinning in a fashion similar to "disuse atrophy".<sup>16</sup> Patients with LBBB might therefore progress to a cardiomyopathic state with fibrodegenerative changes. In the present study abnormal findings of left ventricular biopsy were observed in two patients. Various causes of LBBB, such as hypoperfusion, cardiomyopathy, and disuse atrophy, may lead to fibrodegenerative changes and scarring of the septum. Some patients in this study had abnormal findings also in the inferior wall. Most previous articles reporting abnormal findings in the septal area involving anterior, inferior and apical walls, said that inferior walls showed signs of re-distribution,<sup>17,18</sup> but in our data abnormal inferior regions showed signs of fixed defects without re-distribution. This suggests that a fixed defect in the inferior wall might be due to attenuation by the diaphragm or myocardial damage with scar tissue.<sup>14</sup>

#### Limitations

Our data suggest that the difference between the partial volume effects at the septum and the lateral wall causes abnormality in TI images at rest, but we could not clearly demonstrate the mechanism for re-distribution of TI in the septum. Though there may be hypoperfusion in the septum, there was no lactate production during atrial pacing, suggesting that the ischemia in septum is minimal.

The number of patients included in this study was relatively small. One of the main reasons for the small number is that the study included the invasive assessment. We could therefore not clarify the relationship between minor abnormalities in biopsied specimens and TI-201 abnormality.

In conclusion, our data indicate that abnormal non-gated TI-201 SPECT perfusion images in the septum of patients with LBBB are partially caused by the impairment of septal thickening during systole at rest. Such an abnormal wall motion may reduce the demand for blood flow to the septum, resulting in a reduction in coronary blood flow in the septum and giving the appearance of a reversible low count on exercise stress scintigraphy with minimal ischemia.

#### ACKNOWLEDGMENTS

We thank Mr. Keiji Kamisue and Mr. Yutaka Koshimune of the Department of Nuclear Medicine, Osaka Police Hospital for their help in data analysis.

#### REFERENCES

1. Takeda T, Toyama H, Ishikawa N, Satoh M, Masuoka T, Ajisaka R, et al. Quantitative phase analysis of myocardial wall thickening by technetium-99m 2-methoxy-isobutylisonitrile SPECT. *Ann Nucl Med* 6: 69-78, 1992.
2. Yamamoto K, Asada S, Masuyama T, Nanto S, Matsumura Y, Naito J, et al. Myocardial hibernation in the infarcted region cannot be assessed from the presence of stress-induced ischemia: Usefulness of delayed image of exercise thallium-201 scintigraphy. *Am Heart J* 125: 33-40, 1993.
3. Dillon JC, Chang S, Feigenbaum H. Echocardiographic manifestations of left bundle branch block pattern. *Circulation* 49: 876-880, 1974.
4. Sugihara H, Tamaki N, Nozawa M, Ohmura T, Inamoto Y, Taniguchi Y, et al. Septal perfusion and wall thickening in patients with left bundle branch block assessed by technetium-99m-sestamibi gated tomography. *J Nucl Med* 38: 545-547, 1997.
5. Fukuchi K, Uehara T, Morozumi T, Tsujimura E, Hasegawa S, Yutani K, et al. Quantification of systolic count increase in technetium-99m MIBI ECG-gated myocardial SPECT. *J Nucl Med* 38: 1067-1073, 1997.
6. Cooke CD, Garcia EV, Cullom SJ, Faber TL, Pettigrew RI. Determining the accuracy of calculating systolic wall thickening using a fast Fourier transform approximation: a simulation study based on canine and patient data. *J Nucl Med* 35: 1185-1192, 1994.
7. Hirzel HO, Senn M, Nuesch K, Buettner C, Pfeiffer A, Hess OM, et al. Thallium-201 scintigraphy in complete left bundle branch block. *Am J Cardiol* 53: 764-769, 1984.
8. Ono S, Nohara R, Kambara H, Okuda K, Kawai C. Regional myocardial perfusion and glucose metabolism in experimental left bundle branch block. *Circulation* 85: 1125-1131, 1992.
9. Althoefer C, vom Dahl J, Buell U. Septal glucose metabolism in patients with coronary artery disease and left bundle-branch block. *Coronary Artery Disease* 4: 569-572, 1993.
10. O'Keefe JH, Bateman TM, Sivistri R, Barnhart C. Safety and diagnostic accuracy of adenosine thallium-201 scintigraphy in patients unable to exercise and those with left bundle branch block. *Am Heart J* 124: 614-621, 1992.
11. O'Keefe JH, Bateman TM, Barnhart CS. Adenosine thallium-201 is superior to exercise thallium-201 for detecting coronary artery disease in patients with left bundle branch block. *J Am Coll Cardiol* 21: 1332-1338, 1993.
12. Jukema JW, Wall EE, Vis-Melsen MJE, Kruyswijk HH, Bruschke AVG. Dipyridamole thallium-201 scintigraphy for improved detection of left anterior descending coronary artery stenosis in patients with left bundle branch block. *Eur Heart J* 14: 53-56, 1993.
13. Tighe DA, Hutchinson HG, Park CH, Chung EK, Fischman DL, Raichlen JS. False-positive reversible perfusion defect during dobutamine-thallium imaging in left bundle branch block. *J Nucl Med* 35: 1989-1991, 1994.
14. Knapp WH, Bentrop A, Schmidt U, Ohlmeier H. Myocardial scintigraphy with thallium-201 and technetium-99m-hexakis-methoxyisobutylisonitrile in left bundle branch block: a study in patients with and without coronary artery disease. *Eur J Nucl Med* 20: 219-224, 1993.
15. Tawarahara K, Kurata C, Taguchi Y, Kobayashi A,



- Yamazaki N. Exercise testing and thallium-201 emission computed tomography in patients with intraventricular conduction disturbances. *Am J Cardiol* 69: 97–102, 1992.
16. Burns RJ, Galligan L, Wright LM, Lawand S, Burke RJ, Gladstone PJ. Improved specificity of myocardial thallium-201 single-photon emission computed tomography in patients with left bundle branch block by dipyridamole. *Am J Cardiol* 68: 504–508, 1991.
17. Jazmati B, Sadaniantz A, Emaus SP, Heller GV. Exercise thallium-201 imaging in complete left bundle branch block and the prevalence of septal perfusion defects. *Am J Cardiol* 67: 46–49, 1991.
18. Canna GL, Giubbini R, Metra M, Arosio G, Curnis A, Cicogna R, et al. Assessment of myocardial perfusion with thallium-201 scintigraphy in exercise-induced left bundle branch block: diagnostic value and clinical significance. *Eur Heart J* 13: 942–946, 1992.