

Tuberculosis peritonitis: Gallium-67 scintigraphic appearance

Yukiharu SUMI,* Yutaka OZAKI,* Hiroshi HASEGAWA,* Noboru SHINDOH,*
Hitoshi KATAYAMA* and Fumihiko TAMAMOTO**

*Department of Radiology, Juntendo University Urayasu Hospital

**Department of Radiology, Tokyo Metropolitan Otsuka Hospital

Tuberculosis peritonitis is a rare manifestation of extrapulmonary tuberculosis. The results of gallium-67 scintigraphy of three patients with tuberculosis peritonitis were reviewed to assess its usefulness in the diagnosis of this condition. Tuberculosis peritonitis was associated with diffuse or focal abdominal localization and decreased hepatic accumulation of gallium-67. These gallium-67 scan features of tuberculosis peritonitis may help to optimize the diagnosis and management of this disease.

Key words: tuberculosis peritonitis, gallium-67 scintigraphy, computed tomography

INTRODUCTION

PERITONEAL TUBERCULOSIS is rarely encountered with effective control of pulmonary tuberculosis and widespread pasteurization of milk in Japan and other advanced countries, occurring mainly in patients with acquired immune deficiency syndrome (AIDS).¹⁻³ The diagnosis of tuberculosis peritonitis is often difficult because of vague symptoms, lack of pathognomonic laboratory findings and non specific radiologic features.⁴⁻⁶ Gallium-67 (Ga-67) scintigraphy is useful in the detection of acute and chronic infectious diseases. Gallium accumulation has been reported in intra-abdominal abscess, appendicitis, cholecystitis, peritonitis and pyelonephritis.⁷ Gallium localization has been documented in extrapulmonary as well as pulmonary tuberculosis.⁸ We report three cases of tuberculosis peritonitis that showed characteristic scintigraphic findings.

CASE REPORTS

Case 1

A 47-year-old woman was admitted with a history of high fever (39°C), general malaise, and abdominal discomfort of seven day's duration. Physical examination revealed

ascites and abdominal tenderness. Laboratory tests revealed mild anemia, leukocytosis, and an increased erythrocyte sedimentation rate (ESR). No abnormality was recognized on chest radiograph.

A whole body Ga-67 scan showed diffuse localization throughout the abdominal region and decreased hepatic accumulation (Fig. 1-A, B). Abdominal CT scan with contrast enhancement demonstrated relatively high density (approximately 40 Hounsfield Unit) ascites and accentuation of mesenteric vessels (Fig. 1-C). No lymphadenopathy was noted.

She was started on anti-tuberculosis therapy on the basis of high adenosine deaminase (ADA) levels in ascites and pleural effusion, and imaging findings. She was discharged after 40 days and continued to do well during her routine follow-up.

Case 2

A 46-year-old man presented with a persistent fever and general fatigue of three week's duration. On physical examination, ascites and mild abdominal distention were found. Laboratory tests revealed mild anemia, abnormality of liver function tests, and a high ESR. Chest radiograph revealed no abnormality.

Ga-67 scintigraphy showed diffuse increased uptake throughout the abdomen and decreased hepatic uptake (Fig. 2-A, B). Abdominal CT with contrast enhancement demonstrated a small amount of ascitic fluid and small linear and nodular high density areas in the mesentery. Mild enlargement of paraaortic lymph nodes was also

Received January 18, 1999, revision accepted March 3, 1999.

For reprint contact: Yukiharu Sumi, M.D., Department of Radiology, Juntendo University Urayasu Hospital, Tomioka 2-1-1, Urayasu, Chiba 279-0021, JAPAN.

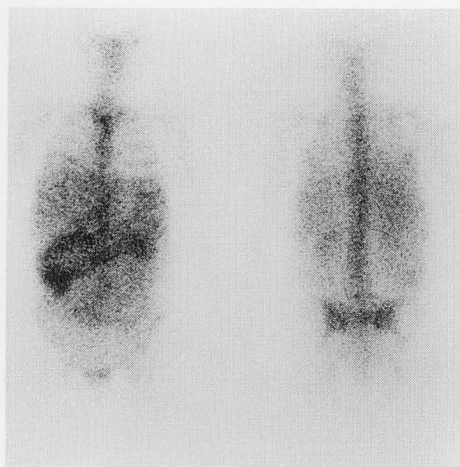

Fig. 1A

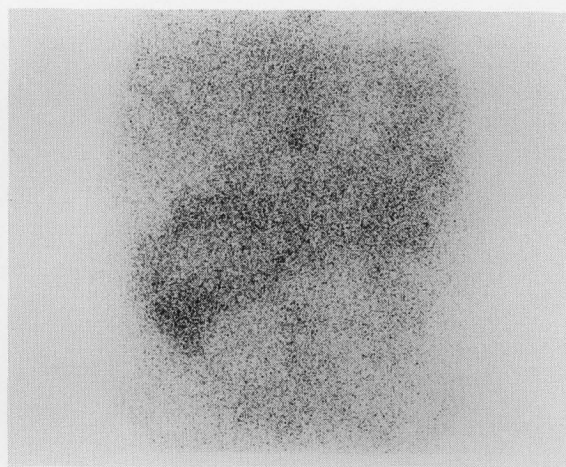


Fig. 1B

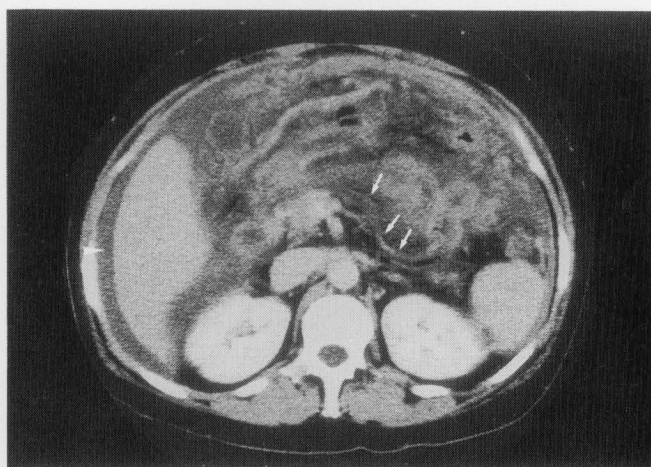


Fig. 1C

Fig. 1 Case 1. A: A whole body Ga-67 scan with purgative preparation taken at 48 hours after intravenous injection of 111 MBq of Ga-67 shows diffuse localization throughout the abdominal region. B: Anterior abdominal spot view reveals markedly decreased hepatic accumulation. C: Upper abdominal CT scan shows relatively high density ascites (arrowhead) and accentuation of mesenteric vessels (arrows).

visualized (Fig. 2-C).

He was started on tuberculosis medication on the basis of high ADA levels in ascites and positive polymerase chain reaction (PCR) detection of *Mycobacterium tuberculosis* in sputa. He was discharged and had an uneventful recovery.

Case 3

A 76-year-old man with a past history of pulmonary tuberculosis presented with a 3-week history of persistent fever and abdominal distention. Physical examination revealed ascites and abdominal distention. Laboratory studies showed leukocytosis and a high ESR. Chest radiograph demonstrated the findings of old pulmonary tuberculosis, but no active lesions were seen.

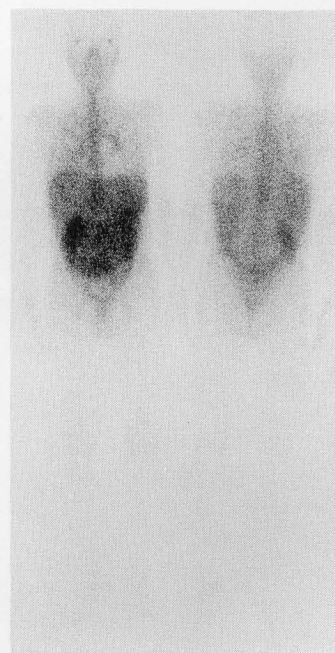


Fig. 2A

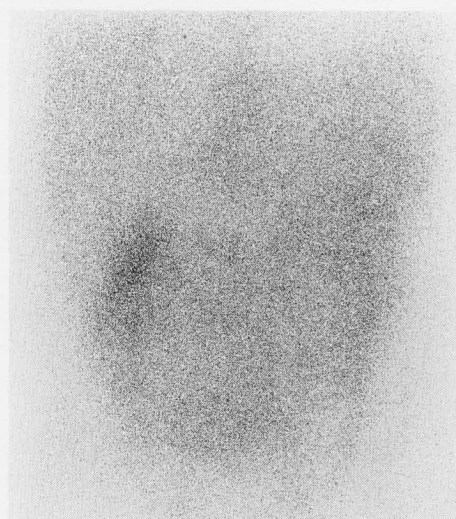


Fig. 2B

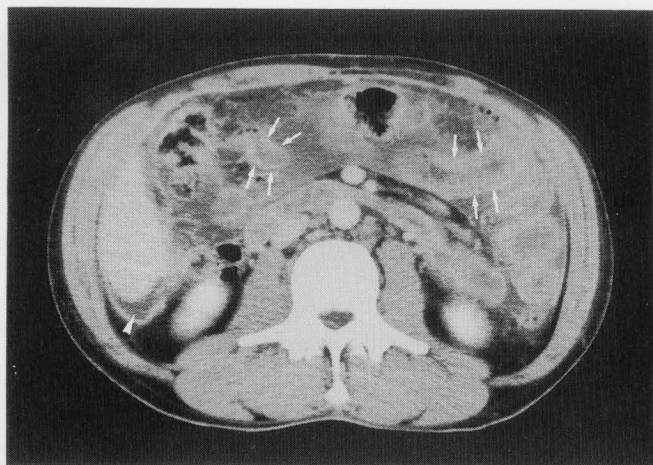


Fig. 2C

Fig. 2 Case 2. A: A whole body Ga-67 scan with purgative preparation taken at 48 hours after intravenous injection of 111 MBq of Ga-67 demonstrates increased homogeneous radioactivity in the whole abdomen. B: Anterior abdominal spot view shows decreased hepatic concentration of radiogallium. C: CT scan of upper abdomen demonstrates a small amount of ascites (arrowhead) and thickening of the bowel wall (arrows).

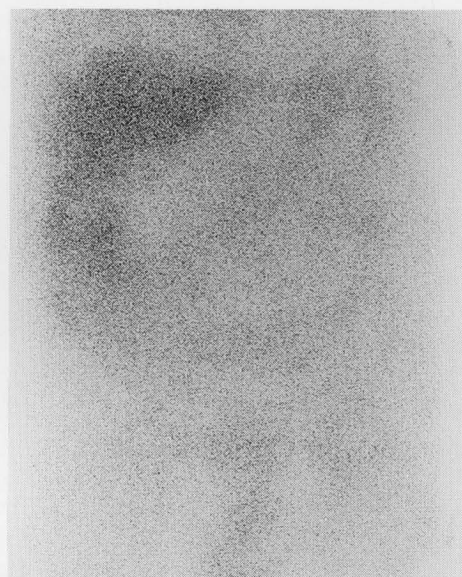


Fig. 3B

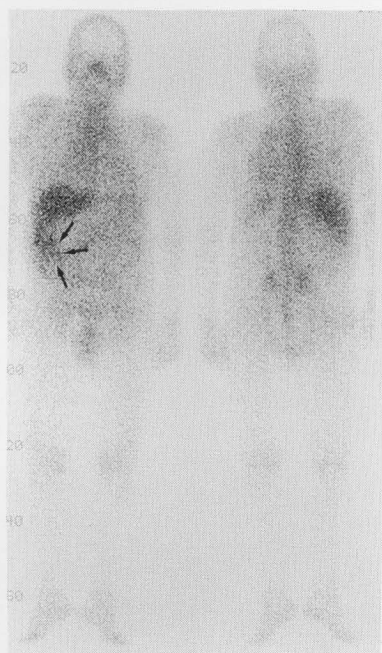

Fig. 3A

A whole body Ga-67 scan demonstrated diffuse abdominal localization with a right epigastric region of maximal concentration (Fig. 3-A, B). Abdominal CT with contrast enhancement showed a small amount of ascites with high density and thickening of the bowel wall adjacent to the mesentery. No lymphadenopathy was noted (Fig. 3-C).

He was started on anti-tuberculosis therapy on the basis

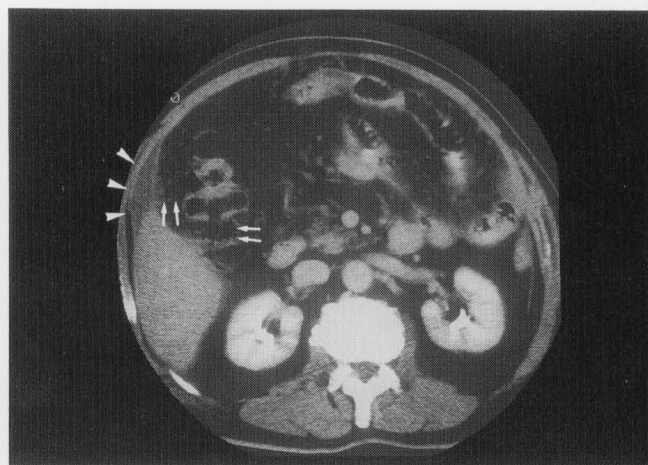


Fig. 3C

Fig. 3 Case 3. A: A whole body Ga-67 scan with purgative preparation taken at 48 hours after intravenous injection of 111 MBq of Ga-67 shows a focal area of increased radioactivity in the right epigastric region (arrows). B: Anterior abdominal spot view reveals normal hepatic uptake. C: Upper abdominal CT scan shows a small amount of high density ascitic fluid (arrowheads) and linear high density area of mesentery (arrows).

of high ADA levels in ascites and radiological features. He was discharged after 58 days and continued to do well in his routine follow-up.

DISCUSSION

Tuberculosis peritonitis is uncommon, occurring in up to only 3.5% of cases of pulmonary tuberculosis.⁹ With

appropriate anti-tuberculosis therapy, the current mortality rate in non-AIDS patient is reported to be only 7%.¹⁰ The peritoneal inflammation is probably related to ingestion of infected material (such as milk), or due to ingestion of sputa in patients with pulmonary tuberculosis. Hematogenous dissemination to the abdominal viscera and lymphatic system from a distant focus (usually in the lungs) is also possible. The diagnosis of tuberculosis peritonitis is often overlooked and delayed because the condition may clinically simulate a host of diseases including malignant lymphoma, pancreatic carcinoma, gastric carcinoma, ovarian carcinoma, inflammatory bowel disease, metastatic melanoma and peritoneal mesothelioma.⁴⁻⁶

Ga-67 scintigraphy is useful in the detection of acute and chronic infectious diseases, and gallium localization has been documented in extrapulmonary as well as pulmonary tuberculosis.⁸ The reason for gallium uptake in inflammatory tissues remains to be elucidated. There are two possible mechanisms based on the similarity of gallium to ferric ion. One postulates that gallium binds to lactoferrin, while the other is that the siderophore mediates direct bacterial uptake of gallium.⁴

To our knowledge, gallium localization has been reported in 16 patients with tuberculosis peritonitis.^{4-6,11-17} Diffuse abdominal uptake was seen in 10 of 16 patients (63%), and focal abdominal uptake in 6 of 16 patients (37%). In the same population, decreased hepatic uptake was seen in 9 of 16 patients (56%), normal hepatic uptake in 4 of 16 patients (25%), and the remaining 3 patients were unknown. This phenomenon was assumed to be the result of competition by the inflammation, which acts as a "sink" for radiogallium.¹⁸ The other causes of reduced hepatic uptake of Ga-67 have been known recent chemotherapy, blood transfusion (iron overload), and liver failure.¹⁸ In our all cases, such other causes were not recognized. The scintigraphic findings of tuberculosis peritonitis are not specific. Many intra-abdominal processes such as bacterial peritonitis, diffuse inflammatory bowel disease, malignant lymphoma, peritoneal metastases, and spread of pancreatitis may present similar features. Nevertheless, if Ga-67 scintigraphy shows diffuse abdominal uptake with decreased hepatic accumulation, similar to that seen in our cases 1 and 2, tuberculosis peritonitis should be considered in the differential diagnosis.

In our patients, tubular accumulation of gallium was observed in the abdomen. This seemed to correspond with affected bowel loop, but the influence of physiological excretion of Ga-67 in the stools could not be denied. Proper measures for bowel preparations, the dosage of Ga-67, and the timing of image acquisition (such as early imaging at 5 to 6 hours after injection) may provide a solution to this problem.

Ga-67 scintigraphy has been widely used in the workup of patients with unexplainable prolonged fever or fever

of unknown origin (FUO). Ga-67 scintigraphy in patients with FUO could provide high diagnostic sensitivity.^{12,18,19} In our present cases, all patients were admitted with FUO. Tuberculosis peritonitis should always be considered in any abdominal disease that is not readily and completely explained by characteristic results of cytologic, biochemical and culture examination of ascites and histologic material. Misdiagnosis of tuberculosis peritonitis is tragic; it is one of the few diffuse peritoneal processes for which there is an appropriate therapy and a good prognosis if promptly diagnosed.

In conclusion, Ga-67 scintigraphy is a sensitive means for the localization of tuberculosis peritonitis. Although other diagnostic studies may still be required, we expect that the presence of characteristic features on a Ga-67 scan would assist early diagnosis of tuberculosis peritonitis.

REFERENCES

1. Bastani B, Shariatzadeh MR, Dehdashti F. Tuberculous Peritonitis: report of 30 cases and review of the literature. *Quarterly Journal of Medicine, New Series* 56 221: 549-557, 1985.
2. Larson EB, Featherstone HJ, Petersdorf RG. Fever of undetermined origin: diagnosis and follow up of 105 cases, 1970-1980. *Medicine* 61: 269-292, 1982.
3. Kramer EL, Sanger JH, Garay SM, Grossman RJ, Tiu S, Banner H. Diagnostic implications of Ga-67 chest-scan patterns in human immuno-deficiency virus-seropositive patients. *Radiology* 170: 671-676, 1989.
4. LaManna MM, Saluk PH, Zekavat PP, Mobini J, Parker JA. Gallium localization in peritonitis—two case reports—. *Clin Nucl Med* 9: 25-27, 1984.
5. Perez J, Rivera JV, Bermudez RH. Peritoneal localization of gallium-67. *Radiology* 123: 695-697, 1977.
6. Steinbach JJ. Abnormal ⁶⁷Ga-citrate scan of the abdomen in tuberculous peritonitis: case report. *J Nucl Med* 17: 272-273, 1976.
7. Muroff LR. Detections of abdominal abscesses with Ga-67 citrate: correlative studies with computed tomography. *Semin Nucl Med* 12: 173-183, 1982.
8. Yang SO, Lee YI, Chung DH, Lee MC, Koh CS, Choi BI, et al. Detection of extrapulmonary tuberculosis with gallium-67 scan and computed tomography. *J Nucl Med* 33: 2118-2123, 1992.
9. Sockocky S. Tuberculosis peritonitis. *Am Rev Respir Dis* 95: 398-401, 1967.
10. McMillen MA, Arnold SD. Tuberculous peritonitis associated with alcoholic liver disease. *NY State J Med* 79: 922-924, 1979.
11. Lere S, Romano T, Denmark L. Gallium-67-citrate scanning in tuberculous peritonitis. *Am J Gastroenterol* 71: 264-268, 1979.
12. Suga K, Nakagi K, Kuramitsu T, Itou K, Tanaka N, Uchisato H, et al. The role of Gallium-67 imaging in the detection of foci in recent cases of fever of unknown origin. *Ann Nucl Med* 5: 35-40, 1991.
13. Baran RJ, Fratkin MJ. Gallium-67 Scanning of Tuberculous Peritonitis. *J Nucl Med* 17: 1020-1021, 1976.

14. Itoh K, Hayasaka T, Kuwabara S, Sasaki H, Saito H. Diffuse abdominal uptake of ^{67}Ga -citrate: report of three cases. *Jpn J Clin Radiol* 34: 1497–1500, 1989.
15. Shimoyama K, Ohashi K, Hayakawa M, Kitagawa A, Ohyama Y, Ishikawa T. Diffuse abdominal uptake on gallium imaging: report of 4 cases and review of the literature. *Jpn J Clin Radiol* 41: 487–490, 1996.
16. Miyazaki H, Asayama J, Sawada T, Toyoda T, Katsume H, Nakagawa M. A case of tuberculous peritonitis showing multiple encapsulated tuberculosis in the peritoneum and pleura. *Saishinigaku* 43: 876–881, 1988.
17. Ohta H, Komibuchi T, Tsuji K, Nasu K, Tomono N, Matsuoka S. Three cases of diffuse abdominal ^{67}Ga uptake. *Clinical Imagiology* 12: 1371–1373, 1996.
18. Roswig DM, Spencer RP. Decreased hepatic concentration of radiogallium- ^{67}Ga . *Semin Nucl Med* 14: 57–58, 1984.
19. Kissin MW, Williamson RCN. Gallium-67 scanning in pyrexia of unknown origin. *Br Med J* 2: 1330–1331, 1979.