

Reverse redistribution of Tc-99m-tetrofosmin in exercise myocardial SPECT in patients with hypertrophic cardiomyopathy

Hiroki SUGIHARA,* Yoko TANIGUCHI,** Noriyuki KINOSHITA,** Tomoki NAKAMURA,**
Satoshi HIRASAKI,** Akihiro AZUMA,** Yo USHIJIMA,* Chio OKUYAMA,*
Masao NAKAGAWA** and Tomoho MAEDA*

**Department of Radiology and **Second Department of Medicine, Kyoto Prefectural University of Medicine*

We examined the usefulness of Tc-99m-tetrofosmin in detecting exercise induced perfusion abnormalities in patients with hypertrophic cardiomyopathy (HCM) and to clarify time-related changes in myocardial distribution of Tc-99m-tetrofosmin after a single injection. We studied 44 consecutive patients with HCM by means of exercise/rest Tc-99m-tetrofosmin single photon emission computed tomography (SPECT). After injecting 370 MBq of Tc-99m-tetrofosmin at the peak exercise, the early SPECT imaging was performed at 30 min (EX-30) and the delayed imaging at 180 min (EX-180). Immediately after the delayed imaging, 740 MBq of Tc-99m-tetrofosmin was injected in the resting state, and the rest SPECT imaging was performed 30 min later. Exercise-induced regional perfusion defects and/or apparent reversible left ventricular cavity dilation were identified in 26 (68.2%) of the 44 patients. When EX-30 images and EX-180 images were compared, reverse redistribution was confirmed in 36 patients (81.8%). Reverse redistribution was detected most frequently in the septal portion of the anterior wall, followed by the septal portion of the posterior wall and the septum. Exercise/rest Tc-99m-tetrofosmin myocardial imaging was a useful method for assessing myocardial perfusion abnormalities in patients with HCM. Reverse redistribution was detected very frequently on early and delayed images of exercise. We assumed that reverse redistribution may reflect a retention disorder of Tc-99m-tetrofosmin caused by some metabolic dysfunction of myocytes.

Key words: Tc-99m-tetrofosmin, hypertrophic cardiomyopathy, myocardial ischemia, reverse redistribution

INTRODUCTION

Tc-99m-TETROFOSMIN is a myocardial perfusion agent with favorable imaging characteristics.¹ Many studies have reported on the clinical usefulness of stress Tc-99m-tetrofosmin myocardial scintigraphy to detect coronary artery disease.¹⁻⁵ This tracer was reported to be rapidly cleared from the blood after intravenous administration and taken up by the myocardium and other tissues. Once Tc-99m-tetrofosmin is taken up by the myocardium, it is

considered that its clearance is relatively slow, and that redistribution does not occur for several hours.⁶ Although myocardial images with Tc-99m-tetrofosmin are believed to be uninfluenced by the starting time of acquisition after injection, we noted that myocardial images with this tracer often showed more reduced tracer uptake on delayed images than on early images in patients with hypertrophic cardiomyopathy, acute myocardial infarction or complete left bundle branch block.⁷ On the other hand, myocardial ischemia may play an important role in the pathophysiology and the natural history of hypertrophic cardiomyopathy, and exercise TI-201 myocardial single photon emission computed tomography (SPECT) has provided a noninvasive means of identifying myocardial perfusion abnormalities.⁸⁻¹² A few studies have reported the assessment of myocardial perfusion abnormalities in

Received June 24, 1998, revision accepted August 24, 1998.

For reprint contact: Hiroki Sugihara, M.D., Department of Radiology, Kyoto Prefectural University of Medicine, Kajicho, Kawaramachi Hirokoji, Kamigyo-ku, Kyoto 602-0841, JAPAN.

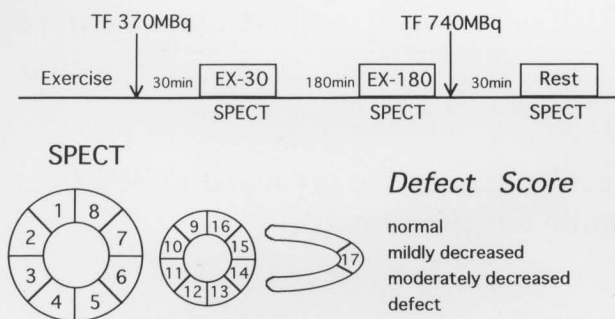


Fig. 1 Study protocol (upper). At peak exercise 370 MBq of Tc-99m-tetrofosmin (TF) was injected and SPECT was performed 30 min (EX-30) and 180 min (EX-180) later. After EX-180 imaging, 740 MBq of TF was injected at rest, and SPECT (REST) was performed 30 min later. A 4-point scoring system (lower). The basal and mid left ventricular levels of the short axial view and the apical portion of the long axial view of SPECT were divided into 17 segments. A 4-point scoring system was used to evaluate myocardial uptake in each segment.

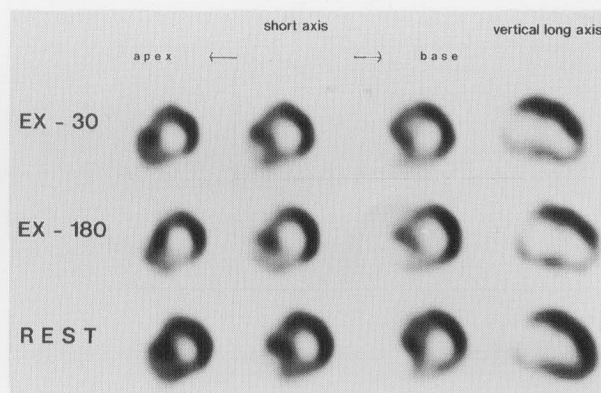


Fig. 3 Tc-99m-tetrofosmin SPECT images in a 56-year-old man with hypertrophic cardiomyopathy. Decreased uptake is observed in the septal portion of the anterior and posterior walls, the apex and the postero-inferior walls in the EX-30 images. In the EX-180, reverse redistribution is seen in the same segments and the septum.

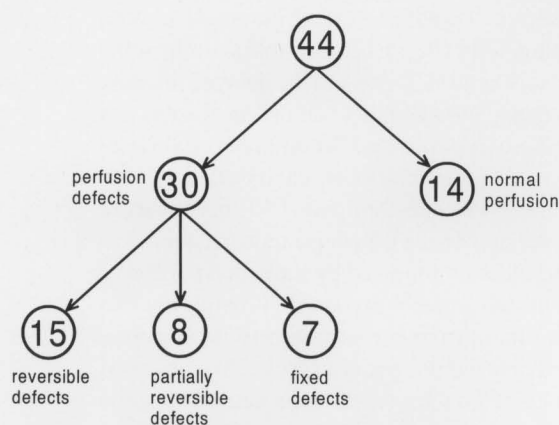


Fig. 2 Flow diagrams showing the prevalence and type of perfusion abnormalities in 44 patients with hypertrophic cardiomyopathy. Numerals within circles indicate the number of patients.

patients with hypertrophic cardiomyopathy with exercise/rest Tc-99m-tetrofosmin SPECT.¹² The present study was performed to determine the usefulness of Tc-99m-tetrofosmin in detecting exercise-induced perfusion abnormalities in patients with hypertrophic cardiomyopathy and to clarify time-related changes in myocardial distribution of Tc-99m-tetrofosmin after a single injection.

METHODS

Patient population

The subjects were 44 patients with hypertrophic cardiomyopathy (average age: 55 ± 10 years, 32 males and 12 females). The diagnosis of hypertrophic cardiomyopathy was based on clinical findings and the echocardiographic

demonstration of unexplained left ventricular hypertrophy. Of the 44 patients, 25 were asymptomatic, 17 had mild symptoms (New York Heart Association functional class II), and 2 had moderate symptoms (class III). There were 36 non-obstructive cases and 8 obstructive cases, and the maximum wall thickness and left ventricular % shortening fraction measured by 2 dimensional echocardiography was 23 ± 7 mm and $49 \pm 6\%$, respectively. All patients had normal coronary angiographic findings. Twenty-three patients received either a Ca channel blocker or a β -blocker and 21 patients did not take medication. Drug administration was suspended for 48 hours before myocardial scintigraphy.

Exercise/rest Tc-99m-tetrofosmin SPECT

All patients underwent bicycle exercise according to a standard multi-stage exercise protocol with continuous monitoring of heart rate, blood pressure, ECG and symptoms. At peak exercise, 370 MBq of Tc-99m-tetrofosmin was intravenously injected and the patient continued to exercise for an additional 1 minute and 30 seconds. Immediately after the injection, each patient drank a glass of milk to accelerate the hepatobiliary clearance of the tracer. SPECT data acquisition was performed twice; early and delayed imaging started 30 and 180 minutes post injection, respectively (EX-30 and EX-180). After EX-180 imaging, 740 MBq of Tc-99m-tetrofosmin was injected intravenously at rest, and each patient drank another glass of milk. SPECT imaging (Rest) was performed 30 minutes later¹³ (Fig. 1). A digital gamma camera (Prism 2000XP; Picker International Inc., Ohio or GCA 901A; Toshiba Co. Ltd., Tokyo) equipped with a low energy, high resolution, parallel-hole collimator was used for SPECT imaging. Projection images were taken for 30-sec 6° increments over 180° circular orbits beginning at 45° left posterior oblique projection and ending at 45°

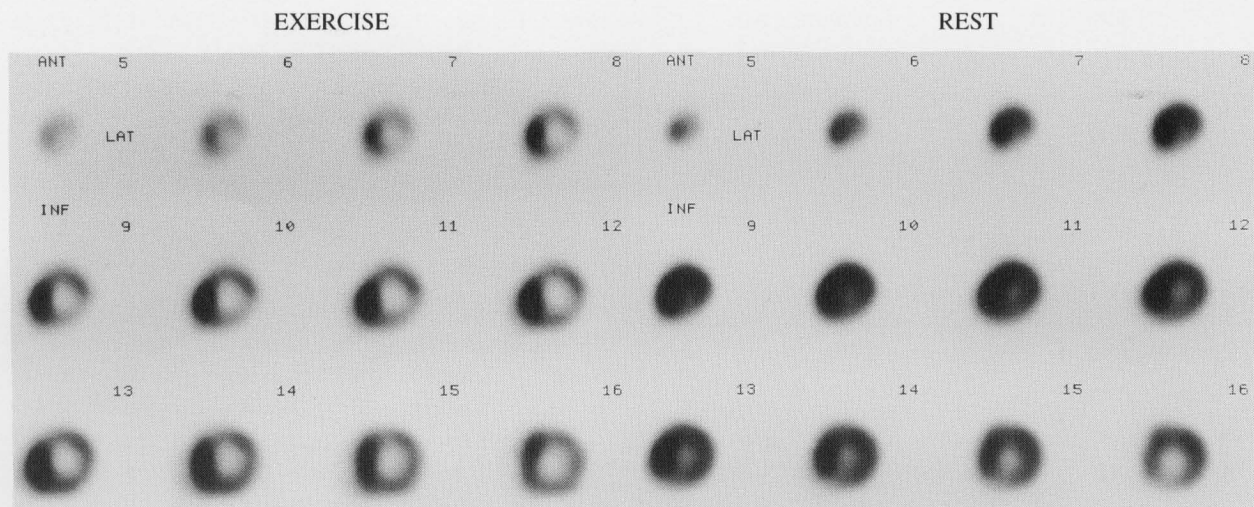


Fig. 4 Short-axis images obtained after exercise (left) and under resting conditions (right) in a 39-year-old man with HCM. Apparent exercise-induced cavity dilation is evident.

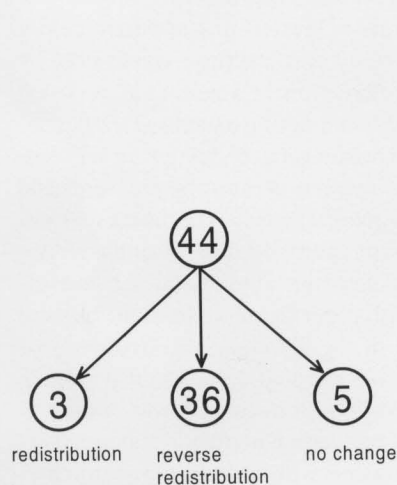


Fig. 5 Comparison of EX-30 and EX-180 in all 44 patients.

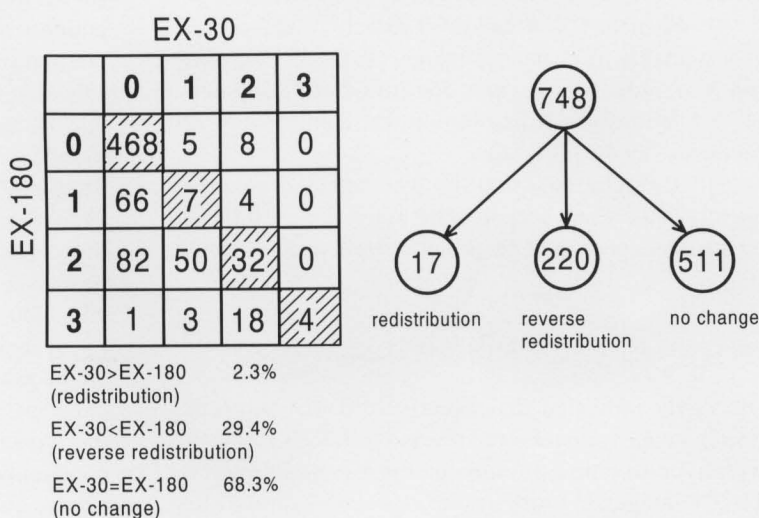


Fig. 6 Comparison of EX-30 and EX-180 in all 748 segments.

right anterior oblique projection. After a preprocedure with a Butterworth filter, transverse axial tomograms of 5.3 mm thickness per slice were reconstructed with a Shepp-Logan filter without correction for attenuation or scatter. The left ventricle was divided into 17 segments as follows: the basal and middle regions of the short axis were divided into 8 segments, and the apical region of the vertical long axis made up the 17th segment. A 4-point scoring system was used to evaluate the regional myocardial uptake of the tracer: defect = 3, moderately decreased = 2, mildly decreased = 1, and normal = 0 (Fig. 1). A score of 2 or 3 was considered to represent a defect. To compare EX-30 and EX-180 images, redistribution was defined as a segment showing an improved score on the EX-180 images, and reverse redistribution was defined as a segment showing a worsened score. The images were ana-

lyzed by 2 experienced observers in a blind manner.

RESULTS

(1) Regional perfusion defects were identified in 30 (68.2%) of the 44 study patients on the EX-30 images. Fifteen of the 30 patients had perfusion abnormalities on the EX-30 images that completely normalized on the Rest images. Partially reversible defects were observed in 8, and fixed defects were observed in 7 of the 30 patients (Figs. 2 and 3).

(2) Regarding EX-30 and Rest images, apparent reversible left ventricular cavity dilation was observed on the short axial images of 9 of the 44 patients (20.5%) (Fig. 4). Completely or partially reversible defects were absent in 3 of the 9 patients. Exercise-induced regional perfusion

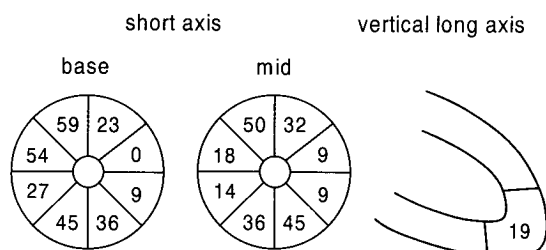


Fig. 7 Schematic presentation of the frequency of the segments showing reverse redistribution. Numerals indicate frequency (%) in 44 patients.

defects and/or apparent reversible left ventricular cavity dilation was detected in 26 of the 44 patients (59.1%).

(3) When the EX-30 and EX-180 of each patient were compared, no changes were detected in 5 patients (11.4%), redistribution was confirmed in 3 patients (6.8%) and reverse redistribution was confirmed in 36 patients (81.8%) (Figs. 3 and 5).

(4) When the EX-30 and EX-180 were compared in all 748 segments, no changes were detected in 511 segments (68.3%), redistribution was confirmed in 17 segments (2.3%) and reverse redistribution was confirmed in 220 segments (29.4%) (Fig. 6).

(5) Reverse redistribution was detected most frequently in the septal portion of the anterior wall, followed by the septal portion of the posterior wall, and the septum (Fig. 7).

DISCUSSION

Our study indicated that exercise/rest Tc-99m-tetrofosmin images often showed reversible defects in patients with hypertrophic cardiomyopathy, as well as exercise TI-201 images.¹³ Furthermore, we demonstrated that the time-related changes in myocardial distribution of Tc-99m-tetrofosmin after a single injection was evident in patients with hypertrophic cardiomyopathy. This reverse redistribution was frequently observed in the septal portion of the anterior and posterior walls and septal wall, where myocardial architectural abnormalities may be most severe in patients with hypertrophic cardiomyopathy.¹⁴

Many studies have reported that myocardial ischemia plays an important role in the natural history of hypertrophic cardiomyopathy.¹⁵⁻¹⁷ Exercise TI-201 myocardial scintigraphy has provided a noninvasive means of identifying myocardial perfusion abnormalities in patients with hypertrophic cardiomyopathy.^{7,8,9,17} Tc-99m-tetrofosmin has now been introduced into clinical routine. The present study was performed to determine the usefulness of Tc-99m-tetrofosmin in detecting exercise-induced perfusion abnormalities in patients with hypertrophic cardiomyopathy. Once Tc-99m-tetrofosmin is taken up by the myocardium, it is retained for a relatively long

time. It has been thought that the time-related changes in myocardial distribution of the tracer do not occur for several hours.^{3,5} Although the myocardial distribution of Tc-99m-tetrofosmin is believed to be uninfluenced by the starting time of acquisition after injection, serial changes in its distribution after a single injection were also analyzed.

(1) Detection of myocardial perfusion abnormalities by exercise/rest Tc-99m-tetrofosmin myocardial SPECT

Previous studies demonstrated that Tc-99m-tetrofosmin is rapidly cleared from the blood and accumulates in the myocardium in proportion to regional myocardial perfusion after intravenous administration. In the present study, since EX-30 and Rest images represented myocardial perfusion during exercise and at rest, respectively, exercise-induced regional myocardial perfusion abnormalities were detected even in the absence of coronary stenosis in 56.7% of the patients. Apparent left ventricular cavity dilation during exercise was observed in 31.8% of patients. O'Gara et al. suggested that apparent cavity dilation in a TI-201 study after exercise was caused by subendocardial hypoperfusion.⁷ Cannon et al. reported that apparent cavity dilation during exercise TI-201 scintigraphy indicates ischemia-related changes in left ventricular filling, with elevation in diastolic pressures and endocardial compression.¹⁸ If exercise-induced regional defects and/or apparent cavity dilation during exercise were to be myocardial perfusion abnormalities, then exercise-induced myocardial perfusion abnormalities were confirmed in 59.1% of the patients. The frequency of HCM showing exercise-induced myocardial perfusion abnormalities with Tc-99m-tetrofosmin was similar to that with TI-201.⁷ As myocardial perfusion abnormalities commonly occur in patients with hypertrophic cardiomyopathy even in the absence of angiographical coronary stenosis, whether TI-201 or Tc-99m-tetrofosmin is superior in detecting myocardial perfusion abnormalities in patients with hypertrophic cardiomyopathy is difficult to determine. Nonetheless, Tc-99m-tetrofosmin may be considered to be excellent because myocardial images with TI-201 often show decreased uptake in the inferior wall by attenuation due to its low-energy photons, and because the image quality of Tc-99m-tetrofosmin SPECT is superior to that of TI-201 SPECT. Further studies are necessary to investigate whether or not differences in the myocardial images of patients with hypertrophic cardiomyopathy are caused by the differences in the mechanism of uptake into myocytes and the physical properties of the 2 tracers.

(2) Early and delayed exercise Tc-99m-tetrofosmin SPECT

Although the myocardial uptake of Tc-99m-tetrofosmin is mainly dependent on the blood flow, the precise mechanism of uptake of this tracer into myocytes has not been

elucidated. The results of a recent study on isolated rat heart suggested that the uptake by myocytes is not achieved by cation channel transport, as it is for Tl-201, but rather is achieved by a metabolism-dependent process. The most likely uptake mechanism is thought to be potential driven diffusion on the lipophilic cations across the sarcolemmal and mitochondrial membranes.^{19,20} Once Tc-99m-tetrofosmin is taken up by the myocardium, it is retained for a relatively long time. It has been thought that the time-related changes in myocardial distribution of the tracer do not occur for 3 to 4 hours.^{3,5} Since the biokinetics of Tc-99m-tetrofosmin have not been fully clarified, in our facilities all SPECT data of Tc-99m-tetrofosmin were obtained twice; an early image 30 min and a delayed image 180 min after administration of this tracer. We noted cases showing a significant difference between early and delayed images, including those with acute myocardial infarction and complete left bundle branch block.⁷ Hypertrophic cardiomyopathy is one of the diseases with this unusual finding.

Reverse redistribution of Tc-99m-tetrofosmin was confirmed in 81.8% of patients with hypertrophic cardiomyopathy. Reverse redistribution was frequently observed in the septal portion of the anterior and posterior walls and the septum. The mechanism of reverse redistribution of Tc-99m-tetrofosmin that occurred in patients with hypertrophic cardiomyopathy is not known. Kuribayashi et al. reported that in patients with hypertrophic cardiomyopathy, both fascicle disarray and myocardial fibrosis were predominant in the septal portion of the anterior and posterior walls,¹⁴ in which reverse redistribution of Tc-99m-tetrofosmin was frequently detected in the present study. Therefore, reverse redistribution of Tc-99m-tetrofosmin in patients with hypertrophic cardiomyopathy may be related to myocardial architectural abnormalities. Regarding the mechanism of the uptake of Tc-99m-tetrofosmin by myocytes, Younes et al. reported that Tc-99m-tetrofosmin accumulation by the mitochondria of myocytes is related to the ability of this tracer to transduce metabolic energy into electron-negative membrane potential.^{19,20} Considering this experimental result, we speculated that in patients with hypertrophic cardiomyopathy the ability of this tracer to transduce metabolic energy into membrane potential is impaired for some undefined reasons, causing the relatively rapid clearance of Tc-99m-tetrofosmin from the septal portion of the anterior and posterior walls and the septum. The detection of reverse redistribution by early and delayed Tc-99m-tetrofosmin SPECT after a single injection may provide useful information regarding metabolism in myocytes. Furthermore, as we previously mentioned,²¹ I-123- β -methyl-p-iodophenyl-pentadecanoic acid (I-123-BMIPP) myocardial SPECT in hypertrophic cardiomyopathy often shows defects in the anterior and posterior junctional segments and septum in which reverse redistribution of Tc-99m-tetrofosmin was frequently observed. Therefore, it was

suggested that the mechanism of reverse redistribution of Tc-99m-tetrofosmin may be related to abnormalities of fatty acid metabolism in patients with hypertrophic cardiomyopathy. To confirm this, it is necessary to investigate the correlation between reverse redistribution of Tc-99m-tetrofosmin SPECT and I-123-BMIPP SPECT abnormalities in the same patients.

Study limitation

We determined myocardial uptake of the tracer by visual inspection. To verify our visual impression of the reverse redistribution, it may be necessary to calculate the regional washout rate of Tc-99m-tetrofosmin in EX-30 and EX-180 in patients with hypertrophic cardiomyopathy and control subjects. In the present study, images obtained 30 and 180 minutes after exercise were compared, but it is necessary to investigate whether or not similar findings are found in early and delayed images at rest.

CONCLUSIONS

Exercise/rest Tc-99m-tetrofosmin myocardial imaging was a useful method for assessing myocardial perfusion abnormalities in patients with hypertrophic cardiomyopathy. Reverse redistribution was detected at high frequency in early and delayed images of exercise. We assumed that reverse redistribution may reflect a retention disorder of Tc-99m-tetrofosmin caused by some metabolic dysfunction of myocytes.

REFERENCES

1. Tamaki N, Takahashi N, Kawamoto M, Torizuka T, Tadamura E, Yonekura Y, et al. Myocardial tomography using technetium-99m-tetrofosmin to evaluate coronary artery disease. *J Nucl Med* 35: 594-600, 1994.
2. Sridhara BS, Braat S, Rigo P, Itti R, Cload P, Lahiri A, et al. Comparison of myocardial perfusion imaging with technetium-99m tetrofosmin versus thallium-201 in coronary artery disease. *Am J Cardiol* 72: 1015-1019, 1993.
3. Jain D, Wackers FJT, Mattera J, McMahon M, Sinusas AJ, Zaret BL. Biokinetics of technetium-99m-tetrofosmin: myocardial perfusion imaging agent: implications for a one-day imaging protocol. *J Nucl Med* 34: 1254-1259, 1993.
4. Zaret BL, Rigo P, Wackers FJT, Hendel RC, Braat SH, Iskandrian AS, et al. Myocardial perfusion imaging with ^{99m}Tc tetrofosmin. Comparison to ²⁰¹Tl imaging and coronary angiography in a phase III multicenter trial. *Circulation* 91: 313-319, 1995.
5. Kinoshita N, Sugihara H, Nakamura T, Ito K, Azuma A, Maeda T, et al. A calculation of an index of the coronary flow reserve using exercise and rest myocardial SPECT with ^{99m}Tc-tetrofosmin. *KAKU IGAKU (Jpn J Nucl Med)* 34: 45-48, 1997.
6. Nakajima K, Taki J, Shuke N, Bunko H, Takata S, Hisada K. Myocardial perfusion imaging and dynamic analysis with technetium-99m-tetrofosmin. *J Nucl Med* 34: 1478-

- 1484, 1993.
7. Sugihara H, Kinoshita N, Adachi Y, Taniguchi Y, Ohtsuki K, Hirasaki S, et al. Early and delayed Tc-99m-tetrofosmin myocardial SPECT in patients with left bundle branch block. *Ann Nucl Med* 12: 281–286, 1998.
8. O'Gara PT, Bonow RO, Maron BJ, Damske BA, Van Lingen A, Bacharach SL, et al. Myocardial perfusion abnormalities in patients with hypertrophic cardiomyopathy: assessment with thallium-201 emission computed tomography. *Circulation* 76: 1214–1223, 1987.
9. Udelson JE, Bonow RO, O'Gara PT, Maron BJ, Van Lingen A, Bacharach SL, et al. Verapamil prevents silent myocardial perfusion abnormalities during exercise in asymptomatic patients with hypertrophic cardiomyopathy. *Circulation* 79: 1052–1060, 1989.
10. Taniguchi Y, Sugihara H, Terada K, Ito K, Ohtsuki K, Shiga K, et al. Myocardial ischemia and abnormality of cardiac sympathetic nervous function in apical hypertrophic cardiomyopathy. *J Cardiol* 24: 293–298, 1994.
11. Cannon III RO, Rosing DR, Maron BJ, Leon MB, Bonow RO, Watson RM, et al. Myocardial ischemia in patients with hypertrophic cardiomyopathy: contribution of inadequate vasodilator reserve and elevated left ventricular filling pressures. *Circulation* 71: 234–243, 1985.
12. Dilsizian V, Bonow RO, Epstein SE, Fananapazir L. Myocardial ischemia detected by thallium scintigraphy is frequently related to cardiac arrest and syncope in young patients with hypertrophic cardiomyopathy. *J Am Coll Cardiol* 22: 796–804, 1993.
13. Ohtsuki K, Sugihara H, Taniguchi Y, Umamoto I, Nakagawa T, Nakamura T, et al. Evaluation of myocardial perfusion and ventricular shape in hypertrophic cardiomyopathy using ^{99m}Tc-tetrofosmin scintigraphy: comparison with ²⁰¹Tl myocardial scintigraphy. *KAKU IGAKU (Jpn J Nucl Med)* 31: 309–318, 1994.
14. Kuribayashi T, Roberts WC. Myocardial disarray at junction of ventricular septum and left and right ventricular free walls in hypertrophic cardiomyopathy. *Am J Cardiol* 70: 1333–1340, 1992.
15. Thompson DS, Naqvi N, Juul SM, Swanton RH, Coltart DJ, Jenkins BS, et al. Effects of propranolol on myocardial oxygen consumption: substrate extraction and hemodynamics in hypertrophic obstructive cardiomyopathy. *Br Heart J* 44: 488–498, 1980.
16. Weiss MB, Ellis K, Sciacca RR, Johnson LL, Schmidt DH, Cannon PJ. Myocardial blood flow in congestive and hypertrophic cardiomyopathy. Relationship to peak wall stress and mean velocity of circumferential fiber shortening. *Circulation* 54: 484–494, 1976.
17. Pitcher D, Wainwright R, Maisy M, Curry P, Sowton E. Assessment of chest pain in hypertrophic cardiomyopathy using exercise Thallium-201 myocardial scintigraphy. *Br Heart J* 44: 650–656, 1980.
18. Cannon III RO, Dilsizian V, O'Gara PT, Udelson JE, Schenke WH, Quyyumi A, et al. Myocardial metabolic, hemodynamic, and electrocardiographic significance of reversible thallium-201 abnormalities in hypertrophic cardiomyopathy. *Circulation* 83: 1660–1667, 1991.
19. Platts EA, North TL, Pickett RD, Kelly JD. Mechanism of uptake of technetium-tetrofosmin. I: uptake into isolated adult rat ventricular myocytes and subcellular localization. *J Nucl Cardiol* 2: 317–326, 1995.
20. Younes A, Songadele JA, Maublant J, Platts E, Pickett R, Veyre A. Mechanism of uptake of technetium-tetrofosmin. II: uptake into isolated adult rat heart mitochondria. *J Nucl Cardiol* 2: 327–333, 1995.
21. Ohtsuki K, Sugihara H, Ito K, Matsumoto K, Taniguchi Y, Terada K, et al. The characteristic feature of myocardial imaging with ¹²³I-labeled 15-(p-iodophenyl)-3R,S-Methylpentadecanoic acid in hypertrophic cardiomyopathy with asymmetric septal hypertrophy. *KAKU IGAKU (Jpn J Nucl Med)* 32: 377–385, 1995.