

Dual-isotope SPECT diagnosis of a skull-base metastasis causing isolated unilateral hypoglossal nerve palsy

Mitsutaka FUKUMOTO,* Yasushi OSAKI,** Daisuke YOSHIDA,* Yasuhiro OGAWA,*
Masayoshi FUJIWARA,* Nobuhiro MIYAZAKI,* Atsushi KUROHARA,*
Naoki AKAGI* and Shoji YOSHIDA*

**Department of Radiology, and **Department of Medicine and Geriatrics, Kochi Medical School*

We describe a 48-year-old female with an isolated unilateral hypoglossal nerve palsy caused by a skull base metastasis from breast cancer. The patient had a medical history of conservative breast therapy for breast cancer. Although the cause of such a neurological deficit includes various pathologies, the reports focusing on metastatic tumor have been limited in number. Radiologic investigation showed a mass involving both the right hypoglossal canal and the clival edge. Swelling of the hypoglossal nerve was observed in views including its canal. Three-dimensional CT images demonstrated the tumor protruding from the enlarged external orifice of the hypoglossal canal. In the present report we mentioned a nuclear medicine procedure to visualize and characterize the small, abnormal tissue in the skull base. Dual-isotope SPECT confirmed an abnormal uptake of ^{99m}Tc -HMDP around the hypoglossal canal and a ^{201}Tl -positive elongated lesion running along the hypoglossal nerve.

Key words: hypoglossal nerve palsy, metastasis, breast cancer, SPECT, Tc-99m HMDP, Tl-201 Cchloride.

INTRODUCTION

ISOLATED unilateral hypoglossal nerve palsy is neurologically rare, and differential diagnosis of such nerve palsy includes various pathologies, but surprisingly a metastatic tumor is seldom the cause. So far the author has found only one report in the literature concerning a metastatic cause of such palsy.¹ The hypoglossal canal is located in a condylar structure that is anatomically complicated. It has been considered that CT and MRI are effective for imaging diagnosis in such a small, complicated area, and no nuclear medicine procedure has been taken into consideration because of poor spatial resolution.

CASE REPORT

A 48-year-old female admitted to our department com-

plained of tongue deviation and dysarthria without apparent cause. Prior to admission, she had received treatment for breast cancer including lumpectomy followed by chemotherapy and anti-estrogen medication over 13 months. Although she was diagnosed neurologically with isolated unilateral hypoglossal nerve palsy, no evidence of metastasis was present in the brain or brain stem. Despite suspicion of multiple metastases elsewhere on bone scintigraphy, the skull base showed no significant tracer uptake to account for her symptoms. Computed tomography with bone windows 2 mm thick revealed dilatation of the right hypoglossal canal (Fig. 1). Subsequently, MRI of the skull base detected a soft tissue mass enhancing slightly after Gd-DTPA administration and located in the area of the hypoglossal canal, also affecting the clival edge (Fig. 2). A multiplanar reconstruction CT (MPR-CT) image showed enlargement of the hypoglossal nerve (Fig. 3). A three-dimensional CT image taken in the right anterior direction displayed a tumor protruding from the dilated right hypoglossal canal (Fig. 1). Surgery for diagnosis and treatment was not performed because of the patient's preference and her unstable status suggestive

Received March 18, 1998, revision accepted May 22, 1998.

For reprint contact: Mitsutaka Fukumoto, M.D., Department of Radiology, Kochi Medical School, Kohasu, Okoh, Nankoku, Kochi 783-8505, JAPAN.

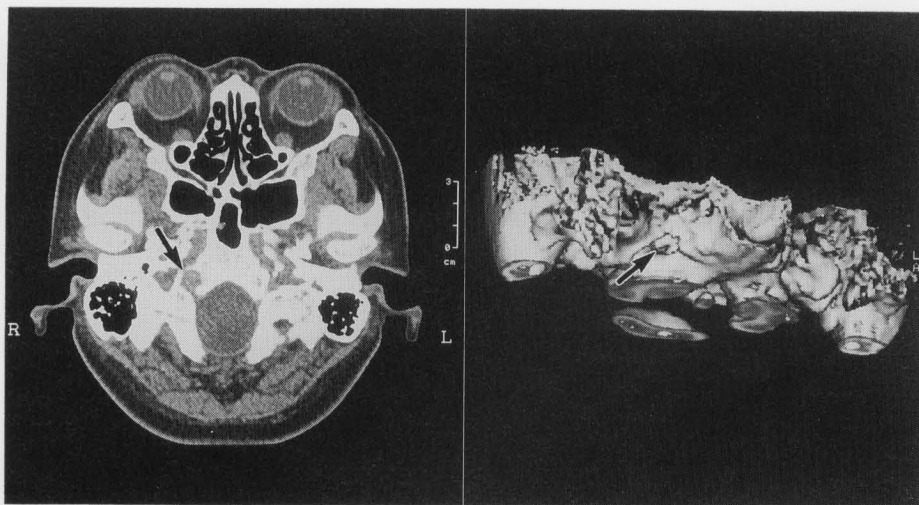

Fig. 1 The skull-base CT shows a markedly dilated right hypoglossal canal and erosive change involving the clival edge (arrow). The three-dimensional CT shows that the tumor arises from the external orifice of the right hypoglossal canal (arrow).

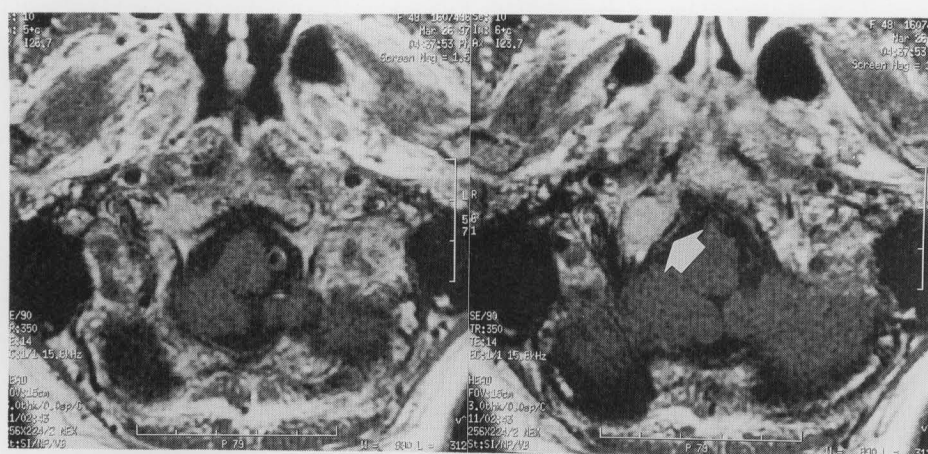


Fig. 2 T1-weighted magnetic resonance image with gadolinium-DTPA contrast obtained at the posterior skull base. (left, hypoglossal canal level; right, 2 mm cranial to canal level) A slightly enhanced lesion (arrow), 1.2 cm in diameter, involves the right clival edge, hypoglossal nerve, and canal.

of impending disseminated intravascular coagulation.

To determine whether or not the skull-base lesion was malignant, dual-isotope SPECT of the skull base was performed (Fig. 4). One portion of the dual-isotope SPECT was intended to visualize bone with ^{99m}Tc -HMDP and provide the details of the anatomic location of the lesion. The other portion of SPECT sought to assess prolonged retention of ^{201}Tl which is more specific for malignant tumors. Since a previous report,² improvements have been added to improve both image quality and diagnostic accuracy. Scanning included intravenous injection of ^{99m}Tc -HMDP (740 MBq) and ^{201}Tl (111 MBq) 3.0 hr before simultaneous SPECT for these isotopes. A three detector SPECT (Toshiba GCA9300A/HG, Tokyo) equipped with a fanbeam collimator with 7.3 mm spatial resolution (FWHM, at the rotation center) was used.

Simultaneously problematic crosstalk fractions, including ^{99m}Tc scatter in the ^{201}Tl energy window, were excluded by a triple energy window method.³

Although diagnosis made by morphological imaging included bone destruction around the hypoglossal canal and involvement of the hypoglossal nerve within the canal, characterization of the lesion was not possible, but in dual-isotope SPECT, an abnormal tracer uptake area of the lesion was strongly suggestive of malignancy including metastasis. We therefore selected chemotherapy including cyclophosphamide, adriamycin, and 5-FU (CAF). The hypoglossal nerve palsy improved dramatically, and the patient was discharged one month after admission.

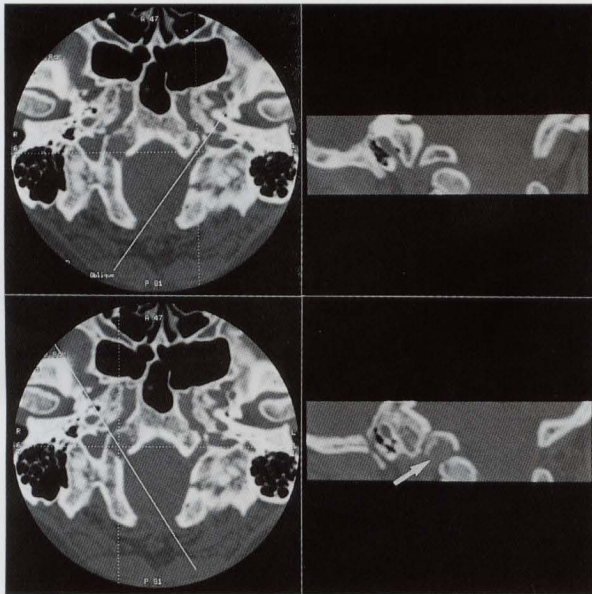


Fig. 3 Oblique-sagittal multiplanar reconstruction CT image of both hypoglossal canals and nerves. Although the left canal is normal (upper two panels), the right canal is dilated in association with nerve enlargement (lower panels, arrow). The posterior skull-base metastasis lies along the course of the nerve.

DISCUSSION

Breast cancer may metastasize to the skull base, particularly in or near the middle cranial fossa. Not uncommonly multiple cranial neuropathies may result. Neurologically an "isolated" hypoglossal nerve palsy is unusual, and an "isolated unilateral" hypoglossal nerve palsy is extremely rare. Although hypoglossal nerve palsy, coexisting with other cranial nerve palsies, may be due to unclear, iatrogenic, traumatic, or neoplastic causes,⁴⁻¹⁰ to our knowledge there is only one report dealing with metastasis responsible for "isolated unilateral" hypoglossal nerve palsy.¹

In our case, a major clinical problem was lack of the option of performing tumor biopsy or resection. Based on imaging findings, the mass was not a neurinoma, which should clearly show enhancement on CT and MRI,¹¹ but contrast MRI showed a slightly enhancing mass. There have also been very few reports on neurinoma analyzed by means of ²⁰¹Tl^{12,13}; in our 4 cases of cranial nerve neurinoma analyzed by ²⁰¹Tl SPECT, no significant ²⁰¹Tl retention occurred (unpublished data). Neurinomas typically arise from sensory cranial nerves and divisions, including the vestibular, cochlear, and trigeminal nerves. The hypoglossal nerve is a pure motor nerve and when motor nerves are involved in neurinoma, underlying neurofibromatosis is likely.¹⁴ As no clinical evidence of

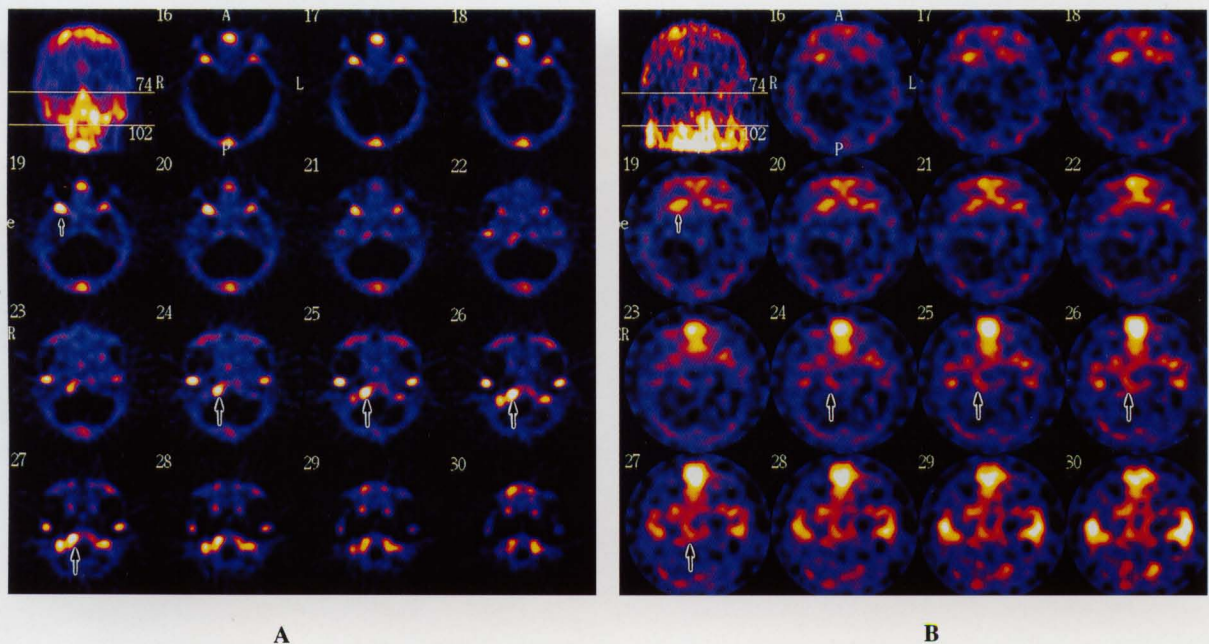


Fig. 4 Dual-isotope SPECT of the skull base. ^{99m}Tc-HMDP bone SPECT (A) and ²⁰¹Tl tumor SPECT (B) are shown. The tomographic level shown for the two isotopes is the same. A lesion with intense ^{99m}Tc-HMDP uptake and ²⁰¹Tl delayed retention is observed in the area of the right hypoglossal canal (arrow). The ²⁰¹Tl-positive lesion is elongated parallel to the long axis of the hypoglossal canal, indicating that the metastatic lesion spreads into the canal with direct involvement of the nerve (arrow). In the right middle cranial fossa, the sphenoid bone shows intense uptake of the tracers (small arrow) representing a suspicion of asymptomatic metastasis not shown by CT or MRI.

this condition was present in this case, the likelihood of neurinoma was extremely low.

In the field of nuclear oncology, ^{201}Tl has been a useful tumor-specific agent due to its retention by malignant lesions.^{15,16} Skull-base SPECT by means of $^{99\text{m}}\text{Tc}$ -HMDP and $^{201}\text{TlCl}$ is a highly sensitive and tumor-specific diagnostic method.² A major advantage of this simultaneous procedure is the ability to directly compare bone and tumor images in the same tomographic slice. In the present case, we strongly suspected that the lesion causing hypoglossal palsy was malignant because it showed prolonged ^{201}Tl retention and high $^{99\text{m}}\text{Tc}$ -HMDP accumulation around the hypoglossal canal. In addition to erosion of the hypoglossal canal and clivus, the most interesting MPR-CT finding is the enlarged nerve in its canal. Enlargement of the hypoglossal nerve suggests either swelling due to edema or direct involvement of the tumor; direct involvement was a reasonable possibility in this case. Tumor SPECT later confirmed an elongated ^{201}Tl -positive lesion running along the hypoglossal nerve (Fig. 4), and three-dimensional CT images visualized the tumor protruding from the enlarged external orifice of the hypoglossal canal. Moreover, a small lesion in the right middle cranial fossa, with $^{99\text{m}}\text{Tc}$ -HMDP uptake and prolonged ^{201}Tl retention, was visualized, suggesting metastasis. As we suggested in our previous report,² this SPECT method was able to visualize lesions not detectable by conventional CT or MRI. Treatment of isolated hypoglossal palsy is aimed at the underlying cause. This patient's dramatic neurologic recovery with chemotherapy is strong evidence indicating that the nerve palsy arose in a metastatic tumor.

In conclusion, we present a case of isolated unilateral hypoglossal nerve palsy caused by a skull-base metastasis from breast cancer. This rare situation was visualized as enlargement of the nerve in the hypoglossal canal, and confirmed by dual-isotope SPECT despite anatomic complexities in the skull base.

REFERENCES

1. Shiraishi T, Yanagida H, Takada K, Yasuhara Y. Unusual cranial metastasis from hepatoma presenting as isolated unilateral hypoglossal nerve paresis. *Neurol Med Chir* 32: 166-168, 1992.
2. Fukumoto M, Yoshida D, Yoshida S, et al. Dual-isotope SPECT of skull-base invasion of head and neck tumors. *J Nucl Med* 36: 1740-1746, 1995.
3. Ichihara T, Ogawa K, Motomura N, Kubo A, Hashimoto S. Compton scatter compensation using the triple energy window method for single- and dual-isotope SPECT. *J Nucl Med* 34: 2216-2221, 1993.
4. Robinson JS, Lopes J, Moody R. Intracranial hypoglossal neurinoma. *Surg Neurol* 12: 496-498, 1979.
5. Berger PS, Bataini JP. Radiation-induced cranial nerve palsy. *Cancer* 40: 152-155, 1977.
6. Hoare TJ, Manjalay G, Proops DW. Isolated hypoglossal nerve palsy caused by carotid artery aneurysm. *J Royal Soc Med* 86: 548-549, 1993.
7. Wright GD, Lee KD. An isolated right hypoglossal nerve palsy in association with infectious mononucleosis. *Postgrad Med J* 56: 185-186, 1980.
8. Felix JK, Schwartz RH, Myers GJ. Isolated hypoglossal nerve paralysis following influenza vaccination. *Am J Dis Child* 130: 82-83, 1976.
9. Talerma A, Magyar E. Hepatocellular carcinoma presenting with pathologic fracture due to bone metastases. *Cancer* 32: 1477-1481, 1973.
10. Millingen K, Pretince M. Isolated unilateral hypoglossal nerve palsy due to a chondroid chordoma. *Clin Exp Neurol* 23: 213-217, 1987.
11. Sato M, Kanai N, Fukushima Y, Matsumoto S, Tatsumi C. Hypoglossal neurinoma extending intra- and extracranially: case report. *Surg Neurol* 45: 172-175, 1996.
12. Charabi S, Lassen NA, Thomsen J, Rossen K, Jacobsen GK. Thallium chloride ^{201}Tl combined with single photon emission computed tomography (SPECT) in the evaluation of vestibular schwannoma growth. *Acta Otolaryngol* 117: 35-40, 1997.
13. Hirano T, Otake H, Kazama K, Wakabayashi K, Zama A, Shibasaki T, et al. Technetium-99m(V)-DMSA and thallium-201 in brain tumor imaging: correlation with histology and malignant grade. *J Nucl Med* 38: 1741-1749, 1997.
14. Berger MS, Edwards MSB, Bingham WG. Hypoglossal neurinoma. Case report and review of the literature. *Neurosurg* 10: 617-620, 1982.
15. Lebowitz E, Greene MW, Fairchild R, Bradley-Moore PR. Thallium-201 for medical use. 1. *J Nucl Med* 16: 151-155, 1975.
16. Tonami N, Shuke N, Yokoyama K, et al. Thallium-201 single photon emission computed tomography in the evaluation of suspected lung cancer. *J Nucl Med* 30: 997-1004, 1989.