

## A case of oophoritis detected by gallium-67-citrate scintigraphy

Susumu SHIOMI,\* Tetsuo KUROKI,\* Joji KAWABE,\*\* Hironobu OCHI,\*\*  
Kiyohiro AZUMA\*\*\* and Hironobu IMURA\*\*\*

*\*Third Department of Internal Medicine, and \*\*Division of Nuclear Medicine,  
Osaka City University Medical School*

*\*\*\*Nuclear Medicine, Ashihara Hospital*

A 39-year-old woman with fever of unknown origin was admitted to our hospital. Whole body scintigrams with  $^{67}\text{Ga}$ -citrate showed an abnormal accumulation of radioactivity in the pelvic cavity. Cystadenocarcinoma of the ovary was suspected on the basis of findings obtained by abdominal computed tomography and magnetic resonance imaging. Left oophorectomy was performed, and oophoritis was diagnosed. We would like to propose that  $^{67}\text{Ga}$ -citrate scintigraphy may be useful for the diagnosis of oophoritis as well as gynecologic malignant tumors.

**Key words:** oophoritis, gynecologic tumor, fever of unknown origin, Ga-67-citrate scintigraphy

### INTRODUCTION

$^{67}\text{Ga}$ -citrate scintigraphy is useful for the diagnosis of malignant tumors and inflammatory diseases.<sup>1–3</sup> It has also been used to differentiate malignant from benign gynecologic tumors,<sup>4,5</sup> but few reports have documented the diagnosis of inflammatory tumors by  $^{67}\text{Ga}$ -citrate scintigraphy in the field of gynecology,<sup>6</sup> and to our knowledge no study has evaluated the usefulness of this technique in patients with oophoritis. We report on a patient with fever of unknown origin in whom oophoritis was detected by  $^{67}\text{Ga}$ -citrate scintigraphy.

### CASE REPORT

A 39-year-old woman was admitted to our hospital because of lumbago and a high fever of 39.0°C. She had been hospitalized three times during the past year because of fever of unknown origin and responded to antibiotic therapy each time.

On admission, the patient was of moderate build and well-nourished. The white blood cell count was 10,600/mm<sup>3</sup>, the red blood cell count was  $428 \times 10^4/\text{mm}^3$ , the platelet count was  $54.0 \times 10^4/\text{mm}^3$ , the serum total protein was 7.4 g/dl, the serum albumin was 3.2 g/dl, the lactate dehydrogenase activity was 285 WU/L, the C-reactive protein concentration was 4.1 mg/dl, and the carcinoembryonic antigen concentration was 2.1 ng/ml.

After treatment with antibiotics, the body temperature decreased to 37.5°C, and the white blood cell count and C-reactive protein concentration fell to the normal range. To identify the cause of the fever of unknown origin, whole body scintigraphy with  $^{67}\text{Ga}$ -citrate was performed 10 days after admission.  $^{67}\text{Ga}$ -citrate scintigrams showed an accumulation of radioactivity in the lower abdomen, and this accumulation did not change when the patient assumed a standing position after urination (Fig. 1). Computed tomography (CT) of the abdomen performed 14 days after admission revealed a solid mass measuring 60 × 70 mm in the left ovary. The mass had a cystic region (Fig. 2). Magnetic resonance imaging (MRI) performed 20 days after admission depicted a solid mass in the left ovary; the region corresponding to the cystic component on the abdominal CT scan showed high intensity on T2-weighted images (Fig. 3). Cystadenocarcinoma of the ovary was suspected, and a left oophorectomy was performed.

The left ovary contained a tumor measuring 50 × 60

Received February 11, 1998, revision accepted April 16, 1998.

For reprint contact: Susumu Shiomi, M.D., Third Department of Internal Medicine, Osaka City University Medical School, 1–5–7 Asahimachi, Abeno-ku, Osaka 545–8586, JAPAN.

E-mail: shiomis@msic.med.osaka-cu.ac.jp

mm. The ovary partially adhered to the sigmoid colon (Fig. 4). Inflammatory cell infiltration and necrosis were found in the resected tissue. The tumor was diagnosed as oophoritis on histological examination.

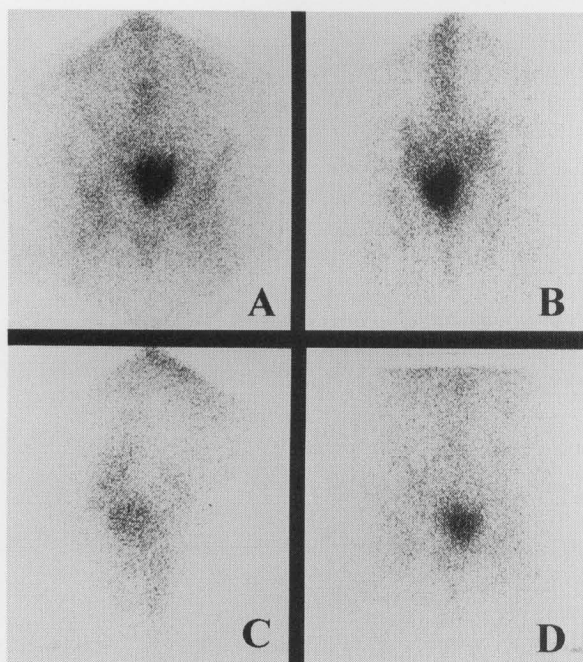
## DISCUSSION

There are many reports on the usefulness of  $^{67}\text{Ga}$ -citrate scintigraphy for the diagnosis of malignant lymphoma.<sup>1</sup> This technique has also been reported to be useful for the

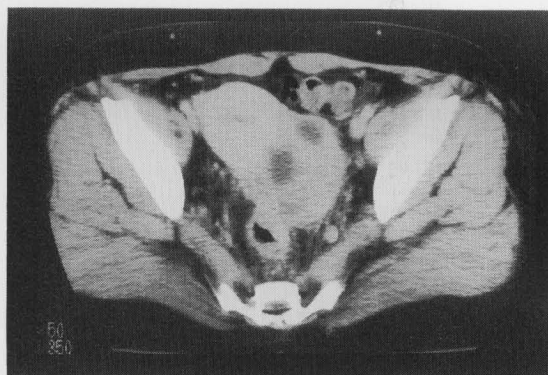
diagnosis of malignant tumors other than malignant lymphoma<sup>2</sup> as well as inflammatory diseases,<sup>3</sup> but the clinical usefulness of  $^{67}\text{Ga}$ -citrate scintigraphy for the diagnosis of malignant tumors and inflammatory diseases is still controversial.

Symmond et al.<sup>4</sup> reported that  $^{67}\text{Ga}$ -citrate scintigraphy was of limited value in the diagnosis of gynecologic tumors because radioactivity did not accumulate in 14 out of 27 cases. The diagnosis of gynecologic tumors is difficult because  $^{67}\text{Ga}$ -citrate is partially eliminated into the intestine lying over lesions<sup>7</sup> and because most gynecologic tumors are cystic.<sup>5</sup> Okamura et al.<sup>5</sup> compared the diagnostic accuracy of abdominal CT with that of  $^{67}\text{Ga}$ -citrate scintigraphy for ovarian tumors. Although these two techniques were of comparable diagnostic accuracy for solid tumors,  $^{67}\text{Ga}$ -citrate scintigraphy was significantly less accurate than abdominal CT for cystic tumors.

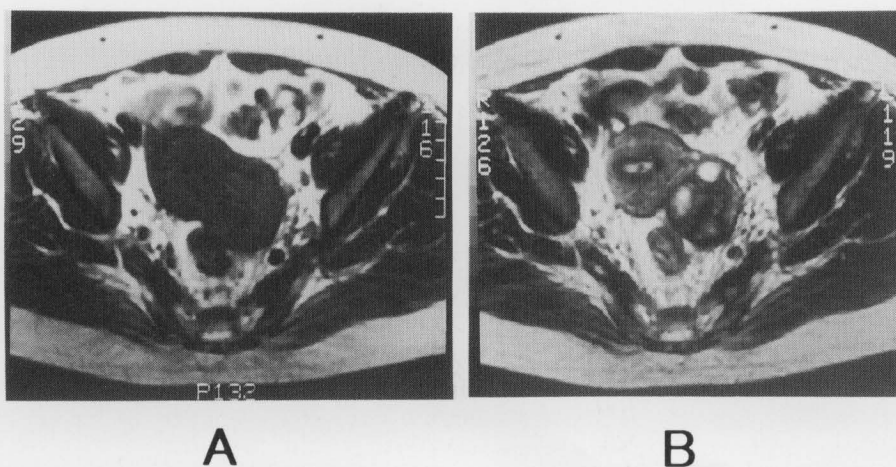
Sakai et al.<sup>6</sup> detected high accumulations of  $^{67}\text{Ga}$ -citrate in 8 of 12 patients with malignant tumors of gynecologic organs and low accumulations in 3 of them, but high



**Fig. 1**  $^{67}\text{Ga}$ -citrate scintigrams, showing an accumulation of radioactivity in the lower abdomen. (A) Anterior view. (B) Posterior view. (C) Right lateral view. (D) Anterior view with patient in the standing position.



**Fig. 2** Abdominal computed tomogram, showing a solid mass measuring 60 × 70 mm in the left ovary. The mass had a cystic region.



**Fig. 3** Magnetic resonance image, showing a solid mass in the left ovary. The region corresponding to the cyst on the abdominal computed tomographic scan shows high intensity on T2-weighted imaging. (A) T1-weighted image. (B) T2-weighted image.



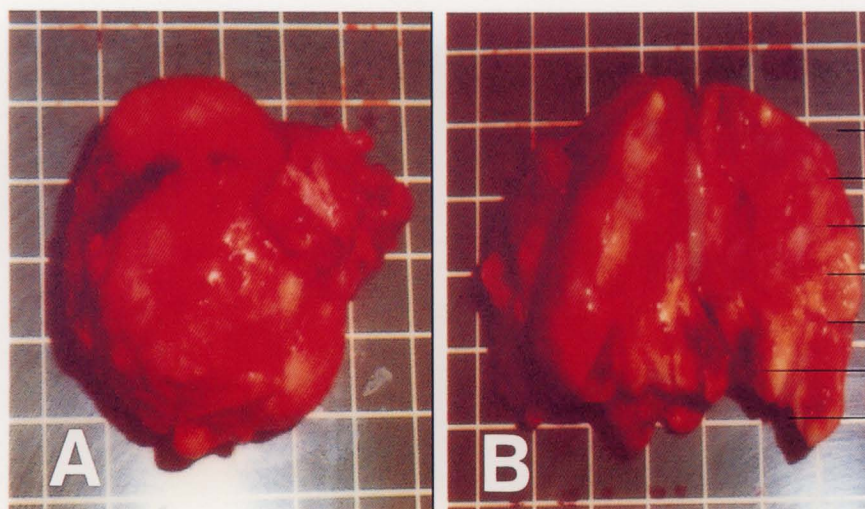


Fig. 4 (A) Resected left ovary including tumor. (B) Section of tumor and left ovary.

accumulations were not seen in any of 24 patients with benign tumors.  $^{67}\text{Ga}$ -citrate scintigraphy was therefore considered useful for distinguishing malignant from benign tumors. Differential diagnosis of malignant and benign tumors was concluded to be more difficult with CT or MRI than with  $^{67}\text{Ga}$ -citrate scintigraphy. Furthermore, they detected high accumulations of radioactivity in all three cases of intrapelvic abscess and stated that  $^{67}\text{Ga}$ -citrate scintigraphy was useful for the diagnosis of inflammatory diseases in the field of gynecology.  $^{67}\text{Ga}$ -citrate binds to transferrin and lactoferrin in the blood, circulates through the body in the bloodstream, and accumulates at the site of inflammation, where it is taken into macrophages and neutrophils.<sup>8</sup>

Okamoto et al.<sup>5</sup> and Sakai et al.<sup>6</sup> reported that most benign tumors and inflammatory tumors contain cystic lesions, whereas malignant tumors do not. A high accumulation of  $^{67}\text{Ga}$ -citrate with a mass containing a cystic lesion strongly suggests the presence of an inflammatory mass in the field of gynecology.

In our case, whole body scintigraphy with  $^{67}\text{Ga}$ -citrate was performed to identify the cause of the fever of unknown origin, and accumulation of radioactivity was seen in the lower abdomen. Caffee et al.<sup>9</sup> and Sfakianakis et al.<sup>10</sup> reported that  $^{67}\text{Ga}$ -citrate scintigraphy was useful for the diagnosis of inflammatory diseases of unknown origin.

$^{67}\text{Ga}$ -citrate scintigraphy has been considered unsuitable for the diagnosis of intrapelvic lesions because it is excreted in feces, but the presence of isotope in feces can be distinguished from isotope accumulation in tumors by taking anterior images as well as back and lateral images, or by the use of single-photon emission tomography.  $^{67}\text{Ga}$ -citrate scintigraphy may therefore be a useful tech-

nique for the diagnosis of gynecologic mass lesions.

## REFERENCES

1. Edwards CL, Hayes RL. Tumor scanning with  $^{67}\text{Ga}$  citrate. *J Nucl Med* 10: 103-105, 1969.
2. Winchell HS, Sanchez PD, Watanabe CK, Hollander L, Anger HO, McRae J. Visualization of tumors in humans using  $^{67}\text{Ga}$ -citrate and the anger whole-body scanner, scintillation camera and tomographic scanner. *J Nucl Med* 11: 459-466, 1970.
3. Lavender JP, Lowe J, Barker JR, Burn JJ, Chaudhri MA. Gallium 67 citrate scanning in neoplastic and inflammatory lesions. *Br J Radiol* 44: 361-366, 1971.
4. Symmonds RE, Tauxe WN. Gallium-67 scintigraphy of gynecologic tumors. *Am J Obstet Gynecol* 144: 356-369, 1972.
5. Okamura S. Diagnosis of ovarian tumors by CT and  $^{67}\text{Ga}$ -citrate scintigraphy. *Acta Obst Gynaec Jpn* 35: 805-813, 1983.
6. Sakai K, Kamiya H, Nagai S. Differential diagnosis of pelvic masses by computed tomography and  $^{67}\text{Ga}$ -scintigraphy. *Acta Obst Gynaec Jpn* 38: 39-44, 1986.
7. Smith FW, Dendy PP. Modification of gallium-67 citrate distribution in man following the administration of iron. *Br J Radiol* 54: 398-402, 1981.
8. Tzen K-Y, Oster ZH, Wagner HN, Tsan M-F. Role of iron-binding proteins and enhanced capillary permeability on the accumulation of gallium-67. *J Nucl Med* 21: 31-35, 1980.
9. Caffee HH, Watts G, Mena I. Gallium 67 citrate scanning in the diagnosis of intraabdominal abscess. *Am J Surg* 133: 665-669, 1977.
10. Sakianakis GN, Al-Sheikh W, Heal A, Rodman G, Zeppa R, Serafini A. Comparisons of scintigraphy with In-111 leukocytes and Ga-67 in the diagnosis of occult sepsis. *J Nucl Med* 23: 618-626, 1982.