

Acetazolamide induced myocardial ischemia in patients with severe coronary artery disease

Yoriko SHIMOTSU,* Kohei HAYASHIDA,* Norihiko KUME,*
Kazuki FUKUCHI* and Tsunehiko NISHIMURA**

**Department of Radiology, National Cardiovascular Center*

***Division of Tracer Kinetics, Biomedical Research Center, Osaka University Medical School*

Acetazolamide (ACZ)-augmented brain SPECT is commonly used for evaluating cerebral vascular reserve in patients with cerebrovascular disease. ACZ may cause myocardial ischemia in patients with coronary artery disease. To evaluate the risk of induction of myocardial ischemia with ACZ-augmented myocardial SPECT, we performed combined ACZ-augmented TI-201 myocardial SPECT (ACZ-myo SPECT) with Tc-99m HMPAO brain SPECT in patients with severe coronary artery disease. **Methods:** Nine patients underwent combined ACZ-myo SPECT with Tc-99m HMPAO brain SPECT. (1) For qualitative analysis, SPECT images were divided into 13 segments to calculate the total defect scores. (2) Six ROIs were placed on the slices in the myocardial SPECT short-axis images and the regional uptake ratio was obtained as the ratio of the mean counts in the myocardium to the maximal count in the slice. The total defect score and regional uptake ratio of ACZ-myo SPECT were compared with those of early and delayed dipyridamole TI-201 myocardial SPECT (DP-TI SPECT) images. **Results:** (1) In the 21 coronary artery territories with coronary stenosis $\geq 75\%$, the total defect score in ACZ-myo SPECT, early and delayed DP-TI SPECT images were $3.52 \pm 4.14^*$, $4.19 \pm 4.65^*$ and 2.25 ± 3.34 , respectively (*: $p < 0.05$ vs. delayed DP-TI SPECT images). (2) In 44 of 54 ROIs with coronary stenosis $\geq 75\%$, the regional uptake ratio of ACZ-myo SPECT, early and delayed DP-TI SPECT images were $0.670 \pm 0.166^{**}$, $0.677 \pm 0.194^{**}$, 0.721 ± 0.178 , respectively (**: $p < 0.01$ vs. delayed DP-TI SPECT images). Systolic blood pressure fell at 11 min after ACZ infusion without electrocardiographic ST-T changes or chest pain. **Conclusion:** As ACZ has the potential to cause myocardial ischemia, ACZ-augmented brain SPECT should be performed with caution in patients with severe coronary artery disease associated with cerebrovascular disease.

Key words: acetazolamide, myocardial ischemia, coronary artery disease, cerebrovascular disease, SPECT

INTRODUCTION

ACETAZOLAMIDE (ACZ), a carbonic anhydrase inhibitor, is useful for evaluating cerebral vascular reserve in patients with cerebrovascular disease.¹⁻⁴ Because patients with coronary artery disease often have cerebral atherosclero-

sis,⁵⁻⁷ brain SPECT with ACZ has been applied for the evaluation of perioperative cerebrovascular risk in cardiovascular surgery including coronary artery bypass surgery.⁸ We previously reported a case in which myocardial SPECT with ACZ detected myocardial ischemia in a patient with severe coronary artery disease.⁹ We should therefore assess the effect of ACZ on myocardial perfusion to perform ACZ-augmented brain SPECT safely in clinical usage. In the present study, we compared the potential of ACZ to cause myocardial ischemia with that of dipyridamole in patients with severe coronary artery disease.

Received August 21, 1997, revision accepted October 13, 1997.

For reprint contact: Kohei Hayashida, M.D., Department of Radiology, National Cardiovascular Center, 5-7-1 Fujishirodai, Suita, Osaka 565-8565, JAPAN.

E-mail: khysd@hsp.ncvc.go.jp

MATERIALS AND METHODS

Patients

We examined 9 patients (4 men and 5 women; mean age 66 ± 5 yrs) with severe coronary artery disease who required coronary artery bypass surgery. Three of nine patients had previous myocardial infarction followed by angina pectoris and six had effort angina without myocardial infarction. Wall motion abnormalities in angiography associated with abnormal Q waves in electrocardiograms were defined as myocardial infarction. Effort angina was defined as chest pain on effort with diagnostic electrocardiographic ST-T changes and significant coronary stenosis ($\geq 75\%$) in coronary angiography. None of the patients underwent coronary revascularization during the acute phase of the ischemic attack. Patient profiles are shown in Tables 1 and 2. Upon carotid B-mode echography, the maximum percent of stenosis was calculated from the ratio of the residual lumen to the original diameter.¹⁰ Seven patients had significant stenosis ($\geq 75\%$) of the internal or common carotid artery and two had no significant stenosis of the internal carotid artery. All patients needed an evaluation of cerebrovascular reserve to assess perioperative cerebrovascular risk associated with coronary artery bypass surgery.

Dipyridamole myocardial SPECT and combined ACZ-augmented myocardial SPECT with Tc-99m HMPAO brain SPECT

After giving informed consent, the patients underwent combined ACZ-augmented thallium-201 myocardial SPECT (ACZ-myo SPECT) with Tc-99m hexamethylpropyleneamine oxime (HMPAO) brain SPECT, and dipyridamole thallium-201 myocardial SPECT (DP-Tl SPECT) over an average period of 15 ± 21 days (3–68 days). Their clinical condition remained unchanged between the two SPECT examinations. Fasting patients were placed in the supine position with their eyes covered by masks during the test.

ACZ (1,000 mg) was administered over a period of 1 min, and 111 MBq of Tl-201 and 555 MBq of Tc-99m HMPAO were simultaneously injected into the patients 10 min after ACZ infusion. Thallium-201 myocardial SPECT and Tc-99m HMPAO brain SPECT were performed 15 min and 1 hr post injection, respectively. Dipyridamole (0.56 mg/kg) was infused over 4 min into the supine patients. Three minutes thereafter, 111 MBq of thallium-201 (Tl-201) was injected, then early and delayed images were taken 15 min and 4 hr post injection, respectively. Blood pressure and heart rate, as well as a 12-lead electrocardiogram were recorded at the baseline and at 1-min intervals for 15 min and 9 min; during ACZ-myo SPECT and DP-Tl SPECT, respectively.

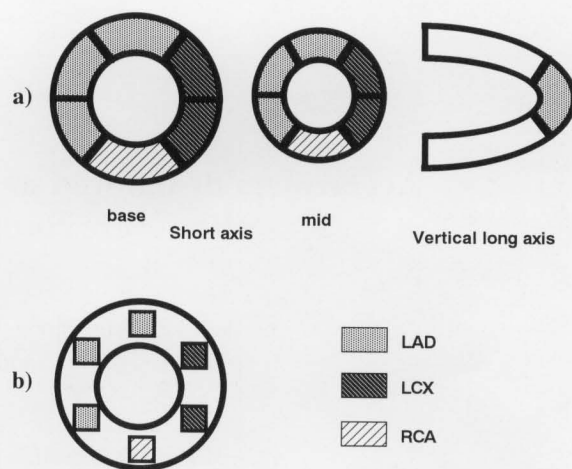
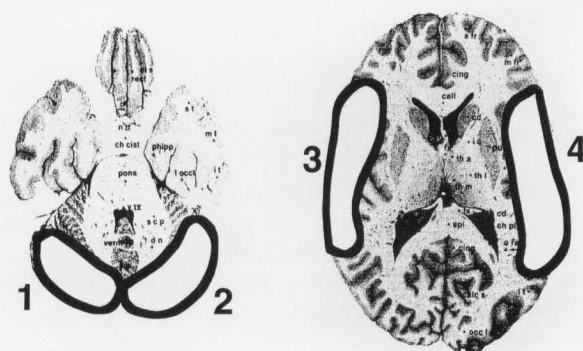


Fig. 1 a) Schemes of segments for grading regional defects qualitatively on myocardial SPECT images including the anterior, anterolateral, anteroapical, septal and apical segments in the left anterior descending artery territory (LAD); the posterolateral and lateral segments in the left circumflex artery territory (LCX); and the inferior segments in the right coronary artery territory (RCA). b) Schemes of ROIs on myocardial SPECT in the short-axis images including the anterior, anteroapical and septal ROIs in the left anterior descending artery territory, the lateral and posterolateral ROIs in the left circumflex artery territory and the inferior ROI in the right coronary artery territory.



R

Fig. 2 Schemes of ROIs on the brain SPECT. (1: ROI in the right cerebellum, 2: ROI in the left cerebellum, 3: ROI in the right middle cerebral artery territory, 4: ROI in the left middle cerebral artery territory, R: right.)

Data acquisition and processing

1) Myocardial SPECT

Myocardial images were taken by means of an L-shaped two-headed SPECT system (VERTEX EPIC, ADAC Co.) equipped with low-energy, general purpose collimators. For ACZ-myo SPECT, a total of 30 projection images were obtained over 180° in 6° increments, with 40 sec/step. The energy discriminator for Tl-201 was centered on 70 keV during ACZ-myo SPECT, and on 70 keV and 168 keV during DP-Tl SPECT, all of which were

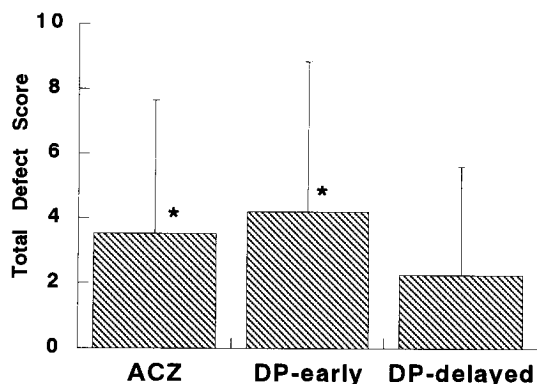


Fig. 3 Comparison of the total defect scores among acetazolamide-augmented myocardial SPECT, early and delayed dipyridamole-Tl-201 myocardial SPECT images. (ACZ: acetazolamide-augmented myocardial SPECT, DP-early: early dipyridamole-Tl-201 myocardial SPECT images, DP-delayed: delayed dipyridamole-Tl-201 myocardial SPECT images. *: $p < 0.05$ vs. delayed dipyridamole-Tl-201 myocardial SPECT images.)

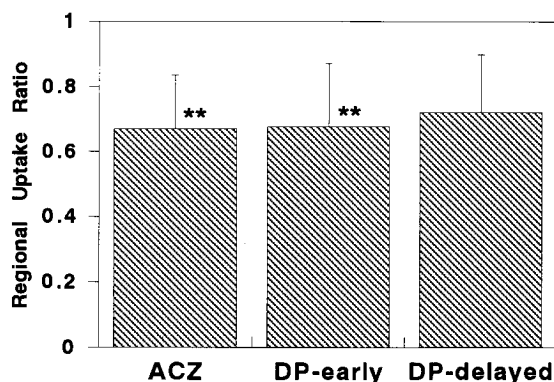


Fig. 4 Comparison of the regional uptake ratio among acetazolamide-augmented myocardial SPECT, early and delayed dipyridamole-Tl-201 myocardial SPECT images. **: $p < 0.01$ vs. delayed dipyridamole-Tl-201 myocardial SPECT images. Other abbreviations as in Fig. 3.

performed with a 20% window. Crosstalk correction was not employed. Filtered back-projection was performed for both Tl-201 myocardial imaging, with Ramp and Butterworth filters to reconstruct the 5 mm thick transverse tomogram slices.

2) Brain SPECT

Technetium-99m HMPAO brain SPECT was performed with a ring-type gamma camera (SET 070 Headtome, Shimadzu Co.) with an 8-mm FWHM. Image data from a 20-min acquisition in the SPECT study were collected in a 128×128 matrix with a general purpose collimator. All data were corrected for attenuation assuming a uniform attenuation coefficient (0.1 cm^{-1}), and the tomographic data were reconstructed by filtered back-projection.

Assessment of the myocardial and brain SPECTs

1) Myocardial SPECT

The myocardial perfusion was assessed by the two methods mentioned below.

First, the myocardial wall was divided into 13 segments by coronary artery territories for qualitative visual analysis in ACZ and dipyridamole-augmented myocardial SPECT images (Fig. 1a). Reconstructed tomographic slices were interpreted by means of consensus of three experienced observers unaware of the clinical and angiographic findings. The defect score of the segments in myocardial SPECTs was obtained by a visually grading scale from 0 to 3; 0 = no defect, 1 = mild defect, 2 = moderate defect, 3 = severe defect. The total defect score of the myocardial SPECTs was the sum of the defect scores in the coronary artery territories.

As the second method, six regions of interest (ROIs), 6×6 pixels ($4.3 \text{ mm} \times 4.3 \text{ mm}$) in size, were determined over the myocardium in the mid level of the short-axis images. Each ROI was divided according to the coronary arterial territories (Fig. 1b). The mean counts in each ROI were measured, then the regional uptake ratio was obtained as the ratio of the mean counts to the maximal counts in the slices of the SPECTs.

2) Brain SPECT

Four ROIs were manually placed on the middle cerebral artery territory and the cerebellum on the transverse slices (Fig. 2). The mean count per voxel was estimated in each ROI. If the mean count ratio of the middle cerebral artery territory to that of the bilateral cerebellum was more than 0.90 in ACZ-augmented brain SPECT, the perfusion reserve was considered to be normal.

Statistical analysis

Values are expressed as the means \pm SD. Comparisons of two mean values were performed by using a paired t test where p values < 0.05 were considered significant.

RESULTS

Comparison of acetazolamide and dipyridamole-augmented myocardial SPECT findings

1) Qualitative analysis

Twenty-one coronary artery territories had significant coronary stenosis. We compared the total defect score of ACZ-myo SPECT with that of DP-Tl SPECT. The total defect scores of ACZ-myo SPECT, and that of early and delayed DP-Tl SPECT images were 3.52 ± 4.14 , 4.19 ± 4.65 and 2.25 ± 3.34 , respectively (Fig. 3). The total defect score in ACZ-myo SPECT was significantly higher than that in delayed DP-Tl SPECT images ($p < 0.05$) but not significantly lower than that in early DP-Tl SPECT images.

2) Semiquantitative analysis

A total of 54 ROIs were divided into two groups according to the coronary artery territories; (1) Stenotic area: 44

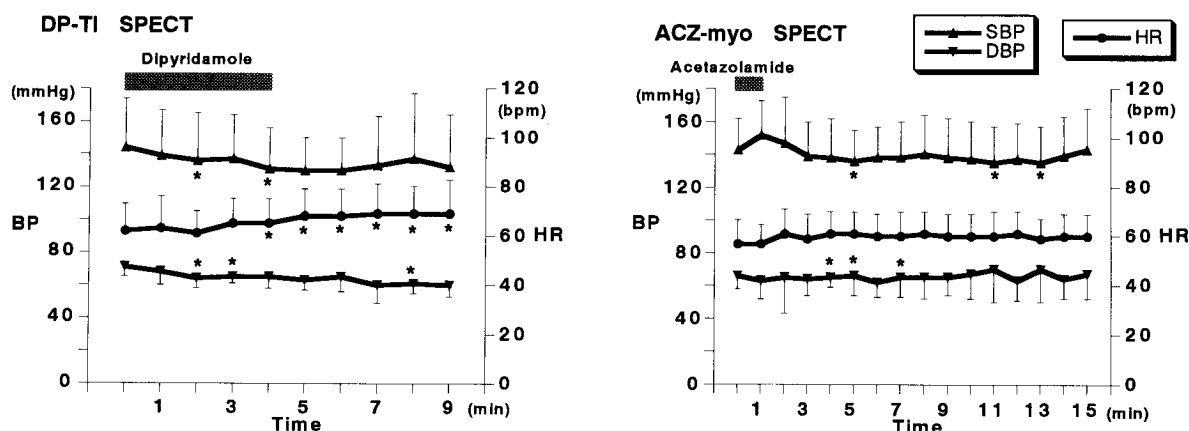


Fig. 5 Sequential change in blood pressure and heart rate after the injection of dipyridamole or acetazolamide. (BP: blood pressure, DBP: diastolic blood pressure, HR: heart rate, SBP: systolic blood pressure, other abbreviations as in Table 1. *: $p < 0.05$ vs. baseline.)

Table 1 Clinical, angiographic and scintigraphic data on coronary artery disease for study patients

Patient number	Age	Sex	Coronary disease	Stenosis in coronary angiography	DP-Tl SPECT		ACZ-myo SPECT	
					CP	ECG	CP	ECG
1	61	M	AP	LAD	-	-	-	-
2	76	F	AP	LMT, LAD, LCX	+	-	-	-
3	62	F	AP	LMT, LAD, LCX	+	+	-	-
4	59	F	AP	LAD, LCX, RCA	+	+	-	-
5	76	F	AP	LAD, LCX, RCA	+	+	-	-
6	65	M	AP	LAD, LCX, RCA	-	-	-	-
7	67	M	OMI (I) + AP	LCX, RCA	-	-	-	-
8	65	F	OMI (I) + AP	LAD, LCX, RCA	-	+	-	-
9	67	M	OMI (A) + AP	LAD, RCA	-	-	-	-

A: anterior, ACZ-myo SPECT: acetazolamide-augmented myocardial SPECT, AP: angina pectoris, CP: chest pain, DP-Tl SPECT: dipyridamole-thallium-201 myocardial SPECT, ECG: electrocardiographic ST-T change, F: female, I: inferior, LAD: left anterior descending artery, LCX: left circumflex artery, LMT: left main trunk, M: male, OMI: old myocardial infarction, RCA: right coronary artery, +: present, -: absent.

ROIs in the coronary artery territories with significant coronary stenosis ($\geq 75\%$), (2) Normal area: 10 ROIs in those without significant stenosis. In the stenotic area, the regional uptake ratios of ACZ-myo SPECT and early and delayed DP-Tl SPECT images were 0.670 ± 0.166 , 0.677 ± 0.194 and 0.721 ± 0.178 , respectively (Fig. 4). There was a significant difference between ACZ-myo SPECT and delayed DP-Tl SPECT images, and between early and delayed DP-Tl SPECT images ($p < 0.01$, $p < 0.01$), but the regional uptake ratio of ACZ-myo SPECT was equivalent to that of early DP-Tl SPECT images. In the normal area, the regional uptake ratios of ACZ-myo SPECT and early and delayed DP-Tl SPECT images were 0.756 ± 0.121 , 0.804 ± 0.079 and 0.792 ± 0.114 , respectively. There was no significant difference among them.

3) Clinical characteristics

The changes in blood pressure and heart rate after ACZ and dipyridamole injections are shown in Figure 5. The systolic blood pressure had fallen significantly at 11 min after ACZ administration compared with that at baseline

($p < 0.05$) and the heart rate had increased significantly at 7 min after dipyridamole injection ($p < 0.05$). No chest pain and no ST-T changes were observed on the electrocardiogram during ACZ infusion. Electrocardiographic ST-T changes appeared and/or chest pain was evident in 5 patients with DP-Tl SPECT (Table 1). These ischemic changes were relieved by an intravenous infusion of 60–125 mg aminophylline in 4 patients, and by an aminophylline infusion combined with sublingual nitroglycerin in one patient.

Patient 6 is presented in detail. This patient had 99% stenosis of the diagonal branch of the left anterior descending artery, total occlusion of the obtuse marginal branch, 75% stenosis of the left circumflex artery and 90% stenosis of the right ventricular branch of the right coronary artery. Left ventriculography showed normal wall motion. Thallium-201 myocardial SPECT with ACZ revealed defects in the anterior, anterolateral and inferior walls. Early DP-Tl SPECT images demonstrated incompletely reversible perfusion defects in the anterior and

anterolateral walls, and showed a fixed perfusion defect in the inferior wall (Fig. 6). Figure 7 shows the regional uptake ratios of the ACZ-myo SPECT and DP-Tl SPECT in Patient 6. The regional uptake ratio of the anterolateral wall in ACZ-myo SPECT was higher than that in the delayed image and lower than that in the early image in DP-Tl SPECT. ACZ-augmented Tc-99m HMPAO brain SPECT revealed normal cerebral vascular reserve.

Brain SPECT images

The mean count ratios of the middle cerebral artery

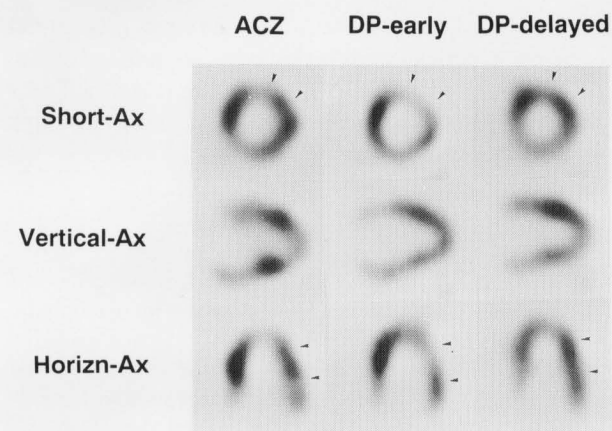


Fig. 6 Myocardial SPECT images of Patient 6 with three-vessel disease. Thallium-201 myocardial SPECT with acetazolamide, early and delayed dipyridamole-Tl-201 myocardial SPECT images were showed in the left, middle and right column, respectively. Thallium-201 SPECT with acetazolamide revealed defects in the anterior, anterolateral (arrowheads) and inferior walls. DP-Tl SPECT images demonstrated incompletely reversible perfusion defects in the anterior and anterolateral walls (arrowheads) and showed fixed perfusion defect in the inferior wall. (Horizn-Ax: horizontal axis, Short-Ax: short axis, Vertical-Ax: vertical long axis, other abbreviations as in Fig. 3.)

territories to the cerebellum are showed in Table 2. Seven of nine patients had stenosis ($\geq 75\%$) in the middle cerebral artery, but only one had decreased cerebral flow reserve.

DISCUSSION

This study suggests that ACZ induces myocardial ischemia in patients with severe coronary artery disease. The severity of the perfusion defects on ACZ-myo SPECT was not significantly different from that on early DP-Tl SPECT images but higher than that on the delayed images. These findings suggest that ACZ may induce myocardial ischemia as dipyridamole in patients with severe coronary artery disease. ACZ-augmented brain SPECT should be performed with caution in patients with severe coronary

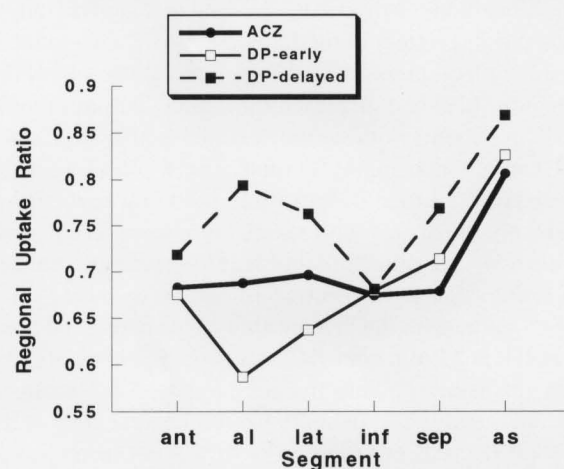


Fig. 7 Comparison of the myocardial uptake ratio among acetazolamide-augmented myocardial SPECT, early and delayed dipyridamole-Tl-201 myocardial SPECT images. (al: anterolateral, ant: anterior, as: anteroposterior, inf: inferior, lat: lateral, sep: septal, other abbreviations as in Fig. 3.)

Table 2 Clinical data on cerebrovascular disease and count ratio in brain SPECT with acetazolamide for study patients

Patient number	Neurological symptom	Stenosis in carotid echography	Mean count ratio			
			ACZ		Baseline	
			rt MCA	lt MCA	rt MCA	lt MCA
1	TIA	lt ICA 95%	0.903	0.692†	0.985	0.840
2	faintness	rt ICA 80%	0.963	0.942	no	no
3	none	rt CCA 75%	0.978	0.906	no	no
4	none	none	0.947	0.987	no	no
5	faintness	rt ICA 80%, lt ICA 75%	0.908	0.841	0.893	0.825
6	none	rt ICA 80%	0.911	0.913	no	no
7	old CI	rt ICA 100%	0.930	0.934	no	no
8	faintness	none	0.960	0.945	no	no
9	none	lt ICA 90%	0.956	0.901	no	no

ACZ: acetazolamide-augmented brain SPECT, CCA: common carotid artery, CI: cerebral infarction, ICA: internal carotid artery, lt: left, MCA: middle cerebral artery territory, Mean count ratio: the mean count ratio of middle cerebral artery territory to cerebellum, no: not done, rt: right, TIA: transient ischemic attack, †: reduced cerebral blood flow reserve.

artery disease combined with cerebral artery disease.

ACZ is a potent cerebral vasodilator that increases cerebral blood flow within 2 min after injection.¹ In an O-15 H₂O PET study, ACZ induced a maximal vasoreactive response of a 41% increase in cerebral blood flow 10 min after ACZ injection at sites of normal perfusion.¹¹ We administered Tc-99m HMPAO and Tl-201 for brain and myocardial SPECT studies when the effect of ACZ was maximal. The mechanism by which ACZ dilates cerebral arteries is not fully understood, but one possibility is that the inhibition of carbonic anhydrase increases intravascular carbon dioxide tension and alters blood flow.⁴ Adenosine triphosphatase activity in the rat heart is not affected by ACZ¹² and the level of carbonic anhydrase in the human heart is extremely low.¹³ Another vasodilation mechanism functions in the direct action of ACZ on the vascular smooth muscle that is unrelated to its ability to inhibit carbonic anhydrase.¹ ACZ altered cardiac output to a variable extent in the rat heart.¹² ACZ also reduced systolic blood pressure by 4%, peripheral vascular resistance by 14% and increased the cardiac output ratio by 10% in patients with various cardiovascular diseases.¹⁴ ACZ might increase myocardial oxygen consumption by increasing cardiac output, thus inducing myocardial ischemia in patients with severe coronary artery disease with low ischemic thresholds. Dipyridamole caused ischemic changes on electrocardiograms or chest pain in 5 of 9 patients in the present study. Systolic blood pressure fell at 11 min after ACZ infusion, but none of these patients manifested electrocardiographic ST-T changes, arrhythmia or chest pain. These results indicate that the myocardial ischemia induced by ACZ is not accompanied by symptoms or electrocardiographic signs of ischemia, but the mechanism of this effect is unknown.

Dipyridamole, an adenosine uptake inhibitor, is a powerful coronary vasodilator, and myocardial perfusion scintigraphy with this agent demonstrates myocardial ischemia.^{15,16} Dipyridamole causes coronary steal phenomenon by shifting coronary flow from a stenotic to a non-stenotic area.¹⁷ Dipyridamole also reportedly has a vasodilatory effect on the cerebral arteries like that of ACZ, which can induce cerebrovascular ischemia in patients with cerebral artery disease.¹⁸

Tc-99m HMPAO is used as a blood flow tracer in brain SPECT because it is lipophilic and crosses the blood-brain barrier. In the rat, Tc-99m HMPAO accumulated in muscle by diffusion, and the initial distribution of Tc-99m HMPAO in the myocardium was reported to be equivalent to that of Tl-201.^{19,20} The myocardial uptake of Tc-99m HMPAO was much lower than that of Tl-201 (0.15% vs. 3.65% of the injected dose per organ).^{21,22} On the other hand, Tl-201 might not affect Tc-99m HMPAO brain SPECT images, since it does not pass through the blood-brain barrier,²³ and crosstalk can be ignored because of the lower energy of Tl-201.

The sensitivity in detecting significant stenosis of middle

cerebral arteries is reported to 77–83% with ACZ-augmented brain SPECT.²⁴ In the present study, ACZ-augmented brain SPECT showed reduced cerebral blood flow reserve in only one of the eight middle cerebral artery territories with significant carotid arteries. In the case of internal or common carotid arterial stenosis, cerebrovascular flow after ACZ provocation could be maintained by collateral blood flow through the arterial circle of the cerebrum.

CONCLUSION

We concluded that because ACZ could cause myocardial ischemia in patients with severe coronary artery disease, ACZ-augmented brain SPECT should be performed with caution in patients with cerebrovascular and severe coronary artery disease.

REFERENCES

1. Hauge A, Nicolaysen G, Thoresen M. Acute effects of acetazolamide on cerebral blood flow in man. *Acta Physiol Scand* 117: 233–239, 1983.
2. Machac J. Cerebral versus myocardial stress perfusion imaging: role of pharmacological intervention in the diagnostic assessment of flow reserve. *J Nucl Med* 35: 41–43, 1994.
3. Yudd AP, Heertum RLV, Masdeu JC. Interventions and functional brain imaging. *Semin Nucl Med* 21: 153–158, 1991.
4. Bonte FJ, Devous MD, Reisch JS. The effect of acetazolamide on regional cerebral blood flow in normal human subjects as measured by single-photon emission computed tomography. *Invest Radiol* 23: 564–568, 1988.
5. Kannel WB, Wolf PA, Verter J. Manifestations of coronary disease predisposing to stroke—the Framingham study. *JAMA* 250: 2942–2946, 1983.
6. Mehigan JT, Buch WS, Pipkin RD, Fogarty TJ. A planned approach to coexistent cerebrovascular disease in coronary artery bypass candidates. *Arch Surg* 112: 1403–1409, 1977.
7. Craver JM, Murphy DA, Jones EL, Curling PE, Bone DK, Smith RB, et al. Concomitant carotid and coronary reconstruction. *Ann Surg* 195: 712–719, 1982.
8. Matsumura K, Nakashima H, Tanaka K, Kitano T, Murashima S, Takeda K, et al. Presurgical evaluation of cerebral perfusion reserve in patients for cardiovascular surgery using Tc-99m ECD SPECT with Diamox enhancement. *KAKU IGAKU (Jpn J Nucl Med)* 33: 223–231, 1996.
9. Shimotsu Y, Hayashida K, Hirose Y, Kume N, Nishimura T. Combined Tl-201 myocardial with Tc-99m HMPAO brain SPECT: myocardial ischemia induced by acetazolamide in severe coronary artery disease. *J Nucl Med* (in print) 1998.
10. Ricotta JJ, Bryan FA, Bond MG, Kurtz A, O'Leary DH, Raines JK, et al. Multicenter validation study of realtime (B-mode) ultrasound, arteriography, and pathologic examination. *J Vasc Surg* 6: 512–520, 1987.
11. Hayashida K, Hirose Y, Tanaka Y, Iwama T, Miyake Y, Ishida Y, et al. Vasoreactive effect of acetazolamide as a

- function of time with sequential PET O-15 water measurement. *Nucl Med Commun* 17: 1047-1051, 1996.
12. Rusxin A. Acetazolamide (Diamox) diuresis. *Arch Int Med* 95: 24-32, 1955.
 13. Shima K, Hibi N, Tashiro K. Carbonic anhydrase III (CA-III). *Shinkeinaika* 28: 464-473, 1988.
 14. Vanninen E, Kuikka JT, Tenhunen-Eskelinen M, Vanninen R, Mussalo H. Haemodynamic effects of acetazolamide in patients with cardiovascular disorders: correlation with calculated cerebral perfusion reserve. *Nucl Med Commun* 17: 325-330, 1996.
 15. Leppo JA. Dipyridamole-thallium imaging: the lazy man's stress test. *J Nucl Med* 30: 281-287, 1989.
 16. Stratmann HG, Kennedy HL. Evaluation of coronary artery disease in the patient unable to exercise: alternatives to exercise stress testing. *Am Heart J* 117: 1344-1365, 1989.
 17. Iskandrian AS. Pharmacologic stress testing and other alternative techniques in the diagnosis of coronary artery disease. In: Iskandrian AS, Verani MS, eds. *2nd ed.*. Philadelphia: F.A. Davis Company, pp. 219-241, 1996.
 18. Hwang TL, Saenz A, Farrell JJ, Brannon WL. Brain SPECT with dipyridamole stress to evaluate cerebral blood flow reserve in carotid artery disease. *J Nucl Med* 37: 1595-1599, 1996.
 19. Hara M, Hirota Y, Takagi Y, Shimomura O, Takahashi M, Tomiguti S. Evaluation of the distribution of Tc-99m HMPAO in the myocardium (abstract). *Jpn J Nucl Med* 25: 488, 1988.
 20. Costa DC, Ell PJ. The evolution of rCBF SPET studies. In: Costa DC, Ell PJ (ed.), *Brain Blood Flow in Neurology and Psychiatry, 1st. ed.*, Edinburgh: Churchill Livingstone, pp. 12-17, 1991.
 21. Volkert WA, Hoffman TJ, Seger RM, Troutner DE, Holmes RA. Tc-99m-propylene amine oxime (Tc-99m-PnPAO); a potential brain radiopharmaceutical. *Eur J Nucl Med* 9: 511-516, 1984.
 22. Bradley-Moore PR, Lebowitz E, Greene MW, Atkins HL, Ansari AN. Thallium-201 for medical use. II: biologic behavior. *J Nucl Med* 16: 156-160, 1974.
 23. Tonami N. Normal distribution of thallium-201. In Hisada K (ed.), *Saishin Syuyou-Kakuigaku, 1st ed.*, Tokyo: Kanehara & Co. Ltd, pp. 42-43, 1993.
 24. Pávics L, Grünwald F, Barzó P, Ambrus E, Menzel C, Schomburg A, et al. Evaluation of cerebral vasoreactivity by SPECT and transcranial Doppler sonography using the acetazolamide test. *Nuklearmedizin* 33: 239-243, 1994.