

## Scan findings of various myocardial SPECT agents in a case of amyloid polyneuropathy with suspected myocardial involvement

Ali Syed ARBAB, Kiyoshi KOIZUMI, Keiji TOYAMA, Takao ARAI, Tatsuya YOSHITOMI  
and Tsutomu ARAKI

*Department of Radiology, Yamanashi Medical University*

A 31-year-old male having familial amyloid polyneuropathy underwent a Tc-99m(V)-DMSA study to evaluate the myocardial involvement. The patient also underwent Tl-201, I-123-BMIPP and I-123-MIBG myocardial SPECT studies to evaluate blood perfusion, fatty acid metabolism and sympathetic function of the heart, respectively. Tc-99m(V)-DMSA SPECT showed uptake to the myocardium indicating myocardial involvement of amyloidosis. Both Tl-201 and I-123-BMIPP studies showed normal uptake indicating normal blood perfusion and fatty acid metabolism but I-123-MIBG SPECT showed no uptake to the heart, indicating severe impairment of sympathetic function.

**Key words:** amyloidosis, Tc-99m(V)-DMSA, Tl-201, I-123-BMIPP, I-123-MIBG

### INTRODUCTION

AMYLOIDOSIS is a group of diseases that are characterized by the extracellular deposition of the fibrous protein amyloid in one or more sites in the body. The disease may involve virtually any organ of the body. The specific diagnosis of amyloidosis depends on the demonstration of amyloid with appropriate staining in a biopsy specimen.<sup>1</sup> Recently Tc-99m(V)-dimercaptosuccinic acid [Tc-99m(V)-DMSA] has shown potentiality in the detection of amyloidosis in various organs.<sup>2,3</sup> Manni et al. have reported a case of cardiac amyloidosis detected by Tc-99m(V)-DMSA.<sup>4</sup> In this case report, scan findings of various cardiac SPECT agents are described in a patient with amyloid polyneuropathy with suspected involvement of the myocardium which was diagnosed by Tc-99m(V)-DMSA scan.

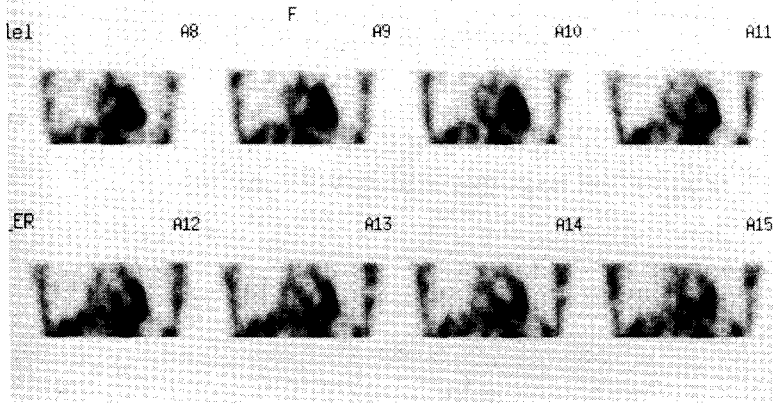
### CASE PRESENTATION

A 31-year-old man was admitted with numbness, disability in his lower extremities and alternating constipation and diarrhea. He had no past history of cerebrovascular or cardiac accident, drug abuse, or endocrine, metabolic or other systemic disorders. On examination there were impairment of sensory and motor functions in lower extremities, loss of tendon reflexes, hyperplasia at the sole of the foot including part of the lower extremities, and atrophy of the pretibial muscles. Laboratory tests showed no remarkable changes except an increased level of creatinine phosphokinase (CPK) and alpha<sub>2</sub> fraction of albumin. Biopsy from the rectum, peripheral nerves and skin showed amyloid protein deposits, confirming a case of amyloidosis. His mother died at the age of 34 due to sudden cardiac arrest following development of arrhythmia and gradual loss of eyesight which started at the age of 30. With this family history he was diagnosed finally as a case of familial amyloid polyneuropathy. On admission he had normal sinus rhythm with a rate of 88/min and a blood pressure of 124/82. Echocardiography showed marked hypertrophy of the myocardium. A radionuclide gated study showed borderline normal ejection fraction. ECG showed incomplete right bundle branch block with flat ST

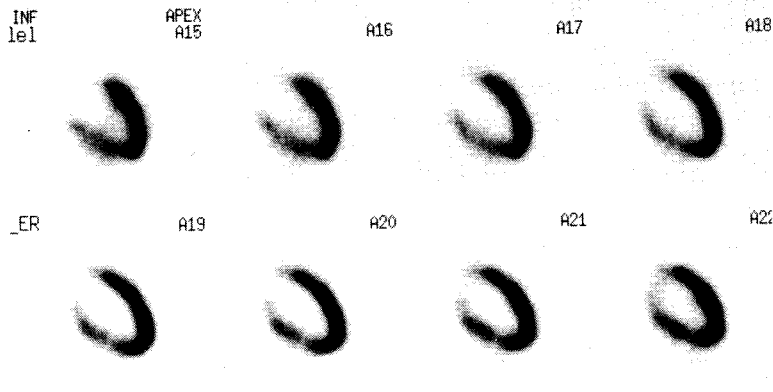
Received November 25, 1996, revision accepted January 20, 1997.

For reprint contact: Ali Syed Arbab, MBBS, Department of Radiology, Yamanashi Medical University, Tamaho-cho, Nakakoma-gun, Yamanashi 409-38, JAPAN.

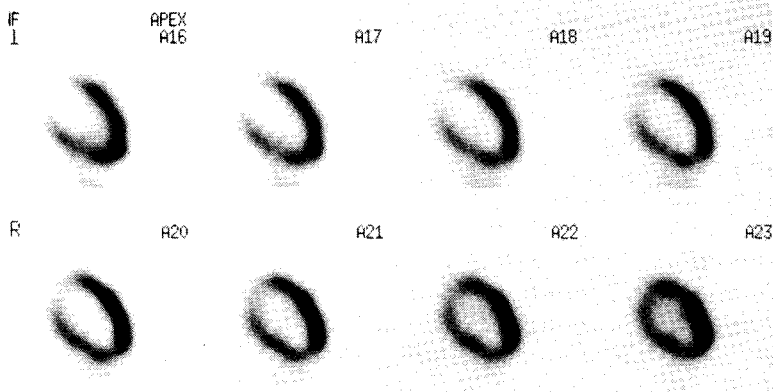
E-mail: saali@res.yamanashi-med.ac.jp.



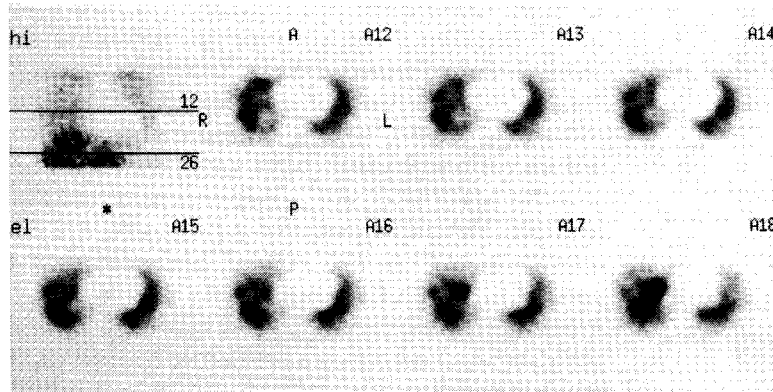
**Fig. 1** Abnormal uptake of Tc-99m(V)-DMSA to the myocardium in coronal section of thoracic SPECT (24 hours after injection). Twenty-four hours delayed SPECT was performed to avoid blood pool activity.



**Fig. 2** Normal perfusion in the myocardium on stress Tl-201 myocardial SPECT (vertical long axis).



**Fig. 3** Normal uptake in the myocardium on early (30 minutes after injection) I-123-BMIPP SPECT (vertical long axis).



**Fig. 4** No uptake to the myocardium indicating severe impairment of sympathetic function on delayed (4 hours after injection) I-123-MIBG SPECT (transaxial images).

segment. Since biopsy from the myocardium was not performed, the patient was referred to our department to rule out involvement of the myocardium by the disease for his cardiac problem. A Tc-99m(V)-DMSA scan was performed to rule out the involvement of myocardium by amyloidosis because the agent has the potential to detect amyloid deposits in various organs.<sup>2-4</sup> After injecting 1.295 GBq (35 mCi) of Tc-99m(V)-DMSA, 24 hours SPECT images were acquired to avoid the blood pool activity in the heart. The SPECT images showed abnormal uptake of the tracer to the myocardium (Fig. 1) indicating strong suspicion of myocardial amyloidosis. After assessing the cardiac status and scan findings, the clinicians concluded that there was myocardial involvement. The patient also underwent routine thallium-201 chloride (TI-201), I-123-p-iodophenyl-methyl-pentadecanoic acid (I-123-BMIPP) and I-123-metaiodobenzylguanidine (I-123-MIBG) SPECT studies for the evaluation of myocardial perfusion, fatty acid metabolism and sympathetic function of the heart, respectively. In our routine I-123-MIBG all drugs that act on the sympathetic function of the heart are discontinued 48 hours before unless contraindicated. Both the TI-201 and the I-123-BMIPP SPECT images showed almost normal uptake to the myocardium (Figs. 2 and 3), indicating intact perfusion and fatty acid metabolism. But no uptake of I-123-MIBG by the myocardium was observed (Fig. 4), indicating severely impaired sympathetic function of the heart.

#### DISCUSSION

The specific diagnosis of amyloidosis depends on the detection of amyloid protein on special staining in biopsy specimens. Although Tc-99m-pyrophosphate has been used in detecting amyloid involvement of the myocardium, reports showed low sensitivity for cardiac amyloidosis.<sup>5</sup> Recently Tc-99m(V)-DMSA has shown potentiality in the detection of amyloidosis in various organs.<sup>2,3</sup> Manni et al. have reported a case of cardiac amyloidosis detected by Tc-99m(V)-DMSA.<sup>4</sup> Due to its potentiality in detecting amyloidosis, Tc-99m(V)-DMSA was chosen instead of Tc-99m-pyrophosphate. In this case the involvement of the myocardium was suspected on the basis of a positive Tc-99m(V)-DMSA scan result. Twenty-four hours delayed SPECT was performed to avoid blood pool activity, and the scan showed good contrast image quality even after 24 hours of injection (Fig. 1). The exact mechanism of uptake of Tc-99m(V)-DMSA is yet to be determined but reports have shown that its uptake might be related to the volume of blood flow, phosphate metabolism or the pH of the lesions.<sup>6</sup>

TI-201 SPECT for the evaluation of myocardial viability and perfusion is well established. On the other hand I-123-BMIPP, a newly developed agent to evaluate myocardial fatty acid metabolism is routinely used to evaluate the fatty acid metabolism in damaged myocardium.<sup>7</sup> Both

these tracers showed almost normal uptake to the myocardium, indicating intact perfusion and fatty acid metabolism. Cardiac amyloidosis, that presents as congestive heart failure or cardiomegaly with a variety of arrhythmias, may not involve the perfusion and fatty acid metabolism of the myocardium in the early stage because there were no symptoms of congestive cardiac failure or arrhythmia in the patient. But I-123-MIBG, an agent for the evaluation of sympathetic innervation that has shown potentiality in detecting impaired sympathetic function in various myocardial disorders,<sup>8</sup> showed no uptake to the myocardium, indicating severe impairment of sympathetic function. Itoh et al. also reported 2 cases of familial amyloid polyneuropathy with no accumulation of I-123-MIBG in the myocardium.<sup>9</sup> Since amyloidosis involves both peripheral (including autonomic ganglia) and central nervous systems, in this patient amyloidosis associated with polyneuropathy might have involved myocardial sympathetic innervation too, and the scan findings of I-123-MIBG SPECT have confirmed this assumption.

In conclusion, in a patient with suspected amyloidosis, both Tc-99m-DMSA and I-123-MIBG scans should be performed to detect involvement of the heart by the amyloid process and to assess the sympathetic function.

#### REFERENCES

1. Cohen AS. Amyloidosis. In: Isselbacher KJ, Braunwald E, Wilson JD, Martin JB, Fauci AS, Kasper DL, eds. *Principles of Internal Medicine*, 13th edition, New York: McGraw-Hill, Inc., pp. 1625-1630, 1994.
2. Kobayashi H, Sakahara H, Itoh T, et al. Technetium-99m(V) dimercaptosuccinic acid uptake in intra-abdominal massive deposit of amyloid protein. *J Nucl Med* 34: 815-817, 1993.
3. Ohta H, Komibuchi T, Kawamata S, et al. Positive imaging of cardiomyopathy with Tc-99m(V)-DMSA. *Ann Nucl Med* 6: 269-271, 1992.
4. Manni C, Sangiorgi G, Boemi S, et al. Cardiac amyloidosis detected by Tc-99m(V)-DMSA myocardial uptake. *Clin Nucl Med* 19: 1109-1111, 1994.
5. Simons M, Isner JM. Assessment of relative sensitivities of noninvasive tests for cardiac amyloidosis in documented cardiac amyloidosis. *Am J Cardiol* 69: 425-427, 1992.
6. Kobayashi H, Sakahara H, Hosono M, et al. Soft-tissue tumor: diagnosis with Tc-99m(V)-dimercaptosuccinic acid scintigraphy. *Radiology* 190: 277-280, 1994.
7. Nishimura T, Uehara T, Shimonagata T, et al. Clinical experience of I-123-BMIPP myocardial imaging for myocardial infarction and hypertrophic cardiomyopathy. *Ann Nucl Med* 7: SII-35-SII-39, 1993.
8. Arbab AS, Koizumi K, Takano H, et al. Parameters of dynamic and static iodine-123-MIBG cardiac imaging. *J Nucl Med* 36: 962-968, 1995.
9. Itoh A, Sone S, Kusaga T, et al. I-123-MIBG myocardial SPECT in two patients with familial amyloid polyneuropathy. *KAKU IGAKU (Jpn J Nucl Med)* 32: 1113-1116, 1995.