

Evaluation of left ventricular wall motion and function in patients with previous myocardial infarction by three-dimensional ^{99m}Tc -HSAD multigated cardiac pool imaging

Junichi YAMAZAKI,* Katsutoshi NAITOU,* Shuichi ISHIDA,* Nariaki UNO,*
Kenichiro SAISHO,* Takehiko MUNAKATA,* Takeshi MORISHITA,*
Masaaki TAKANO** and Yoshimasa YABE***

**First Department of Internal Medicine, **Radioisotope Inspection Laboratory,
and ***Cardiovascular Diagnostic Laboratory, Ohmori Hospital,
Toho University School of Medicine*

To evaluate left ventricular (LV) wall motion stereoscopically from all directions and to calculate the LV volume by three-dimensional (3D) imaging, ^{99m}Tc -DTPA human serum albumin-multigated cardiac pool-single photon emission computed tomography (^{99m}Tc -MUGA-SPECT) was performed. A new data processing program was developed with the Application Visualization System-Medical Viewer (AVS-MV) based on images obtained from ^{99m}Tc -MUGA-SPECT. In patients with previous myocardial infarction, LV function and LV wall motion were evaluated by 3D- ^{99m}Tc -MUGA imaging. The LV end-diastolic volume (LVEDV) and end-systolic volume (LVESV) were obtained from 3D- ^{99m}Tc -MUGA images by the surface rendering method, and the left ventricular ejection fraction (LVEF) was calculated at thresholds of 35% (T1), 40% (T2), 45% (T3), and 50% (T4). There was a strong correlation between the LV volume calculated by 3D- ^{99m}Tc -MUGA imaging at a threshold of 40% and that determined by contrast left ventriculography (LVEDV: 194.7 ± 36.0 ml vs. 198.7 ± 39.1 ml, $r = 0.791$, $p < 0.001$; LVESV: 91.6 ± 44.5 ml vs. 93.3 ± 41.3 ml, $r = 0.953$, $p < 0.001$), respectively. When compared with the LVEF data obtained by left ventriculography, significant correlations were found for 3D images reconstructed at each threshold (T1: $r = 0.966$; T2: $r = 0.962$; T3: $r = 0.958$; and T4: $r = 0.955$). In addition, when LV wall motion obtained by 3D- ^{99m}Tc -MUGA imaging (LAT and LAO views) was compared with the results obtained by left ventriculography (RAO and LAO views), there was good agreement.

3D- ^{99m}Tc -MUGA imaging was superior in allowing evaluation of LV wall motion in all directions and in assessment of LV function, since data acquisition and image reconstruction could be done within a short time with the three-detector imaging system and AVS-MV. This method appears to be very useful for the observation of both LV wall motion and LV function in patients with ischemic heart disease, because it is a noninvasive examination.

Key words: ^{99m}Tc -DTPA human serum albumin, 3D-cardiac pool imaging, left ventricular wall motion, left ventricular volume, myocardial infarction

INTRODUCTION

IT IS IMPORTANT to assess left ventricular (LV) function and LV wall motion in patients with previous myocardial infarction for evaluation of ischemic zones, myocardial viability, and prognosis. ^{99m}Tc -DTPA-human serum albumin-multigated cardiac pool planar imaging (^{99m}Tc -MUGA planar) provides two-dimensional (2D) image of LV wall

Received February 17, 1997, revision accepted April 21, 1997.

For reprint contact: Junichi Yamazaki, M.D., First Department of Internal Medicine, Ohmori Hospital, Toho University, School of Medicine, 6-11-1 Ohmori-Nishi, Ohta-ku, Tokyo 143, JAPAN.

motion,¹⁻⁴ but these images are not so clear as those obtained by left ventriculography or echocardiography. Nevertheless, imaging has been improved by using single photon emission computed tomography (SPECT) to perform ^{99m}Tc-MUGA SPECT, which allows LV wall motion to be observed from any direction.⁵⁻⁷ A long time was required for data acquisition when using units with a single-detector, but this has been shortened to approximately 1/3 of the previous time for 360-degree acquisition by introducing of the three-detector imaging system.⁷ Conventional left ventriculography or echocardiography can only evaluate LV wall motion two-dimensionally. Three-dimensional (3D) echocardiography was developed recently,⁸⁻¹⁰ but it is not yet widely available. In this study, we performed ^{99m}Tc-MUGA SPECT with a three-detector imaging system in patients with previous myocardial infarction. A new processing program (Application Visualization System—Medical Viewer; AVS-MV)¹¹ was employed to reconstruct 3D-^{99m}Tc-MUGA images from ^{99m}Tc-MUGA SPECT data, and LV wall motion and LV function were compared with the findings obtained by left ventriculography in order to study the clinical applicability of the new method.

MATERIALS AND METHODS

Subjects

The subjects were twenty-one patients with previous myocardial infarction, including 13 with anteroseptal (A/S) infarction (13 men aged 63.0 ± 8.4 years), 5 with postero-inferior (P/I) infarction (5 men aged 64.4 ± 10.5 years), and 3 with A/S and P/I infarction (3 men aged 68.7 ± 7.8 years), as well as 4 healthy volunteers (4 men aged 31.5 ± 3.5 years). All the patients had a past history of prolonged chest pain, as well as sequential electrocardiographic changes and myocardial enzyme (CK, GOT, and LDH) changes consistent with myocardial infarction. The patients with A/S infarction had ST-segment changes in precordial leads V₁ through V₆, P/I infarction had ST-segment changes in leads II, III, and aV_F. Akinesia or dyskinesia in the infarct zones obtained by left ventriculography was shown in 8 of 21 patients. All subjects underwent ^{99m}Tc-MUGA SPECT and left ventriculography at an interval of 2 weeks or less. Patients with significant ventricular arrhythmias (multiple or multi-focal premature ventricular contractions), atrio-ventricular block, and atrial fibrillation were excluded from this study. No changes in the clinical condition or medical treatment occurred during the period between ^{99m}Tc-MUGA SPECT and left ventriculography.

Data acquisition by ^{99m}Tc-MUGA-SPECT

^{99m}Tc-MUGA-SPECT was performed with a dedicated three-detector imaging system equipped with low-energy, general purpose collimators (PRISM-3000; Picker Corp., Cleveland, Ohio / Shimadzu Corp., Kyoto). Before

Table 1 Comparison of LV volumes (LVEDV and LVESV) and LVEF obtained by 3D-^{99m}Tc-MUGA imaging and VC in healthy volunteers

threshold	LVEDV (ml)	LVESV (ml)	LVEF (%)
35%	167.8 ± 10.8	72.1 ± 6.8	57.1 ± 2.3
40%	147.1 ± 9.4	57.4 ± 6.3	60.9 ± 3.4
45%	131.4 ± 10.3	47.8 ± 5.7	63.6 ± 3.5
50%	122.4 ± 8.2	41.0 ± 5.9	66.5 ± 3.3
VC	(/)	(/)	61.2 ± 3.2

LV: left ventricular, LVEDV: left ventricular end-diastolic volume, LVESV: left ventricular end-systolic volume, LVEF: left ventricular ejection fraction, 3D: three-dimensional, MUGA: multigated, VC: left ventricular volume curve

Table 2 Comparison of LV volumes (LVEDV and LVESV) and LVEF obtained by 3D-^{99m}Tc-MUGA imaging and LVG

threshold	LVEDV (ml)	LVESV (ml)	LVEF (%)
35%	216.8 ± 38.3	107.6 ± 48.9	52.2 ± 14.0
40%	194.7 ± 36.0	91.6 ± 44.5	53.6 ± 14.6
45%	168.6 ± 34.2*	76.2 ± 39.3	56.4 ± 14.8
50%	144.7 ± 32.1**	63.9 ± 34.2*	57.7 ± 14.1
LVG	198.7 ± 39.1	93.3 ± 41.6	54.0 ± 15.0

LV: left ventricular, LVEDV: left ventricular end-diastolic volume, LVESV: left ventricular end-systolic volume, LVEF: left ventricular ejection fraction, 3D: three-dimensional, MUGA: multigated, LVG: left ventriculography, **: p < 0.01, *: p < 0.05 significant different from LVG

imaging, ^{99m}Tc-DTPA-human serum albumin (740 MBq, 20 mCi) was injected intravenously. After bed rest in the supine position for 5 minutes to allow heart rate stabilization the electrocardiogram was monitored for 2 minutes with an apparatus connected to the gamma camera system, from which the mean R-R interval ± 10% (msec) was calculated, and an electrocardiographic cyclic mode with 16 equal divisions was established. The gamma camera was peaked on the 140 KeV X-ray peak (15% window). After the ^{99m}Tc-MUGA planar studies, projection data were collected with the camera in the step & sheet mode using 6-degree steps, and 60 views were obtained by means of a short-distance noncircular rotation system over 360 degrees, with a total imaging time of approximately 15 minutes. Data for each frame were obtained with a zoom factor of 1.33 on a 64 × 64 acquisition matrix and 40–50 beats per view.

Image processing and reconstruction of 3D-^{99m}Tc-MUGA images

With ODYSSEY software (Titan 750; Ohio Imaging, Cleveland, Ohio), the image quality was improved by means of a low pass filter, and 360-degree reconstructed SPECT images were obtained with a ramp filter. Attenuation correction was not performed. Transverse images were reconstructed for all time phases. Short-axis,

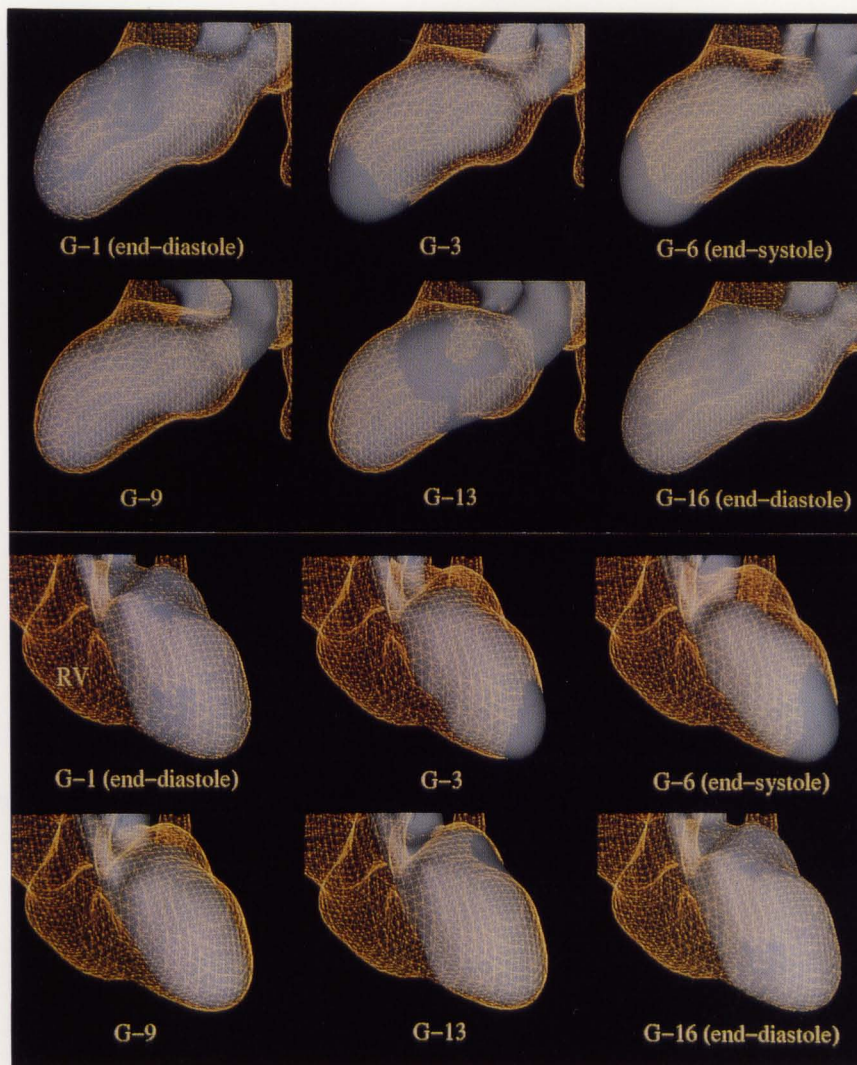


Fig. 1 Display of 3D- ^{99m}Tc -MUGA imaging (LAT and LAO views) in end-diastole and end-systole (LAT: lateral, LAO: left anterior oblique).

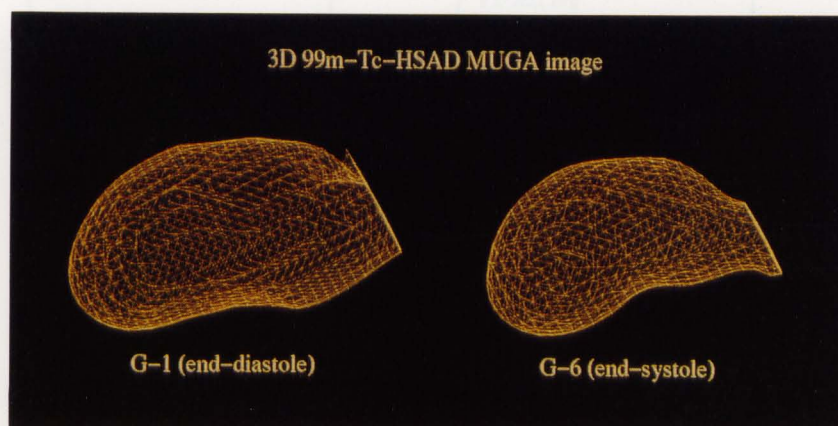


Fig. 2 Determining the position of aortic valve visually for calculation of LV volume in end-diastole and end-systole (LV: left ventricular).

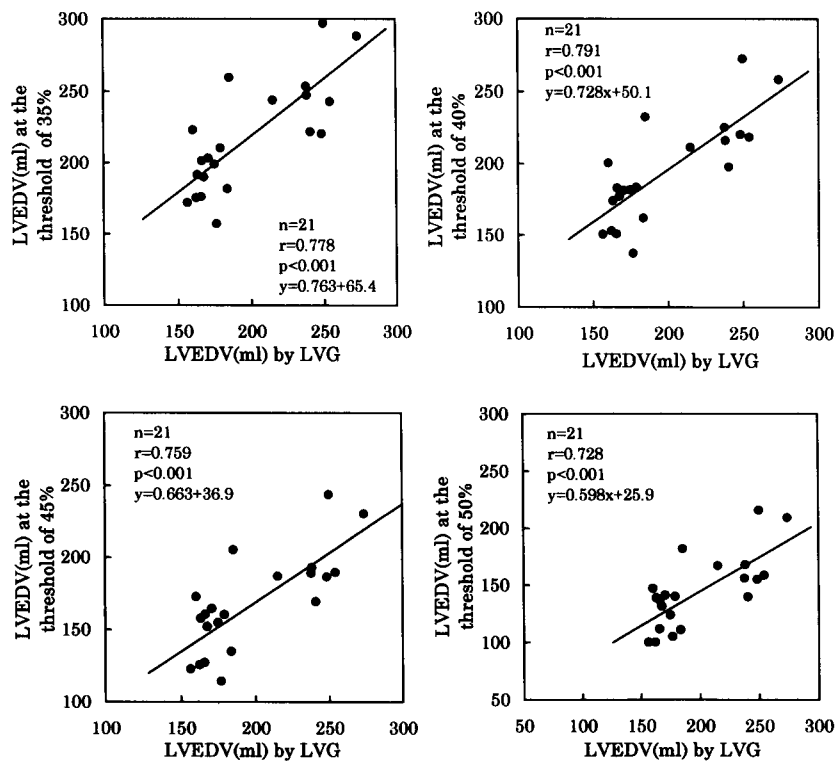


Fig. 3 Comparison of LVEDV obtained by 3D-^{99m}Tc-MUGA imaging and left ventriculography (LVEDV: left ventricular end-diastolic volume, 3D: three-dimensional, MUGA: multigated).

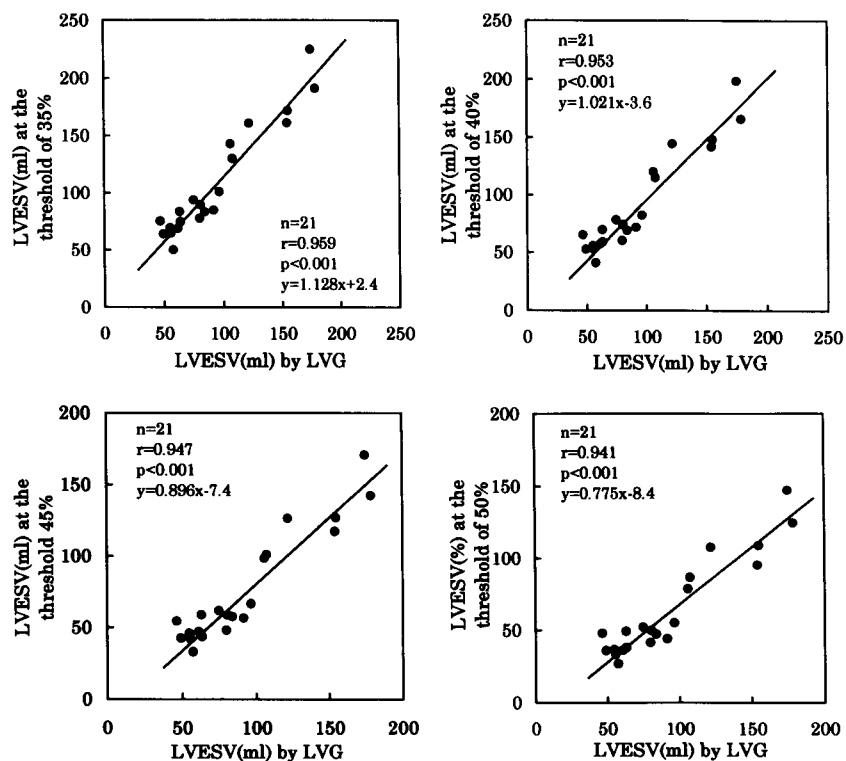


Fig. 4 Comparison of LVESV obtained by 3D-^{99m}Tc-MUGA imaging and left ventriculography (LVESV: left ventricular end-systolic volume, 3D: three-dimensional, MUGA: multigated).

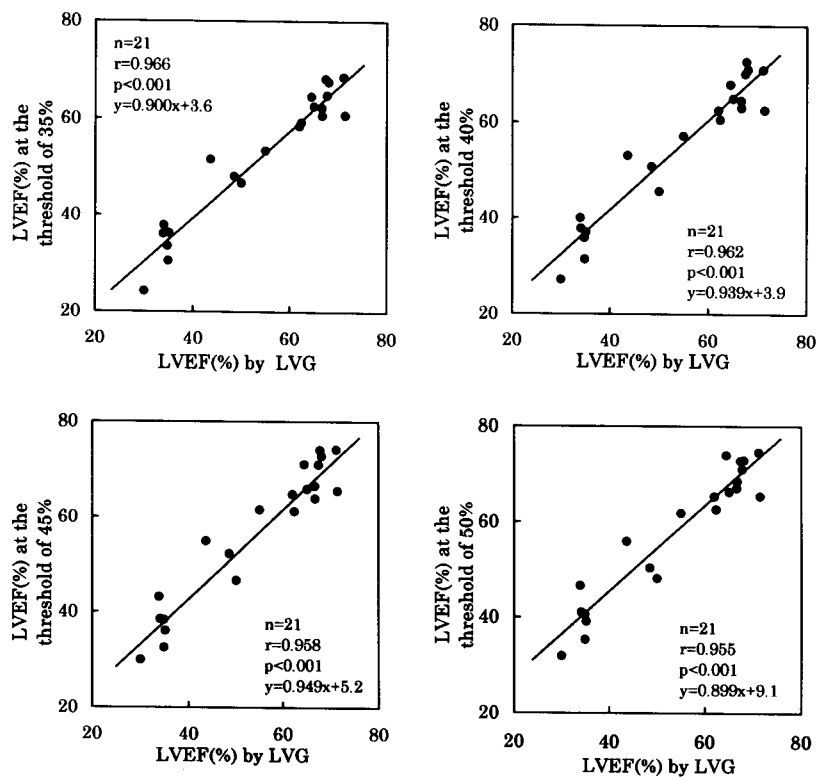


Fig. 5 Comparison of LVEF obtained by 3D-^{99m}Tc-MUGA imaging and left ventriculography (LVEF: left ventricular ejection fraction, 3D: three-dimensional, MUGA: multigated).

Table 3 Comparison of LV volumes (LVEDV and LVESV) and LVEF obtained by 3D-^{99m}Tc-MUGA imaging
LV volumes vs. LVEF in all patients (n = 21)

	r	Regression Equation	p value
LVEDV vs. LVEF	-0.647	$y = -0.263x + 105.9$	$p < 0.01$
LVESD vs. LVEF	-0.949	$y = -0.311x + 83.1$	$p < 0.001$

LV volumes vs LVEF in patients with akinesia or dyskinesia (n = 8)

	r	Regression Equation	p value
LVEDV vs. LVEF	-0.711	$y = -0.234x + 92.6$	$p < 0.05$
LVESV vs. LVEF	-0.930	$y = -0.258x + 75.1$	$p < 0.001$

LV: left ventricular, LVEDV: left ventricular end-diastolic volume, LVESV: left ventricular end-systolic volume, LVEF: left ventricular ejection fraction, 3D: three-dimensional, MUGA: multigated, r: correlation coefficient

Table 4 Comparison of LV wall motion obtained by 3D-^{99m}Tc-MUGA imaging and LVG

	G-0	G-1	G-2	G-3	G-4	G-5
G-0	50					
L	G-1	6	36	2		
V	G-2		2	14	3	
G	G-3			1	17	3
	G-4				7	4
	G-5					2

LV: Left ventricular, LVG: left ventriculography, 3D: three-dimensional, MUGA: multigated, G-0: normal, G-1: mild, G-2: moderate, G-3: severe, G-4: akinesia, G-5: dyskinesia

vertical long-axis and horizontal long-axis images were obtained from the transaxially reconstructed cardiac volume. After 3-point spatial smoothing in every time phase, masking of the aortic area and axial correction were performed, and a short-axis image in 16 time phases was used as the basis for each 3D-^{99m}Tc-MUGA image. The ^{99m}Tc-MUGA-SPECT (short-axis images) prepared with ODYSSEY were transferred to the AVS-MV (Titan 2; K.G.T. Corp., Tokyo) via the internet. The module was fixed so that two different data sets could be imposed at the same time on the AVS-MV image, and a network for 3D-^{99m}Tc-MUGA image reconstruction was prepared. To reconstruct 3D-^{99m}Tc-MUGA images from short-axis images obtained by ^{99m}Tc-MUGA-SPECT, the surface

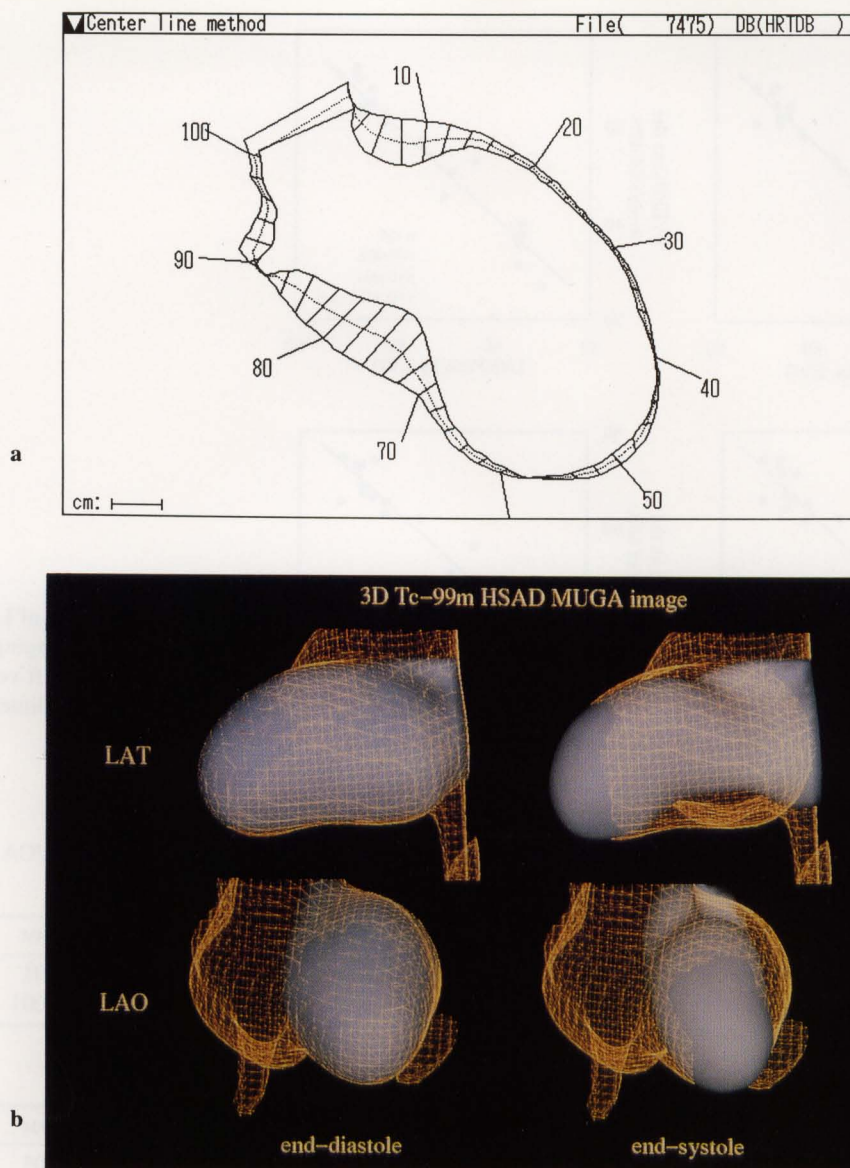


Fig. 6 a: Case; left ventriculography (RAO view) in a patient with A/S previous myocardial infarction (RAO: right anterior oblique, A/S: antero-septal). b: Case; 3D- ^{99m}Tc -MUGA imaging (LAT and LAO views) in a patient with A/S previous myocardial infarction (LAT: lateral, LAO: left anterior oblique).

rendering method was selected with a volume sufficient to set the optimum threshold. For comparison of the images obtained by left ventriculography and by 3D- ^{99m}Tc -MUGA imaging, thresholds were set at 35% (T1), 40% (T2), 45% (T3), and 50% (T4).

Assessment of LV volume and LV function

To calculate the LV volume, masking of the aortic component, right ventricle, pulmonary artery, and background was performed on the short-axis images. After masking of the short-axis image obtained by ^{99m}Tc -MUGA-SPECT, a 3D- ^{99m}Tc -MUGA image of the left ventricle was reconstructed. 3D- ^{99m}Tc -MUGA imaging was displayed on the viewer with the end-diastolic image fixed at each thresh-

old as a mesh, and one cardiac cycle of 16 time phases was shown from end-diastole to end-systole by imposition in white (Fig. 1). To calculate the left ventricular end-diastolic volume (LVEDV) and left ventricular end-systolic volume (LVESV), the position of the aortic valve was determined visually in end-diastole and end-systole on the 3D- ^{99m}Tc -MUGA image (Fig. 2). Setting the maximum radioisotope count in 1 voxel on the 3D- ^{99m}Tc -MUGA image thus obtained as 100%, the LV volumes were calculated at thresholds of 35%, 40%, 45%, and 50%. The LVEDV and LVESV calculated from the 3D- ^{99m}Tc -MUGA images obtained at each threshold were compared with the volumes obtained by left ventriculography. The ^{99m}Tc -MUGA images on a 64×64 matrix

obtained with ODYSSEY had an area of $3.5 \times 3.5 \text{ mm}^2/\text{pixel}$, which was multiplied by the slice thickness to calculate the voxel size (volume). Then the left ventricular ejection fraction (LVEF) was calculated from the LVEDV and LVESV obtained from the 3D- ^{99m}Tc -MUGA image, and was compared with the LVEF obtained by left ventriculography.

Determination of LV wall motion by 3D- ^{99m}Tc -MUGA imaging and left ventriculography

The lateral (LAT) view and the left anterior oblique (LAO) view obtained by 3D- ^{99m}Tc -MUGA imaging, as well as the right anterior oblique (RAO) view and LAO view obtained by left ventriculography, were evaluated by visual comparison. Based on the classification of the American Heart Association (AHA), the RAO view on left ventriculography and the LAT view on 3D- ^{99m}Tc -MUGA imaging were divided into 5 regions (basal anterior wall, anterior wall, apical apex, inferior wall, and posterior wall), while both the LAO views were divided into 2 regions (lateral wall and ventricular septum). In addition, LV wall motion was classified into 6 categories: normokinesia, mild hypokinesia, moderate hypokinesia, severe hypokinesia, akinesia, and dyskinesia.

Left ventriculography

Left ventriculography was performed after a bolus injection of contrast medium through a pigtail catheter and ventriculograms were recorded on cine film. RAO and LAO ventriculograms were obtained simultaneously. The endocardial contours at end-diastole and end-systole were traced. Then global indexes of LV volumes and LV function (LVEDV, LVESV, and LVEF) were calculated by the area-length method.¹² LV motion was measured along 100 chords drawn perpendicular to a centerline constructed midway between the end-diastolic and end-systolic contours.¹³

Statistical analysis

3D- ^{99m}Tc -MUGA imaging was compared with left ventriculography by simple linear regression. Results were expressed as the mean \pm S.D. and the unpaired t-test was used for analysis, with the level of significance being set at $p < 0.05$.

RESULTS

Assessment of LV volumes (LVEDV and LVESV) and LVEF obtained by 3D- ^{99m}Tc -MUGA imaging in healthy volunteers (Table 1)

The mean LVEDV values obtained by 3D- ^{99m}Tc -MUGA imaging at each threshold were $T1 = 167.8 \pm 10.8 \text{ ml}$, $T2 = 147.1 \pm 9.4 \text{ ml}$, $T3 = 131.4 \pm 10.3 \text{ ml}$ and $T4 = 122.4 \pm 8.2 \text{ ml}$. The mean LVESV values obtained by 3D- ^{99m}Tc -MUGA imaging at each threshold were $T1 = 72.1 \pm 6.8 \text{ ml}$, $T2 = 57.4 \pm 6.3 \text{ ml}$, $T3 = 47.8 \pm 5.7 \text{ ml}$ and $T4 = 41.0$

$\pm 5.9 \text{ ml}$. The mean LVEF value obtained by 3D- ^{99m}Tc -MUGA imaging at a threshold of 40% was close the value obtained with the LV volume curve of ^{99m}Tc -MUGA planar imaging ($60.9 \pm 3.4\%$ vs. $61.2 \pm 3.2\%$, $p = \text{NS}$).

Comparison of LV volumes (LVEDV and LVESV) obtained by 3D- ^{99m}Tc -MUGA imaging and left ventriculography (Table 2, Figs. 3, 4)

The mean LVEDV values calculated by 3D- ^{99m}Tc -MUGA imaging at the thresholds of 45% (T3) and 50% (T4) were different from the value of $198.7 \pm 39.1 \text{ ml}$ obtained by left ventriculography ($T1 = 216.8 \pm 38.3 \text{ ml}$; $T2 = 194.7 \pm 36.0 \text{ ml}$; $T3 = 168.6 \pm 34.2 \text{ ml}$, $p < 0.01$; and $T4 = 144.7 \pm 32.1 \text{ ml}$, $p < 0.01$). There was a close correlation between the LVEDV value obtained by 3D- ^{99m}Tc -MUGA imaging at a threshold of 40% (T2) and that obtained by left ventriculography (LVG) ($r = 0.791$, $p < 0.001$, $y = 0.728x + 50.1$). There were also good correlations between both for LVEDV values at the 3 other thresholds ($T1$: $r = 0.778$, $p < 0.001$; $T3$: $r = 0.759$, $p < 0.001$; and $T4$: $r = 0.728$, $p < 0.001$). The mean LVESV values obtained by 3D- ^{99m}Tc -MUGA imaging at a threshold of 50% were significantly different from the value of $93.3 \pm 41.6 \text{ ml}$ obtained by left ventriculography ($T1 = 107.6 \pm 48.9 \text{ ml}$, $T2 = 91.6 \pm 44.5 \text{ ml}$, $T3 = 76.2 \pm 39.3 \text{ ml}$ and $T4 = 63.9 \pm 34.2 \text{ ml}$, $p < 0.05$). Comparison of the LVESV values obtained by 3D- ^{99m}Tc -MUGA imaging at each threshold and by left ventriculography showed complete agreement ($T1$: $r = 0.959$, $p < 0.001$; $T2$: $r = 0.953$, $p < 0.001$; $T3$: $r = 0.947$, $p < 0.001$; and $T4$: $r = 0.941$, $p < 0.001$). The mean LVESV obtained by 3D- ^{99m}Tc -MUGA imaging at a threshold of 40% was significantly higher in 8 patients with akinesia or dyskinesia than in 13 patients without these changes ($123.8 \pm 48.5 \text{ ml}$ vs. $71.8 \pm 28.6 \text{ ml}$, $p < 0.05$). The mean LVEDV values obtained by 3D- ^{99m}Tc -MUGA imaging at a threshold of 40% and by left ventriculography were $209.3 \pm 44.0 \text{ ml}$ and $185.7 \pm 28.2 \text{ ml}$, respectively ($p = \text{NS}$).

Comparison of LVEF obtained by 3D- ^{99m}Tc -MUGA imaging and left ventriculography (Table 2, Fig. 5)

The mean LVEF values calculated at each threshold did not differ significantly from the value of $54.0 \pm 15.0\%$ obtained by left ventriculography ($T1 = 52.2 \pm 14.0\%$, $T2 = 53.6 \pm 14.6\%$, $T3 = 56.4 \pm 14.8\%$ and $T4 = 57.7 \pm 14.1\%$). Comparison of the LVEF values obtained by 3D- ^{99m}Tc -MUGA imaging at each threshold and by left ventriculography showed good agreement between the two methods ($T1$: $r = 0.966$, $p < 0.001$; $T2$: $r = 0.962$, $p < 0.001$; $T3$: $r = 0.958$, $p < 0.001$ and $T4$: $r = 0.955$, $p < 0.001$). The mean LVEF obtained by 3D- ^{99m}Tc -MUGA imaging at a threshold of 40% was significantly lower in 8 patients with akinesia or dyskinesia than in 13 patients without these changes ($42.5 \pm 12.7\%$ vs. $62.0 \pm 10.3\%$, $p < 0.01$).

Comparison of LV volumes (LVEDV and LVESV) and LVEF obtained by 3D-^{99m}Tc-MUGA imaging (Table 3)

There was a good correlation between the LVEDV and LVEF values obtained by 3D-^{99m}Tc-MUGA imaging at a threshold of 40% ($r = -0.647$, $p < 0.01$) in all patients. Comparison of the LVESV and LVEF values also showed an excellent agreement ($r = -0.949$, $p < 0.001$). There was a good correlation between the LVEDV and LVEF values obtained by 3D-^{99m}Tc-MUGA imaging at a threshold of 40% ($r = -0.711$, $p < 0.05$) in patients with akinesia or dyskinesia. Comparison of the LVESV and LVEF values also showed an excellent agreement ($r = -0.930$, $p < 0.001$).

Evaluation of LV wall motion (Table 4)

When the LAT and LAO views obtained by 3D-^{99m}Tc-MUGA imaging at a threshold of 40% were compared with the RAO and LAO views obtained by left ventriculography, abnormalities in LV wall motion coincided in 85.7%. There was also good agreement between both methods in assessments of LV wall motion at the 3 other thresholds. 3D-^{99m}Tc-MUGA imaging detected all of 8 patients with akinesia or dyskinesia on left ventriculography.

Case presentation

The case is a 76-year-old patient with previous A/S myocardial infarction. Coronary arteriography showed 81% stenosis at the left anterior descending artery (LAD: #6). Left ventriculography (RAO view) showed dyskinesia of the apical apex and akinesia at the anterior wall (Fig. 6a). The 3D-^{99m}Tc-MUGA imaging (LAT view) also showed dyskinesia of the apical apex and akinesia of the anterior wall. In the LAO view, 3D-^{99m}Tc-MUGA imaging showed severe hypokinesia of the septum, as did left ventriculography (LAO view), and the LVEF determined by 3D-^{99m}Tc-MUGA imaging at a threshold of 40% was 39.5% (Fig. 6b).

DISCUSSION

^{99m}Tc-MUGA planar imaging is one of the methods for assessing LV wall motion. Since it employs planar images, it is easy to collect data and to assess cardiac function with the ejection fractions obtained from the left and right ventricular volume curves.^{1-4,14} The first-pass technique or the equilibrium technique can be used for data acquisition. Generally, LV wall motion is observed in the right anterior oblique (RAO) view for the former method and the left anterior oblique (LAO) view for the latter. With ^{99m}Tc-MUGA-SPECT by means of a single-detector imaging system, it is feasible to evaluate LV wall motion with optional tomograms.⁵⁻⁷ To assess myocardial viability, left ventriculography and echocardiography have mainly been used, but ^{99m}Tc-MUGA-SPECT may obtain equal or better results.^{5,15,16} McGhie et al.⁷ evaluated LV

wall motion by left ventriculography, echocardiography, and multigated tomographic radionuclide ventriculography, and reported that a good correlation was noted between these methods. With either invasive or non-invasive methods, detailed evaluation of LV wall motion is feasible, but multigated SPECT has the characteristic of allowing wall motion to be observed in any desired tomogram. When a rotating gamma-camera is used to collect data over 180 degrees or 360 degrees, the ordinary single-detector imaging system requires a long time for data acquisition but the three-detector imaging system developed recently has reduced the acquisition time to 1/3 of the previous time.⁷ 3D-^{99m}Tc-MUGA imaging makes it feasible to observe LV wall motion three-dimensionally from any direction, which might be thought to make wall motion evaluation easier. Despite this, it has not been applied clinically to date, because too much time was required for data processing and 3D-^{99m}Tc-MUGA image reconstruction. We developed a new 3D-^{99m}Tc-MUGA display program with the Application Visualization System-Medical Viewer (AVS-MV: K.G.T. Corp., Tokyo).

Evaluation of LV volume by 3D-^{99m}Tc-MUGA imaging

To calculate the LV volume, before 3D-^{99m}Tc-MUGA images of the left ventricle was reconstructed, the short-axis images were masked to eliminate the right ventricle, the aortic component, the pulmonary artery and the background. In this way, the LV chambers were well separated, whether or not the patients had dyskinesia or akinesia of the septum. Reconstruction of 3D-^{99m}Tc-MUGA images was done with short-axis images which made it easy to determine the outer border of the LV chamber.

The 3D-^{99m}Tc-MUGA LVEDV and LVESV data obtained at a threshold of 40% were compared with the results obtained by left ventriculography, and excellent agreement was noted. When the threshold was set at 40%, the LV volumes obtained by 3D-^{99m}Tc-MUGA images were in accord with the findings of left ventriculography. This result suggests that an adequate threshold for reconstruction of 3D-^{99m}Tc-MUGA images is 40% in the clinical setting but this might differ from patient to patient, so it is important to set an appropriate threshold. To determine the threshold, the 3D-^{99m}Tc-MUGA image needs to be compared with a 3D multigated MRI image. The mean LVEF values calculated at thresholds of 35%, 40%, 45% and 50% were close to each other, since the LVEF is a relative value calculated from LVEDV and LVESV.

Another finding in this study is that 3D-^{99m}Tc-MUGA imaging is a suitable method for evaluating remodeling of the entire LV including infarct expansion of akinetic or dyskinetic segment after myocardial infarction.¹⁷ The LVESV and LVEF were significant factors in LV dysfunction, because an excellent relationship between the LVESV and LVEF values obtained by 3D-^{99m}Tc-MUGA imaging at a threshold of 40% was seen in patients with

akinesia or dyskinesia.

Evaluation of LV wall motion by 3D-^{99m}Tc-MUGA imaging

The AVS-MV has software that visualizes data easily and simply.¹¹ When ^{99m}Tc-MUGA-SPECT is performed, the data are first obtained, thresholds are fixed at 30%, 40%, 45%, and 50%, and 3D-^{99m}Tc-MUGA images are reconstructed. This requires approximately 10 minutes. By rotating a 3D-^{99m}Tc-MUGA image, LV wall motion can be observed motion from any direction. The LAT view appears to be particularly useful for evaluating the anterior wall, apex and postero-inferior wall. Cine 3D-^{99m}Tc-MUGA imaging is superior in allowing LV wall motion to be observed from any direction in a short time by using the three-detector imaging system and high speed processing unit. Our comparison of 3D-^{99m}Tc-MUGA imaging with left ventriculography showed that the two methods achieved similar results. When the LV wall motion of the same patient was studied with 3D-^{99m}Tc-MUGA images obtained at a threshold of 40%, there was good agreement with left ventriculography at 85.7%.

When LV wall motion was observed by 3D-^{99m}Tc-MUGA imaging at other thresholds of 35%, 45% and 50% also, there was good agreements with left ventriculography. 3D-^{99m}Tc-MUGA imaging is a suitable method for observing the full extent of dyskinetic or akinetic regions. By displaying the LV end-diastolic image as a mesh, evaluation of LV wall motion becomes easier. This three-dimensional display may allow a higher diagnostic accuracy for LV wall motion abnormalities than compared with echocardiography or left ventriculography.

Limitations of this study

The limitations of this study are the lack of prospective data after determination of the most suitable threshold of 40%, and the lack of comparison of the LV volume values obtained by 3D-^{99m}Tc-MUGA imaging and by the Simpson method of left ventriculography in some patients in whom there was a discrepancy between LVEDV values calculated by 3D-^{99m}Tc-MUGA imaging and by LVG. It is possible that a different threshold level was established in each patient.

Clinical usefulness of 3D-^{99m}Tc-MUGA imaging

It takes approximately 15 minutes of data acquisition to perform ^{99m}Tc-MUGA-SPECT, so it seems rather difficult to apply motion and drug loading during 3D-^{99m}Tc-MUGA imaging, since a stable heart rate should be maintained during data acquisition. Although echocardiography has limitations in an obese constitution, lung diseases such as emphysema, geometric assumptions regarding the shape of the ventricle and the position and orientation of the imaging planes, while nuclear medicine data can be collected from all patients except those with arrhythmia. When left ventriculography is compared with 3D-^{99m}Tc-MUGA imaging, the former is invasive and the

contrast medium bolus might make left heart function even lower than it usually is. From this point of view, 3D-^{99m}Tc-MUGA imaging is superior for evaluation of cardiac function and LV wall motion at rest. In the circulatory field, 3D displays have recently been introduced for various types of diagnostic imaging. In the case of nuclear medicine also, the three-detector imaging system and supercomputer are widely available, so 3D-^{99m}Tc-MUGA imaging should be employed more frequently in the future.^{18,19}

REFERENCES

1. Burow RD, Strauss HW, Singleton R, Pond M, Rehn T, Bailey IK. Analysis of the ventricular function from multiple gated acquisition cardiac blood pool imaging: Comparison to contrast angiography. *Circulation* 56: 1024–1028, 1977.
2. Rieber JHC, Lie WH, Kooij PPM. Clinical validation of fully automated computation of ejection fraction from gated equilibrium blood-pool scintigrams. *J Nucl Med* 24: 1099–1107, 1983.
3. Ekman M, Lomsky M, Stromblad SO, Carlsson S. Closed-line integral optimization edge detection algorithm and its application in equilibrium radionuclide angiocardiology. *J Nucl Med* 36: 1014–1018, 1995.
4. Vera P, Gardin I, Bok B. Comparative study of three automatic programs of left ventricular ejection fraction evaluation. *Nucl Med Commun* 16: 667–674, 1995.
5. Corbett JR, Janson DE, Lewis SE, Gabliani GI, Nicod P, Filipchuck NG, et al. Tomographic gated blood pool radionuclide ventriculography: analysis of wall motion and left ventricular volumes in patients with coronary artery disease. *J Am Coll Cardiol* 6: 349–358, 1985.
6. Gill JB, Moore RH, Tamaki N, Miller D, Barkai-Kovach M, Yasuda T, et al. Multi-gated blood-pool tomography: new method for the assessment of left ventricular function. *J Nucl Med* 12: 1916–1924, 1986.
7. McGhie AI, Faber TL, Willerson JT, Corbett JR. Evaluation of left ventricular aneurysm after acute myocardial infarction using tomographic radionuclide ventriculography. *Am J Cardiol* 75: 720–724, 1995.
8. Handschumacher MD, Lethor JP, Siu SC, Mele D, Rivera JM, Picard MH, et al. A new integrated system for three-dimensional echocardiographic reconstruction: development and validation for ventricular volume with application in human subjects. *J Am Coll Cardiol* 21: 743–753, 1993.
9. Sapin PM, Schroeder KM, Smith MD, De Maria AN, King DL. Three-dimensional echocardiographic measurement of left ventricular volume *in vitro*: comparison to two-dimensional echocardiography and cineventriculography. *J Am Coll Cardiol* 22: 1530–1537, 1993.
10. Gopal AS, Shen Z, Sapin PM, Keller AM, Schnellbaeher MJ, Leibowitz DW, et al. Assessment of cardiac function by three-dimensional echocardiography compared with conventional noninvasive methods. *Circulation* 92: 842–853, 1995.
11. Siegel CS. Creating 3D models from medical images using AVS. 1995 international advanced visual systems users group conference proceedings, Boston, Massachusetts April

- 19–21; pp. 424–431, 1995.
12. Sandler H, Dodge HT. The use of single plane angiograms for the calculation of left ventricular volume in man. *Am Heart J* 75: 325–334, 1968.
13. Sheehan FH, Bolson EL, Dodge HT, Mathey DG, Schofer J, Woo HW. Advantages and application of the centerline method for characterization regional ventricular function. *Circulation* 74: 293–305, 1986.
14. Dymond DS, Elliott A, Stone D, Hendrix G, Spurrell R. Factors that affect the reproducibility of measurements of left ventricular function from first-pass radionuclide ventriculograms. *Circulation* 65: 311–322, 1982.
15. Hecht HS, Josephson MA, Hopkins JM, Singh BN, Parzen E, Elashoff J. Reproducibility of equilibrium radionuclide ventriculography in patients with coronary artery disease: Response of left ventricular ejection fraction and regional wall motion to supine bicycle exercise. *Am Heart J* 104: 567–574, 1982.
16. Kelbaek H, Gjørup T, Bulow K, Nielsen SL. Observer variability of radionuclide left ventricular volume determination at rest and during exercise. *Acta Radiol* 34: 179–182, 1993.
17. White HD, Norris RM, Brown MA, Brandt PW, Whitlock RML, Wild CJ. Left ventricular end-systolic volume as the major determinant of survival after recovery from myocardial infarction. *Circulation* 76: 44–51, 1987.
18. Faber TL, Stokely EM, Templeton GH, Akers MS, Parkey RW, Corbett JR. Quantification of three-dimensional left ventricular segment wall motion and volumes from gated tomographic radionuclide ventriculograms. *J Nucl Med* 30: 638–649, 1989.
19. Faber TL, Akers MS, Peshock RM, Corbett JR. Three dimensional motion and perfusion quantification in gated single-photon emission computed tomograms. *J Nucl Med* 32: 2311–2317, 1991.