

Assessment of Technetium-99m Technegas scintigraphy for ventilatory impairment in pulmonary emphysema: Comparison of planar and SPECT images

Katashi SATOH,* Masatada TANABE,* Kazue TAKAHASHI,* Takuya KOBAYASHI,*
Yoshihiro NISHIYAMA,* Yuka YAMAMOTO,* Naomi HONJO,* Mayumi SASAKI,*
Motoomi OHKAWA,* Jiro FUJITA** and Hiroki OKADA**

**Department of Radiology, and **First Department of Internal Medicine,
Kagawa Medical University, School of Medicine*

Pulmonary emphysema can be diagnosed easily by X-ray CT (CT) as a low attenuation area. Recently Tc-99m-Technegas (Technegas) has been used for ventilation scintigraphy. The present study was undertaken to assess the usefulness of planar and SPECT images by using Technegas scintigraphy in patients with pulmonary emphysema. Technegas scintigraphy, CT and pulmonary function tests were performed in 20 patients (males, age 32–78 years). We classified the findings of Technegas images into 4 grades. Comparing planar and SPECT images of Technegas, more detailed findings were shown by SPECT than by planar images in mild cases (6 cases, 30%). In more severe cases, findings of SPECT and planar images were equivalent (14 cases, 70%). The degree of abnormal findings obtained by SPECT was equivalent to that obtained by CT in severe cases (6 cases, 30%). SPECT should be excluded in advanced stages as indicated by planar images.

Key words: technegas, pulmonary emphysema, ventilation study, planar images, SPECT images

INTRODUCTION

RECENTLY, ultrafine Technetium-99m labeled carbon particles (Technegas) are being used for ventilation scintigraphy.^{1–6} Ventilation scintigraphy can be performed with inert gases such as Xe-133 and Kr-81m, but there are some limitations. Tc-99m phytate aerosol and Technegas can be generated in any institution. However, Peltier et al. reported that Tc-99m phytate aerosol images were not superior to Technegas images and had a limitation where there is a possible existence of intense high bronchial foci or hot spot formation in cases of severe chronic obstructive pulmonary disease.⁵ On the other hand, morphologically CT can depict pulmonary emphysema as small low attenuation areas.^{7,8} The purpose of this study was to

assess the usefulness of Technegas scintigraphy by both planar and SPECT images in patients with pulmonary emphysema.

MATERIALS AND METHODS

Patients

Twenty patients (all males with age range of 32–78 years and a mean age of 67 years: 18 heavy smokers, 1 non-smoker, and 1 ex-smoker) underwent X-ray CT (CT) and Technegas scintigraphy. All patients were diagnosed as having pulmonary emphysema by clinical symptoms, pulmonary function test and CT. The patients were arranged from 1–20 by % forced expiratory volume in one second (%FEV 1.0) from mild to severe (Table 1). Pulmonary function test were performed by Chestac-35K and Chestac-55V (Chest MI, Tokyo, Japan).

Technegas

Technegas is generated in a proprietary generator (Technegas Generator, Tetley Manufacturing Ltd., Sydney, Australia) by the resistive heating of a graphite crucible up to

Received January 8, 1997, revision accepted February 19, 1997.

For reprint contact: Katashi Satoh, M.D., Department of Radiology, Kagawa Medical University, 1750–1 Ikenobe, Miki-cho, Kita-gun, Kagawa 761–07, JAPAN.

E-mail: satoh@kms.ac.jp

Table 1 List of cases and data of pulmonary function test

Case No.	Age Sex	Cigarette Index	Pulmonary function test			
			%FEV 1.0	%VC	RV/TLC	FEV 1.0%
1	62M	1140	101.20	95.80	35.40	76.40
2	61M	800	100.80	97.00	27.44	74.05
3	49M	1100	94.00	97.10	39.90	74.10
4	78M	1000	93.60	98.05	39.25	64.35
5	70M	600	92.59	100.91	30.65	77.64
6	71M	750	75.11	77.23	31.07	79.71
7	69M	1800	70.85	86.48	51.20	73.04
8	72M	–	60.70	54.30	47.60	75.50
9	78M	900	58.72	63.75	50.91	64.13
10	63M	700	54.69	92.58	30.85	56.97
11	72M	3000	51.04	80.07	46.97	51.60
12	76M	800	50.00	91.22	53.64	48.38
13	75M	1500	47.30	68.80	/	48.10
14	69M	1000	43.72	52.81	65.48	70.61
15	73M	1060	35.65	56.04	/	42.95
16	56M	1050	34.80	70.40	61.10	51.30
17	67M	1200	34.63	76.04	40.44	51.94
18	72M	900	31.48	57.46	58.98	54.21
19	74M	*	30.87	81.42	47.00	45.27
20	69M	900	27.83	67.39	73.08	47.56

* Ex-smoker (Stopped smoking 15 years ago), – Non-smoker,
/ not examined

Table 2 Stage in Technegas and CT staging of patients

	Case	Technegas stage		
		planar	SPECT	
A)	9	III	III	
	3	IV	IV	
	4	IV	IV	
	8	IV	IV	
	SPECT and planar equivalent	11	IV	IV
	12	IV	IV	
	13	IV	IV	
	14	IV	IV	
	15	IV	IV	
	16	IV	IV	
B)	17	IV	IV	
	18	IV	IV	
	19	IV	IV	
	20	IV	IV	
	SPECT better than planar	2	I	II
	6	I	II	
7	I	II		
1	II	IV		
5	II	IV		
10	II	IV		

2,500°C in which a saline solution of 505 MBq of Tc-99m pertechnetate has been placed and dried. After generation of the aerosol in an atmosphere of 100% argon, it is dispersed in a lead-lined chamber. Following inhalation

of 100% oxygen at 5 l/min for 3 minutes, all patients were given Technegas by inhalation through a mouthpiece while wearing a nose clip and lying in the supine position, in several tidal volume breaths without breath holding. Following the administration of Technegas, planar imaging was performed in 6 projections: anterior, posterior, right lateral, left lateral, right posterior oblique and left posterior oblique.

The SPECT system used was Picker model Prism 2000 (Northford, Connecticut, USA) with a low-energy, high-resolution collimator. SPECT was rotated through 360°. Seventy-two images were collected at 5° intervals for 40 seconds each with 128 × 128 matrix size. A low pass filter and a Ramp filter were used. No correction was made for attenuation. SPECT imaging was also performed in 3 projections with 4.95 mm thickness: axial, coronal, and sagittal. The axial images were compared with CT.

The lower cut level of display was 0% in planar images and 0–5% in SPECT images.

We classified the findings of Technegas imaging into 4 stages according to the extent of peripheral irregularity and central hot spot formation: Stage I) normal homogeneous distribution; Stage II) peripheral heterogeneity; Stage III) additional hot spot formation; and Stage IV) further regional defect.¹⁰

CT

CT was performed after Technegas scintigraphy making 12 slices from above the aortic arch to the diaphragm with

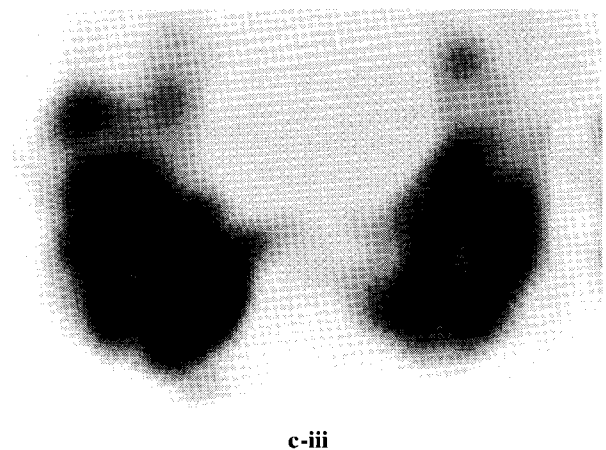

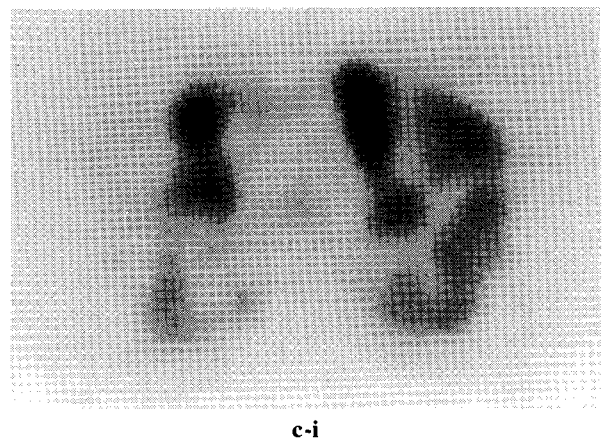
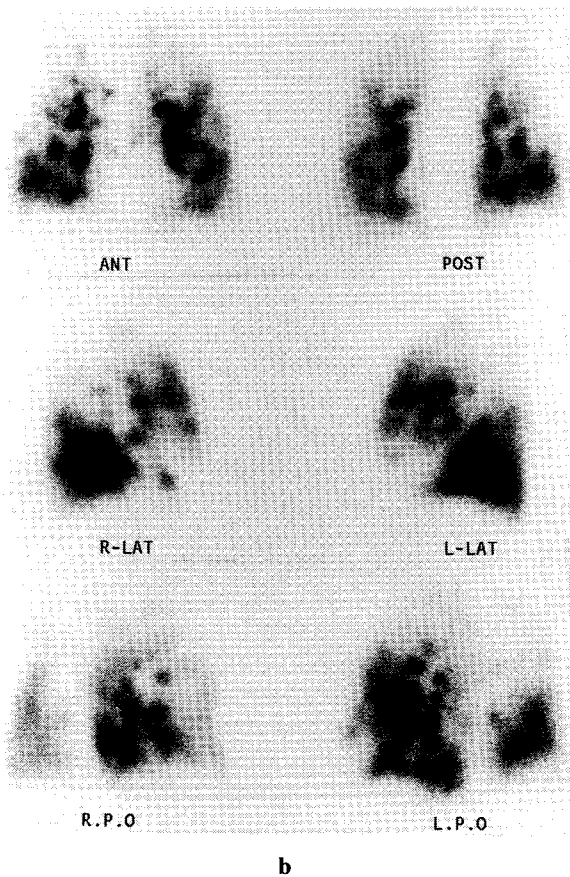
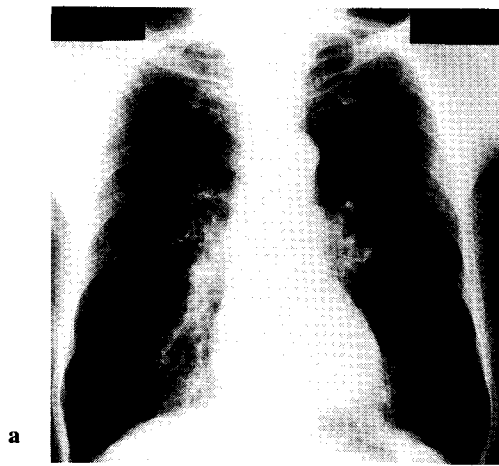


Fig. 1 Case 20. A 69-year-old male. Cigarette index: 900. Chest X-ray film shows the narrowing of pulmonary vessels especially in the upper and lower lung field (a). Planar images of Technegas scintigraphy, Stage IV, shows heterogeneity of the peripheral lung field (b). SPECT, Stage IV, shows heterogeneity, hot spot formation and defects throughout the peripheral lung field: upper (c-i); middle (c-ii); and lower (c-iii) lung fields. In this case, planar and SPECT images are equivalent.

5 mm collimation in a bone detail algorithm during moderate inspiration using two CT scanners, CT9800 and HiSpeed Advantage (General Electric, Milwaukee, Wisconsin, USA). CT images from each lung were displayed with window level - 600 and window width 1,500.

RESULTS

Table 2 shows the results of images of planar and SPECT according to Technegas stages.

Cases 3, 4 and 5 had normal pulmonary function tests.

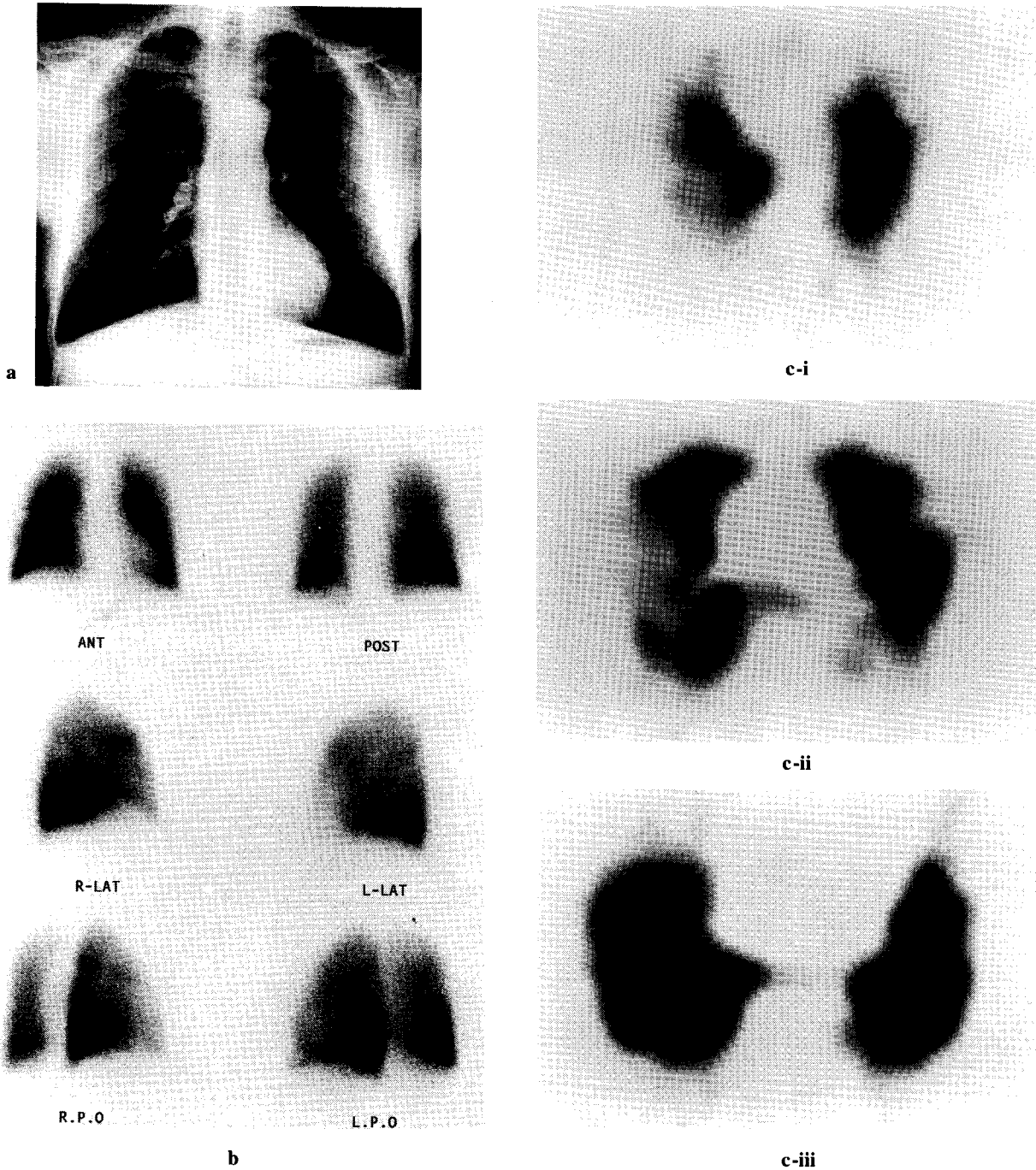


Fig. 2 Case 1. A 62-year-old male. Cigarette index: 1140. Chest X-ray film shows mild pleural thickness at the base bilaterally and no vascular narrowing (a). Planar images of Technegas scintigraphy, Stage II, shows the normal homogeneous distribution (b). SPECT, Stage IV, shows heterogeneity, hot spot formation and defects throughout the peripheral lung fields (c-i, ii, iii). In this case, SPECT is better than planar image.

They showed localized severe bullous changes on CT. In cases 3 and 4, both images of planar and SPECT revealed Stage IV, whereas in case 5, planar images revealed Stage II whereas SPECT revealed Stage IV.

In 14 of the 20 cases (70%), SPECT and planar images of Technegas were equivalent in terms of the degree and range of involvement (Table 2, Group A). With Technegas

SPECT all stages observed were IV in Group A except in case 9, which was shown as Stage III.

In the remaining 6 cases (30%), more detailed findings were shown by SPECT than by planar images (Table 2, Group B). Stages of planar images in Technegas were: 3 as Stage I and 3 as Stage II. All 3 Stage I cases in planar corresponded to stage II in SPECT, and all 3 Stage II cases

corresponded to Stage IV in SPECT. In these cases SPECT showed heterogeneity and hot spot formation which was not observed in planar images. Findings in planar and SPECT images were the same in the more severe cases, Stages III and IV.

Figure 1 shows a case (#20) in which planar and SPECT were equivalent. Figure 2 shows a case (#1) in which SPECT was superior to planar.

DISCUSSION

CT can demonstrate tiny low attenuation areas less than 5 mm in diameter, confirmed by radiologic-pathologic correlative studies.^{8,9} Although spatial resolution of the scintigram in nuclear medicine is inferior to CT, nuclear medicine can depict the physiological kinetic movement and assess the regional pulmonary function in contrast with overall function^{11,12} as with CT.¹³ Ventilation scintigraphy by inert gases such as Xe-133 and Kr-81m has some limitations, such as the necessity for preparation of gases in advance. Furthermore, Xe-133 requires a ventilator system or bag-box spirometer, and Kr-81m is high in cost in spite of the "gold standard."⁶ Although particle size of Technegas is in the order of $0.005 \mu\text{m}^2$, different authors agree that they are more likely less to be than $0.2 \mu\text{m}$.^{4,6} Because particles larger than $2 \mu\text{m}$ are likely to be deposited in the proximal bronchial trunks, Tc-99m phytate aerosol images are not superior to Technegas images and have a limitation due to a intense bronchial foci or hot spot formation in cases with severe chronic obstructive pulmonary disease.⁵ Since the appropriate energy of the Technetium-99m made Technegas delineates the outline of the lung in multiple projections, Technegas is reported to be superior to or not different from Xe-133.^{1,2} However, there have been only few reports about SPECT using Technegas.^{7,13} Zhang et al. reported that an index expressing the subliminal heterogeneous distribution by Technegas SPECT correlated well with severity of silicosis.⁷

Localized pulmonary emphysema, even if it is severe in images on CT or Technegas, does not influence the overall pulmonary function. In comparing planar and SPECT images of Technegas, SPECT showed more detailed findings of advanced stages than planar images in mild Stage I and II cases. This implies that SPECT could be excluded in advanced stages, such as Stage III and IV and replaced by planar images. In Stages III and IV, the more severe cases, images of SPECT and planar are equivalent.

REFERENCES

1. Rimkus DS, Ashburn WL. Lung ventilation scanning with a new carbon particle radioaerosol (Technegas). Preliminary patient studies. *Clin Nucl Med* 15: 222-226, 1990.
2. Amis TC, Crawford ABH, Davison A, Engel LA. Distribution of inhaled ^{99m}Tc-labeled ultrafine carbon particle aerosol (Technegas) in human lungs. *Eur Respir J* 3: 679-685, 1990.
3. Crawford ABH, Davison A, Amis TC, Engel LA. Intrapulmonary distribution of ^{99m}Tc-labeled ultrafine carbon aerosol (Technegas) in severe airflow obstruction. *Eur Respir J* 3: 686-692, 1990.
4. Isawa T, Teshima T, Anazawa Y, Miki M, Motomiya M. Technegas for inhalation lung imaging. *Nucl Med Commun* 12: 47-55, 1991.
5. Peltier P, Bardies M, Chetanneau A, Chatal JF. Comparison of technetium-99m and phytate aerosol in ventilation studies. *Eur J Nucl Med* 19: 349-354, 1992.
6. James JM, Lloyd JJ, Leahy BC, Church S, Hady CC, Shields RA, et al. ^{99m}Tc-Technegas and krypton-81m ventilation scintigraphy: a comparison in known respiratory disease. *Br J Radiol* 65: 1075-1082, 1992.
7. Zhang X, Hirano H, Yamamoto K, Kusaka Y, Sugimoto K, Kimoto T, et al. Technegas ventilation SPECT for evaluating silicosis in comparison with computed tomography. *Ann Nucl Med* 10: 165-170, 1996.
8. Murata K, Itoh H, Todo G. Centrilobular lesions of the lung: demonstration by high-resolution CT and pathologic correlation. *Radiology* 161: 641-645, 1986.
9. Webb WR, Stein MG, Finkbeiner WE, Im JG, Lynch D, Gamsu G. Normal and diseased isolated lungs: high-resolution CT. *Radiology* 166: 81-87, 1988.
10. Suzuki T. Evaluation of the regional lung function revealed in radioaerosol scintigram of chronic obstructive pulmonary disease. I. The comparison of radioaerosol scintigram with the lung function tests in chronic obstructive pulmonary disease. *Nippon Acta Radiologica* 40: 156-167, 1980. (Japanese, abstract in English)
11. Alderson PO, Lee H, Summer WR, Motazed A, Wagner HN. Comparison of Xe-133 washout and single-breath imaging for the detection of ventilation abnormalities. *J Nucl Med* 20: 917-922, 1979.
12. Alderson PO, Secker-Walker RH, Forrest JV. Detection of obstructive pulmonary disease. Relative sensitivity of ventilation-perfusion studies and chest radiography. *Radiology* 111: 643-648, 1974.
13. Satoh K, Tanabe M, Nakano S, Nishiyama Y, Takahashi K, Kobayashi T, et al. Comparison of ^{99m}Tc-Technegas scintigraphy and high resolution CT in pulmonary emphysema. *KAKU IGAKU (Jpn J Nucl Med)* 32: 487-494, 1995. (Japanese, abstract in English)