

Scintigraphic assessment of double-chambered right ventricle

Tsunehiko NISHIMURA, Toshiisa UEHARA and Kohei HAYASHIDA

Department of Radiology, National Cardiovascular Center, Suita, Osaka, Japan

A double-chambered right ventricle is often clinically misdiagnosed and may be missed even during cardiac catheterization. We encountered a 56-year-old male who had abnormal right ventricular thallium-201 uptake and a photon deficient area in the right ventricle by radionuclide cardioangiography. These findings strongly suggested the existence of anomalous muscle band in the right ventricle. It was demonstrated by contrast angiography that the right ventricle was divided into two chambers by a hypertrophic muscular band; the pressure gradient in the right ventricle was 98 mmHg.

Key words: Double-chambered right ventricle, Myocardial perfusion imaging, Gated blood pool scan

INTRODUCTION

THE DIVISION of the right ventricle into two chambers (high and low pressure chambers) by hypertrophic muscle bands is a very unusual congenital cardiac malformation, which may be mistaken for tetralogy of Fallot or an interventricular septal defect. These abnormalities have been called a double-chambered right ventricle.¹⁻³ A correct diagnosis of a double-chambered right ventricle is seldom made clinically and sometimes may be missed during cardiac catheterization. We encountered a patient with a double-chambered right ventricle that was demonstrated by nuclear medicine imaging before cardiac catheterization.

CASE REPORT

A 56-year-old male was admitted to our hospital with a long history of progressive dyspnea upon exertion. He had a heart murmur and mild cyanosis first pointed out at the age of 20, but he had no medical treatment. On admission, his physical examination revealed a bradycardia of 38/min and a blood pressure of 120/72 mmHg. He had a loud

left basilar systolic murmur, and the second sound in this area was diminished in intensity. The electrocardiogram showed complete atrioventricular block and right axis deviation. The chest X-ray showed significant cardiomegaly.

CARDIAC IMAGING

Two dimensional echocardiography was performed using the Toshiba SSH-11A phased array scanner. It was difficult to obtain a correct diagnosis owing to poor echo images, but an interventricular septal defect and aortic regurgitation were detected. Radionuclide cardioangiography was carried out using 20 mCi of ^{99m}Tc-red blood cell. A photon deficient area in the right ventricle was demonstrated by first pass method (Fig. 1). In the static images, a photon deficient area which suggested the existence of hypertrophic muscle band was also observed in the right ventricle (Fig. 2). Myocardial perfusion imaging was carried out using 2 mCi of thallium-201. Abnormal thallium-201 uptake was clearly demonstrated at the right ventricle (Fig. 3). Cardiac catheterization and contrast angiography were performed. The anteroposterior view demonstrated a typical double-chambered right ventricle muscular filling defect, which divided the right ventricle into the ventricular sinus and was obstructing outflow. The lateral view revealed a positive jet from a ventricular septal defect in the systolic phase in addition to the muscular filling defect (Fig. 4). Cardiac catheterization re-

Received April 21, 1987; revision accepted July 15, 1987.

For reprints contact: Tsunehiko Nishimura, M.D., Department of Radiology, National Cardiovascular Center, 5-7-1, Fujishiro-dai, Suita, Osaka 565, JAPAN

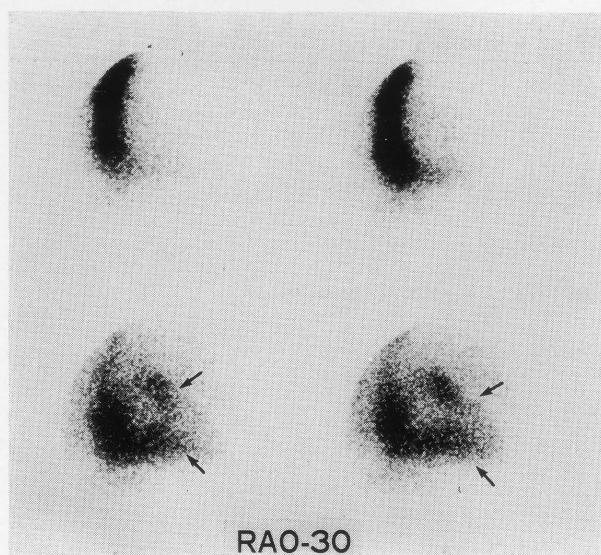


Fig. 1 A photon deficient area (arrows) in the right ventricle was demonstrated by radionuclide cardioangiography.

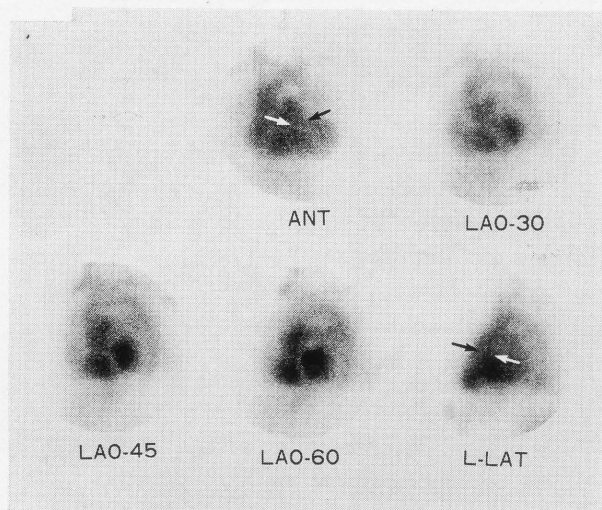


Fig. 2 A photon deficient area (arrows) was also detected at the site of hypertrophic muscle band of the right ventricle in anterior and lateral views of the static images.

vealed the pressure in the high pressure chamber was 125 mmHg, while the pressure in the distal chamber was 27 mmHg. The pressure gradient imposed by the right ventricular muscle bundle was 98 mmHg.

SURGICAL FINDINGS

A surgical resection of the obstructing right ventricular muscle band and VSD patch closure were performed on this patient. In the right ventricle, a thick, wedge-shaped muscle band, extending from the base of the septum to the midportion of the

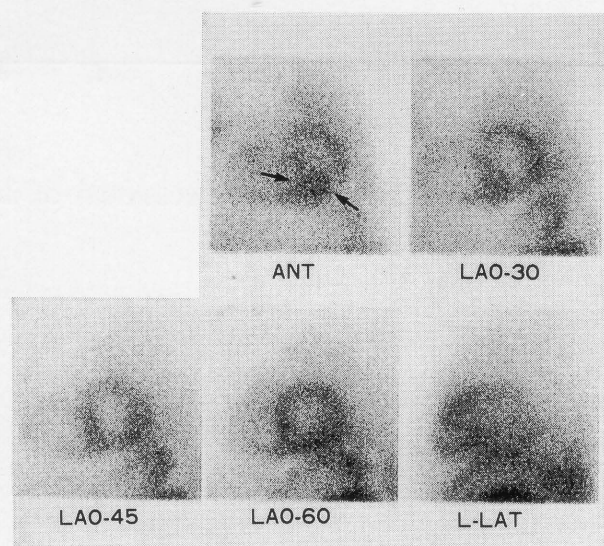


Fig. 3 Abnormal thallium-201 uptake (arrows) was clearly demonstrated in the hypertrophic muscle band at the right ventricle, especially in the anterior view.

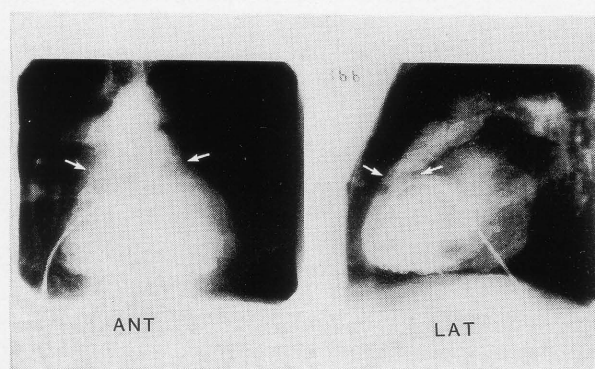


Fig. 4 Contrast angiography showed a typical double-chambered right ventricular filling defect in the anterior and lateral views (arrows). Lateral views showed a positive jet from a ventricular septal defect in the systolic phase.

anterior wall, divided the ventricular cavity into two zones.

DISCUSSION

Tsifutis and Hartmann first described the double-chambered right ventricle in 1961.¹ Although more than 100 cases have been reported, clinical and anatomic entities of double-chambered right ventricle should be separated from other forms of right ventricular obstruction.¹⁻³ Rowland et al³ reviewed seventeen patients with double-chambered right ventricles, but the correct diagnosis was not made prior to catheterization in any of these patients. Our case was also diagnosed to have a ventricular septal defect or tetralogy of Fallot on the basis of clinical findings.

Echocardiography has been used as the first choice for the diagnosis of congenital heart disease, but it has some problems such as bone and air transmission. Cardiovascular nuclear imaging has been also established for the evaluation of cardiac structure and function. In this case, abnormal thallium-201 uptake and a photon deficient area in the right ventricle by radionuclide cardioangiography suggested the existence of hypertrophic muscle band in the right ventricle, although photon deficient areas were also generally observed in cases such as cardiac tumor or thrombi.⁴⁻⁵ By selective angiography, it was confirmed that the right ventricle was divided into two chambers by hypertrophic muscle band. Thus, these scintigraphic findings should be considered to demonstrate anomalous muscle band in cases with double-chambered right ventricle, since accurate diagnosis may have important surgical implications.

REFERENCES

1. Tsifutis AA, Hartmann AF, Arvidsson H: Two-chambered right ventricle: Report on seven patients. *Circulation* 24: 1058, 1961
2. Lucus RV, Varco RL, Lillhei CW, et al: Anomalous muscle bundle of the right ventricle: Hemodynamic consequence and surgical consideration. *Circulation* 25: 433, 1962
3. Rowland TW, Rosenthal A, Castaneda AR: Double-chambered right ventricle: Experience with 17 cases. *Am Heart J* 89: 455, 1975
4. Pohost GM, Pastore JO, Mckusick KA, et al: Detection of left atrial myxoma by gated radionuclide cardiac imaging. *Circulation* 55: 88, 1977
5. Stratton TR, Ritchie JL, Hammermeister KE, et al: Detection of left ventricular thrombi with radionuclide angiography. *Am J Cardiol* 48: 565, 1981