Annals of Nuclear Medicine Vol. 1, No. 1, 43–46, 1987

Iodine-123 IMP SPECT before and after bypass surgery in a patient with occlusion of left anterior and middle cerebral arteries with basal abnormal telangiectasis (unilateral Moyamoya disease)

Norinari HONDA,* Kikuo MACHIDA,* Teruo TAKISHIMA,* Hiroyuki KAIZU* and Eiichi SUGIMOTO**

*Department of Radiology, Saitama Medical Center, Saitama Medical School
**Department of Radiology, Saitama Medical School Hospital

A case of left anterior and middle cerebral arterial occlusion with angiographic features similar to Moyamoya disease was reported. IMP SPECT of the patient revealed the success of bypass surgery clearly. The patient complained of transient right hemiparesis with aphasia 4 times. The cerebral arteriography disclosed occlusions of left anterior and middle cerebral arteries at their proximal portions. Right internal carotid and its branches were normal. I-123 IMP SPECT study showed hypoperfusion in left temporal lobe, basal ganglia with incomplete reperfusion on the delayed (4 hours after injection) SPECT images. After the superficial temporal-middle cerebral artery anastomosis, I-123 IMP SPECT showed improvement of the brain blood flow. I-123 IMP SPECT was very useful in detecting the ischemic areas and evaluating the revascularizing surgery in this case.

Key words: Moyamoya disease, Transient ischemic attack, Reversible ischemic neurological deficit, I-123 IMP SPECT

INTRODUCTION

MOYAMOYA DISEASE is defined as the idiopathic bilateral occlusions of distal portions of intracranial internal carotid arteries with basal telangiectasis (Moyamoya phenomenon).[1] There is a group of patients who do not fit the definition of Moyamoya disease but have similar clinical and angiographic features of Moyamoya disease.[1–4] We recently had a patient with such atypical Moyamoya disease, or unilateral Moyamoya disease. N-isopropyl-p-(^{123}I) iodoamphetamine single photon emission computed tomography (I-123 IMP SPECT) was useful in detecting an ischemic area and evaluating the result of revascularization surgery in the patient. As far as we know, this is the first reported case of unilateral Moyamoya disease in which IMP SPECT was useful.

Received April 24, 1987; revision accepted June 15, 1987.

For reprints contact: Norinari Honda, Department of Radiology, Saitama Medical Center, Saitama Medical School, 1981 Tsujido, Kamoda, Kawagoe, Saitama 350, JAPAN.

CASE REPORT

Case: female, 33 years of age.

The patient was admitted to the Department of Neurosurgery, Saitama Medical Center on February 25, 1987, complaining of 4 episodes of transient right hemiparesis. The episodes had occurred in August 1985, February and June 1986, and January 1987, with a fairly identical pattern. After feeling tightness over the right side of her face, she noticed muscle weakness in her right upper extremity, and then weakness in her right lower extremity. She was alert but unable to speak during the episodes. The attacks lasted 2–3 minutes with full recovery of her neurological deficits.

Her left ovary had been resected for endometriosis at 26 years of age. She had been suffering from a left ureter stone from 32 years of age. She did not give a past history of meningitis, diabetes mellitus, or tuberculosis. She denied intravenous drug abuse and had never taken oral contraceptive pills.

She was in no acute distress at the admission with BT of 36.9 C, PR of 78/min, and BP 134/80. The neurological examination was normal. Peripheral

arterial pulses including carotid pulses felt bilaterally equal. Vascular bruits were not heard over her neck, supraclavicular areas, or abdomen. The lung and heart sounds were normal.

Neither anemia, thrombocytosis, nor erythrocytosis was noticed in the blood cell count. Blood coagulation studies (activated partial thromboplastine time, prothrombine time, bleeding time) were normal. Erythrocyte sedimentation rate was 10 mm/hour and CRP was negative. Cardiac ultrasound was normal without intracardiac thrombus or mitral stenosis. EEG was interpreted as normal though spiky waves were found in left temporal leads. CT of the brain was normal except for punctate enhancing spots on left hemisphere after contrast enhancement (Fig. 1). Cerebral arteriography disclosed occlusions of the left anterior cerebral and of the middle cerebral arteries at their proximal portions with basal abnormal telangiectasis and collateral flow (Fig. 2). The right internal carotid artery and its branches were normal. Left superficial temporal-middle cerebral arterial anastomosis (STA-MCA anastomosis) was performed on March 10, 1987, with success. She took an uneventful postoperative course, and has been free from attacks of right hemiparesis after the operation.

Brain SPECT studies were performed before and after the operation using 3 mCi (111 MBq) of I-123 IMP. IMP was injected intravenously after covering her eyes with a mask. SPECT was performed 30 minutes after (early scan) and 4 hours after (delayed scan) the injection. Sixty-four scintigraphic images (64×64 pixels, 30 s/frame) were collected during a 360-degree rotation of a gamma camera (ZLC 7500, Siemens) equipped with a slant hole collimator (NuTech). Transverse images were reconstructed by Shepp-Logan filtered back projection method with absorption correction. IMP SPECT showed decreased perfusion in left temporal lobe and left basal ganglia with incomplete reperfusion on delayed SPECT images (Fig. 3A, B). The second I-123 IMP SPECT done 17 days after the operation showed improvement of the cerebral blood flow on early (Fig. 3C) and delayed images. Intra-arterial digital subtraction angiography of the left common carotid showed the patent anastomosis and blood flow to the temporal areas.

DISCUSSION

Our case represents a peculiar type of cerebrovascular occlusive disease that does not completely fit the criteria of Moyamoya disease. Moyamoya disease is defined as an idiopathic disease characterized by 1) bilateral occlusions or stenosis of carotid gabels, 2) abnormal basal telangiectasis.[1] Our case does not fit the recently recognized clinical entity, idiopathic occlusion of the middle cerebral artery,[2] since the anterior cerebral artery was affected. Tuberculous meningitis, drug toxicity and atherosclerosis were unlikely either from her past history or from angiographic features. The most suitable diagnosis of our case would be atypical Moyamoya or unilateral Moyamoya disease. Since some cases of unilateral Moyamoya disease are known to progress to typical Moyamoya disease,[1,3–5] our patient must be carefully followed. IMP SPECT will be a very useful noninvasive examination to assess the disease progression, if any, in this patient.

IMP SPECT of our patient detected an ischemic area in the brain which had shown normal CT and determined that the anastomosis was functioning well after the revascularization surgery. To our knowledge, there are only a limited number of reports on improved IMP accumulation after STA-MCA anastomosis.[6–9] These patients were diagnosed as having occlusions of the internal carotid[6,7,9] and occlusion of the right middle cerebral artery.[8] So this is the first case report of unilateral Moyamoya disease with STA-MCA anastomosis followed by I-123 IMP SPECT. Previous investigators suggested that IMP SPECT is useful in evaluating the results of surgery. Our experience with this case supports their opinion.

Defects found by IMP SPECT in patients with normal CT are reported by several authors.[8–10] Diagnoses of these patients (except for cerebral infarction in acute stage) are Moyamoya disease,[8,10] occlusion of middle cerebral,[8] internal carotid,[8] and frontal ascending arteries,[9] and cerebellar hemorrhage.[10] Tanada et al[11] found abnormal IMP SPECT with normal brain CT in 4 out of 37 patients. Clinical presentation of these patients are reversible ischemic neurological deficit (RIND), transient ischemic attack (TIA), and convulsive seizure. Thus our case had a clinical presentation similar to the reported cases.

ACKNOWLEDGMENTS

The authors thank Professor Takao Asano, Associate Professor Taku Shigeno, Hiroo Jyosita, MD, Kazuya Nagata, MD, and Tohru Matsui, MD, of the Department of Neurosurgery, Saitama Medical Center, for referring the patient to us. The authors also thank Mr. Keiji Suzuki for his technical help and Miss Yasuko Soya for her secretarial help.

REFERENCES

1. Nishimoto A: Angiographic criteria of cerebrovascular Moyamoya disease. *Advances in Neurol Sciences* 20: 758–767, 1976
2. Fukawa O, Aihara H, Wakasa H: Middle cerebral

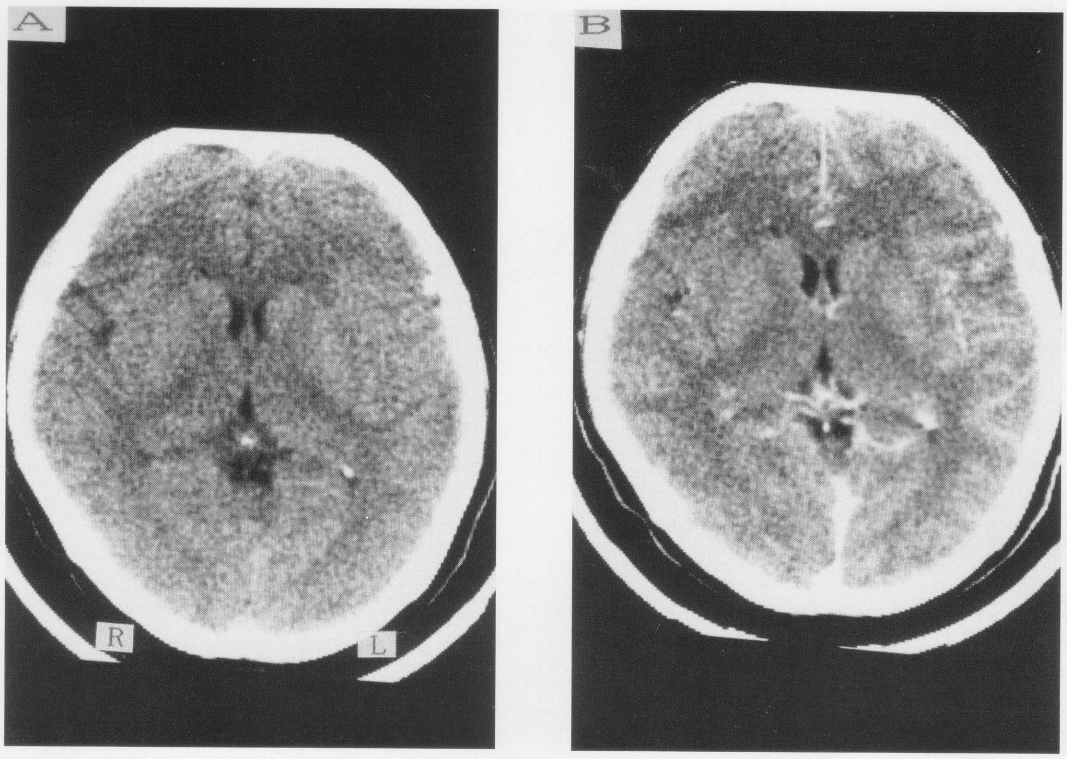

Fig. 1 Brain CT. No abnormal low density areas were noted both before (A) and after (B) infusion of contrast material. Punctate enhancing spots on left hemisphere (B) are probably dilated collateral vessels.

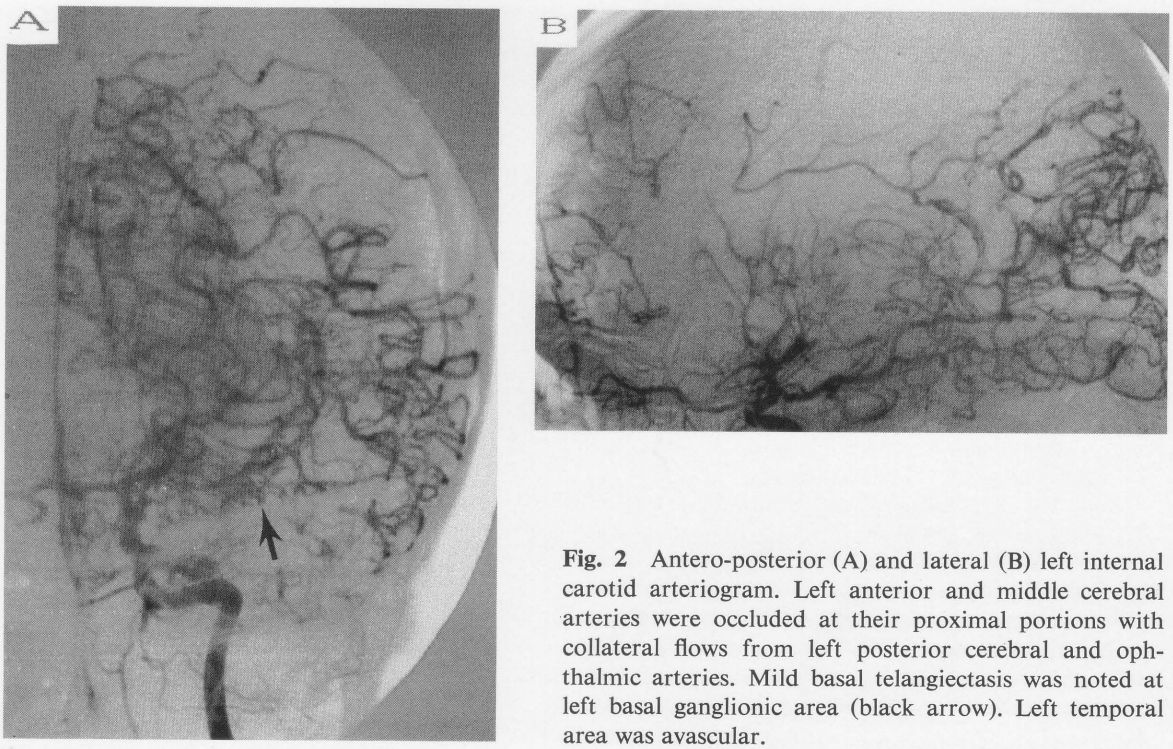

Fig. 2 Antero-posterior (A) and lateral (B) left internal carotid arteriogram. Left anterior and middle cerebral arteries were occluded at their proximal portions with collateral flows from left posterior cerebral and ophthalmic arteries. Mild basal telangiectasis was noted at left basal ganglionic area (black arrow). Left temporal area was avascular.

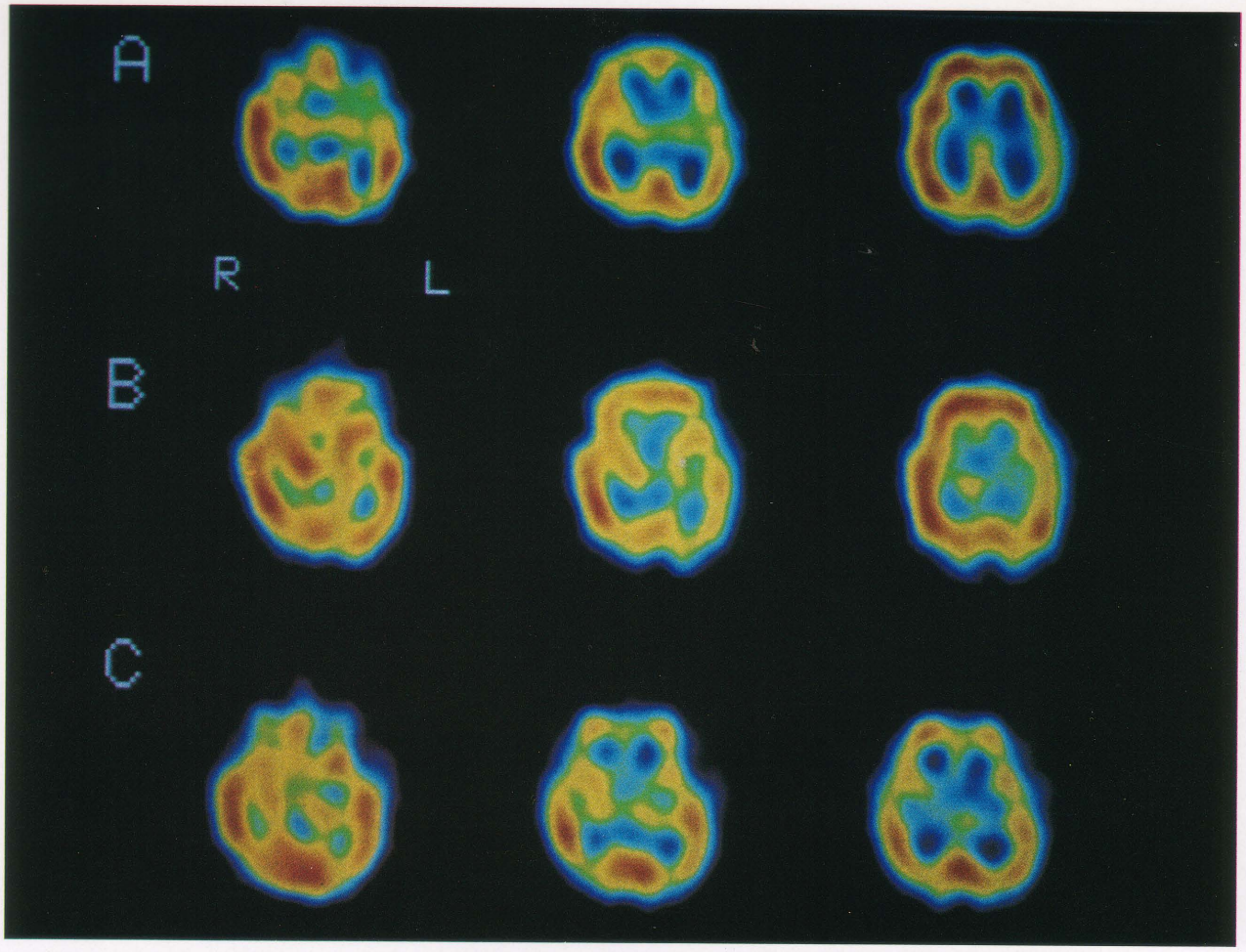

Fig. 3 Transverse images of I-123 IMP SPECT. Hypoperfused area was found at left temporal lobe and basal ganglionic area (A) with incomplete reperfusion on delayed image (B) before STA-MCA anastomosis. After operation, early SPECT showed normal cerebral blood flow except for left caudate nucleus (C). Delayed SPECT images after operation did not show reperfusion.

artery occlusion with moyamoya phenomenon. Second report: Report of an autopsy case. *Neurological Surgery* 10: 1303–1310, 1982

3. Murphy MJ: Progressive vascular changes in moyamoya syndrome. *Stroke* 11: 656–685, 1980
4. Galligioni F, Andrioli GC, Matrin G, et al: Hypoplasia of the internal carotid artery associated with cerebral pseudoangiomatosis. Report of 4 cases. *Amer J Roentogenol* 112: 251–262, 1971
5. Taveras JM: Multiple progressive intracranial arterial occlusion: A syndrome of children and young adults. *Amer J Roentogenol* 106: 235–268, 1969
6. Shiozaki H, Kishikawa T, Ikeda J, et al: Evaluation of STA-MCA anastomosis using N-isopropyl-p-[^{123}I]Iodoamphetamine brain imaging. A case report. *Jpn J Nucl Med* 22: 229–232, 1985
7. Wada M, Ichiya Y, Katsuragi M, et al: Clinical evaluation of N-isopropyl-p-I-123-Iodoamphetamine—Iodoamphetamine in cerebrovascular disorders—comparison study with X-ray CT and positron CT. *Jpn J Nucl Med* 22: 1477–1483, 1985
8. Sakai F, Tazaki Y, Ishii K, et al: Measurement of regional cerebral blood flow using N-isopropyl-p-[^{123}I]iodoamphetamine in patients with stroke. *Jpn J Stroke* 7: 402–410, 1985
9. Kawamura M, Murase K, Nagao S, et al: Cerebral perfusion studies with N-isopropyl-p-(^{123}I)iodoamphetamine and SPECT in cerebrovascular disorders. *Nippon Act Radiol* 46: 38–47, 1986
10. Sone T, Fukunaga M, Otsuka N, et al: Scintigraphy of cerebral blood flow with N-isopropyl-p-[^{123}I]-iodoamphetamine in cerebrovascular accident. *Jpn J Nucl Med* 22: 1447–1459, 1985
11. Tanada S, Yonekura Y, Torizuka K, et al: The single photon emission computed tomography with N-isopropyl-p-(I-123) iodoamphetamine in cerebrovascular disease compared with X-ray CT findings. *Jpn J Stroke* 7: 275–282, 1985